

Case Report

First reported case of COVID-19 induced permanent third-degree atrioventricular (AV) block in a young patient

Lucy Hickcox¹, Matthew RW Smolin¹, Mohammad Reza Movahed^{1,2,3}

¹Mercy Hospital, Durango, Colorado, USA; ²University of Arizona Sarver Heart Center, Tucson, Arizona, USA; ³University of Arizona, Phoenix, Arizona, USA

Received May 17, 2023; Accepted August 7, 2023; Epub August 15, 2023; Published August 30, 2023

Abstract: SARS-CoV2 virus, COVID-19, was first reported in Wuhan, China in 2019. The most common symptoms of COVID-19 are dry cough, fever, and diarrhea that occur within 2-14 days of exposure. Primary infection from COVID-19 develops in the respiratory tract. Cardiovascular disease has become a more prominent manifestation of COVID-19 infection, however very little is known regarding the impact of COVID-19 on the cardiac conduction system. We present a young patient with COVID-19 who developed a permanent third-degree Atrioventricular (AV) heart block. This report is the first documentation of COVID-19 induced permanent third-degree heart block in a young male.

Keywords: High grade AV block, SARS-CoV2 infection, pacemaker, arrhythmias, bradycardia, conduction defect

Introduction

In December 2019, SARS-CoV-2, a new strain of coronavirus was identified in Wuhan, China. By March of 2020, the World Health Organization (WHO) declared the COVID-19 outbreak a pandemic. According to the WHO as of February 7, 2022, 410,565,868 cumulative cases of COVID-19 infection have been confirmed with 5,810,88 deaths worldwide. As of February 14, 2022, 77,707,349 had confirmed COVID-19 infection in the United States with 919,255 deaths.

While the symptoms of COVID-19 can vary the most common symptoms, including fever, dry cough, and occasionally diarrhea, usually develop within 2 to 14 days of exposure [1]. An early study on clinical characteristics of COVID-19 patients from Wuhan, China reported that the primary infection develops in the respiratory tract with resulting complications being predominantly acute respiratory distress and secondly arrhythmias, experienced in 44% of patients requiring intensive care [2]. While respiratory complications are the main clinical mani-

festation of COVID-19, cardiovascular issues including thromboembolic events, myocarditis, and pericarditis are not uncommon. Cardiac injury has been reported in 19.7% of patients during hospitalization [3, 4].

Cardiac arrhythmias are common in patients with COVID-19 infection. It appears to be related to direct injury due to COVID-19 infection and the multi-organ injury leading to arrhythmias. Adverse reactions to multiple drugs used in critically ill patients with COVID-19 infection also play a role in the occurrence of cardiac arrhythmias. A recent large study of 700 patients with COVID-19 receiving intensive care revealed 9 cardiac arrests, 9 bradyarrhythmias, 25 incident atrial fibrillation, and 10 non-sustained ventricular arrhythmias [5]. The occurrence of cardiac arrests was associated with an increase in mortality.

The occurrence of bradycardia in patients with COVID-19 infection is not uncommon. A retrospective case series of four patients with significant bradycardia revealed mostly sinus bradycardia occurring after 9 to 15 days post-

admission [6]. All four patients were treated sometime during their stay with propofol and during bradycardia and 3 patients were receiving corticosteroid therapy. The etiology of transient sinus bradycardia is multifactorial needing increasing awareness. There have been case reports of patients developing cardiac conduction abnormalities in the setting of COVID-19 but there have been no reports of patients experiencing permanent AV block and only a few reports of young patients developing transient or lesser degrees of AV block [1-3, 7-11]. Third degree AV block is diagnosed based on atrioventricular dissociation with atrial electrical activity not conducted into the ventricle. It will lead to escape rhythm being initiated in the AV junction or ventricle at much lower rate than sinus rhythm. Escape rhythm initiation in the left ventricle is usually very slow and wide and is poorly tolerated. In most cases, urgent temporary pacer insertion followed by a permanent pacer insertion is necessary unless it was related to a reversible cause. Junctional escape rate is usually higher than ventricular escape and is better tolerated. However, it is commonly associated with dizziness, syncope, fatigue and poor exercise tolerance that requires pacemaker insertion for definite treatment. In this case, we present a young patient hospitalized with COVID-19 who was found to have symptomatic bradycardia secondary to permanent third-degree atrioventricular (AV) heart block. The case is presented without identifier and based on IRB, consent is waved.

Case report

A 36-year-old athletic male mountain biker with no significant past medical or cardiac history suffered from upper respiratory symptoms 6 weeks before hospital admission. He had a positive test by polymerase chain reaction (PCR) for COVID-19 infection at that time. The patient had received the second dose of the Moderna vaccine at the end of May 2021. Two months later, he suffered from severe fatigue and persistent bradycardia at the time of his positive COVID-19 testing with a heart rate (HR) in the 30 s. He was diagnosed with a breakthrough COVID-19 infection. His symptoms gradually improved but his exercise tolerance remained very limited and he could not raise his heart rate appropriately with activities. Due to persistent fatigue and bradycardia, he went

to urgent care where he denied any significant dizziness or syncope.

Initial diagnosis/assessment

He was found to be in third-degree Atrioventricular (AV) block and was sent to our emergency department. A repeat electrocardiogram (EKG) confirmed the diagnosis of third-degree AV block with junctional escape (**Figure 1**). The patient was a very healthy young man in the past with no previous EKG. His vital signs included normal blood pressure and oxygen saturation with a HR of 30-40 beats per minute. His complete heart block did not respond to atropine administration in the emergency department. Further testing including a chest x-ray, echocardiogram, complete metabolic panel, complete blood count (CBC), and a thyroid-stimulating hormone (TSH), were all within normal limits. Due to his stable condition, he was discharged. His 30 days Holter monitor showed persistent third-degree AV block. He underwent treadmill stress testing using the Bruce protocol on which he exercised for 12 minutes attaining a peak heart rate of 44 beats per minute with persistent third-degree AV block (**Figure 2**). His Lyme titer was negative. His magnetic resonance imaging (MRI) testing of his heart was completely normal without any late gadolinium enhancement. After few months of observation, his third-degree AV block persisted leading to a permanent dual chamber pacemaker insertion.

Treatment/management

Treatment of acquired third-degree AV block is a class 1 indication for pacer insertion. However, congenital third-degree AV blocks are usually asymptomatic as AV nodes will take over the function of the sinus node with normal heart rate adjustment with activities. Initially, he was very symptomatic and therefore, pacer insertion would have been appropriate. However, he refused pacer insertion initially due to his excellent functional capacity. Electrophysiological testing of his conduction system could have been helpful in order to get more information about the location of the AV block and any potential conduction response to pacing. However, the patient also refused any further electrophysiological testing and finally underwent permanent dual chamber pacer inser-

COVID-19 associated third degree AV block

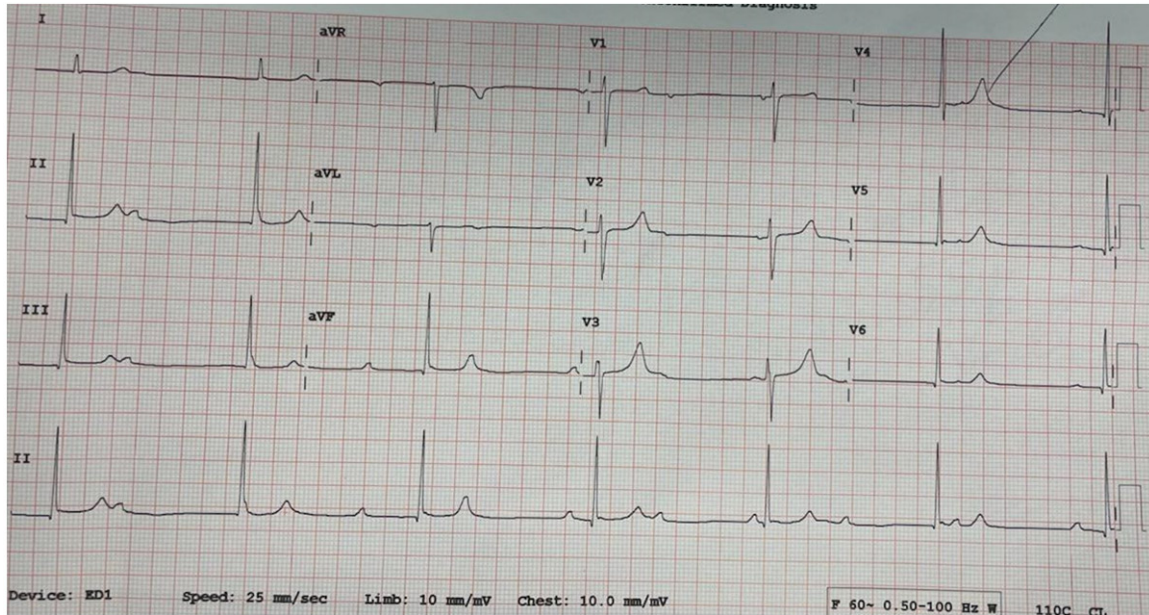


Figure 1. EKG showing third degree AV block with a junctional escape rhythm.

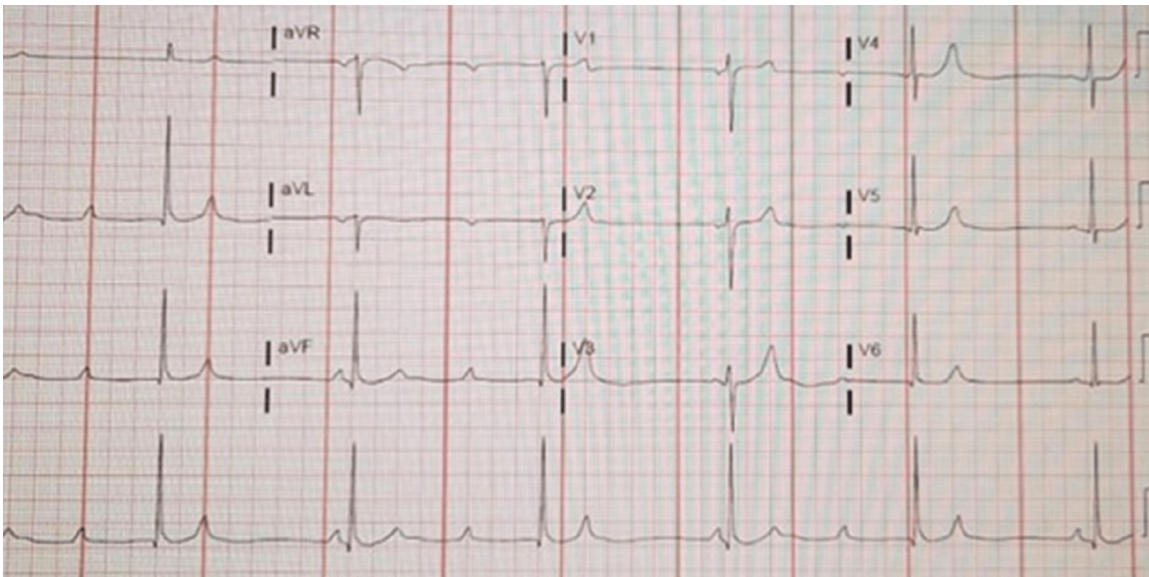


Figure 2. Persistent third degree AV block seen during his entire exercise test with max HR of 44.

tion 3 months later due to persist third degree AV-block and severe bradycardia with limited functional capacity.

Discussion

COVID-19 infection can involve cardiovascular system in different levels. It can affect myocardium directly and cause a rare cause of myocarditis. We believe that our patient suffered

from a mild form of myocarditis leading to his third degree AV block. Pericarditis has been also reported. The most devastating effect of COVID-19 infection involving cardiovascular system is related to increase in thrombogenesis that can lead to pulmonary embolism and myocardial infarction. New-onset AV node disease can develop from ischemic cardiac disease, cardiomyopathy, myocarditis, endocarditis, thyroid disease, and medications [1, 4].

COVID-19 may contribute to the etiology of AV node conduction disruption. COVID-19 has been shown to contribute to and cause cardiovascular diseases in 19.7% of patients [2]. A study performed in June of 2020, analyzed the occurrence of varying cardiac arrhythmias in COVID-19 patients reported by 1,197 respondents. These issues ranged from atrial fibrillation (20.79% reported) and atrial flutter (5.42%) to AV block (13.57%), and bundle branch blocks (2.42%) [11]. Emerging case reports have shown that patients with COVID-19 have occasionally developed heart block. One case presented a 44-year-old male with new-onset diabetes and no cardiac history who tested positive for COVID-19 and experienced transient complete heart block [1]. Another case presented an 82-year-old male who presented with shortness of breath and a dry cough. He tested positive for COVID-19 and shortly after endotracheal intubation developed a complete heart block. This report also presented a 55-year-old male with no medical history who developed transient second-degree heart block on day six of admission after receiving a positive COVID-19, and a 43-year-old male with no medical history who tested positive for COVID-19 on day six of admission and developed intermittent complete heart block on day 24 of admission [3]. Additionally, a case was presented of a 10-year-old male with a 7-day history of fever, fatigue, cough, and diarrhea who developed first-degree heart block after 24 hours of admission that resolved overnight, and transient complete heart block on day three of admission [10]. None of these cases resulted in permanent heart block however they do demonstrate that transient conduction abnormalities may be seen in the setting of COVID-19.

While all degrees of AV block have been reported in COVID-19 patients, there have been few to no reports on patients developing permanent AV block from COVID-19 infections. In this case, we present a 36-year-old male with no previous significant medical history who developed permanent third-degree AV heart block. While the long-term effects of COVID-19 continue to be studied this case presents a previously unreported permanent complication of COVID-19. The patient had the vaccination before few months before his breakthrough infection. Therefore, it is doubtful that the vaccine played any role in the occurrence of his

third-degree AV block. We cannot be 100% certain that his third-degree AV block was related to COVID-19 infection. However, the occurrence of his third degree AV block shortly after having COVID-19 infection with symptoms is highly suggestive of COVID-19 induced third-degree AV block. His MRI was negative for any scarring. However, with a spatial resolution of a cardiac MRI of 1.5×1.8 mm [12], it would be impossible to detect a small area of scarring in the AV node. Case series of 6 patients requiring permanent pacemaker insertion during their COVID-19 infection have been reported [13]. However, all these 6 patients were elderly patients with severe COVID-19 infection requiring hospitalization for very critical conditions. Our case is unique as the third-degree AV block occurred in a young person with previous vaccination who had only self-limiting mild upper respiratory symptoms.

Conclusion

Clinicians need to be aware of the occurrence of permanent high-grade AV block even in young patients with COVID-19 infection regardless of immunization status. This condition can occur in patients with normal cardiac function and normal MRI. Future studies hopefully can shed light on the pathogenesis of this condition.

Disclosure of conflict of interest

None.

Address correspondence to: Dr. Mohammad Reza Movahed, Clinical Medicine, University of Arizona Sarver Heart Center, 1501 North Campbell Avenue, Tucson, Arizona 85724, USA. Tel: 949-400-0091; E-mail: rmova@aol.com

References

- [1] Chen JH, Robinson B, Patel P, Kata P, Kanukuntla AK, Okere A and Cheriya P. Transient complete heart block in a patient with COVID-19. *Cureus* 2021; 13: e15796.
- [2] Wang D, Hu B, Hu C, Zhu F, Liu X, Zhang J, Wang B, Xiang H, Cheng Z, Xiong Y, Zhao Y, Li Y, Wang X and Peng Z. Clinical characteristics of 138 hospitalized patients with 2019 novel coronavirus-infected pneumonia in Wuhan, China. *JAMA* 2020; 323: 1061-1069.
- [3] Eneizat Mahdawi T, Wang H, Haddadin FI, Al-Qaysi D and Wylie JV. Heart block in patients with coronavirus disease 2019: a case series

COVID-19 associated third degree AV block

- of 3 patients infected with SARS-CoV-2. *Heart-Rhythm Case Rep* 2020; 6: 652-656.
- [4] Shi S, Qin M, Shen B, Cai Y, Liu T, Yang F, Gong W, Liu X, Liang J, Zhao Q, Huang H, Yang B and Huang C. Association of cardiac injury with mortality in hospitalized patients with COVID-19 in Wuhan, China. *JAMA Cardiol* 2020; 5: 802-810.
- [5] Manolis AS, Manolis AA, Manolis TA, Apostolopoulos EJ, Papatheou D and Melita H. COVID-19 infection and cardiac arrhythmias. *Trends Cardiovasc Med* 2020; 30: 451-460.
- [6] Amaratunga EA, Corwin DS, Moran L and Snyder R. Bradycardia in patients with COVID-19: a calm before the storm? *Cureus* 2020; 12: e8599.
- [7] Dagher L, Wanna B, Mikdadi G, Young M, Sohns C and Marrouche NF. High-degree atrio-ventricular block in COVID-19 hospitalized patients. *Europace* 2021; 23: 451-455.
- [8] Ricardo JV, Christian JL, Qassem KA, Conte JJ, Lattanzio N, Wiese-Rometsch W and Cheng HG. Complete heart block in a patient with COVID-19. *International Archives of Cardiovascular Diseases* 2021; 5.
- [9] Azarkish M, Laleh Far V, Eslami M and Mollazadeh R. Transient complete heart block in a patient with critical COVID-19. *Eur Heart J* 2020; 41: 2131.
- [10] Assaad IE, Hood-Pishchany MI, Kheir J, Mistry K, Dixit A, Halyabar O, Mah DY, Meyer-Macaulay C and Cheng H. WITHDRAWN: complete heart block, severe ventricular dysfunction and myocardial inflammation in a child with COVID-19 infection. *JACC Case Rep* 2020; [Epub ahead of print].
- [11] Gopinathannair R, Merchant FM, Lakkireddy DR, Etheridge SP, Feigofsky S, Han JK, Kabra R, Natale A, Poe S, Saha SA and Russo AM. COVID-19 and cardiac arrhythmias: a global perspective on arrhythmia characteristics and management strategies. *J Interv Card Electrophysiol* 2020; 59: 329-336.
- [12] Saeed M, Van TA, Krug R, Hetts SW and Wilson MW. Cardiac MR imaging: current status and future direction. *Cardiovasc Diagn Ther* 2015; 5: 290-310.
- [13] Akhtar Z, Leung LW, Kontogiannis C, Zuberi Z, Bajpai A, Sharma S, Chen Z, Beeton I, Sohal M and Gallagher MM. Prevalence of bradyarrhythmias needing pacing in COVID-19. *Pacing Clin Electrophysiol* 2021; 44: 1340-1346.