

## Review Article

# Tubal origin of ovarian low-grade serous carcinoma

Chenglu Chen<sup>1</sup>, Jie Li<sup>2,3,4</sup>, Guang Yao<sup>1,5</sup>, Setsuko K Chambers<sup>2,5</sup>, Wenxin Zheng<sup>2,3,4,5</sup>

<sup>1</sup>Department of Molecular and Cellular Biology, University of Arizona, Tucson, AZ, USA; <sup>2</sup>Department of Obstetrics and Gynecology, University of Arizona, Tucson, AZ, USA; <sup>3</sup>Department of Pathology, University of Arizona College of Medicine, Tucson, AZ, USA; <sup>4</sup>Department of Obstetrics and Gynecology, Qilu Hospital, Shandong University, Shandong, China; <sup>5</sup>Arizona Cancer Center, University of Arizona, Tucson, AZ, USA

Received October 2, 2013; Accepted November 10, 2013; Epub December 7, 2013; Published December 15, 2013

**Abstract:** Our understanding of the carcinogenesis and histogenesis of ovarian cancer has undergone a paradigm shift in recent years, after accumulating evidence from morphologic and molecular genetic studies. Findings from these studies suggest that both high-grade and low-grade serous ovarian cancers, traditionally believed to start from the ovarian surface, may originate from the distal fallopian tube. This article reviews recent evidence for the tubal origin of serous ovarian cancers, especially the low-grade serous carcinomas.

**Keywords:** Ovarian cancer, serous carcinoma, fallopian tube, cell of origin

### Introduction

Ovarian cancers are the 5<sup>th</sup> leading cause of cancer-related deaths in women and the most lethal gynecologic malignancy. In 2013, it is estimated that 22,240 new cases of ovarian cancers will be diagnosed, with 14,030 associated deaths from this disease [1]. Ovarian epithelial cancers (OECs) account for 80~90% of all ovarian cancers. Among OECs, serous carcinomas are the most common, accounting for ~70% of all cases [2].

Serous ovarian cancers can be divided into two broad groups: type I or low-grade serous carcinomas (LG-SCs), and type II or high-grade serous carcinomas (HG-SCs). LG-SCs are generally present at early stages and clinically less aggressive; they rarely harbor TP53 mutations, instead, contain other specific mutations (e.g. *KRAS* and *BRAF*) and are genetically relatively stable. On the contrary, HG-SCs are clinically aggressive; they frequently display TP53 mutations and are genetically unstable [3]. HG-SCs account for the majority (~90%) of ovarian serous cancers while LG-SCs account for ~10%.

How do ovarian serous cancers originate and develop? Last decade has seen a paradigm

shift in ovarian cancer carcinogenesis. Rather than starting from the ovarian surface, many ovarian HG-SCs have been surprisingly found to originate from the distal fallopian tube, possibly from expansion of secretory cells, as shown by a large body of recent clinical-pathological and molecular studies [4-9].

The cell of origin of LG-SCs is less clear compared with that of HG-SCs. LG-SCs are thought to evolve in a stepwise fashion, from ovarian epithelial inclusions (OEI) to benign cystadenomas and borderline tumors, and finally to LG-SCs [3, 10]. Li, et al. recently suggested that the majority of OEIs are derived from the fallopian tube rather than ovarian surface epithelium (OSE), and that the tubal secretory cells are likely the cell origin of LG-SCs [11]. This central role of the fallopian tube in LG-SC development has received further support [12, 13]. Here we summarize evidence for the fallopian tube as the site of origin for ovarian LG-SCs.

### LG-SCs evolve from OEIs

The stepwise development of LG-SCs from OEIs is supported by several morphological and histological observations. First, the majority of benign cystadenomas seem to derive from

## Tubal origin of ovarian low-grade serous carcinoma

OEIs, as cystadenomas display an epithelial lining similar to that of OEIs morphologically and immunophenotypically. Actually, the diagnostic criterion that separates cystadenomas from OEIs is merely an arbitrary threshold made at the 1 cm size [14]. Second, histological transitions from cystadenomas to borderline tumors are observed at high frequency in nearly 75% of cases [15]. Third, borderline tumors are found associated with the majority of LG-SCs [16]. It is seen that, foci of true early invasion in borderline tumors resemble LG-SCs [15, 17-19], and, invasive implants mostly associated with micropapillary serous borderline tumors, which has been recently defined as LS-SC [20-22], are histologically identical to LG-SCs [23, 24]. All these morphological and histological observations support a model wherein LG-SCs evolve from OEIs, via intermediate stages of serous cystadenomas and borderline tumors.

### OEIs' tubal origin

Since OEIs may represent the earliest putative precursor for LG-SCs, origination of OEIs may provide cues of the LG-SC origin. Recently, the morphologic and immunophenotypic features of OEIs, serous tumors (cystadenomas, borderline tumors, and LG-SCs), ovarian surface epithelium (OSE), and distal tubal epithelium were evaluated [11]. Two types of OSE were found: the vast majority of OSE displayed a mesothelial phenotype (calretinin+/PAX8-/tubulin-) and a low proliferative index (0.012), while about 4% of cases displayed foci with tubal phenotype (calretinin-/PAX8+/tubulin+). Although the OSE with tubal phenotype were found in only 4% of the cases, it did show that benign tubal epithelia can possibly implant on the ovarian surface and architecturally simulate 'OSE' microscopically. Meanwhile, there were also two types of OEIs: most (78%) of the OEIs displayed a tubal phenotype (vs. mesothelial phenotype) and had a significantly higher proliferative index than OSE's, suggesting that OEIs and OSE are mostly of different cellular lineages. The fact that significantly more tubal-like epithelia were found in OEIs than in OSE argues that most OEIs are not derived from the OSE, rather, bear a tubal origin. One straightforward explanation is that the fallopian-derived OEIs represent intraovarian endosalpingiosis, which is well in line with the ideas expressed by Dubeau and Crum [25, 26]. Regarding the possibility that tubal-phenotype OEIs (78%) origi-

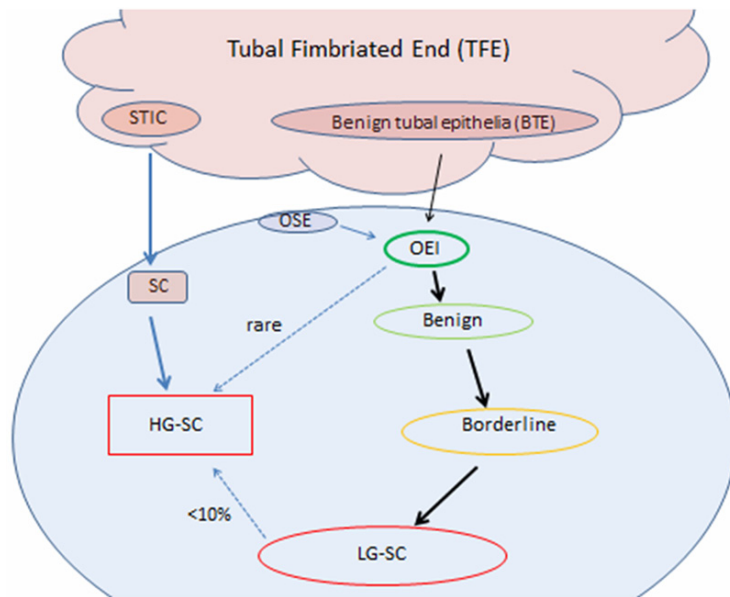
nate from mesothelium-derived OEIs through a müllerian metaplasia, if it were true, the metaplastic process must result in a hybrid type of OEIs in the ovary. The fact that the hybrid or intermediate type of OEIs with both mesothelial and tubal phenotypes were rarely found makes the müllerian metaplasia hypothesis unlikely. Furthermore, mesothelium-derived OEIs may not be able to grow into a tumor mass due to their extremely low cellular proliferative index (similar to OSE's), while fallopian-derived OEIs showed proliferative activities and immunophenotypes similar to ovarian serous tumors. The above findings suggest that OEIs with tubal phenotype and increased proliferative index [11] are likely originated from tubal epithelia, and are likely the precursors of LG-SCs.

### Development model from tubal epithelia to OEIs

Based on the connection between the tubal epithelium and LG-SCs, Li et al. proposed a two-step model of LG-SC development as following [11]. First, fallopian tubal epithelia, mostly from fimbriated end, may detach and implant on the ovarian surface. This step could occur via two possibilities: 1) the close spatial relationship between the tubal fimbriated end and the ovarian surface may allow detached tubal epithelium to implant in the ovarian stroma, especially when ovulation or non-ovulation induced disruption of the ovarian surface occurs [27]; and 2) adhesion of tubal epithelium on the ovarian surface (due to inflammation or other factors) and dynamic stromal growth around it may result in tubal derived OEIs formation. During the second step, the acquisition of mutations such as *KRAS* or *BRAF* in tubal derived OEIs results in their transformation to cystadenomas, borderline tumors and ultimately to LG-SCs [28-32]. Notably, the further acquisition of additional mutations such as *TP53* in LG-SCs may contribute to the development of a small proportion of HG-SCs [27].

There are other recent studies linking LG-SC origin to the fallopian tube. Kurman et al identified a fallopian tube lesion, designated as papillary tubal hyperplasia (PTH) whose cytological appearance is essentially identical to that of atypical proliferating serous tumor (APST), non-invasive implants, and endosalpingiosis [13]. The authors hypothesized both a PTH-pathway and a non-PTH pathway model [9] for the origin

## Tubal origin of ovarian low-grade serous carcinoma



**Figure 1.** LG-SC development with a tubal origin. Serous cancers, including HG-SCs and LG-SCs, originate mostly from the tubal fimbriated end (TFE). For LG-SCs, benign tubal epithelia (BTE) are able to form OEIs through an unclear pathway, then evolve into benign cystadenomas, borderline tumors and eventually LG-SCs. Some OEIs may derive from OSE. However, those OSE-derived OEIs are thought to have limited proliferative index and rarely develop into LG-SCs. Less than 10% of LG-SCs might develop into HG-SCs upon the acquisition of p53 mutation. HG-SCs also mainly originate from the TFE, starting from serous tubal intraepithelial carcinoma (STIC). This figure is adapted from REF [48].

and development of the pelvic low-grade serous proliferations. The PTH process begins with chronic inflammation, leading to tubal hyperplasia, which, if progresses to PTH, can shed and implant tubal epithelium on ovarian and peritoneal surfaces, resulting in a variety of low-grade serous proliferations including serous borderline tumors, noninvasive epithelial implants, and endosalpingiosis. In the non-PTH pathway, which is similar to the aforementioned model by Li et al., APST evolves from OEIs and normal tubal epithelium may form endosalpingiosis directly. APST and endosalpingiosis then can both form non-invasive implants. Another study by Laury et al showed that PAX2-null secretory cell outgrowths (SCOUTs) were more frequently found in the fallopian tubes of women with serous borderline tumors correlating with the loss of PAX2 expression found in most serous borderline tumors [12]. In particular, they identified two cases with discrete multifocal papillary SCOUTs that resemble PTH in the fallopian tubes, which were thought to associate with serous borderline tumors. These observations

provided additional support for a tubal origin of LG-SCs.

### Cell origin of LG-SCs

There are two types of epithelial cells within the fallopian tubal mucosa: ciliated and non-ciliated, the latter are also called secretory cells. Both types of the cells are also present in fallopian tube-derived OSE, fallopian tube-derived OEI, serous cystadenomas, and borderline tumors, with a significant increase in secretory-to-ciliated cell ratio (S/C ratio) observed during the apparent transition from the normal fallopian tube to fallopian tube-derived OEIs ( $P < 0.001$ ) [11]. Fallopian tube-derived OEIs and cystadenomas displayed very similar S/C ratios (consistent with their arbitrary pathologic difference, size threshold of 1 cm), while the S/C ratio of serous borderline tumors was slightly higher. In contrast, LG-SCs contained almost entirely secretory cells in their epithelial

components and displayed a strikingly high S/C ratio [11]. These results suggested that LG-SCs are likely derived from the expansion [33] or outgrowth of tubal secretory cells, similar to HG-SCs [34, 35]. The significant increase of the S/C ratio between normal tubal epithelium to fallopian tube-derived OEIs suggests that during this transition step some molecular event(s) occurred, either facilitating secretory cell expansion or ciliated cell suppression. The reduction in cilia with advancing tumor development could indicate an impaired maturation program. Overall, the progressive increase of S/C ratio from fallopian tube-derived OEIs all the way to LG-SCs is consistent with the concept of a stepwise progression, and the secretory cells in fallopian tube appear to be the cell of origin of LG-SCs.

### Emerging concept of mesothelial-müllerian junction as a potential source of LG-SC origination

Another model for the origination of ovarian serous carcinomas has been gradually emerg-

ing [36-39] in light of the recent discovery of a cancer-prone stem cell niche at the junction area of OSE, mesothelium and tubal epithelium [40], as well as the knowledge advancement in cervical cancer origin [41-44], which suggests that Krt7+ embryonic progenitors give rise to immuno-phenotypically distinct progeny under stromal influences via a 'top-down' differentiation. The ovarian surface and müllerian cortical inclusion cysts have been implicated to give rise to borderline tumors, LG- and HG-SCs [27]. Since the residual multipotential embryonic epithelial cells in cervix squamo-columnar junction can be transformed and differentiate into either squamous or columnar neoplasms, the same scenario might happen as well in the remainder of the female genital tract (Krt7+ cells extends from the fallopian tube to the extra tubal mesothelium and ovarian surface epithelium/mesothelium), thus potentially allowing LG-SC to arise from the OSE, in particular within the potentially vulnerable mesothelial-müllerian junction under neoplastic stimuli.

### Conclusion

Our understanding of the origin of LG-SCs has important clinical significance. A clear role of the fallopian tube in ovarian cancer origin has been suggested by a rapidly increasing body of studies, as summarized here in this review for LG-SCs and in several recent reviews for HG-SCs [45-47] (**Figure 1**). This paradigm shift in the understanding of ovarian cancer origin provides exciting opportunities for identifying precursor lesions and early-stage malignancies, as well as for developing screening methods and early-detection biomarkers. Fallopian tube and tubal epithelia cells are becoming the direction for future ovarian cancer early detection and prevention.

### Disclosure of conflict of interest

None.

**Address correspondence to:** Guang Yao, Department of Molecular and Cellular Biology, University of Arizona, Tucson, AZ, USA. E-mail: guangyao@arizona.edu

### References

- [1] Siegel R, Naishadham D and Jemal A. Cancer statistics, 2013. *CA Cancer J Clin* 2013; 63: 11-30.
- [2] McCluggage WG. Morphological subtypes of ovarian carcinoma: a review with emphasis on

- new developments and pathogenesis. *Pathology* 2011; 43: 420-432.
- [3] Kurman RJ and Shih leM. Molecular pathogenesis and extraovarian origin of epithelial ovarian cancer—shifting the paradigm. *Hum Pathol* 2011; 42: 918-931.
- [4] Medeiros F, Muto MG, Lee Y, Elvin JA, Callahan MJ, Feltmate C, Garber JE, Cramer DW and Crum CP. The tubal fimbria is a preferred site for early adenocarcinoma in women with familial ovarian cancer syndrome. *Am J Surg Pathol* 2006; 30: 230-236.
- [5] Crum CP, Drapkin R, Kindelberger D, Medeiros F, Miron A and Lee Y. Lessons from BRCA: the tubal fimbria emerges as an origin for pelvic serous cancer. *Clin Med Res* 2007; 5: 35-44.
- [6] Levanon K, Crum C and Drapkin R. New insights into the pathogenesis of serous ovarian cancer and its clinical impact. *J Clin Oncol* 2008; 26: 5284-5293.
- [7] Kindelberger DW, Lee Y, Miron A, Hirsch MS, Feltmate C, Medeiros F, Callahan MJ, Garner EO, Gordon RW, Birch C, Berkowitz RS, Muto MG and Crum CP. Intraepithelial carcinoma of the fimbria and pelvic serous carcinoma: Evidence for a causal relationship. *Am J Surg Pathol* 2007; 31: 161-169.
- [8] Carlson JW, Miron A, Jarboe EA, Parast MM, Hirsch MS, Lee Y, Muto MG, Kindelberger D and Crum CP. Serous tubal intraepithelial carcinoma: its potential role in primary peritoneal serous carcinoma and serous cancer prevention. *J Clin Oncol* 2008; 26: 4160-4165.
- [9] Vang R, Shih leM and Kurman RJ. Fallopian tube precursors of ovarian low- and high-grade serous neoplasms. *Histopathology* 2013; 62: 44-58.
- [10] Shih leM and Kurman RJ. Ovarian tumorigenesis: a proposed model based on morphological and molecular genetic analysis. *Am J Pathol* 2004; 164: 1511-1518.
- [11] Li J, Abushahin N, Pang S, Xiang L, Chambers SK, Fadare O, Kong B and Zheng W. Tubal origin of 'ovarian' low-grade serous carcinoma. *Mod Pathol* 2011; 24: 1488-1499.
- [12] Laury AR, Ning G, Quick CM, Bijron J, Parast MM, Betensky RA, Vargas SO, McKeon FD, Xian W, Nucci MR and Crum CP. Fallopian tube correlates of ovarian serous borderline tumors. *Am J Surg Pathol* 2011; 35: 1759-1765.
- [13] Kurman RJ, Vang R, Junge J, Hannibal CG, Kjaer SK and Shih leM. Papillary tubal hyperplasia: the putative precursor of ovarian atypical proliferative (borderline) serous tumors, noninvasive implants, and endosalpingiosis. *Am J Surg Pathol* 2011; 35: 1605-1614.
- [14] Scully RE. Pathology of ovarian cancer precursors. *J Cell Biochem Suppl* 1995; 23: 208-218.
- [15] Smith Sehdev AE, Sehdev PS and Kurman RJ. Noninvasive and invasive micropapillary (low-

## Tubal origin of ovarian low-grade serous carcinoma

- grade) serous carcinoma of the ovary: a clinicopathologic analysis of 135 cases. *Am J Surg Pathol* 2003; 27: 725-736.
- [16] Malpica A, Deavers MT, Lu K, Bodurka DC, Atkinson EN, Gershenson DM and Silva EG. Grading ovarian serous carcinoma using a two-tier system. *Am J Surg Pathol* 2004; 28: 496-504.
- [17] McKenney JK, Balzer BL and Longacre TA. Patterns of stromal invasion in ovarian serous tumors of low malignant potential (borderline tumors): a reevaluation of the concept of stromal microinvasion. *Am J Surg Pathol* 2006; 30: 1209-1221.
- [18] Seidman JD, Soslow RA, Vang R, Berman JJ, Stoler MH, Sherman ME, Oliva E, Kajdacsy-Balla A, Berman DM and Copeland LJ. Borderline ovarian tumors: diverse contemporary viewpoints on terminology and diagnostic criteria with illustrative images. *Hum Pathol* 2004; 35: 918-933.
- [19] Burks RT, Sherman ME and Kurman RJ. Micropapillary serous carcinoma of the ovary. A distinctive low-grade carcinoma related to serous borderline tumors. *Am J Surg Pathol* 1996; 20: 1319-1330.
- [20] Seidman JD and Kurman RJ. Subclassification of serous borderline tumors of the ovary into benign and malignant types. A clinicopathologic study of 65 advanced stage cases. *Am J Surg Pathol* 1996; 20: 1331-1345.
- [21] May T, Virtanen C, Sharma M, Milea A, Begley H, Rosen B, Murphy KJ, Brown TJ and Shaw PA. Low malignant potential tumors with micropapillary features are molecularly similar to low-grade serous carcinoma of the ovary. *Gynecol Oncol* 2010; 117: 9-17.
- [22] Curry EW, Stronach EA, Rama NR, Wang YY, Gabra H and El-Bahrawy MA. Molecular subtypes of serous borderline ovarian tumor show distinct expression patterns of benign tumor and malignant tumor-associated signatures. *Mod Pathol* 2013; doi: 10.1038/modpathol.2013.130. [Epub ahead of print].
- [23] Longacre TA, McKenney JK, Tazelaar HD, Kempson RL and Hendrickson MR. Ovarian serous tumors of low malignant potential (borderline tumors): outcome-based study of 276 patients with long-term (> or =5-year) follow-up. *Am J Surg Pathol* 2005; 29: 707-723.
- [24] Bell DA, Longacre TA, Prat J, Kohn EC, Soslow RA, Ellenson LH, Malpica A, Stoler MH and Kurman RJ. Serous borderline (low malignant potential, atypical proliferative) ovarian tumors: workshop perspectives. *Hum Pathol* 2004; 35: 934-948.
- [25] Crum CP. Intercepting pelvic cancer in the distal fallopian tube: theories and realities. *Mol Oncol* 2009; 3: 165-170.
- [26] Dubeau L. The cell of origin of ovarian epithelial tumours. *Lancet Oncol* 2008; 9: 1191-1197.
- [27] Kurman RJ and Shih IeM. The origin and pathogenesis of epithelial ovarian cancer: a proposed unifying theory. *Am J Surg Pathol* 2010; 34: 433-443.
- [28] Singer G, Oldt R 3rd, Cohen Y, Wang BG, Sidransky D, Kurman RJ and Shih IeM. Mutations in BRAF and KRAS characterize the development of low-grade ovarian serous carcinoma. *J Natl Cancer Inst* 2003; 95: 484-486.
- [29] Alvarez AA, Moore WF, Robboy SJ, Bentley RC, Gumbs C, Futreal PA and Berchuck A. K-ras mutations in Mullerian inclusion cysts associated with serous borderline tumors of the ovary. *Gynecol Oncol* 2001; 80: 201-206.
- [30] Haas CJ, Diebold J, Hirschmann A, Rohrbach H and Lohrs U. In serous ovarian neoplasms the frequency of Ki-ras mutations correlates with their malignant potential. *Virchows Arch* 1999; 434: 117-120.
- [31] Mayr D, Hirschmann A, Lohrs U and Diebold J. KRAS and BRAF mutations in ovarian tumors: a comprehensive study of invasive carcinomas, borderline tumors and extraovarian implants. *Gynecol Oncol* 2006; 103: 883-887.
- [32] Sieben NL, Macropoulos P, Roemen GM, Kolkman-Uljee SM, Jan Fleuren G, Houmadi R, Diss T, Warren B, Al Adnani M, De Goeij AP, Krausz T and Flanagan AM. In ovarian neoplasms, BRAF, but not KRAS, mutations are restricted to low-grade serous tumours. *J Pathol* 2004; 202: 336-340.
- [33] Li J, Ning Y, Abushahin N, Yuan Z, Wang Y, Yuan B, Cragun JM, Chambers SK, Hatch K, Kong B and Zheng W. Secretory cell expansion with aging: Risk for pelvic serous carcinogenesis. *Gynecol Oncol* 2013 Dec; 131: 555-60.
- [34] Chen EY, Mehra K, Mehrad M, Ning G, Miron A, Mutter GL, Monte N, Quade BJ, McKeon FD, Yassin Y, Xian W and Crum CP. Secretory cell outgrowth, PAX2 and serous carcinogenesis in the Fallopian tube. *J Pathol* 2010; 222: 110-116.
- [35] Jarboe E, Folkins A, Nucci MR, Kindelberger D, Drapkin R, Miron A, Lee Y and Crum CP. Serous carcinogenesis in the fallopian tube: a descriptive classification. *Int J Gynecol Pathol* 2008; 27: 1-9.
- [36] Crum CP, Herfs M, Ning G, Bijron JG, Howitt BE, Jimenez CA, Hanamornroongruang S, McKeon FD and Xian W. Through the glass darkly: intraepithelial neoplasia, top-down differentiation and the road to ovarian cancer. *J Pathol* 2013; doi: 10.1002/path.4263. [Epub ahead of print].
- [37] Auersperg N. The origin of ovarian carcinomas: a unifying hypothesis. *Int J Gynecol Pathol* 2011; 30: 12-21.

## Tubal origin of ovarian low-grade serous carcinoma

- [38] Auersperg N, Woo MM and Gilks CB. The origin of ovarian carcinomas: a developmental view. *Gynecol Oncol* 2008; 110: 452-454.
- [39] Seidman JD, Yemelyanova A, Zaino RJ and Kurman RJ. The fallopian tube-peritoneal junction: a potential site of carcinogenesis. *Int J Gynecol Pathol* 2011; 30: 4-11.
- [40] Flesken-Nikitin A, Hwang CI, Cheng CY, Michurina TV, Enikolopov G and Nikitin AY. Ovarian surface epithelium at the junction area contains a cancer-prone stem cell niche. *Nature* 2013; 495: 241-245.
- [41] Wang X, Ouyang H, Yamamoto Y, Kumar PA, Wei TS, Dagher R, Vincent M, Lu X, Bellizzi AM, Ho KY, Crum CP, Xian W and McKeon F. Residual embryonic cells as precursors of a Barrett's-like metaplasia. *Cell* 2011; 145: 1023-1035.
- [42] Xian W, Ho KY, Crum CP and McKeon F. Cellular origin of Barrett's esophagus: controversy and therapeutic implications. *Gastroenterology* 2012; 142: 1424-1430.
- [43] Herfs M, Yamamoto Y, Laury A, Wang X, Nucci MR, McLaughlin-Drubin ME, Munger K, Feldman S, McKeon FD, Xian W and Crum CP. A discrete population of squamocolumnar junction cells implicated in the pathogenesis of cervical cancer. *Proc Natl Acad Sci U S A* 2012; 109: 10516-10521.
- [44] Herfs M, Vargas SO, Yamamoto Y, Howitt BE, Nucci MR, Hornick JL, McKeon FD, Xian W and Crum CP. A novel blueprint for 'top down' differentiation defines the cervical squamocolumnar junction during development, reproductive life, and neoplasia. *J Pathol* 2013; 229: 460-468.
- [45] Nik NN, Vang R, Shih IM and Kurman RJ. Origin and Pathogenesis of Pelvic (Ovarian, Tubal, and Primary Peritoneal) Serous Carcinoma. *Annu Rev Pathol* 2013; [Epub ahead of print].
- [46] Erickson BK, Conner MG and Landen CN Jr. The role of the fallopian tube in the origin of ovarian cancer. *Am J Obstet Gynecol* 2013 Nov; 209: 409-14.
- [47] Mehra K, Mehrad M, Ning G, Drapkin R, McKeon FD, Xian W and Crum CP. STICS, SCOUTs and p53 signatures; a new language for pelvic serous carcinogenesis. *Front Biosci (Elite Ed)* 2011; 3: 625-634.
- [48] Li J, Fadare O, Xiang L, Kong B and Zheng W. Ovarian serous carcinoma: recent concepts on its origin and carcinogenesis. *J Hematol Oncol* 2012; 5: 8.