

Original Article

No reactivation of JCV and CMV infections in the temporal cortex and cerebellum of sporadic Creutzfeldt-Jakob disease patients

Judith Löffler¹, Susanne Krasemann¹, Inga Zerr², Jakob Matschke¹, Markus Glatzel¹

¹Institute of Neuropathology, University Medical Center Hamburg-Eppendorf, Hamburg, Germany; ²National Reference Center for TSE, Medical Center Georg-August University, Goettingen, Germany

Received October 28, 2014; Accepted November 12, 2014; Epub December 5, 2014; Published December 15, 2014

Abstract: Sporadic Creutzfeldt-Jakob disease (sCJD) is characterized by great phenotypic variability regarding clinical course and neuropathology. The most prominent disease modifiers are a polymorphism in Codon 129 of the prion protein gene and conformational variations of the misfolded prion protein. The cellular form of the prion protein restricts replication of viruses and may be involved in viral host defense, and viral infections influence the presentation and neuropathology in prion diseased mice. We investigated the occurrence of reactivated persistent viral infections of the brain in brain tissue samples of 25 sCJD patients. No evidence of reactivated JCV and CMV infections could be detected. This suggests that JCV and CMV infections are not reactivated as consequence of prion disease and do not act as disease modifiers in sCJD.

Keywords: Prion, Creutzfeldt-Jakob disease, persistent viral infection, JCV, CMV, disease modifier

Introduction

Transmissible spongiform encephalopathies (TSE) are fatal neurodegenerative diseases occurring as inherited, acquired and sporadic traits [1]. The deposition of PrP^{Sc}, a misfolded form of the cellular prion protein (PrP^C), spongiosis as well as astrocytosis and microgliosis are important neuropathological characteristics [2]. With an incidence of 1 to 2 cases per million per year, sporadic Creutzfeldt-Jakob disease (sCJD) is the most common TSE in humans [3, 4]. Comprising symptoms such as rapidly progressive dementia, cerebellar ataxia, myoclonic seizures, visual disorders and akinetic mutism, the clinical picture of sCJD is inconsistent [1]. A polymorphism of Codon 129 of the prion protein gene (PRNP) and the predominant molecular subtype of PrP^{Sc} are important disease modifiers [5, 6]. The molecular subtypes vary considerably regarding their median age of onset (47.2 to 67.8 years) and the median duration of disease (4 to 13 months) [7].

PrP^C holds neuroprotective functions, additionally it restricts replication of viruses and may be

involved in viral host defense pathways [8, 9]. The conversion of PrP^C to PrP^{Sc} may lead to loss of protective functions [10, 11]. In prion diseased mice, persistent retroviral infection influences the symptomatology as well as the neuropathological signature [8, 9, 12]. Thus it is conceivable that prion disease may lead to reactivation of persistent viral infections of the brain and these may influence neuropathology and thus clinical presentation of the disease. On the other hand, a role of viral elements in the development of sCJD has been suggested [13].

In humans, common persistent viruses of the brain include JC virus (JCV) and Cytomegalovirus (CMV) [14, 15]. Both are double stranded DNA-viruses with lifelong latency; seroprevalence rates range from 66-92% for JCV and 40-100% for CMV [16, 17]. In both instances immunodeficiency or immunomodulatory treatment may lead to reactivation [14, 15, 18]. In the case of JCV, reactivation leads to progressive multifocal leukoencephalopathy (PML) affecting mainly the white matter but also neurons, whereas for CMV, reactivation leads to encephalopathy [14,

JCV, CMV infections and CJD

Table 1. Demographic and neuropathological data on studied sCJD patients

Age	Sex	Dis. Dur.	PRNP	Gliosis				Spongiosis		Predominant PrP ^{Sc} type		sCJD Histo Type
				Astrocytosis		Microgliosis		Temp.	Cerb.	Temp.	Cerb.	
				Temp.	Cerb.	Temp.	Cerb.					
70	m	2.0	n.a.	++	+++	++	+++	+	++	-	Syn.	n.a.
42	f	4.0	n.a.	+	++	++	+	-	++	Intran.	Syn.	n.a.
58	f	25.2	MV	++	++	+	++	+++	-	Perin.	Syn.	MV2C
48	m	25.0	n.a.	++	++	++	++	-	-	Syn.	Syn.	n.a.
68	f	6.7	MM	+++	++	+++	+++	++	+	Syn.	Syn.	MM1
87	f	4.4	MM	+++	++	+++	+++	+++	++	Perivac	Syn.	MM1
66	f	10.0	n.a.	++	++	+++	+++	+++	+	Perivac	Syn.	n.a.
66	f	2.9	MM	++	++	+++	+++	+	+	Punct.	Syn.	MM1
55	f	19.9	MV	+++	+++	++	+++	+++	+++	Syn.	Plaque	MV2K
62	m	5.0	n.a.	+++	+++	+++	+++	+	++	Intran.	Syn.	n.a.
71	f	2.6	MM	++	++	++	+++	+	+	Intran.	-	MM1
58	f	4.9	MM	+++	+++	+	+++	++	+	Syn.	Syn.	MM1
77	f	6.9	VV	+++	++	++	++	++	-	Syn.	-	VV1
68	m	2.6	MV	+++	++	++	++	+++	+	Perivac	Syn.	MV1
71	m	2.6	MV	+	++	++	++	+	++	Intran.	Syn.	MV1
53	f	5.3	MM	+++	+++	+	++	++	++	Syn.	Syn.	MM1
65	m	6.0	n.a.	+++	++	+++	+++	++	+	-	Punct.	n.a.
61	f	6.8	MM	++	+++	+++	++	+	++	Intran.	Syn.	MM1
78	f	4.0	n.a.	++	++	++	++	+	+	-	Syn.	n.a.
74	m	9.6	MV	+++	++	++	+++	+++	+	Perivac	Plaque	MV2K
80	m	1.4	MM	++	++	++	++	+	++	Intran.	Syn.	MM1
62	m	4.4	n.a.	+++	+++	+++	+++	++	+	-	Plaque	n.a.
74	f	11.7	MM	+++	+++	+	+	++	++	Syn.	-	MM1
84	m	5.8	n.a.	+++	+++	+++	+++	++	++	-	Syn.	n.a.
61	f	8.0	n.a.	++	+++	++	+	+	++	Syn.	Syn.	n.a.

Age of death: 66.36 ± 10.85; f = 60%, m = 40%; MM = 60%, MV = 33.3%, VV = 6.6%; Disease duration: 7.508 ± 6.55. f = female, m = male, M = methionine, V = valine, n.a. = not available. Dis = disease duration (months). Deposition pattern: Syn. = synaptic, perivac. = perivacuolar, intran. = intraneuronal, perin. = perineuronal, punct. = punctuate.

15, 18, 19]. Detection of JCV and CMV capsid proteins using immunohistochemistry are sensitive and specific markers for viral reactivation [20, 21].

In this paper, we investigated if reactivated persistent viral infections of the brain occur in sCJD and if this influences the neuropathologic signature of sCJD. For that purpose, we characterized a cohort of 25 sCJD patients with respect to neuropathological presentation and presence of JCV and CMV capsid proteins using histochemical techniques and immunohistochemistry.

Materials and methods

Material

Brain tissue samples used in this project were obtained from 25 patients who died from spo-

radic Creutzfeldt-Jakob-disease between 1994 and 2013. The use of specimens is in agreement with the regulations and ethical standards at the contributing hospitals and written consent by patients or relatives was obtained where necessary. Samples of temporal cortex and cerebellum were taken during postmortem examinations. After formalin fixation and pretreatment with 100% formic acid for 60 minutes, samples were post-fixed in formalin and paraffin-embedded. Two micrometer sections were used for histological and immunohistochemical staining.

Genotyping

The identification of PRNP Codon-129-polymorphism was performed as published by PRNP amplification via polymerase chain reaction and DNA sequencing [22].

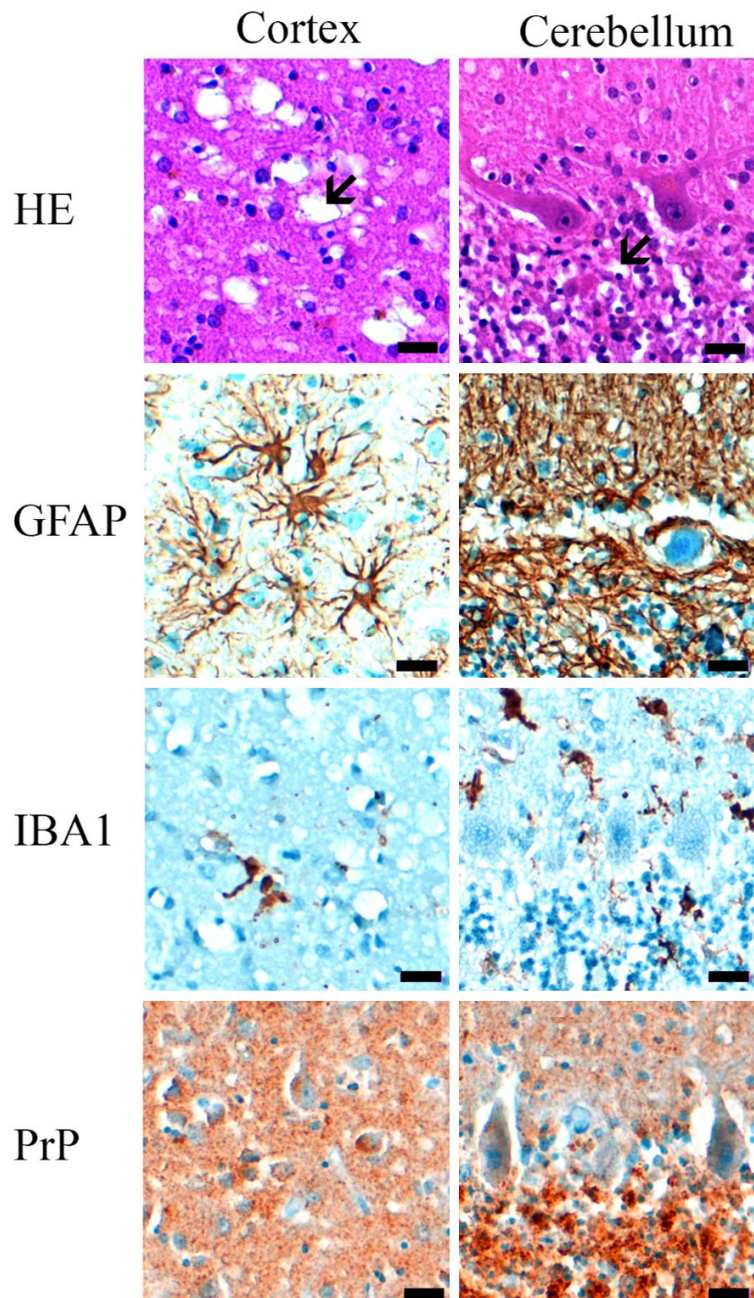


Figure 1. Example of neuropathological findings of a sCJD patient (58y, f, MM1) included in the studied cohort. Temporal cortex and cerebellum show confluent vacuoles mainly in the cortex (HE) in addition to prominent astrocytosis (GFAP) and focal microglial activation (IBA1). PrP deposits are pronounced and mainly synaptic (PrP). Scale bar is 20 μ m.

Histological staining and immunohistochemistry

Specimen were stained with hematoxylin and eosin (H&E) using routine protocols. Two micrometer sections were submitted to immunohistochemical staining on an automated Ventana HX system (Ventana-Roche Medical systems, Tucson, AZ, USA) following the manu-

facturer's instructions. For PrP^{sc} staining, pre-treatment was 5 minutes 99% formic acid and 100°C for 20 minutes in an autoclave (Fedegari Autoclavi, Albuzzano, Italy). The secondary antibodies linked to peroxidase were detected by diaminobenzidine as chromogen (Ultraview Universal DAB Detection Kit, Ventana Roche). The primary antibodies used were anti-GFAP (DAKO, Glostrup, Denmark, M-761, 1:200), anti-IBA1 (Wako, Neuss, Germany, 019-19741, 1:2000), anti-PrP (DAKO, M-7216, 1:50), anti-SV40 (used for detecting JCV, Ventana, 760-4449, ready to use) and anti-CMV (DAKO, M0757, 1:100). Brain tissue samples of patients with PML or CMV-encephalitis served as positive controls for the latter two antibodies.

Evaluation

The degree of spongiosis, astrocytosis and microglial activation were evaluated semi-quantitatively in at least 2 cm² of cortex (temporal) or foliae (cerebellum) using a four-tiered scale (0 = absent, 1 = slight, 2 = moderate, 3 = extensive) as published [23]. The predominant PrP^{sc} deposition patterns were determined as suggested [24]. Positively stained nuclei (SV40, CMV) were assessed in a representative area of at least 2 cm² using a 40x objective as published [23].

Results

Demographical and neuropathological profile of sCJD patients

With 60% of female patients, an average age of death of 66.4 years, an average disease duration of 7.51 months and the observed frequency of PRNP genotypes (60% MM 33.3% MV,

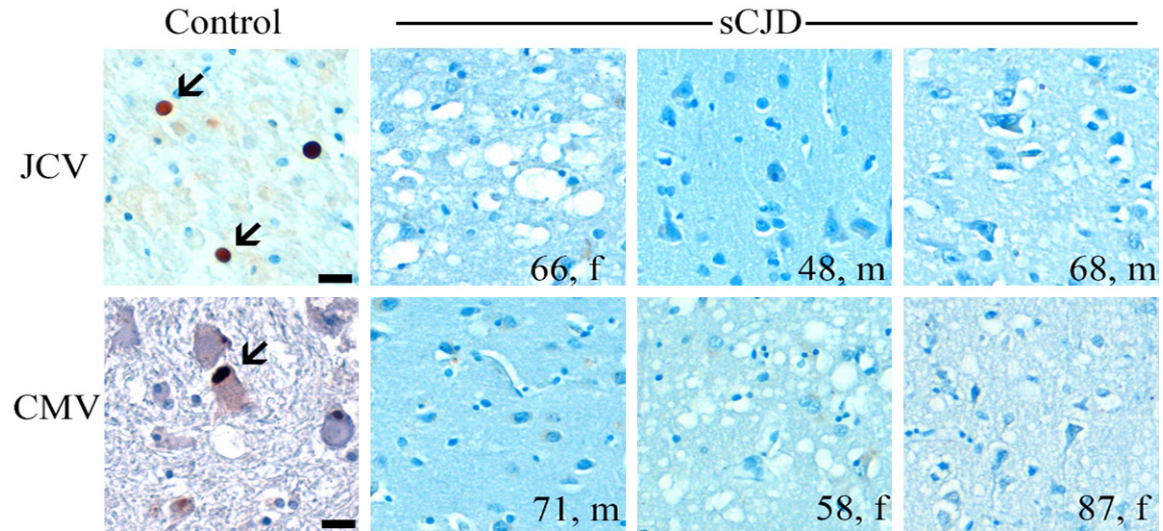


Figure 2. Examples of immunohistochemical assays detecting JCV and CMV capsid proteins. Shown is temporal cortex of sCJD patients, indicated is age and gender. No positively stained nuclei could be detected in brains of sCJD patients (cerebellum is not shown) whereas in brain tissue of control patients (PML or CMV-encephalitis) positively stained nuclei can be detected (arrows). Scale bar is 20 μ m.

6.6% VV; M = methionine, V = valine), this collective can be considered as representative for sCJD patients (**Table 1**) [25]. Although we did not have cryomaterial available for biochemical analyses we followed newly defined algorithms to determine the six major phenotypic subtypes found in sCJD by neuropathological determination of sCJD histotypes taking PRNP Codon 129 genotypes into consideration [26]. Analysis included determination of spongiosis in addition to scoring of astro- and microgliosis and the determination of the predominant type of PrP^{Sc}-deposition in cortical areas (temporal cortex) and the cerebellum (**Figure 1**). All of the common sCJD histotypes could be detected with expected frequencies and MM1 and MV1 being the most common subtypes (**Table 1**; **Figure 1**) [7, 25].

No evidence for reactivation of JCV or CMV in sCJD

In order to assess if reactivation of JCV or CMV occurs as a consequence of prion disease we assessed JCV or CMV reactivation using morphological criteria on cerebral cortex and cerebellum stained with routine histochemical staining (HE), and immunohistochemistry for the astroglial marker GFAP and the microglial marker IBA1. We did not find any demyelinating foci, enlarged nuclei of oligodendrocytes, intranuclear or intracytoplasmic inclusions indica-

tive for JCV or CMV reactivation (**Figure 2**). Furthermore, presence of JCV and CMV capsid proteins was assessed by performing immunohistochemistry on cerebral cortex and the cerebellum [20, 21]. As controls we used brain tissue samples of patients with PML or CMV-encephalitis. We could not identify any positively stained nuclei indicate of JCV or CMV reactivation (**Figure 2**).

Discussion

In this study we investigated if reactivated persistent viral infection of the brain occur in sCJD and if this influences the neuropathologic signature of sCJD. For that purpose, we characterized a cohort of 25 sCJD patients with respect to neuropathological presentation and presence of JCV and CMV capsid proteins using histochemical techniques and immunohistochemistry.

Our cohort can be considered representative for sCJD since we identified all of the common sCJD histotypes with expected frequencies [7, 25]. Since we did not have cryomaterial available for biochemical analyses, determination of sCJD subtypes was performed according to newly defined algorithms based on the assessment of key neuropathological findings in a limited amount of brain regions [26]. Parchi et al. studied cortical regions, thalamus, and cere-

bellum, whereas we studied cortical regions, and cerebellum, nevertheless we believe that our determination of sCJD histotypes was adequately sensitive and specific [26]. Thus our study further underscores the possibility to use histopathological analyses to determine sCJD subtypes in patients where molecular analyses are not feasible [5, 26, 27].

We did not detect cerebral reactivation of JCV or CMV by morphological methods including sensitive and specific immunohistochemical assays [20, 21]. Our data stand in contrast to data from murine studies indicating that PrP^C controls replication of viruses, and viral infection influences symptomatology and neuropathological signature of prion diseases [8, 9, 12]. This may be due to the limitations of our study. We only examined two brain regions and since viral reactivation can be focal it may have been missed by us. On the other hand, our results are consistent with the findings of Jeong et al. who did not find an association between the development of sCJD and infection with BK virus, polyomavirus family member [28]. Furthermore we only assessed viral reactivation for two common persistent viral infections of the human CNS using one specific antibody per virus, whereas reactivation of other persistent viral infections of the human CNS such as Epstein-Barr virus, Varicella-Zoster virus or Herpes Simplex virus 1 and 2 remained unregarded in this study [29].

In conclusion, we investigated reactivation of persistent JCV and CMV infections of the brain in brain sCJD patients. No evidence of viral reactivation could be found. Our data indicate sCJD does not lead to reactivation of JCV and CMV and neither JCV nor CMV act as disease modifiers in sCJD.

Acknowledgements

We thank Kendra Richter, Sandra Deutsch and Ann-Kathrin Lüttges for the help with histological analysis. MG received funding from the Leibniz Graduate School (Model Systems for Infectious Diseases) and the Landesexzellenzinitiative (SDI-LEXI) of the city of Hamburg. This study was funded by the Robert Koch-Institute through funds of the Federal Ministry of Health (grant no 1369-341).

Disclosure of conflict of interest

None to declare.

Address correspondence to: Markus Glatzel, Institute of Neuropathology, University Medical Center Hamburg-Eppendorf, Hamburg, Germany. Tel: +49 40 741052218; Fax: +49 40 741054929; E-mail: m.glatzel@uke.de

References

- [1] Geissen M, Krasemann S, Matschke J and Glatzel M. Understanding the natural variability of prion diseases. *Vaccine* 2007; 25: 5631-5636.
- [2] Budka H. Neuropathology of prion diseases. *Br Med Bull* 2003; 66: 121-130.
- [3] Glatzel M, Rogivue C, Ghani A, Streffer JR, Amsler L and Aguzzi A. Incidence of Creutzfeldt-Jakob disease in Switzerland. *Lancet* 2002; 360: 139-141.
- [4] Ladogana A, Puopolo M, Croes EA, Budka H, Jarius C, Collins S, Klug GM, Sutcliffe T, Giulivi A, Alperovitch A, Delasnerie-Laupretre N, Brandel JP, Poser S, Kretschmar H, Rietveld I, Mitrova E, Cuesta Jde P, Martinez-Martin P, Glatzel M, Aguzzi A, Knight R, Ward H, Pocchiari M, van Duijn CM, Will RG and Zerr I. Mortality from Creutzfeldt-Jakob disease and related disorders in Europe, Australia, and Canada. *Neurology* 2005; 64: 1586-1591.
- [5] Hill AF, Joiner S, Wadsworth JD, Sidle KC, Bell JE, Budka H, Ironside JW and Collinge J. Molecular classification of sporadic Creutzfeldt-Jakob disease. *Brain* 2003; 126: 1333-1346.
- [6] Schoch G, Seeger H, Bogousslavsky J, Tolnay M, Janzer RC, Aguzzi A and Glatzel M. Analysis of prion strains by PrPSc profiling in sporadic Creutzfeldt-Jakob disease. *PLoS Med* 2006; 3: e14.
- [7] Collins SJ, Sanchez-Juan P, Masters CL, Klug GM, van Duijn C, Poleggi A, Pocchiari M, Almonti S, Cuadrado-Corrales N, de Pedro-Cuesta J, Budka H, Gelpi E, Glatzel M, Tolnay M, Hewer E, Zerr I, Heinemann U, Kretschmar HA, Jansen GH, Olsen E, Mitrova E, Alperovitch A, Brandel JP, Mackenzie J, Murray K and Will RG. Determinants of diagnostic investigation sensitivities across the clinical spectrum of sporadic Creutzfeldt-Jakob disease. *Brain* 2006; 129: 2278-87.
- [8] Alais S, Soto-Rifo R, Balter V, Gruffat H, Manet E, Schaeffer L, Darlix JL, Cimarelli A, Raposo G, Ohlmann T and Leblanc P. Functional mechanisms of the cellular prion protein (PrP(C)) associated anti-HIV-1 properties. *Cell Mol Life Sci* 2012; 69: 1331-1352.
- [9] Lotscher M, Recher M, Lang KS, Navarini A, Hunziker L, Santimaria R, Glatzel M, Schwarz P, Boni J and Zinkernagel RM. Induced prion protein controls immune-activated retroviruses in the mouse spleen. *PLoS One* 2007; 2: e1158.

- [10] Hetz C, Maundrell K and Soto C. Is loss of function of the prion protein the cause of prion disorders? *Trends Mol Med* 2003; 9: 237-243.
- [11] Glatzel M and Aguzzi A. The shifting biology of prions. *Brain Res Brain Res Rev* 2001; 36: 241-248.
- [12] Krasemann S, Neumann M, Luepke JP, Grashorn J, Wurr S, Stocking C and Glatzel M. Persistent retroviral infection with MoMuLV influences neuropathological signature and phenotype of prion disease. *Acta Neuropathol* 2012; 124: 111-126.
- [13] Jeong BH, Lee YJ, Carp RI and Kim YS. The prevalence of human endogenous retroviruses in cerebrospinal fluids from patients with sporadic Creutzfeldt-Jakob disease. *J Clin Virol* 2010; 47: 136-142.
- [14] White FA 3rd, Ishaq M, Stoner GL and Frisque RJ. JC virus DNA is present in many human brain samples from patients without progressive multifocal leukoencephalopathy. *J Virol* 1992; 66: 5726-5734.
- [15] Cannon MJ, Schmid DS and Hyde TB. Review of cytomegalovirus seroprevalence and demographic characteristics associated with infection. *Rev Med Virol* 2010; 20: 202-213.
- [16] Sanders VJ, Felisan S, Waddell A and Tourtelotte WW. Detection of herpesviridae in post-mortem multiple sclerosis brain tissue and controls by polymerase chain reaction. *J Neurovirol* 1996; 2: 249-258.
- [17] Padgett BL and Walker DL. Virologic and serologic studies of progressive multifocal leukoencephalopathy. *Prog Clin Biol Res* 1983; 105: 107-117.
- [18] White MK and Khalili K. Pathogenesis of progressive multifocal leukoencephalopathy—revisited. *J Infect Dis* 2011; 203: 578-586.
- [19] Gheuens S, Wuthrich C and Korolnik IJ. Progressive multifocal leukoencephalopathy: why gray and white matter. *Annu Rev Pathol* 2013; 8: 189-215.
- [20] Schmidbauer M, Budka H, Ulrich W and Ambros P. Cytomegalovirus (CMV) disease of the brain in AIDS and congenital infection: a comparative study by histology, immunocytochemistry and in situ DNA hybridization. *Acta Neuropathol* 1989; 79: 286-293.
- [21] Munoz-Marmol AM, Mola G, Fernandez-Vasalo A, Vela E, Mate JL and Ariza A. JC virus early protein detection by immunohistochemistry in progressive multifocal leukoencephalopathy: a comparative study with in situ hybridization and polymerase chain reaction. *J Neuropathol Exp Neurol* 2004; 63: 1124-1130.
- [22] Kovacs GG, Puopolo M, Ladogana A, Pocchiari M, Budka H, van Duijn C, Collins SJ, Boyd A, Giulivi A, Coulthart M, Delasnerie-Laupretre N, Brandel JP, Zerr I, Kretzschmar HA, de Pedro-Cuesta J, Calero-Lara M, Glatzel M, Aguzzi A, Bishop M, Knight R, Belay G, Will R and Mitrova E. Genetic prion disease: the EURO-CJD experience. *Hum Genet* 2005; 118: 166-174.
- [23] Hagel C, Krasemann S, Löffler J, Puschel K, Magnus T and Glatzel M. Up-regulation of Shiga toxin receptor CD77/Gb3 and interleukin-1beta expression in brain of EHEC patients with hemolytic uremic syndrome and neurologic symptoms. *Brain Pathol* 2014; [Epub ahead of print].
- [24] Kovacs GG, Voigtlander T, Hainfellner JA and Budka H. Distribution of intraneuronal immunoreactivity for the prion protein in human prion diseases. *Acta Neuropathol* 2002; 104: 320-326.
- [25] Parchi P, Strammiello R, Giese A and Kretzschmar H. Phenotypic variability of sporadic human prion disease and its molecular basis: past, present, and future. *Acta Neuropathol* 2011; 121: 91-112.
- [26] Parchi P, de Boni L, Saverioni D, Cohen ML, Ferrer I, Gambetti P, Gelpi E, Giaccone G, Hauw JJ, Hofberger R, Ironside JW, Jansen C, Kovacs GG, Rozemuller A, Seilhean D, Tagliavini F, Giese A and Kretzschmar HA. Consensus classification of human prion disease histotypes allows reliable identification of molecular subtypes: an inter-rater study among surveillance centres in Europe and USA. *Acta Neuropathol* 2012; 124: 517-529.
- [27] Cali I, Castellani R, Yuan J, Al-Shehlee A, Cohen ML, Xiao X, Moleres FJ, Parchi P, Zou WQ and Gambetti P. Classification of sporadic Creutzfeldt-Jakob disease revisited. *Brain* 2006; 129: 2266-2277.
- [28] Jeong BH, Lee JH, Cho HJ and Kim YS. Absence of association between the incidence of BK virus and sporadic Creutzfeldt-Jakob disease. *Intervirology* 2013; 56: 184-189.
- [29] Koyuncu OO, Hogue IB and Enquist LW. Virus infections in the nervous system. *Cell Host Microbe* 2013; 13: 379-393.