

Review Article

Omental transplantation for neuroendocrinological disorders

Hernando Rafael

Academia Peruana de Cirugía Lima, Peru

Received August 27, 2015; Accepted August 28, 2015; Epub September 10, 2015; Published September 15, 2015

Abstract: Neurosurgical evidences show that the aging process is initiated between 25 to 30 years of age, in the arcuate nucleus of the hypothalamus. Likewise, experimental and neurosurgical findings indicate that the progressive ischemia in the arcuate nucleus and adjacent nuclei are responsible at the onset of obesity and, type 2 diabetes mellitus in adults, and essential arterial hypertension (EAH). On the contrary, an omental transplantation on the optic chiasma, carotid bifurcation and anterior perforated space can provoke rejuvenation, gradual loss of body weight, decrease or normalization of hyperglycemia and normalization of EAH; all of them, due to revascularization of the hypothalamic nuclei. Besides, our surgical method have best advantages than the bariatric surgery, against obesity and type 2 diabetes mellitus.

Keywords: Arcuate nucleus, ghrelin, leptin, obesity, type 2 diabetes, omental transplantation

Introduction

To date, almost all researchers conclude that several challenging diseases such as aging, obesity and type 2 diabetes mellitus (DM) in adults and, essential arterial hypertension (EAH); all of them are of etiology unknown. However, based on neurosurgical experiences [1-5], my colleagues and I believe that these diseases have ischemic origin in the hypothalamus, because its revascularization by means of an omental transplantation on the optic chiasma, carotid bifurcation and anterior perforated space, it can provoke rejuvenation [1], weight loss [2], decrease of the circulating levels of blood glucose [4, 6] and normalization of EAH [7].

Thereby, in this review article I will analyze the involved hypothalamic structures in the pathogenesis of these diseases, especially anatomical and pathological findings at the circle of Willis observed during an omental transplantation at the chiasmatic región.

Hypothalamus and its normal vascularization

A diencephalic structure, the hypothalamus (constituted by about 11 major nuclei), has a

mean height of 10-mm and a mean anteroposterior diameter of 15-mm, and weight about 4-gr in the average adult human Brain [8, 9]. It is a neuroendocrine structure very vascularized by anterior perforating arteries and a fenestrated capillaries network [10-16]. On the other hand, the hypothalamus has many neural connections of afferent fibers (retino-hypothalamic, fronto-hypothalamic, spino-hypothalamic and tegment-hypothalamic) and, afferent and efferent fibers with the amygdala (through the stria terminalis and ventral amygdalofugal pathways), septal area, hippocampus (through the fornix, the hippocampal formation exerts an excitatory function, especially on the arcuate nucleus and ventromedial nuclei, VMN), mid-brain (through the dorsal longitudinal fasciculus and mammilo-tegmental tracts) and spinal cord (spino-hypothalamic tracts, through somatosensory fibers that provides input necessary for orgasm, and hypothalamic-spinal tracts, which projects to the dorsal motor nuclei of the vagus (DMNV) and finally, to preganglionic sympathetic and parasympathetic neurons in the spinal intermediolateral cell column [6, 17-23]. Besides the fornix, VMN receives numerous fibers from the amygdala through the stria terminalis.

Omentum for neuroendocrinological disorders

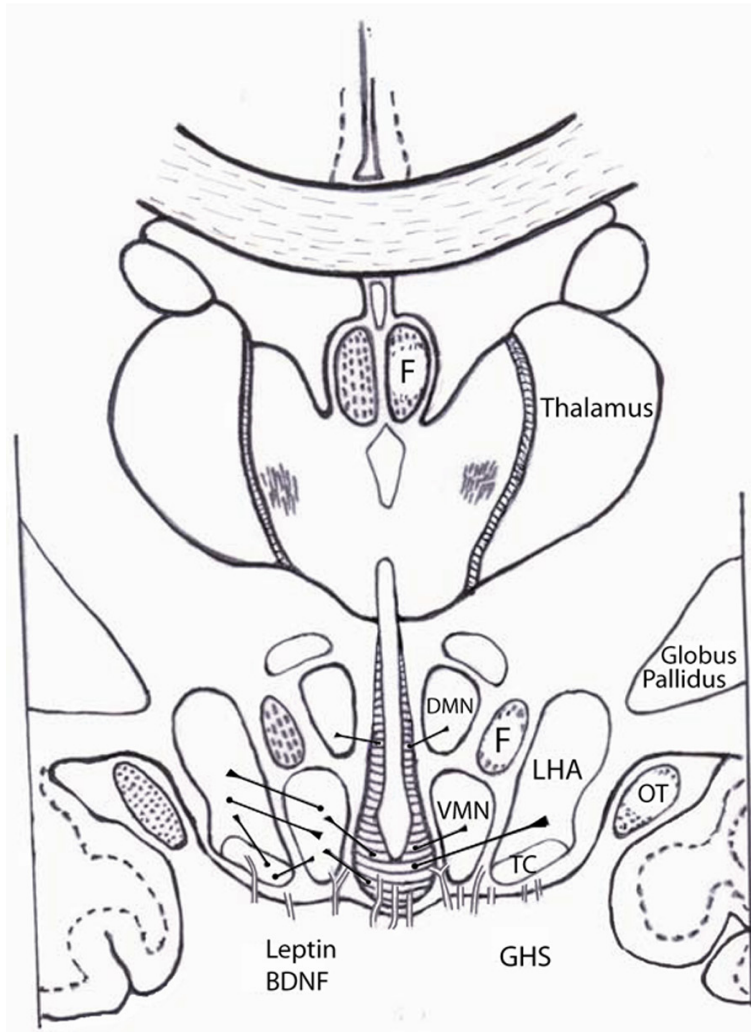


Figure 1. Mediobasal portion of the hypothalamus and its vascularization by arterioles and small arteries, showing to the arcuate nucleus. F, fornix. VMN, ventromedial nuclei. DMN, dorsomedial nuclei. LHA, lateral hypothalamic areas. TC, tuber cinereum. OT, optic tract. BDNF, brain-derived neurotrophic factor. GHS, growth hormone secretagogues. Adapted from reference [27].

Normally the mediobasal portion of the hypothalamus obtains its blood supply from three origins [10, 12, 13, 15, 16, 24, 25]. 1) Superior hypophyseal arteries (SHAs) originated from the ophthalmic segments of the supraclinoid carotids in the 95% of cases, it are a group of one to five small branches (average diameter, 0.22-mm) that terminate on the pituitary stalk and gland, optic chiasma and nerves, and in the floor of the third ventricle; 2) Infundibular or premammillary arteries are also a group of arteries arose from the proximal third of the posterior communicating arteries (PCoAs) and are distributed in the infundibulum. Some of these infundibular arteries are originated from

SHAs and by contrast, in the 5% of cases, the SHAs are arising from the PCoAs and finally, 3) Some perforating branches are originated directly from the communicating segments of the supraclinoid carotids.

The SHAs and infundibular arteries pass medially below the chiasma to reach the tuber cinereum. In most cases, this vascular standard has anatomical variants in relation to number, caliber and distribution of these perforating arteries [12, 13, 15, 16, 24]. At grade infundibular these arteries form a fine circuminfundibular plexus, which gives rise to small arteries (range 0.07 to 0.40-mm of caliber) and arterioles to the basal and medial portions of the hypothalamus to form subependymal capillaries plexus, surrounding the third ventricle, as well as in the median eminence [10-12, 14, 15, 26]. In the hypothalamic parenchyma, there are not end-arteries, but on the contrary, their terminal branches have anastomoses which branches of other origins as anterior perforating arteries, posterior perforating arteries and medial lenticulostriate arteries [9, 10, 12, 13, 24].

Thus, the vascularization in the median eminence and arcuate nucleus is by means of fenestrated capillaries [11-14].

A small part of the hypothalamus located in the mediobasal portion and on either side of the third ventricle and just above the median eminence, it correspond to the producing hypothalamic nuclei (lowermost portion of the VMN, arcuate nucleus and both tuber cinereum) of growth hormone-releasing hormone (GHRH). The arcuate nucleus (**Figure 1**) is constituted by small cells such as dopamine (A12 cell group), luteinizing hormone-releasing hormone (LHRH), GHRH, neuropeptide Y (NPY), vasoactive intestinal peptide (VIP), ghrelin neural, Agouti-related

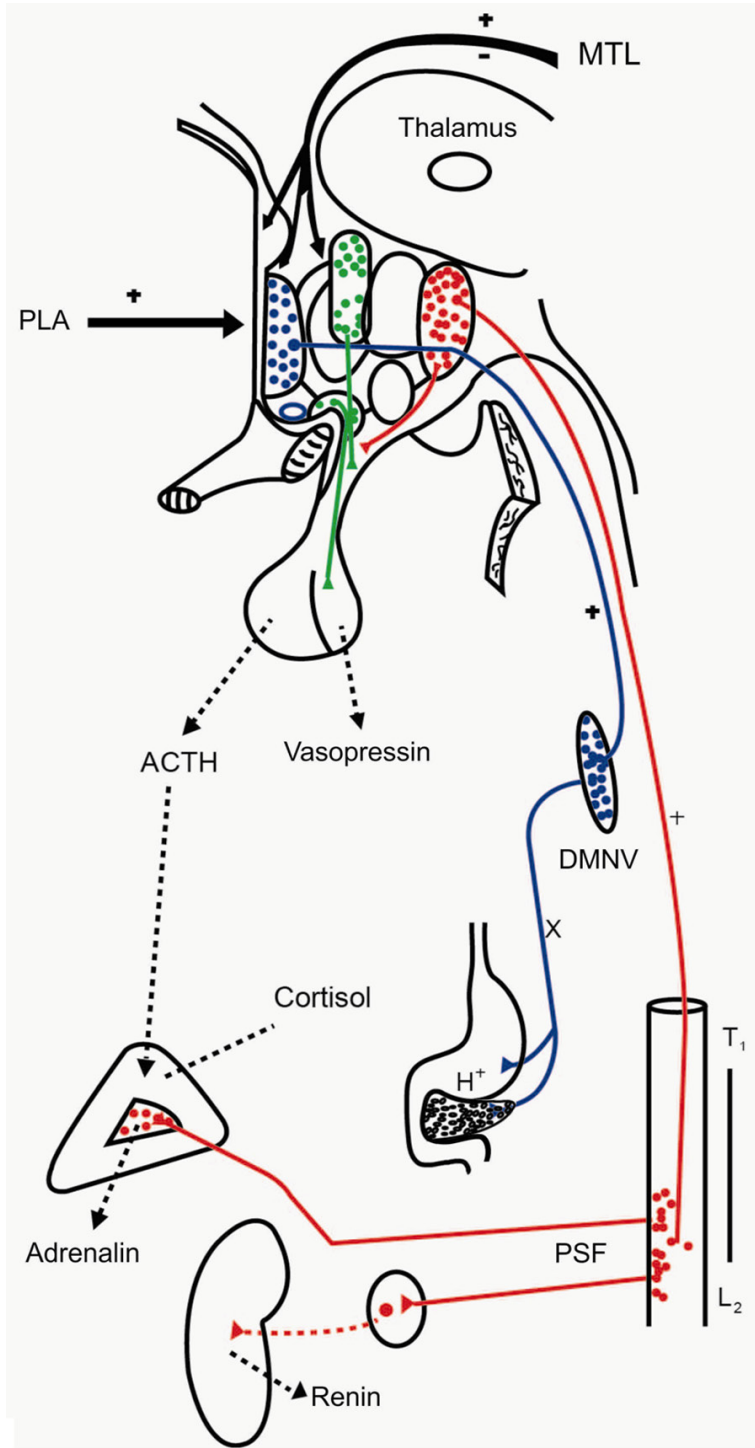


Figure 2. Afferent and efferent fibers of the hypothalamus. Schematic representation of the hypothalamic-pituitary-adrenal and hypothalamic-autonomic-renal axes. The excitation of the sympathetic pathway is related which neurogenic hypertension; whereas the two others with type 2 Diabetes. MTL, medial temporal lobes. PLA, prefrontal limbic áreas. DMNV, dorsal motor nuclei of the vagus. PSF, preganglionic sympathetic fibers. Adapted from reference [6].

protein (AgRP), Cocaine amphetamine-regulated transcript (CART) and proopiomelanocortin

(POMC) neurons, as well as ependymal cells and tanycytes [9, 25, 27-31]. Moreover, unlike the presence of adult stem cells located in the sub-ventricular zone (SVZ) of the lateral ventricles during whole the adult life [32-34], it seems that these neural stem cells in the SVZ of the third ventricle [35-37], it are scarce or do not exist after the 30 years of age [27, 33] due to a vascular deterioration and progressive decrease in the number of neurons which age [9, 27, 38, 39].

The NPY, AgRP and ghrelin neural cells are orexigenic neurons (inductor of the appetite) with excitatory function through the NPY, ghrelin and AgRP neuropeptides on the orexigenic neurons distributed in the lateral hypothalamic área (LHA), perifornical área, dorsomedial nuclei (DMN) and the caudal portion of the paraventricular nuclei (PVN) [20, 25, 26, 31, 40]. In the arcuate nucleus, the ghrelin-containing neurons send efferent fibers onto POMC neurons to suppress the release of this anorexigenic peptide [31]; whereas other axons of the ghrelin neurons acts on NPY neurons in the PVN, which in turn suppress GABA release, resulting in the stimulation of corticotropin-releasing hormone (CRH)-expressing neurons.

Some orexigenic neurons from the LHA and perifornical área send descending axons to terminate in the ventral tegmental area, rostral raphe pallidus, nucleus of the tractus solitarius and DMNV [18, 37, 39, 41-44]. Then, descending projections originated from the preoptic nuclei [19, 45, 46] and orexinergic system [21, 39, 43], they terminate in the DMNV

Omentum for neuroendocrinological disorders

and, through the parasympathetic division of the vagus nerves (**Figure 2**), the gastric, pancreatic and biliar secretion are increased. So, the digestion of proteins, lipids and carbohydrates are favored and the plasma levels of glucose amino acids and lipids are increased. Therefore, the chronic excitation of this parasympathetic pathway from the hypothalamus are related, in part, with the overweight and obesity [6, 19].

The POMC and CART neurons are anorexigenic cells (inductor of the satiety) with inhibitory function through the POMC and alpha-melanocyte stimulating hormone (alpha-MSH) neuropeptides on the anorexigenic neurons distributed in the DMN, PVN, perifornical area and the LHA [25, 31, 47, 48]. The VMN comprises mainly of glutamatergic neurons with exciting function on the orexigenic neurons [25, 41]. Lesions of these nuclei result in obesity driven by excessive food intake, indicating that, it has an important role in satiety, and by contrast, damage to the LHA can cause reduced food intake [49]. Likewise, low-frequency electrical stimulation to the LHA cause a desire to eat, while stimulating the VMN causes a desire to stop eating [41, 49, 50].

The hypothalamic-pituitary-adrenal (hpa) axis

The paraventricular nuclei (PVN) contains neuroendocrine neurons that synthesize and secrete vasopressin and corticotropin-releasing hormone (CRH). Parvocellular neurons within the PVN send short axons to terminate in the median eminence, wherein they secrete CRH. Thus, the hyperfunction of the HPA axis (also known as the limbic-hypothalamic-pituitary-adrenal (LHPA) axis) by stress can cause an increase in the serum ACTH and cortisol levels, which is implicated in the overweight, because the endogenous cortisol stimulates the secretion of gastric acid [18, 51]. Then, the chronic hyperfunction of this HPA axis may cause obesity and type 2 DM [6, 52, 53]. Therefore, the parasympathetic pathways and the HPA axis, both of them can provoke the accumulation of fat tissue in the liver, omentum and subcutaneous tissue, among other regions.

Currently the adipose tissue is considered as an endocrine organ [54-57] by producing numerous adipocytokines, which include both pro-inflammatory and anti-inflammatory mole-

cules with an ample biological activity [55, 56, 58-60]. However two adipocytokines, tumor necrosis factor alpha (TNF-alpha) and resistin, both are closely associated with the development of insulin resistance in peripheral tissues such as skeletal muscle and the liver [56, 58, 61], to interfere with the insulin at grade of its receiving located in the cellular membrane [58, 62, 63]. That is, glucose does not enter into cells after it has attacked to its insulin receptor. Both cytokines, TNF-alpha and resistin are proteins with potent inflammatory effects [62, 64]. Therefore, aspirin can improve the dysfunction of endothelial cells in arteries [65, 66] and perhaps, to prevent damage to the insulin receptor caused by the cytokines. For example, a 75-year-old woman with history of type 2 DM between 45 to 55 years of age, she received metformin, Bi-Euglucon M and glibenclamide, and then, besides this anti-diabetic therapy, she received diclofenac, ibuprofen and aspirin by osteoarthritis in fingers, wrists and knees. But about 60 years of age, she presented periods of hypoglycemia. For these reasons, she suspended willfully the anti-diabetic therapy. Since then and until her death, she received only 500 mg% of aspirin per day and glycemias of 80 to 110 mg% [65].

The macrophages and mononuclear leukocytes of the adipose tissue are the primary source of TNF-alpha and resistin and, its production is increased in obese people [55-57, 61]. In addition to these two cytokines, the insulin receptor (a glycoprotein) can also be antagonized by the cortisol, growth hormone, glucagón and catecholamines and by contrast, is activated by insulin and insulin-like growth factor-1 (IGF-1) [60, 63]. Therefore, type 2 DM in obese children and adolescents is related, essentially, with insulin resistance [19, 54]; meanwhile in adults, with progressive ischemia in the arcuate nucleus and adjacent nuclei of the hypothalamus [1, 3, 6, 65].

The hypothalamic-autonomic-renal (har) axis

Like other neurological diseases [19, 27, 67], arterial hypertension is considered a challenging disease for medical communicating in spite of neurosurgical experiences since 1973, when was performed the first vascular decompression of the lateral medulla and/or 9th-10th cranial nerves [68]. Since then and to date, several

Omentum for neuroendocrinological disorders

surgical techniques are used against arterial hypertension [5, 7, 69-71].

To date, the medical communicating continuous whereas there are two types of arterial hypertension. The first, essential arterial hypertension (EAH) whose etiology is unknown and it represent, 90 to 95% of all cases of hypertension, and the second, secondary arterial hypertension (SAH) caused by coarctation of the aorta, pheochromocytoma and renal disease, among others. At least, five áreas are related with neurogenic hypertension (main representative of EAH) [4, 18, 72-76]. 1) baroreceptors in the aortic arch and carotid sinus, 2) the cardiovascular réflex center (CRC) of the nucleus solitarius; 3) the A1/C1 cell groups, 4) the A2/C2 cell groups, and 5) lateral and posterior hypothalamus (the ergotropic triangle). Neurosurgical evidences has, however, demonstrated that of these áreas, the posterior hypothalamus is the main component responsible for neurogenic hypertension by means of two pathways of increased activity [4, 5, 7, 18, 73, 74]. A principal, constituted by 1) the posterior hypothalamic nuclei (PHN) and the A1/C1 cell groups, 2) the intermediolateral cell columns of the spinal cord (T1-L2), 3) the sympathetic nervous system, 4) the adrenal medulla, and 5) the juxtaglomerular apparatus of the kidney (origin of the renin-angiotensin system); and An accessory, integrated by 1) PVN, LHA and PHN, 2) the pituitary gland (the origin of ACTH), and 3) the adrenal cortex (origin of the cortisol), as is showed in the **Figure 2**.

Recently have reported 60 patients which EAH and cerebrovascular diseases [7]. All of them received an omental transplantation on the carotid bifurcation and anterior perforated space. In the 80% of cases, AEH was normalized during the first weeks after surgery and without anti-hypertensive treatment, and in the rest of cases, during the first 6 months. Likewise, into 36 patients the cardiac silhouette was reduce of size. Therefore, SAH constitute the immense majority of cases with arterial hypertension, because the etiology is proved (neurogenic hypertension, coarctation of the aorta, pheochromocytoma, and renal disease, among others). A conclusión opposite to the established up to now by the medical communicating [77].

The gastro-hypothalamic axis

Ghrelin is a neuropeptide produced predominantly in the stomach (gastric ghrelin), especially in the fundus than in the pylorus [48, 78] and is an endogenous ligand of the ghrelin receptor, also known as growth hormone secretagogue receptor (GHS-R) [78, 79]. Ghrelin secretion has a circadian rhythm with an increase before each meal and a reduction after food intake. This preprandial increase plays a role in prompting food intake [48, 57]. Normally this hormone is one of the most powerful orexigens acting on the ghrelin receptor of the NPY and AgRP neurons in the arcuate nucleus and VMN of the hypothalamus [26, 57, 80-82]. That is, gastric and hypothalamic ghrelin stimulates the synthesis of NPY and AgRP neuropeptides and both hormones exert an excitatory function on the orexigenic neurons. Likewise, GHRH neurons are also targets of ghrelin [83-85] and therefore, the ghrelin facilitates GHRH secretion from the arcuate nucleus. Moreover, oral administration of MK-677 (an oral ghrelin) [86], capromorelin (other orally active ghrelin agonist) [87] and other synthetic growth hormone secretagogues act on the same GHS-R in the hypothalamus.

In conclusion, normally circulating exogenous and endogenous ghrelin can freely and rapidly diffuse from the fenestrated capillaries in the median eminence and arcuate nucleus and, to exert their action on the GHS-R [26, 79]. So that, ghrelin have two essential functions. First, it stimulate the synthesis and secretion of GHRH [1, 17] and Second, ghrelin stimulates appetite by acting on NPY and AgRP neurons [31, 81, 87]. Accordingly, this gastro-hypothalamic axis is very important in the childhood and adolescence for the growth and development, and by contrast, in healthy older adults can favor the rejuvenation [9, 86].

The adipose tissue-hypothalamic axis

The adipocytokine, leptin is a peptide hormone secreted principally but not exclusively by adipocytes [54, 88]. Serum leptin levels are significantly associated with body-mass index, ie., with the amount of adipose tissue [56, 58]. Thus, the circulating leptin levels in normal adults is of 11.5 (6.35-20) ng/ml and in obese adults, 22 (13.5-44) ng/ml [54]. That is, in

Omentum for neuroendocrinological disorders

obese subjects the circulating level of the anorexigenic hormone leptin is increased; whereas surprisingly, the levels of the orexigenic hormone ghrelin is decreased [79, 89]. However, in obese subjects, generally the appetite is increased.

At the level of the arcuate nucleus of the hypothalamus, leptin exerts an inhibitory action on the leptin receptor (ob-R, also known as LEP-R) [56, 90] of the NPY and AgRP neurons and by contrast, POMC and CART neurons are activated by hormone leptin [42, 91, 92]. In other words, leptin stimulates the anorexigenic pathway and inhibits to the orexigenic pathway; both of them originate in the arcuate nucleus.

Therefore, VMN is a potential target for leptin's anti-diabetic effects because leptin-sensitive neurons in these nuclei are implicated in glucose homeostasis [93, 94]. So that, normally the leptin acts in the arcuate nucleus and adjacent nuclei to reduce body weight and fat mass [95, 96] and on the contrary, loss of the leptin receptor or a deficiency of leptin in the circulation results in hyperphagia, obesity and type 2 DM [88, 97]. In base to neurosurgical experiences [2, 7]. I believe that the obese adults are not leptin-resistant [89], but that there is not penetration of leptin inside the arcuate nucleus. Moreover, in the hypothalamus [98] and circulating brain-derived neurotrophic factor (BDNF) levels [99] can also act in the control eating, drinking and body weight. Since this protein exert as nerve growth factor and so, promotes the dendritic spine reorganization into the hypothalamus and hippocampal formation, among other cerebral areas [100, 101].

In conclusion, the circulating leptin and BDNF levels and its penetration in the arcuate nucleus and adjacent areas, both have inhibitory action on the appetite. ie., both of them cause a desire to stop eating. A different conclusion to the bariatric surgery procedures (gastric sleeve and band ,among others) to lose body weight. Likewise, BDNF is essential for the development of the central nervous system and for neuronal plasticity.

The hypothalamic-pituitary-gonadal (hpg) axis

Normally from both temporal lobes, all sensory modalities (especially,sexual excitation) are send to the hypothalamus through the fornix [22, 23, 46] and moreover, it receive also sen-

sory impulses from the spinal cord. So that, LHRH neurons located in the arcuate nucleus and preoptic area [93] are stimulated by sexual impulses through glutamatergic axons originated from the hippocampal formation. The pulsatile LHRH secretion from small neurons located in the arcuate nucleus and preoptic area are transported through unmyelinated axons in the median eminence. Then, this hormone is released into a network (primary plexus) and transported through veins (hypophyseal portal veins) to a secondary capillaries network (secondary plexus) that supplies the adenohypophysis. Here, LHRH acts on the gonadotrophs to provoke the liberation of follicle stimulating hormone (FSH) and luteinizing hormone (LH) to the blood stream [20, 83, 102]. The secretion of FSH occurs when the pulsatile frequency of LHRH is low and by contrast, LH when is high. Both sexual hormones have biological action in the ovaries and testicles [83, 103]. The LHRH activity is very low during childhood and is activated at puberty or adolescence. There are differences in LHRH secretion between females and males. In males, LHRH is secreted in pulses at a constant frequency; However, in females the frequency of the pulses varies during the menstrual cycle and there is a large surge of LHRH just before ovulation [104]. Therefore, the stimulation frequent of this HPG axis may favor the growth and function of the sexual organs and besides, to provoke rejuvenation [1, 27, 39].

Hypothalamic dysfunction and omental transplantation

Between 25 to 30 years of age, the cerebral blood flow decline progressively to means values of adults [9, 27, 105] and in general, starting from 50 years the cerebral blood flow and glucose consumption are reduced still more [105, 106]. Deterioration circulatory that coincides which appearance of atheromatous plaques in the supraclinoid carotids [106-108] and it observed into patients who received omental transplantation on the optic chiasma, carotid bifurcation and anterior perforated space for patients with ischemic optic chiasma [109, 110], Huntington's disease [67, 111], Alzheimer's disease [112-116] and neurogenic hypertension [4, 7, 74].

In addition to the anatomical variants of the circle of Willis and its branches [117-119], the atheromatous plaques located at the mouths

Omentum for neuroendocrinological disorders

of the superior hypophyseal, infundibular and anterior perforating arteries are responsible for progressive ischemia in the adenohypophysis and mediobasal portion of the hypothalamus. Thus, this mediobasal portion does not receive suitably the amount of ghrelin, leptin, BDNF and oxygen, among other substances from the circuminfundibular plexus; because several anterior perforating arteries are exsanguines [1, 6, 7, 27].

On May 1998, we transplanted omental tissue to a 75-year-old woman with history of type 2 DM, attacks of daytime sleepiness and mild Alzheimer's disease. After surgery, we observed complete reversal of the three clinical data [3, 110, 116]. In my opinion, the reversal of these periods of somnolence was due to functional recovery of the orexin neurons; because in contrast to this, the loss of these neurons in humans is associated with the sleep disorder narcolepsy [44, 120]. On March 2003, we report to two patients with history of cerebrovascular disease, obesity and EAH whom received an omental transplantation. After surgery, they experienced neurological improvement, loss of weight (the reduction of the abdominal obesity was evident) and normalization of arterial hypertension [2]. I think that, this gradual loss of body weight, without no food restriction was due to suppression exerted by leptin on the NPY and AgRP neurons in the arcuate nucleus [89, 95, 121]. A surgical method against obesity [2] and very different to the bariatric surgery procedures. Likewise, on January 2004, we transplanted omental tissue to a 82-year-old man with history of type 2 DM, EAH, cerebrovascular disease and erectile dysfunction. After the operation, he presented neurological improvement, normal levels of circulating blood glucose, normalization of EAH, rejuvenation and sex life with erection and orgasm in 3 or 4 times a month [1, 3]. Neurological findings suggestive of a functional recovery of residual neurons in the arcuate nucleus and adjacent nuclei [1, 7, 9, 27, 74]. Then the excessive food intake into obese patients is due to short of penetration of leptin in the arcuate nucleus [2] and by contrast, action of ghrelin neural cells on the NPY and AgRP neurons within the hypothalamus [31]. For these reasons, the obese patients have the appetite increased.

I believe that these neurosurgical observations were due to the omentum by two reasons [33,

56, 58, 122-125]. First, because the omentum is the best tissue for developing vascular connections with underlying and adjacent zones and second, it provides omental stem cells for neurogenesis and neuronal regeneration in the hypothalamic nuclei. In other words, this surgical technique can produce anatomical and functional improvement of the hypothalamus and so, to improve or normalize the function of many neuroendocrinological disorders of hypothalamic origin

Conclusions

Like aging, Huntington's disease, Alzheimer's disease, Parkinson's disease and amyotrophic lateral sclerosis [9, 27, 67, 112, 126]. I believe that obesity in adults, type 2 DM in people adults, EAH and narcolepsy have also ischemic origin, in one or several hypothalamic nuclei. Progressive ischemia which is caused by atherosclerosis in the supraclinoid carotids and associated with vascular anomalies of the circle of Willis.

In contrast to this, its revascularization by means of omental tissue provoke complete reversal or improvement of these diseases. Because the omental tissue placed on the optic chiasma, carotid bifurcation and anterior perforated space promotes the neof ormation of blood vessels and, through omental penetrating vessels into the underlying and adjacent brain, transports neurotransmitters, cytokines, and neurotrophic factors. Thus, the hypothalamic nuclei receives an increase in blood flow, leptin, ghrelin, oxygen, and omental stem cells, to maintain the neuroendocrine regulation of the hypothalamus. In other words, in my opinion, the hypothalamic revascularization with omental tissue in adult patients with obesity and type 2 DM have best advantages than the bariatric surgery procedures.

Disclosure of conflict of interest

None.

Address correspondence to: Dr. Hernando Rafael, Bélgica 411-BIS, Colonia Portales, Mexico 03300, Mexico. Tel: +(5255) 5532 9101; +(51) 991 489 111; E-mail: hrtumi@yahoo.com

References

- [1] Rafael H. Rejuvenation after omental transplantation on the optic chiasma and carotid

Omentum for neuroendocrinological disorders

- bifurcation. *Case Rep Clin Pract Rev* 2001; 7: 48-51.
- [2] Rafael H, Fernandez E, Ayulo V, Dávila L. Weight loss following omental transplantation on the anterior perforated space. *Case Rep Clin Pract Rev* 2003; 4: 160-162.
- [3] Rafael H, Mego R, Moromizato P, Garcia W, Rodriguez J. Omental transplantation for type 2 diabetes mellitus. A report of two cases. *Case Rep Clin Pract Rev* 2004; 5: 481-486.
- [4] Rafael H. Hipertension arterial esencial. Un análisis neurológico sobre su etiología. *Hipertensión (Méx)* 2000; 20: 7-10.
- [5] Rafael H, Mego R, Correa F, Moromizato P, Espinoza M. Transplante de epiplón en hipertensos con isquemia hipotalámica: Report de 3 casos. *Hipertensión (Peru)* 2000; 5: 26-28.
- [6] Rafael H. Isquemia hipotalámica por aterosclerosis y diabetes mellitus tipo 2. *Rev Climaterio (Méx)* 2004; 7: 192-197.
- [7] Rafael H, Ayulo V, Mego R. Transplante de epiplón sobre la bifurcación carotídea en contra de la hipertensión arterial esencial. *Rev Mex Cardiol* 2010; 21: 19-24.
- [8] Lang J. Surgical anatomy of the hypothalamus. *Acta Neurochir* 1985; 75: 5-22.
- [9] Rafael H. Therapeutic methods against aging. *Turk J Geriatri* 2010; 13: 138-144.
- [10] De Souza DG, Prevedello DM, Ditzel Filho LF, Barges-Col J, Doglietto F, Morera V, et al. Superior hypophyseal artery anatomy: A ventral perspective. *J Neurol Surg Dis* 2014; 75: A116.
- [11] Meeratana W, Asuvapongpatana S, Poonkhum R, Pradidarcheep W, Mingsakul T, Somana R. Hypothalamic vascularization in the common free shrew (*tupaia glis*) as revealed by vascular corrosion cast/SE technique. *Science Asia* 2002; 28: 319-326.
- [12] Rhoton AL Jr. The supratentorial arteries. *Neurosurgery* 2002; 51 Suppl 1: 53-120.
- [13] Daniel PM. The blood supply of the hypothalamus and pituitary gland. *Br Med Bull* 1966; 22: 202-208.
- [14] Liu W, Xu ZM, Liu XM, Long L, Yin WN, Wang GH. Microsurgical anatomy of perforated arteries in the hypothalamic area. *Turk Neurosurg* 2015; 25: 63-68.
- [15] Marinkovic SV, Milisavljevic MM, Marinkovic ZD. Microanatomy and posible clinical significance of anastomosis among hypothalamic arteries. *Stroke* 1989; 20: 1341-1352.
- [16] Dawson BH. The blood vessels of the human optic chiasma and their relation to those of the hypophysis and hypothalamus. *Brain* 1958; 81: 207-217.
- [17] Martin JB. Neural regulation of growth hormone secretion. *N Engl J Med* 1973; 288: 1384-1392.
- [18] Rafael H. *Nervios craneanos*. Tercera edición. In: México DF, editor. 2009. pp. 205-245.
- [19] Rafael H. Etiología y fisiopatología de la diabetes mellitus type 2. *Rev Mex Cardiol* 2011; 22: 39-43.
- [20] Gómez-Torres N, Aguilera-Reyes U, Garcia-Castillo O. Las orexinas dos péptidos hipotalámicos: Su localización y acciones en el eje hipotálamo-hipófisis-gonadas. *Rev Mex Neurosci* 2014; 15: 345-350.
- [21] Morrison SF, Madden Ch J, Tupone D. An orexigenic projection from perifornical hypothalamic to raphe pallidus increase rat Brown adipose tissue thermogenesis. *Adipocyte* 2012; 1: 116-120.
- [22] Rafael H, Valadez MT. Disfunción cerebral mínima. II: Etiología y fisiopatología. *Salud Pública Méx* 1986; 28: 495-503.
- [23] Nigri A, Ferraro S, DIncert L, Critchley H, Bruzzone MG, Minati L. Connectivity of the amígdala, piriform, and orbitofrontal cortex during olfactory stimulation: A functional MRI study. *Neuroreport* 2013; 24: 171-175.
- [24] Krisht AF, Barrow DL, Barret DW, Bonner GD, Shengalala G. The Microsurgical anatomy of the superior hypophyseal artery. *Neurosurgery* 1994; 35: 899-903.
- [25] Schneeberger M, Gomis R, Claret M. Hypothalamic and brainstem neuronal circuits controlling homeostatic energy balance. *J Endocrinol* 2014; 220: T25-T46.
- [26] Schaeffer M, Langlet F, Lafont Ch, Molino F, Hodson DJ, Roux T, Lamarque L, Verdié P, Bourrier E, Dehouck B, Banères JL, Martinez J, Méry PF, Marie J, Trinquet E, Fehrentz JA, Prévot V, Mollard P. Rapid sensing of circulating ghrelin by hypothalamic appetite modifying neurons. *Proc Natl Acad Sci U S A* 2013; 110: 1512-1517.
- [27] Rafael H, Valadez MT. Hypothalamic revascularization and rejuvenation. *J Aging Gerontol* 2014; 2: 24-29.
- [28] Backberg M, Madjid N, Ogren SO, Meister B. Down-regulated expression of agouti-related protein (AgRP) in RNA in the hypothalamic arcuate nucleus of hyperphagic and obese tub/tub mice. *Brain Res Mol Res* 2004; 125: 129-139.
- [29] Kaushik S, Rodriguez-Navarro JA, Arias E, Kiffin R, Sahu S, Schwartz GJ, Cuervo AM, Singh R. Autophagy in hypothalamic AgRP neurons regulates food intake and energy balance. *Cell Metab* 2011; 14: 173-183.
- [30] Wu Q, Whiddon BO, Palmiter D. Ablation of neurons expressing agouti-related protein, but not melanin concentrating hormone, in leptin-deficient mice restores metabolic functions and fertility. *Proc Natl Acad Sci U S A* 2012; 109: 3155-3160.
- [31] Kojima M, Kangawa K. Ghrelin: Structure and function. *Physiol Rev* 2005; 85: 495-522.
- [32] Ayuso-Sacido A, Roy NS, Schwartz TH, Greenfield JP, Boockvar JA. Long-term expansion of

Omentum for neuroendocrinological disorders

- adult human brain subventricular zone precursors. *Neurosurgery* 2008; 62: 223-231.
- [33] Rafael H. Stem cells. *J Neurosurg* 2008; 108: 841-842.
- [34] Altman J. A new neurons formed in the brain of adult mammals. *Science* 1962; 135: 1127-1128.
- [35] Bolborea M, Dale N. Hypothalamic tanycytes: Potential roles in the control of feeding and energy balance. *Trends Neurosci* 2013; 36: 91-100.
- [36] Kokoeva MV, Yin H, Flier JS. Neurogenesis in the hypothalamus of adult mice: Potential role in energy balance. *Science* 2005; 310: 679-683.
- [37] Livesey FJ. A potential link between obesity and neural stem cells dysfunction. *Nature Cell Biol* 2012; 14: 987-989.
- [38] Leal S, Andrade JP, Paula-Barbosa MM, Madeira MD. Arcuate nucleus of the hypothalamus: Effects of age and sex. *J Comp Neurol* 1988; 401: 65-88.
- [39] Veldhuis JD, Keenan DM, Liu PY, Iranmanesh A, Takahashi PY, Nehra AX. The aging male hypothalamic-pituitary-gonadal axis: Pulsatility feedback. *Mol Cell Endocrinol* 2009; 299: 14-22.
- [40] Stanley BG, Magdalin W, Seirafi A, Thomas WJ, Leibowitz SF. The perifornical area: The major focus of patchily distributed hypothalamic neuropeptide Y-sensitive feeding systems. *Brains Res* 1993; 604: 304-317.
- [41] King BM. The rise, fall and resurrection of the ventromedial hypothalamus in the regulation of feeding behavior and body weight. *Physiol Rev* 2006; 87: 221-244.
- [42] Cone RD. Anatomy and regulation of the central melanocortin system. *Nat Neurosci* 2005; 8: 571-578.
- [43] Peyron C, Tighe DK, Van den Pol AN, DeLecea L, Heller HC, Sutcliffe JG, Kilduff TS. Neurons containing hypocretin (orexin) project to multiple neuronal systems. *J Neurosci* 1998; 18: 9996-10015.
- [44] Tupone D, Madden CJ, Cano G, Morrison SF. An orexigenic projection from perifornical hypothalamus to raphe pallidus increases rat Brown adipose tissue thermogenesis. *J Neurosci* 2011; 31: 15944-15945.
- [45] Obici S, Feng Z, Arduini A, Conti R, Rossetti L. Inhibition of hypothalamic carnitine palmitoyl-transferase-1 decrease food intake and glucose production. *Nat Med* 2003; 9: 756-761.
- [46] Campbell RE, Gaidamaka G, Han SK, Herbison AE. Dendro-dendritic bundling and shared synapses between gonadotropin-releasing hormone neurons. *Proc Natl Acad Sci U S A* 2009; 106: 10835-10840.
- [47] Fu LY, Van den Pol AN. Agouti-related peptide and MC3/4 receptor agonist both inhibit excitatory hypothalamic ventromedial nucleus neurons. *J Neurosci* 2008; 28: 5433-5449.
- [48] Mendez-Sanchez N, Chavez-Tapia NC, Uribe-Esquivel M. La ghrelina y su importancia con el eje gastro-hipotalámico. *Gac Med Méx* 2006; 142: 49-58.
- [49] Melega WP, Lacan G, Gorgulho AA, Behnke EJ, De Salles AAF. Hypothalamic deep brain stimulation reduce weight gain in an obesity animal model. *PLoS One* 2012; 7: e30672.
- [50] Whiting DM, Tomycz ND, Bailes J, de Jonge L, Lecoultre V, Wilent B, Alcindor D, Prostko ER, Cheng BC, Angle C, Cantella D, Whiting BB, Mizes JS, Finniss KW, Ravussin E, Oh MY. Lateral hypothalamic area deep brain stimulation for refractory obesity: A pilot study with preliminary data on safety, body weight, and energy metabolism. *J Neurosurg* 2013; 119: 56-63.
- [51] Sangild PT, Hilsted L, Nexø E, Fowden AL, Silver M. Secretion of acid gastrin, and cobalamin-binding proteins by the fetal pig stomach: Developmental regulation by cortisol. *Exp Physiol* 1994; 79: 135-146.
- [52] Rosmond R. Stress induced disturbances of the HPA axis: A pathway to type 2 diabetes? *Med Sci Monit* 2003; 9: RA35-39.
- [53] Chalew S, Nagel H, Shore S. The hypothalamic-pituitary-adrenal axis in obesity. *Obes Res* 1995; 3: 371-382.
- [54] Mahadik SR, Deo SS, Mehtalia SD. Role of adipocytokines in insulin resistance: Studies urban western indian population. *Inter J Diabetes Metab* 2010; 18: 35-42.
- [55] Ouchi N, Ohashi K, Shibata R, Murohara T. Adipocytokines and obesity-linked disorders. *Nagoya J Med Sci* 2012; 74: 19-30.
- [56] Galic S, Oakhill JS, Steinberg GR. Adipose tissue as an endocrine organ. *Mol Cell Endocrinol* 2010; 316: 129-139.
- [57] Gimenez O, Caixas A. Ghrelina: De la secreción de hormona de crecimiento a la regulación del equilibrio energético. *Endocrinol Nutr* 2004; 51: 464-472.
- [58] Bettowski J. Adiponectin and resistin: New hormones of White adipose tissue. *Med Sci Monit* 2003; 9: RA55-61.
- [59] Bettowski J. Apelin and visfatin: Unique beneficial adipokines upregulated in obesity? *Med Sci Monit* 2006; 12: RA112-119.
- [60] Gerrits AJ, Gitz E, Koekman CA, Visseren FL, Van Haeften TW, Akkerman JWN. Induction of insulin resistance by adipokines resistin, leptin, plasminogen activator inhibitor-1 and retinol binding protein 4 in human megakaryocytes. *Haematologic* 2012; 97: 1149-1157.
- [61] Jamaluddin MS, Weakley SM, Yao Q, Chen C. Resistin: Functional roles and therapeutic considerations for cardiovascular diseases. *Br J Pharmacol* 2012; 165: 622-632.

Omentum for neuroendocrinological disorders

- [62] Lee S, Lee HC, Kwan YW, Lee SE, Cho Y, Kim J, Lee S, Kim JY, Lee J, Yang HM, Mook-Jung I, Nam KY, Chung J, Lazar MA, Kim HS. Adenylyl-cyclase associated protein 1 is a receptor for human resistin and mediates inflammatory actions of human monocytes. *Cell Metabolism* 2014; 19: 484-497.
- [63] Olefsky JM, Koterman OG. Mechanism of insulin resistance in obesity and non-insulindependent (Type 2) diabetes. *Am J Med* 1981; 70: 151-168.
- [64] Tsao TS, Hug CH, Ladish HF. Adipokines: Regulator of metabolic integration and energy metabolism. In: Le Roith D, Taylor SI, Olefsky JM, editors. *Diabetes mellitus: A fundamental and clinical text*. 3rd edition. Part VI. Chapter 65. Philadelphia: Lippincott Williams & Wilkins; 2004. pp. 963-977.
- [65] Rafael H, Rodriguez J. Drogas anti-inflamatorias no-esteroides para la hipertensión esencial. *Rev Fac Med UNAM* 2009; 52: 227-229.
- [66] Starke RM, Chalouhi N, Ding D, Hasan DM. Potential role of aspirin in the prevention of aneurysmal subarachnoid hemorrhage. *Cerebrovasc Dis* 2015; 39: 332-342.
- [67] Rafael H. Omental transplantation for neurodegenerative diseases. *Am J Neurodegener Dis* 2014; 3: 50-63.
- [68] Laha RK, Jannetta PJ. Glossopharyngeal neuralgia. *J Neurosurg* 1977; 47: 316-320.
- [69] Fein JM, Frishman W. Neurogenic hypertension related to vascular compression of the lateral medulla. *Neurosurgery* 1980; 6: 615-622.
- [70] Levy EI, Scarrow HM, Jannetta PJ. Microvascular decompression in the treatment of hypertension: Review and update. *Surg Neurol* 2001; 55: 2-11.
- [71] Carey RM. Best papers in hypertension. *Hypertension* 2013; 61: 746-750.
- [72] Ewalt JR. The neurogenic aspects of hypertension. *Dis Nerv Syst* 1944; 5: 330-334.
- [73] Rafael H, Mego R. Normalization of neurogenic arterial hypertension after surgery in the left cerebellar hemisphere. *Case Rep Clin Pract Rev* 2006; 7: 52-55.
- [74] Rafael H. Neurogenic hypertension. *J Neurosurg* 2003; 99: 1117-1118.
- [75] Saper CB, Loewy AD, Swanson LW, Cowan WM. Direct hypothalamic-autonomic connections. *Brain Res* 1976; 117: 305-312.
- [76] Bucy PC. Carotid sinus nerve in man. *Arch Intern Med* 1936; 58: 418-432.
- [77] Rafael H. La hipertensión neurogénica debe ser definido como secundaria. *Acta Med Per* 2013; 30: 101-102.
- [78] Sakata I, Sakai T. Ghrelin cells in the gastrointestinal tract. *Int J Pept* 2010; 2010.
- [79] Milke MP. Ghrelina: mas allá de la regulación del hambre. *Rev Gastroenterol Méx* 2005; 70: 465-474.
- [80] Gil-Campos M, Aguilera CM, Cañete R, Gil A. Ghrelin: A hormone regulating food intake and energy homeostasis. *Br J Nutri* 2006; 96: 201-226.
- [81] Wang Q, Liu Ch, Uchida A, Chuang JC, Walker A, Liu T, Osborne-Lawrence S, Mason BL, Mosher C, Berglund ED, Elmquist JK, Zigman JM. Arcuate AgRP neurons mediate orexigenic and gluco-regulatory actions of ghrelin. *Mol Metab* 2014; 3: 64-72.
- [82] Malenka RC, Nestler EJ, Hyman SE. Neural and neuroendocrine control of the internal milieu. In: Sydor A, and Brown RY. *Molecular pharmacology*, editors. A foundation for clinical neuroscience (2nd ed). New York: McGraw-Hill Medical; 2009. pp. 265-266.
- [83] Veldhuis JD. Aging and hormones of the hypothalamo-pituitary axis: Gonadotrophic axis in men and somatotrophic axis in men and toman. *Aging Res Rev* 2008; 7: 189-208.
- [84] Osterstock G, Escobar P, Mitutsova V, Gouty-Colomer LA, Fontanoud P, Molina F, Fehrentz JA, Carmignac D, Martinez J, Guerinéau NC, Robinson IC, Mollard P, Méry PF. Ghrelin stimulation of growth hormone-releasing hormones is direct in the arcuate nucleus. *PLoS One* 2010; 5: e9159.
- [85] Sibilia V, Pagani F, Cuidabono F, Loutelli V, Torsello A, Deghenghi R, Netti C. Evidence for a central inhibitory role of growth hormone secretagogues and ghrelin on gastric acid secretion in conscious rats. *Neuroendocrinology* 2002; 75: 92-97.
- [86] Nass R, Pezzoli SS, Oliveri MC, Patrie JT, Harrel FE Jr, Clasey JL, Heymsfield SB, Bach MA, Vance ML, Thorner MO. Effects of oral ghrelin mimetic on body composition and clinical outcome in healthy older adults: A randomized trial. *Ann Intern Med* 2008; 149: 601-611.
- [87] Zollers B, Rhodes L. Capromorelin, an orally active ghrelin agonist stimulates growth hormone, sustained increases in IGF-1, increased food intake and weight gain in Beagle dogs. Presented on Aratana Therapeutics to present at 2014 ACVIM Forum. Kansas City, May 2, 2014.
- [88] Wabitsch M, Funcke JB, Lennerz B, Kunnle U, Lahr G, Debatin KM, Vatter P, Gierschik P, Moepf B, Fischer-Posovszky P. Biological inactive leptin and early-onset extreme obesity. *N Engl J Med* 2015; 372: 48-54.
- [89] Klok MD, Jakobsdottir S, Drent ML. The role of leptin and ghrelin in the regulation of food intake and body weight in humans: A review. *Obes Rev* 2007; 8: 21-34.
- [90] Munzberg H, Jobst EE, Bates SH, Jones J, Villanueva E, Leshan R, Björnholm M, Elmquist J, Sleeman M, Cowley MA, Myers MG Jr. Appropriate inhibition of orexigenic hypothalamic arcu-

Omentum for neuroendocrinological disorders

- ate nucleus neurons independently of leptin receptor/stats3 signaling. *J Neurosci* 2007; 27: 69-74.
- [91] Simpson KA, Martin NM, Bloon SR. Hypothalamic regulation of food intake and clinical therapeutic applications. *Arq Bras Endocrinol Metab* 2009; 53: 120-128.
- [92] León F. Desnutrición y amenorrea hipotalámica funcional. Neuropeptidos (leptina, adiponectina, ghrelina) y su relación con la homeostasis metabólica. *Rev Argent Endocrinol Metab* 2009; 46: 11-21.
- [93] Chee MJ, Myers MG Jr, Price CJ, Colmers WF. Neuropeptide Y suppresses anorexigenic output from the ventromedial nucleus of the hypothalamus. *J Neurosci* 2010; 30: 3380-3390.
- [94] Meek TH, Matsen ME, Dorfman MD, Guyenet SJ, Damian V, Nguyen HT, Taborsky GJ Jr, Morton GJ. Leptin action in the ventromedial hypothalamic nucleus is sufficient, but not necessary, to normalize diabetic hyperglycemia. *Endocrinology* 2013; 154: 3067-3076.
- [95] Bouret SG, Draloe SJ, Simerly RB. Trophic action of leptin on hypothalamic neurons that regulate feeding. *Science* 2004; 304: 108-110.
- [96] Perello M, Raingo J. Leptin activates oxytocin neurons of the hypothalamic paraventricular nucleus in both control and diet-induced obese rodents. *PLoS One* 2013; 8: e59625.
- [97] Elmquist JK, Bjorbaek C, Ahima RS, Flier JS, Saper CB. Distributions of leptin receptor mRNA isoforms in the rat brain. *J Comp Neurol* 1998; 395: 395-547.
- [98] Conner JM, Lauterborn JC, Yan Q, Gall CM, Varon S. Distribution of brain-derived neurotrophic factor (BDNF) protein and mRNA in the normal adult rat CNS: Evidence for anterograde axonal transport. *J Neurosci* 1997; 17: 2295-2313.
- [99] Binder DK, Scharfman HE. Brain-derived neurotrophic factor. *Growth Factors* 2004; 22: 123-131.
- [100] Maffioletti E, Zanardini R, Gennarelli M, Bocchio-Chiavetto L. Influence of clotting duration on brain-derived neurotrophic factor (BDNF) dosage in serum. *Biotechniques* 2014; 57: 111-114.
- [101] Autry AE, Monteggia LM. Brain-derived neurotrophic factor and neuropsychiatric disorders. *Pharmacol Rev* 2012; 64: 238-258.
- [102] Tanriverdi F, Silveira LF, MacColl GS, Bouloux PM. The hypothalamic-pituitary-gonadal axis: Immune function and autoimmunity. *J Endocrinol* 2003; 176: 293-304.
- [103] Potau VN, Carreño de Pug A. Gonadotropinas (LH y FSH) y corticotropina (ACTH). *Endocrinol Nutri* 2007; 54: 109-117.
- [104] Ehlers K, Halvorson LM. Gonadotropin-releasing hormone (GnRH) and the GnRH receptor (GnRH-R). *Glob libr women's med (ISSN:1756-2228)* 2013. Doi 10.3843/Glown.10285.
- [105] Lassen NA. Cerebral blood flow and oxygen consumption in man. *Physiol Rev* 1959; 39: 183-238.
- [106] Hass WK, Fields WS, North RR, Kricheff I, Chase NE, Bauer RB. Joint study of extracranial arterial occlusion. II: Arteriography, technique, sites and Complications. *JAMA* 1968; 203: 961-968.
- [107] Flora GC, Baker AB, Loewenson RB, Klassen AC. A comparative study of cerebral atherosclerosis in males and females. *Circulation* 1968; 39: 701-710.
- [108] Surur A, Cámara JP, Salvatierra W, Sanz R, Canavosio N, Videla R, et al. Localización y frecuencia de placas ateromatosas intracraneales en pacientes mayores de 40 años. *Rev Argent Radiol* 2014; 78: 193-198.
- [109] Rafael H, Moromizato P, Espinoza M, Talavera V. Functional recovery of the injured optic chiasma after omental transplantation. *Turk Neurosurg* 1999; 9: 68-72.
- [110] Rafael H, Mego R. Omental transposition. *Surg Neurol* 1999; 52: 539-541.
- [111] Rafael H, Mego R, Moromizato P, Buendia J. Enfermedad de Huntington y ausencia de flujo sanguíneo en las arterias recurrentes. *Rev Mex Aterosc* 2000; 3: 4-8.
- [112] Rafael H. Cerebral atherosclerosis and oxidative stress in some challenging diseases. *J Neurol Sci (Turk)* 2004; 21: 343-349.
- [113] Rafael H, Mego R, Moromizato P, Espinoza M. Enfermedad de Alzheimer y aterosclerosis del polígono de Willis. *Rev Mex Aterosc* 1999; 2: 30-33.
- [114] Rafael H, Valadez MT. Enfermedad de Alzheimer: Hallazgos clínicos y tomográficos. *Rev Climaterio Méx* 2001; 5: 3-7.
- [115] Rafael H. Cerebral atherosclerosis and mild Alzheimer's disease. *Stroke* 2003; 34: e106.
- [116] Rafael H, Mego R, Moromizato P, Espinoza M, Valadez MT. Transplante de epiplón para la enfermedad de Alzheimer. *Rev Climaterio Méx* 2000; 3: 83-89.
- [117] Riggs HE, Griffiths JO. Anomalies of the circle of Willis in persons with nervous and mental disorders. *Arch Neurol Psychiat (Chicago)* 1938; 39: 1353-1354.
- [118] Alpers BJ, Berry RG. Circle of Willis in cerebral vascular disorders: The anatomical structure. *Arch Neurol* 1963; 8: 398-402.
- [119] Silva AR, Brandao RL, Moraes M. Carotid siphon geometry and variants of the circle of Willis in the origin of carotid aneurysms. *Arq Neuro-Psiquiat* 2012; 70: 917-921.
- [120] Liblau R, Vassalli A, Seifinejad A, Tafti N. Hypocretin (orexin) biology and the pathophysiology of narcolepsy with cataplexy. *Lancet Neurol* 2015; 14: 318-328.

Omentum for neuroendocrinological disorders

- [121] Fulton S, Woodside B, Shizgal P. Modulation of brain reward circuitry by leptin. *Science* 2000; 287: 125-128.
- [122] García-Gómez I, Goldsmith HS, Angulo J, Prados A, López-Hervás P, Cuevas B, Dujovny M, Cuevas P. Angiogenic capacity of human omental stem cells. *Neurol Res* 2005; 27: 807-811.
- [123] Rivera F, Avila E, Calderon JL, Valenzuela T, Gagne-Vogt L. Neuronal repopulation into arcuate nucleus of hypothalamus. *Arch Neurosci (Méx)* 2009; 14: 111-115.
- [124] Izadpanah R, Trygg C, Patel B, Kriedt C, Dufour J, Gimble JM, Bunnell BA. Biological properties of mesenchymal stem cells derived from bone marrow and adipose tissue. *J Cell Biochem* 2006; 99: 1285-1297.
- [125] Mohammadi R, Azizi S, Amini K. Effects of undifferentiated cultured omental adipose-derived stem cells on peripheral nerve regeneration. *J Surg Res* 2013; 180: E91-E97.
- [126] Rafael H. Cerebral atherosclerosis causes neurodegenerative diseases. *Med Sci Monit* 2010; 16: L1-2.