Am J Nucl Med Mol Imaging 2024;14(1):63-71
www.ajnmmi.us /ISSN:2160-8407/ajnmmi0154980

Original Article

Unexpected ^{99m}Tc-pertechnetate avidity of lymph node metastases predicts better response to radioiodine therapy in differentiated thyroid cancer patients with lymph node metastases

Jie Liu[1*], Xin Li[1*], Linfa Li[1], Yuhua Yin[2], Hu Cai[3], Heqing Yi[1]

[1]*Department of Nuclear Medicine, Zhejiang Cancer Hospital, Hangzhou 310022, Zhejiang, China;* [2]*Department of Quality Management, Hangzhou First People's Hospital, Hangzhou 310022, Zhejiang, China;* [3]*Department of Integration of Western and Traditional Chinese Medicine, Zhejiang Cancer Hospital, Hangzhou 310022, Zhejiang, China.* [*]*Equal contributors.*

Received December 16, 2023; Accepted February 11, 2024; Epub February 20, 2024; Published February 28, 2024

Abstract: Objective: To investigate the value of ^{99m}Tc-pertechnetate scan in postoperative differentiated thyroid cancer (DTC) patients with lymph node (LN) metastases (LNM) uptake ^{99m}Tc-pertechnetate, especially the predictive value to their response to radioiodine-131 (^{131}I) therapy. Methods: This retrospective study collected 752 patients with DTC and LNM treated at Zhejiang Cancer Hospital between May 2012 and December 2017. Depending on the ability of LNM uptake ^{99m}Tc-pertechnetate, the patients were grouped as the ^{99m}Tc-pertechnetate-avid (n=88) vs. ^{99m}Tc-pertechnetate-non-avid (n=664) groups. And Propensity score matching (PSM) was performed at a 1:4 ratio to reduce confounding bias. Results: In the PSM analysis, the 1:4 matched cohort comprised 752 patients (88 with ^{99m}Tc-pertechnetate-avid LNM, 664 with ^{99m}Tc-pertechnetate-non-avid LNM). Patients' age, initial ^{131}I activity and frequency of iodine therapy were included as covariates. After PSM analysis, 363 patients (^{99m}Tc-pertechnetate-avid group, n=83; ^{99m}Tc-pertechnetate-non-avid group, n=280) were successfully matched. Among the 363 PSM-matched patients, 48/83 (57.8%) in the ^{99m}Tc-pertechnetate-avid group and 158/280 (56.4%) in the ^{99m}Tc-pertechnetate-non-avid group had two or more ^{131}I treatments. The nsTg and the percentage of changes in ssTg between the ^{99m}Tc-pertechnetate-avid and ^{99m}Tc-pertechnetate-non-avid groups were significantly different ([0.05 (0.04 to 0.90) vs. 0.40 (0.04 to 4.92), p=0.018] and [-88% (-98%, -50%) vs. -66% (-86%, -30%), $p < 0.001$], respectively). No significant differences were observed between the two groups in the other parameters (age, pathological type, distant metastasis, follow-up time, AJCC TNM stage, initial ^{131}I treatment activity, and ^{131}I treatment frequency) after PSM (all $p > 0.05$). Conclusion: In patients with DTC and LNM, LNM uptake of ^{99m}Tc-pertechnetate is a rare phenomenon. Patients with ^{99m}Tc-pertechnetate-avid LNMs were more likely to benefit from ^{131}I therapy, even after adjustment for age, ^{131}I treatment frequency, and initial ^{131}I activity.

Keywords: Differentiated thyroid cancer, lymphatic metastasis, ^{99m}Tc-pertechnetate, radioiodine, SPECT/CT, thyroglobulin

Introduction

Thyroid cancer is the 11th most common cancer worldwide, with an estimated 586,202 new cases in 2020 and 43,646 deaths [1]. In recent years, the incidence of differentiated thyroid cancer (DTC) has shown a significant upward trend [2, 3]. Papillary thyroid cancer (PTC) is the most common type of thyroid cancer (reported to account for about 80% of all thyroid cancers) [4]. PTC can be sporadic or genetic and can be subtyped as well-differentiated or poorly differentiated, with each subtype encompassing multiple variants (some being more aggressive than others) [4, 5]. Follicular thyroid cancer (FTC) arises from thyroid follicular cells, is classified as a DTC, and accounts for about 10%-20% of all thyroid cancers [6].

Radioactive iodine (RAI) (^{131}I) therapy can be used in some patients with DTC to minimize the risk of disease recurrence and metastatic spread after total thyroidectomy [6]. The goals of administering postoperative RAI therapy after total thyroidectomy include 1) Employing RAI remnant ablation facilitates the identification of disease recurrence and initial staging through tests such as thyroglobulin (Tg) measurements or whole-body RAI scans, 2) Utilizing RAI adjuvant therapy amins to improve disease-free survival by eliminating suspected subclinical microscopic residual disease, particularly in patients who are at elevated risk of disease recurrence, and 3) RAI therapy is employed to improve disease-specific and disease-free survival by treating persistent disease in high-risk patients [6].

^{99m}Tc-pertechnetate imaging is often used before ^{131}I treatment for DTC to assess the residual thyroid status after surgery [7]. Most studies of ^{99m}Tc-pertechnetate scans in patients with DTC mainly focused on the diagnostic efficiency of thyroid remnant or predicted value of low- to intermediate-risk DTC's therapy response to RAI therapy [7-9]. In postoperative ^{99m}Tc-pertechnetate scan, ^{99m}Tc-pertechnetate avidity of DTC metastatic lesions is a rare phenomenon, only described by case reports [10-15], in which the ^{99m}Tc-pertechnetate-avid metastatic foci were detected serendipitously. Some literature described the clinical characteristics of ^{99m}Tc-pertechnetate-avid metastatic foci in DTC, including distant metastasis like lung and bone [16-18]. A previous study showed that among

https://doi.org/10.62347/PBCV5827

184 patients with stimulated serum thyroglobulin (ssTg) > 10 ng/mL, 72 patients had ^{99m}Tc-pertechnetate-avid metastases, and the ^{99m}Tc-pertechnetate scans would have changed the therapeutic decisions in 10.3% of the patients [16]. In addition, the decrease in ssTg after RAI therapy was more significant in the ^{99m}Tc-pertechnetate-avid group than in the ^{99m}Tc-pertechnetate-non-avid group [16]. Still, the relationship between the avidity of metastatic lesions for ^{99m}Tc-pertechnetate and the therapeutic response to RAI still needs further exploration.

Therefore, this retrospective study analyzed the clinical data of patients diagnosed with DTC and lymph node (LN) metastases (LNM) who underwent RAI treatment at a single hospital. The findings aim to contribute to the delineation of the role of ^{99m}Tc-pertechnetate scans in the management of DTC.

Methods

Study design and patients

This retrospective study included patients with DTC and LNM admitted to the Department of Nuclear Medicine of the Zhejiang Cancer Hospital between May 2012 and December 2017. The study was approved by the Ethics Committee of Zhejiang Cancer Hospital. The requirement for individual informed consent was waived by the committee because of the retrospective nature of the study.

The study included 970 consecutive patients with pathologically confirmed DTC and LNM that were proved by RAI whole-body imaging after RAI treatment. All patients underwent total or nearly total thyroidectomy (≥ 4 weeks) followed by RAI therapy under hormone withdrawal protocol with thyroid-stimulating hormone (TSH) > 30 mU/L. The exclusion criteria were 1) a history of other malignant tumors, 2) thyroglobulin antibodies (TgAb) exceeded the upper limit of normal (because the presence of TgAb affects the accuracy of Tg measurements), or 3) ssTg exceeded the upper limit of the measurement range before the first and second RAI treatment.

Evaluation of the ^{99m}Tc-pertechnetate uptake in metastatic foci

The analysis of the ^{99m}Tc-pertechnetate imaging of the metastatic lesions was performed by two experienced nuclear medicine physicians in combination with the results of neck B-mode ultrasound, chest computed tomography (CT), other related imaging examinations, and laboratory examinations. A consensus was reached regarding the ^{99m}Tc-pertechnetate avidity status of each patient. The diagnostic criteria were as follows. Positive lesions were considered when there were significant radioactive signals outside the thyroid bed, exceeding the surrounding background, and residual thyroid or physiological uptake was excluded. The examination was negative when there were no radioactive signals outside the thyroid bed, i.e., the same as the background. Whether the signal was an LNM depended on the radioiodine whole-body scan (Rx-WBS) and single-photon emission computed tomography (SPECT)/CT or postoperative pathology as the gold standard. The number of ^{99m}Tc-pertechnetate-avid LNMs, the number of ^{99m}Tc-pertechnetate-avid uptake foci, and the location of ^{99m}Tc-pertechnetate-avid LNMs were collected.

The evaluation of the RAI therapy response was based on the prognostic criteria of the 2015 American Thyroid Association Guidelines (ATA Guidelines) [6], combined with the ssTg levels of the last TSH suppression state dynamically monitored after treatment and imaging results to evaluate the effectiveness of RAI therapy. There were four types of response: excellent response (ER), indeterminate response (IDR), biochemical incomplete response (BIR), and structural incomplete response (SIR).

Data collection

The patient's demographic information, including gender and age, along with details such as pathological type, frequency of RAI treatments, ^{131}I activity in the initial RAI treatment, initial stimulated serum thyroglobulin before the first RAI treatment (ssTg1), stimulated serum thyroglobulin before the second RAI treatment (ssTg2), percentage changes in ssTg, LNM site, distant metastasis, AJCC TNM stage, clinical outcomes, and other relevant indicators, were systematically collected. The number of patients who had treatment plan adjustments (converted to surgical treatment or changes in RAI activity) based on their ^{99m}Tc-pertechnetate avidity was recorded. The percentage change in ssTg was calculated as (ssTg2-ssTg1)/ssTg1 × 100%.

Statistical analysis

SPSS 25.0 (IBM, Armonk, NY, USA) and Mstata medical statistical robot were used for data analysis. Propensity score matching (PSM) was performed to match the characteristics between the patients exhibiting ^{99m}Tc-pertechnetate-avid and ^{99m}Tc-pertechnetate-non-avid patients, with a matching ratio of 1:4. Covariates such as patient age, number of RAI treatments, and the initial ^{131}I treatment activity were incorporated into the analysis. The caliper value used for propensity score matching was set at 0.04. The continuous variables that conformed to the normal distribution were presented as means ± standard deviations and compared using the independent sample *t*-test. Continuous variables deviating from normal distribution were expressed as medians with interquartile ranges (IQR) and compared using the Mann-Whitney U-test. The categorical variables were presented as n (%) and assessed using either the chi-square test or Fisher's exact test. Two-sided *p*-values < 0.05 were considered indicative of statistically significant.

Results

A total of 970 patients with LNMs were initially collected. Among them, 95 (9.79%) exhibited ^{99m}Tc-pertechnetate-

Table 1. Characteristics of the patients

Characteristics	^{99m}Tc-pertechnetate-avid group (n=88)	^{99m}Tc-pertechnetate-non-avid group (n=664)	*p*
Gender			< 0.001
Male	50 (56.8%)	248 (37.3%)	
Female	38 (43.2%)	416 (62.7%)	
Age	42.00 (32.00-53.00)	51.00 (40.00-60.00)	< 0.001
RAI treatment frequency	2.00 (1.00-2.00)	2.00 (1.00-2.00)	0.728
^{131}I activity (mCi)	100.00 (100.00-150.00)	100.00 (100.00-120.00)	0.104
ssTg before the first ^{131}I therapy (ng/ml)	23.61 (5.54-81.78)	12.57 (3.10-71.97)	0.041
Distant metastasis			0.010
M0	62 (70.5%)	548 (82.5%)	
M1	26 (29.5%)	116 (17.5%)	

All data are shown as n (%) or median (interquartile range).

Table 2. Site of ^{99m}Tc-pertechnetate-avid LNM and treatment strategy adjustment

Site of ^{99m}Tc-pertechnetate-avid lymph node	n	Transfer to surgical treatment	Increase ^{131}I activity
Mediastinum	40	0	10
Lateral neck	19	7	3
Clavicular region	20	5	2
Mediastinum and lateral neck	1	0	2
Lateral neck and clavicular region	8	2	0
Mediastinum and clavicular region	5	1	4
Mediastinum, lateral neck, and clavicular region	2	2	0
Total	95	17	21

avid LNMs. After excluding 218 patients due to missing data (n=106), high TgAb (n=76), and ssTg values exceeding the upper limit of the measurement range during the first two iodine treatments (n=36), baseline comparisons were conducted between the remaining two groups (88 and 664 patients).

Statistically significant differences were observed in gender [38 (43.2%) vs. 416 (62.7%) female; 50 (56.8%) vs. 248 (37.3%) male], age [42.00 (32.00-53.00) years vs. 51.00 (40.00-60.00) years], distant metastasis cases [26 (29.5%) vs. 116 (17.5%)], ssTg before ^{131}I therapy [23.61 (5.54-81.78) ng/ml vs. 12.57 (3.10-71.97) ng/ml], percentage changes in ssTg between ^{99m}Tc-pertechnetate-avid and ^{99m}Tc-pertechnetate-non-avid groups (all $p < 0.05$). There are 51 patients in the ^{99m}Tc-pertechnetate-avid group and 391 patients in the ^{99m}Tc-pertechnetate-non-avid group had more than two RAI treatments. The percentage changes in ssTg between ^{99m}Tc-pertechnetate-avid and ^{99m}Tc-pertechnetate-non-avid groups were statistically significant [-89% (-97%, -54%) vs. -64% (-87% to -31%), $p < 0.001$]. However, no significant differences were observed in RAI treatment frequency and ^{131}I activity during the initial RAI treatment between the two groups (**Table 1**).

The ^{99m}Tc-pertechnetate imaging revealed a total of 143 LNMs in 95 patients. Among these, 40 patients had LNMs in the upper chest (mediastinal region), 20 in the clavicular region, and 19 in the lateral neck (outside the thyroid bed). Eight patients exhibited ^{99m}Tc-pertechnetate-avid LNs in the lateral neck and clavicular region. Five patients had ^{99m}Tc-pertechnetate-avid LNs in the mediastinal and clavicular region. Two patients presented with ^{99m}Tc-pertechnetate-avid LNs in the lateral neck, mediastinal, and clavicular region simultaneously. Furthermore, one patient had ^{99m}Tc-pertechnetate-avid LNs in both the lateral neck and mediastinal region (**Table 2**).

The presence of ^{99m}Tc-pertechnetate-avid LNMs influenced the treatment plan for 38 patients. Among them, 17 patients, with a total of 26 ^{99m}Tc-pertechnetate-avid LNs, underwent a second neck LN dissection. Postoperative pathology confirmed the metastatic nature of all these ^{99m}Tc-pertechnetate-avid LNs. In 21 patients, the RAI activity was increased during subsequent treatments (**Table 2**). Following treatment, an Rx-WBS combined with SPECT/CT revealed that the ^{99m}Tc-pertechnetate-avid LNMs exhibited a higher concentration of ^{131}I.

Despite surgical intervention, four patients still had residual iodine-avid LNMs after a second operation. These included two patients with three LNMs in the mediastinum and one in the retropharyngeal space, which was challenging to access during surgery. Additionally, two other patients had positive LNs in the supraclavicular region that had been overlooked by CT and ultrasound examinations before reoperation. The preoperative evaluation did not consider the positive results of the ^{99m}Tc-pertechnetate scan, resulting in residual LNMs after dissection (**Figure 1**). The concentration of iodine in the post-

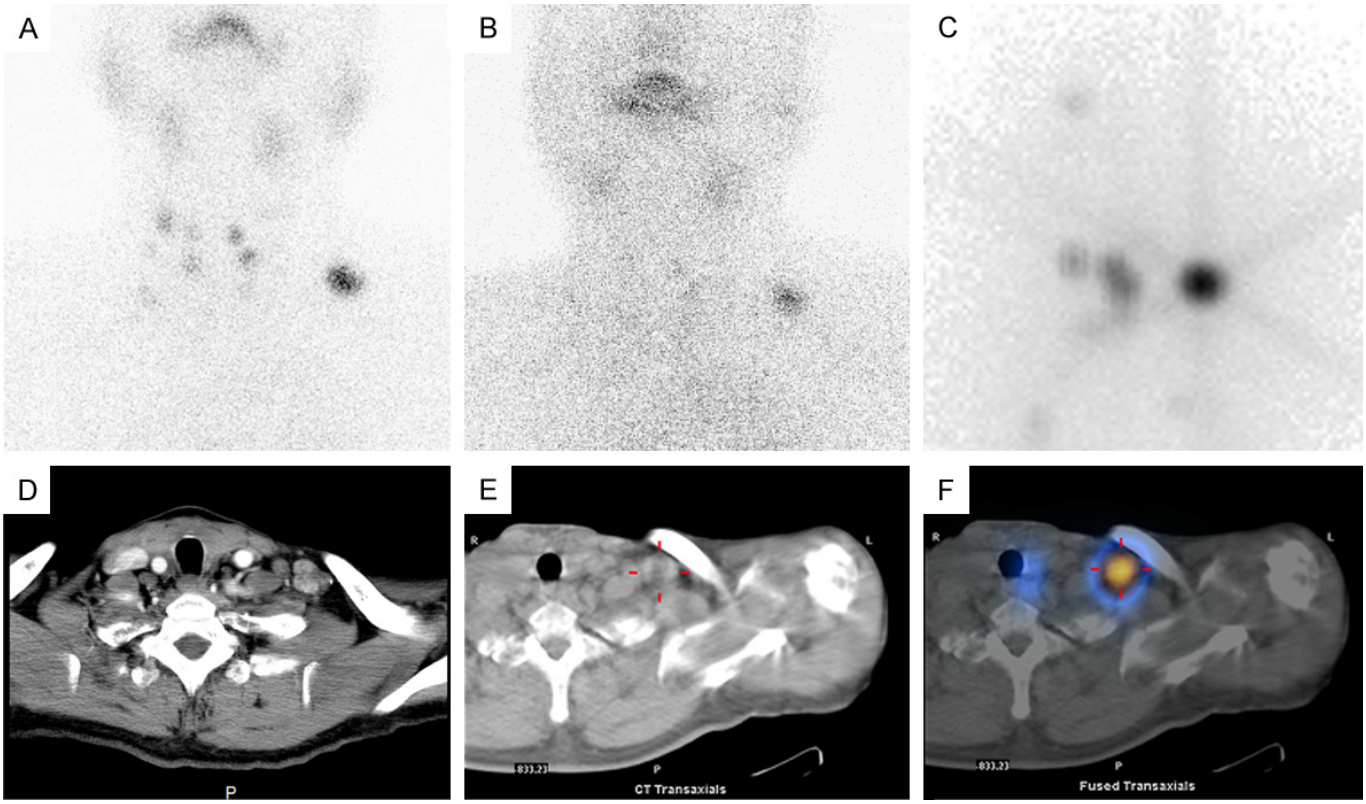

Figure 1. ^{131}I-avid-supraclavicular LNM accumulating ^{99m}Tc-pertechnetate. A 63-year-old male patient with PTC presented with suspected LNM two months after total thyroidectomy with ssTg of 233.20 ng/mL and TSH of 120.80 mU/L. The first ^{99m}Tc-pertechnetate imaging showed residual thyroid tissue and bilateral cervical LNM (A) with surgical indication, and the patient was then gone back to surgery for cervical dissection. But only right cervical lymph node dissection was performed, for the left supraclavicular LNM was missed diagnosis by CT (D) and ultrasound. Thus, the second ^{99m}Tc-pertechnetate scan showed the LNM remaining visible (B). ^{131}I planar image (C) and SPECT/CT (E, F) 5 days after the initial administration of 5.5 MBq (150 mCi) ^{131}I correspondingly showed the residual thyroid tissue and supraclavicular LNM with increased ^{131}I accumulation.

therapeutic radioiodine Rx-WBS reveals a more pronounced localization in LNMs compared to the ^{99m}Tc-pertechnetate imaging. The latter often exhibits a mild to moderate ^{99m}Tc-pertechnetate uptake (**Figure 2**).

After matching, the two groups achieved balance in age, with no statistically significant difference ($p > 0.05$, SMD value < 10%). Additionally, the balance of other indicators without statistically significant difference was significantly improved (**Table 3**).

Among the 363 patients successfully matched, 48 in the ^{99m}Tc-pertechnetate-avid group and 158 in the ^{99m}Tc-pertechnetate-non-avid group underwent more than two RAI treatments. The median age for the ^{99m}Tc-pertechnetate-avid group was 42.00 (35.50-52.00) years, and for the ^{99m}Tc-pertechnetate-non-avid group, it was 47.00 (36.00-55.00) years, with no significant difference after the match (p=0.320). Regarding gender, there were 19 females (39.6%) in the ^{99m}Tc-pertechnetate-avid group compared to 92 females (58.2%) in the non-avid group, indicating a significant difference between the two groups (p=0.035). There were no missing data in these variables. After PSM, the median value of RAI treatment frequency and ^{131}I activity for both groups were similar, with no significant differences (p=0.677 and p=0.649, respectively). Additionally, no significant differences were found between the two groups in terms of sstg1, sstg2, thyroid cancer subtype, TSH, metastatic site, distant metastasis status, follow-up time, AJCC TNM stage, or clinical outcomes. However, there was a significant difference in gender, nsTg level, and the percentage changes in ssTg between the two groups (p=0.035, p=0.018 and $p < 0.001$, respectively).

The initial ssTg (ssTg1) levels before the first RAI treatment in ^{99m}Tc-pertechnetate-avid group (n=48) and ^{99m}Tc-pertechnetate-nonavid group (n=158) were 36.44 (7.80-95.47) ng/mL and 29.12 (5.50-141.20) ng/mL respectively with no significant differences observed (p=0.759). While ssTg level before the second RAI treatment (ssTg2) in the ^{99m}Tc-pertechnetate-avid group and ^{99m}Tc-pertechnetate-non-avid group were 5.00 (0.25-23.87) ng/mL and 9.10 (1.04-59.70) ng/mL, respectively. The percentage of changes in ssTg between the ^{99m}Tc-pertechnetate-avid and ^{99m}Tc-pertechnetate-non-avid groups was statistically significant [-88% (-98%, -50%) vs. -66% (-86%, -30%), $p < 0.001$]. Similarly, there was a significant difference in nsTg [0.05 (0.04 to 0.90) vs. 0.40 (0.04 to 4.92), p=0.018] between the two groups (**Table 4**).

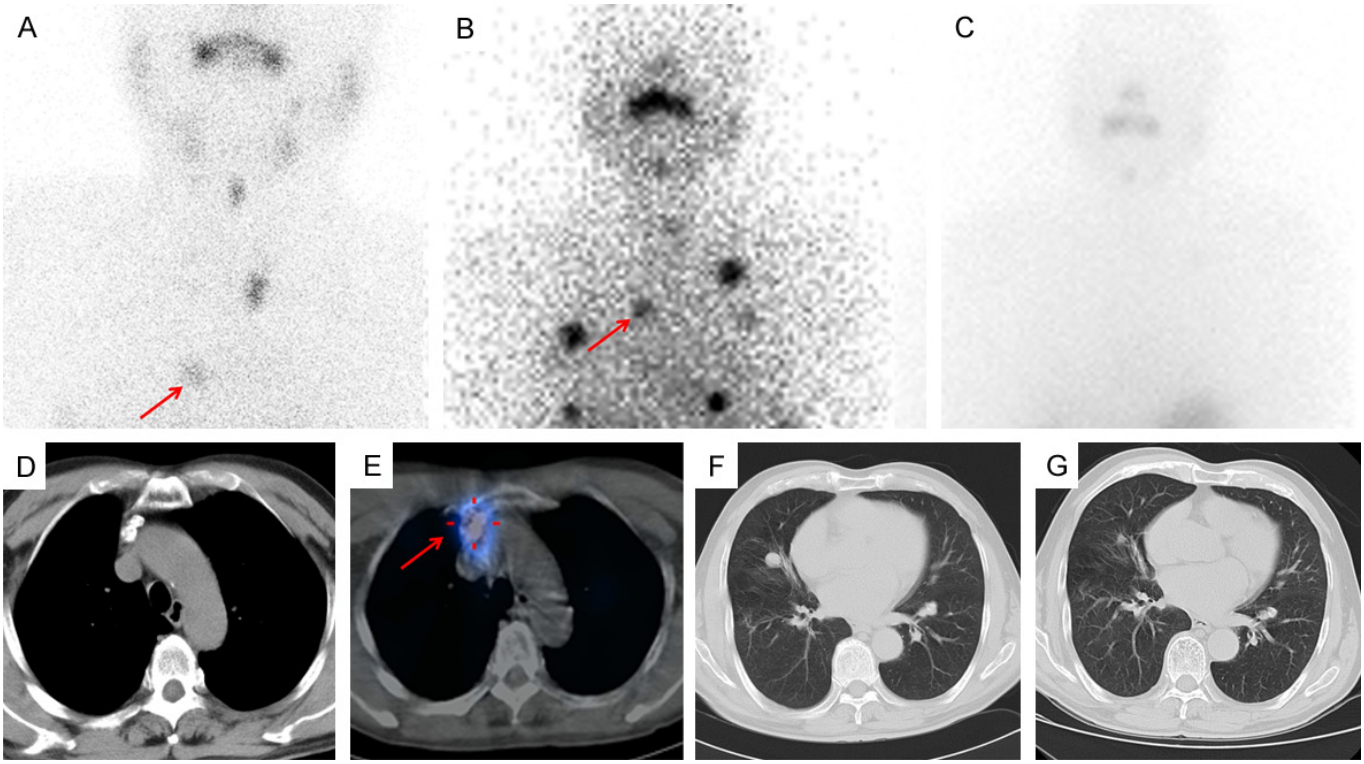

Figure 2. ^{131}I-avid mediastinum LNM accumulating ^{99m}Tc-pertechnetate. A 70-year-old male with PTC presented with suspicious lung metastatic two months after total thyroidectomy with elevated ssTg of 77.65 ng/mL and TSH of 43.60 mU/L. ^{99m}Tc-pertechnetate scan (A) and CT image (D) before the initial administration of 7.4 MBq (200 mCi) ^{131}I followed by Rx-WBS (B) and ^{131}I-SPECT/CT (E) showed radiotracer-avid calcified LNs in the superior mediastinum (red arrow). ssTg decreased to 1.80 ng/mL with TSH of 67.63 mU/L just before the third course of ^{131}I therapy. Disappeared uptake of ^{131}I in LNs in the neck, lung and superior mediastinum was revealed by the third ^{131}I scan (C) and CT revealed the lung metastatic lesion shrank after RAI (F, G). And the patient's nsTg remained at a low level (0.05 ng/mL) during 4 years' follow-up.

Table 3. Comparison of age, treatment frequency, and initial ^{131}I treatment activity before and after matching between the ^{99m}Tc-pertechnetate-avid and ^{99m}Tc-pertechnetate-non-avid groups

Characteristics	Before Matching			After Matching		
	^{99m}Tc-pertechnetate-non-avid group (n=664)	^{99m}Tc-pertechnetate-avid group (n=88)	SMD	^{99m}Tc-pertechnetate-non-avid group (280)	^{99m}Tc-pertechnetate-avid group (n=83)	SMD
Age	50.09±13.04	43.73±13.90	-0.458	46.55±12.83	44.23±13.49	-0.024
RAI treatment frequency	1.90±1.10	1.95±1.13	0.046	1.90±1.04	1.95±1.13	0.042
^{131}I Activity	115.11±27.89	120.45±30.73	0.174	116.43±28.70	117.47±28.41	-0.067

Data are shown as means ± standard deviations.

During the follow-up with a median duration of 27 (5.00-52.00) months for the ^{99m}Tc-pertechnetate-avid group and 30 (6.00-59.50) months for the ^{99m}Tc-pertechnetate-non-avid group ($p > 0.05$), the proportion of ER, IDR, BIR, and SIR in ^{99m}Tc-pertechnetate-avid group were 62.50% (30/48), 10.42% (5/48), 16.67% (8/48), and 10.42% (5/48), respectively. In the ^{99m}Tc-pertechnetate-nonavid group, 11 cases of patients were lost to follow-up. Among the remaining patients, 40.81% (60/147), 19.04% (28/147), 22.44% (33/147), 17.68% (26/147) were categorized into ER, IDR, BIR, and SIR, respectively. The difference in therapeutic response between ^{99m}Tc-pertechnetate-avid group and ^{99m}Tc-pertechnetate-nonavid group was not statistically significant (x^2=7.06; p=0.07). Nor was the difference in follow-up time between the two groups (p=0.470) (**Table 4**).

Discussion

The occurrence of LNM in DTC is notably high, constituting a significant risk factor for the recurrence of DTC and diminished overall survival [2, 3]. Hence, the identification of LNMs subsequent to DTC surgery holds paramount significance for patients' prognosis and treatment considerations. ^{99m}Tc-pertechnetate imaging is extensively employed for evaluating residual thyroid both pre- and post- RAI treatment [8, 9]. This phenomenon can be elucidated by the homologous nature of technetium and iodine; possessing comparable physical and chemical

Table 4. Comparison between the ^{99m}Tc-pertechnetate-avid and ^{99m}Tc-pertechnetate-non-avid groups who received two or more ^{131}I treatments after matching

Characteristics	^{99m}Tc-pertechnetate-avid (n=48)	^{99m}Tc-pertechnetate-non-avid (n=158)	*p*
Age	42.00 (35.50-52.00)	47.00 (36.00-55.00)	0.320
Gender			0.035
Female	19 (39.6%)	92 (58.2%)	
Male	29 (60.4%)	66 (41.8%)	
RAI treatment frequency	2.00 (2.00 to 3.00)	2.00 (2.00 to 3.00)	0.677
^{131}I activity (mCi)	100.00 (100.00-150.00)	100.00 (100.00-150.00)	0.649
ssTg1 (ng/ml)	36.44 (7.80-95.47)	29.12 (5.50-141.20)	0.759
ssTg2 (ng/ml)	5.00 (0.25-23.87)	9.10 (1.04-59.70)	0.126
Percentage changes in ssTg	-88% (-98%--50%)	-66% (-86%--30%)	< 0.001
Pathological type			0.657
PTC	47 (97.9%)	155 (98.1%)	
FTC	1 (2.1%)	2 (1.3%)	
FTC+PTC	0	1 (0.6%)	
TSH (mIU/L)	72.94 (52.98-105.96)	86.71 (61.44-115.29)	0.143
Metastatic site			0.193
LN	29 (60.4%)	114 (72.2%)	
LN and lung	18 (37.5%)	38 (24.1%)	
Others	1 (2.1%)	6 (3.8%)	
Distant metastasis			-0.172
M0	29 (60.4%)	114 (72.2%)	
M1	19 (39.6%)	44 (27.8%)	
nsTg (ng/ml)	0.05 (0.04 to 0.90)	0.40 (0.04 to 4.92)	0.018
Follow-up time (months)	27.00 (5.00-52.00)	30.00 (6.00-59.50)	0.470
Tumor staging			0.109
I	21 (43.8%)	94 (59.5%)	
II	21 (43.8%)	54 (34.2%)	
III	1 (2.1%)	4 (2.5%)	
IV	5 (10.4%)	6 (3.8%)	
Clinical outcome			0.070
ER	30 (62.5%)	60 (40.8%)	
IDR	5 (10.4%)	28 (19.0%)	
BIR	8 (16.7%)	33 (22.4%)	
SIR	5 (10.4%)	26 (17.7%)	

properties, they both function as monovalent anions that can accumulate through the sodium iodide symporter (Na+/I-symporter) situated in the membrane of thyroid cells, facilitating imaging [19]. Once ^{99m}Tc-pertechnetate enters thyroid cells, it is unable to partake in further thyroid hormone synthesis (with faster elution). As a result, metastases from differentiated thyroid cancer (DTC) typically do not exhibit uptake of ^{99m}Tc-pertechnetate [20].

In clinical practice, unexpected findings of ^{99m}Tc-pertechnetate-avid DTC metastatic lesions is an infrequent phenomenon, with such instances documented in only a limited number of case reports [1, 21, 22].

Owing to the low frequency of ^{99m}Tc-pertechnetate-avid LNs, only a limited number of studies have undertaken the analysis of the diagnostic significance of ^{99m}Tc-pertechnetate avidity in patients with DTC [16-18]. These studies have indicated that ^{99m}Tc-pertechnetate scanning exhibits low sensitivity in identifying metastatic lesions in DTC. However, its positive predictive value in detecting DTC metastatic lesions is high, and its predictive significance for the efficacy of RAI therapy has not been comprehensively assessed.

The current findings reveal that the majority of cases with ^{99m}Tc-pertechnetate-avid metastases predominantly involve lymph node, lung, and bone metastases, with lymph node metastases being particularly prevalent. However, the underlying mechanism remains unclear. Theoretically, the visualization of DTC metastatic lesions on a ^{99m}Tc-pertechnetate scan may signify a heightened activity of the sodium iodide symporter, demonstrating a robust ability to concentrate ^{99m}Tc-pertechnetate for imaging. Conversely, these lesions may also exhibit enhanced con-

centration of ^{131}I, resulting in a higher radiation dose, and patients with such avid lesions may be expected to respond more favorably to radioiodine therapy compared to those with ^{99m}Tc-pertechnetate-nonavid lesions [23].

The prospective study conducted by Liu et al. [16] reported that patients with DTC and ^{99m}Tc-pertechnetate-avid metastatic foci exhibited a more favorable response to RAI therapy.

Nevertheless, due to the scarcity of cases and the relative difficulty in collecting and comparing them, only the prospective case-control study by Liu et al. [16] confirmed that patients with ^{99m}Tc-pertechnetate-avid DTC metastases could benefit from RAI treatment. Considering the small number of patients in their study (13 patients with ^{99m}Tc-pertechnetate-avid LNs and two or more RAI treatments), their conclusions were relatively weak. Despite its retrospective nature, the present study encompassed a larger patient cohort and substantiated the observation that individuals with ^{99m}Tc-pertechnetate-avid lymph node metastases (LNMs) demonstrated a more favorable response to treatment. While a comparison with the findings of Liu et al. [16] reveals a relatively lesser reduction in stimulated serum thyroglobulin (ssTg) levels after the second RAI treatment in the present study and no statistically significant divergence in clinical outcomes, the primary outcomes still align with and lend support to the conclusions drawn in their research.

In the present study, we observed that the initial ssTg of the ^{99m}Tc-pertechnetate-avid group were higher than those in the ^{99m}Tc-pertechnetate-nonavid group. Additionally, the reduction in ssTg following the initial iodine treatment was more pronounced in the ^{99m}Tc-pertechnetate-avid group compared to the ^{99m}Tc-pertechnetate-non-avid group. These findings suggest that LNMs displaying ^{99m}Tc-pertechnetate avidity may exhibit a better-differentiated state, rendering them more responsive to iodine therapy. However, the baseline characteristics of the two groups exhibited differences, with a higher number of distant metastasis cases in the ^{99m}Tc-pertechnetate-avid group (n=26, 29.5%) compared to the ^{99m}Tc-pertechnetate-non-avid group (n=116, 17.5%; p=0.01) (**Table 1**). This discrepancy may be attributed to the larger sample size of ^{99m}Tc-pertechnetate-non-avid group, and potential poorly differentiated cases in ^{99m}Tc-pertechnetate-non-avid group were not detected in the Rx-WBS with ^{131}I-SPECT/CT. Following PSM matching, the distribution of age, ssTg1 and distant metastatic cases between the two groups was harmonized. The results suggested that patients with ^{99m}Tc-pertechnetate-avid LNMs were more likely to derive benefit from RAI therapy compared to those with ^{99m}Tc-pertechnetate-non-avid LNMs.

This study reveals that the unexpected detection of ^{99m}Tc-pertechnetate-avid LNMs would have influenced the treatment decisions in 38/970 (3.9%) patients. These alterations included a shift towards repeating neck dissection surgery (n=17) or escalating the ^{131}I activity in RAI treatment (n=21). Notably, this rate is comparatively lower than the 11% reported by Liu et al. [16]. Discrepancies in these figures may stem from variations in patient characteristics and the retrospective/prospective design of the respective studies.

Furthermore, the present study revealed that the proportion of male patients with ^{99m}Tc-pertechnetate-avid LNMs was abnormally high, constituting for 56.8% (54/95), in contrast to the 36.1% observed in male patients with ^{99m}Tc-pertechnetate-non-avid lesions indicating a statistically significant difference. This finding deviates from the outcomes reported by Liu et al. [16]. The discrepancy may be attributed to the relatively small sample size (n=13; women =7, men =6) [16]. Additionally, DTC is more prevalent in women than in men [24], implying potential variations in the biology and natural progression of ^{99m}Tc-pertechnetate-avid DTC compared to ^{99m}Tc-pertechnetate-non-avid DTC. Furthermore, the impact of gender on the recurrence risk of DTC remains a subject of controversy [25-28], yet discernible gender differences in the incidence rate, invasiveness, and prognosis of thyroid cancer [29].

Hei et al. [30] reported that male patients with ^{99m}Tc-pertechnetate-avid have a higher risk of extra-glandular invasion compared to their female counterparts. Park et al. [25] presented findings indicating a higher incidence and number of LNMs and an increased occurrence of vascular invasion in men compared to women. Nevertheless, it is noteworthy that in the aforementioned studies, the proportion of male patients was significantly lower compared with female patients. Hence, the observed gender discrepancy observed in the present study remains unexplained. Firstly, the patient cohort originated from a single center, and the study period was confined, resulting in a relatively small sample size. Additionally, the outcomes may have been influenced by local practices and the expertise of the nuclear medicine physicians involved. The imaging protocol was restricted to local ^{99m}Tc-pertechnetate planar scans of the neck and chest, precluding the assessment of distant metastases beyond the scanning range.

This study has several limitations. Firstly, the patient cohort originated from a single center, and the study period was confined, resulting in a relatively small sample size. Additionally, the outcomes may have been influenced by local practices and the expertise of the nuclear medicine physicians involved. The imaging protocol was restricted to local ^{99m}Tc-pertechnetate planar scans of the neck and chest, precluding the assessment of distant metastases beyond the scanning range. In conclusion, patients with ^{99m}Tc-pertechnetate-avid LNMs demonstrated a greater likelihood of deriving benefits from RAI therapy, even following adjustment for age, frequency of

RAI treatment, and the initial activity of ^{131}I in the RAI treatment.

In summary, individuals with ^{99m}Tc-pertechnetate-avid LNMs demonstrated a greater likelihood of deriving benefits from RAI therapy, even following adjustments for age, frequency of RAI treatment, and the initial dose of ^{131}I in the RAI treatment.

Acknowledgements

The authors acknowledge the help of all the participants and staff (especially Ms. Jingjing Wang) from Zhejiang Cancer Hospital, China. This article was supported by the National Natural Science Foundation of China (No. 81903982), the Zhejiang Province Traditional Chinese Medicine Science and Technology Project (No. 2023ZL297) and the Medical Health Science and Technology Project of Zhejiang Province (No. 2022PY043).

Disclosure of conflict of interest

None.

Abbreviations

^{131}I, radioiodine-131; BIR, biochemical incomplete response; DTC, differentiated thyroid cancer; ER, excellent response; IDR, indeterminate response; L-T4, levothyroxine; LN, lymph node; nsTg, non-stimulated thyroglobulin; RAI, radioactive iodine; Rx-WBS, radioiodine whole-body scan; SIR, structural incomplete response; SPECT/CT, single photon emission computed tomography/computed tomography; ssTg, stimulated serum thyroglobulin; TSH, thyroid-stimulating hormone.

Address correspondence to: Dr. Heqing Yi, Department of Nuclear Medicine, Zhejiang Cancer Hospital, Hangzhou 310022, Zhejiang, China. Tel: +86-18257152796; E-mail: yiheqing1980@163.com; yihq@zjcc.org.cn; Dr. Hu Cai, Department of Integration of Western and Traditional Chinese Medicine, Zhejiang Cancer Hospital, Hangzhou 310022, Zhejiang, China. Tel: +86-15958164109; E-mail: slch007@163.com

References

[1] Sung H, Ferlay J, Siegel RL, Laversanne M, Soerjomataram I, Jemal A and Bray F. Global cancer statistics 2020: GLOBOCAN estimates of incidence and mortality worldwide for 36 cancers in 185 countries. CA Cancer J Clin 2021; 71: 209-249.

[2] Lim H, Devesa SS, Sosa JA, Check D and Kitahara CM. Trends in thyroid cancer incidence and mortality in the United States, 1974-2013. JAMA 2017; 317: 1338-1348.

[3] Powers AE, Marcadis AR, Lee M, Morris LGT and Marti JL. Changes in trends in thyroid cancer incidence in the United States, 1992 to 2016. JAMA 2019; 322: 2440-2441.

[4] Abdullah MI, Junit SM, Ng KL, Jayapalan JJ, Karikalan B and Hashim OH. Papillary thyroid cancer: genetic alterations and molecular biomarker investigations. Int J Med Sci 2019; 16: 450-460.

[5] McLeod DSA, Zhang L, Durante C and Cooper DS. Contemporary debates in adult papillary thyroid cancer management. Endocr Rev 2019; 40: 1481-1499.

[6] Haugen BR, Alexander EK, Bible KC, Doherty GM, Mandel SJ, Nikiforov YE, Pacini F, Randolph GW, Sawka AM, Schlumberger M, Schuff KG, Sherman SI, Sosa JA, Steward DL, Tuttle RM and Wartofsky L. 2015 American Thyroid Association management guidelines for adult patients with thyroid nodules and differentiated thyroid cancer: the American Thyroid Association Guidelines Task Force on thyroid nodules and differentiated thyroid cancer. Thyroid 2016; 26: 1-133.

[7] Ozdemir D, Cuhaci FN, Ozdemir E, Aydin C, Ersoy R, Turkolmez S and Cakir B. The role of postoperative Tc-99m pertechnetate scintigraphy in estimation of remnant mass and prediction of successful ablation in patients with differentiated thyroid cancer. Nucl Med Commun 2016; 37: 640-645.

[8] Giovanella L, Paone G, Ruberto T, Ceriani L and Trimboli P. (99m)Tc-pertechnetate scintigraphy predicts successful postoperative ablation in differentiated thyroid carcinoma patients treated with low radioiodine activities. Endocrinol Metab (Seoul) 2019; 34: 63-69.

[9] Lan W, Gege Z, Ningning L, Qiang W, Lin B, Qingjie M and Bin J. Negative remnant (99m)Tc-pertechnetate uptake predicts excellent response to radioactive iodine therapy in low- to intermediate-risk differentiated thyroid cancer patients who have undergone total thyroidectomy. Ann Nucl Med 2019; 33: 112-118.

[10] Mathiopoulou L, Chrisoulidou A, Boudina M, Mitsakis P, Mandanas S and Pazaitou-Panayiotou K. 99mTc pertechnetate thyroid scan leads to serendipitous detection of metastatic thyroid cancer. Clin Nucl Med 2012; 37: 604-606.

[11] Sundaraiya S, Dizdarevic S, Miles K, Quin J, Williams A, Wheatley T and Zammitt C. Unusual initial manifestation of metastatic follicular carcinoma of the thyroid with thyrotoxicosis diagnosed by technetium Tc 99m pertechnetate scan: case report and review of literature. Endocr Pract 2009; 15: 458-462.

[12] Wang CY, Xiao BR, Shen MJ, Shen Y and Cui KW. (99m) TcO(4)(-) scintigraphic detection of follicular thyroid cancer and multiple metastatic lesions: a case report. Oncol Lett 2013; 6: 1729-1732.

[13] Yamamoto Y, Nishiyama Y, Ono Y, Satoh K, Ohkawa M, Kawasaki Y and Tanabe M. Accumulation of technetium-99m pertechnetate in a patient with metastases of thyroid carcinoma. Ann Nucl Med 1999; 13: 357-359.

[14] Campenni A, Ruggeri RM, Santoro D, Cucinotta M, Conti S, Sindoni A, Bellinghieri G and Baldari S. Accidental discovery of lung metastases from differentiated thyroid cancer by 99mTc sodium pertechnetate scan in a patient with secondary hyperparathyroidism. Clin Nucl Med 2012; 37: 895-896.

[15] Khan SU, Khan AU, Khan A, Shah AS and Khan K. Extrathyroidal uptake from thyroid carcinoma on 99mTc-pertechnetate scintigraphy. J Coll Physicians Surg Pak 2011; 21: 772-774.

[16] Liu M, Chai L, Luo Q, Ruan M, Cheng L, Lv Z and Chen L. 99mTc-pertechnetate-avid metastases from differentiated thyroid cancer are prone to benefit from 131I therapy: a prospective observational study. Medicine (Baltimore) 2017; 96: e7631.

[17] Long B, Yao LF, Chen SC, Shui J, Ye XM, Yi HQ and Lou C. Clinical significance of extra-thyroid (99m)Tc-pertechnetate uptake before initial radioiodine therapy for differentiated thyroid carcinoma. J Int Med Res 2021; 49: 3000605211012667.
[18] Lou K, Gu Y, Hu Y, Wang S and Shi H. Technetium-99m-pertechnetate whole-body SPET/CT scan in thyroidectomized differentiated thyroid cancer patients is a useful imaging modality in detecting remnant thyroid tissue, nodal and distant metastases before (131)I therapy. A study of 416 patients. Hell J Nucl Med 2018; 21: 121-124.
[19] Singh N and Lewington V. Molecular radiotheragnostics in thyroid disease. Clin Med (Lond) 2017; 17: 453-457.
[20] Zuckier LS, Dohan O, Li Y, Chang CJ, Carrasco N and Dadachova E. Kinetics of perrhenate uptake and comparative biodistribution of perrhenate, pertechnetate, and iodide by NaI symporter-expressing tissues in vivo. J Nucl Med 2004; 45: 500-507.
[21] Hoberuck S, Michler E, Seppelt D, Kotzerke J and Brogsitter C. Unexpected bone metastases in 99mTc-pertechnetate scan of recurrent goiter. Clin Nucl Med 2019; 44: 72-74.
[22] Shao F, Zhou D and Lan X. Increased 99mTc pertechnetate uptake but unimpressive 131I activity in the metastatic mediastinal lymph nodes in a thyroid cancer patient. Clin Nucl Med 2019; 44: 176-178.
[23] Verma N, Singh-Wadhwa S and Arvela OM. Metastatic thyroid cancer visualized on technetium pertechnetate and iodine-131 scintigraphy. Clin Nucl Med 2002; 27: 610.
[24] Shobab L, Burman KD and Wartofsky L. Sex differences in differentiated thyroid cancer. Thyroid 2022; 32: 224-235.
[25] Park J, Kim K, Lim DJ, Bae JS and Kim JS. Male sex is not an independent risk factor for recurrence of differentiated thyroid cancer: a propensity score-matching study. Sci Rep 2021; 11: 14908.
[26] Zahedi A, Bondaz L, Rajaraman M, Leslie WD, Jefford C, Young JE, Pathak KA, Bureau Y, Rachinsky I, Badreddine M, De Brabandere S, Fong H, Maniakas A and Van Uum S. Risk for thyroid cancer recurrence is higher in men than in women independent of disease stage at presentation. Thyroid 2020; 30: 871-877.
[27] Kim H, Kwon H and Moon BI. Predictors of recurrence in patients with papillary thyroid carcinoma: does male sex matter? Cancers (Basel) 2022; 14: 1896.
[28] Siraj AK, Parvathareddy SK, Annaiyappanaidu P, Siraj N, Al-Sobhi SS, Al-Dayel F and Al-Kuraya KS. Male sex is an independent predictor of recurrence-free survival in middle eastern papillary thyroid carcinoma. Front Endocrinol (Lausanne) 2022; 13: 777345.
[29] Ding J, Wu W, Fang J, Zhao J and Jiang L. Male sex is associated with aggressive behaviour and poor prognosis in Chinese papillary thyroid carcinoma. Sci Rep 2020; 10: 4141.
[30] Hei H, Zhou B, Gong W, Zheng C and Qin J. Male patients with papillary thyroid cancer have a higher risk of extranodal extension. Int J Clin Oncol 2022; 27: 648-654.