

## Original Article

# Efficacy of $^{99m}\text{Tc}$ -EDDA/HYNIC-TOC SPECT/CT scintigraphy in Graves' ophthalmopathy

Rong Zhao<sup>1</sup>, Jiang Wang<sup>2</sup>, Jinglan Deng<sup>3</sup>, Weidong Yang<sup>3</sup>, Jing Wang<sup>3</sup>

<sup>1</sup>Department of Nuclear Medicine, Urumqi General Hospital of Lanzhou Military Region, Urumqi, Xinjiang, 830002, China; <sup>2</sup>Department of General Surgery, Urumqi General Hospital of Lanzhou Military Region, Urumqi, Xinjiang, 830002, China; <sup>3</sup>Department of Nuclear Medicine, Xijing Hospital, Fourth Military Medical University, Xi'an, Shaanxi, 710032, China

Received March 5, 2012; accepted March 19, 2012; Epub March 28, 2012; Published April 15, 2012

**Abstract:** The aim of this study was to investigate the predictive role of the orbital somatostatin receptor scintigraphy with  $^{99m}\text{Tc}$ -EDDA/HYNIC-TOC ( $^{99m}\text{Tc}$ -TOC) to detect clinical stage of Graves' ophthalmopathy and the response to corticosteroid therapy. The subjects of the experiment were 46 patients with Graves' ophthalmopathy (GO) and four volunteers without eye disease or GO as the normal group (NG). Single photon emission computed tomography (SPECT), computed tomography (CT) and the left and right lateral position planar imaging of the heads of the all subjects were obtained 4 h after the intravenous injection of 555 MBq of  $^{99m}\text{Tc}$ -TOC. The  $^{99m}\text{Tc}$ -TOC SPECT/CT was repeated 3 months later. 35 (35/46) patients were received corticosteroid therapy (prednisolone, 10 mg po tid ) for 3 months, however, the other 11 patients as control groups did not receive any treatment. The treatment effect was evaluated both by the orbital  $^{99m}\text{Tc}$ -TOC uptake and NOSPECS. A significant decrease in the O/OC ratio was observed in 22 GO patients between pre- and post-treatment ( $1.64 \pm 0.13$  vs.  $1.21 \pm 0.09$ ,  $P < 0.05$ ). There were neither significant difference of the O/OC ratio in 13 GO patients between pre- and post-treatment periods, nor significant difference in the 9 (9/11) patients before and after three months. Orbital  $^{99m}\text{Tc}$ -TOC scintigraphy is a feasible technique to estimate the Graves' ophthalmopathy activity and predict the response to subsequent corticosteroid therapy in GO patients. The technique could be a useful tool for physicians not familiar with CAS determination.

**Keywords:** Graves' ophthalmopathy, single photon emission computed tomography (SPECT), somatostatin receptor,  $^{99m}\text{Tc}$ -TOC

## Introduction

Graves' ophthalmopathy (GO), one of the most frequent complications of Graves' disease [1], is characterized by eye proptosis caused by enlargement of the extraocular muscles, augmentation of retrobulbar fat and orbital soft tissues inflammation. In the early stage of the disease (active GO), the retrobulbar infiltration is characterized by lymphocytes and interstitial edema, whereas in later stage (inactive GO), fatty infiltration and fibrosis occur [2]. The treatment of GO varies from immunosuppressive to surgical therapy. Immunosuppression therapy is beneficial only in the early active stage, whereas surgery is more effective in the stable late stage of the disease. Thus, the clinical definition of ophthalmopathy activity at the initial presentation is crucial to the identification of the right

therapeutic approach. Several methods to evaluate disease activity have been proposed; none has yet become generally accepted for routine use in clinical practice [3-5].

A study demonstrated that somatostatin (SST) and its receptor genes are expressed on primary fibroblast cultures from retro-orbital tissues of GO patients [6]. Furthermore, somatostatin receptor scintigraphy (SRS) has been shown able to reveal the presence of activated lymphocytes in inflammatory foci of several autoimmune diseases [7]. Orbital uptake of  $^{111}\text{In}$ -octreotide in GO patients detected by scintigraphy is a sensitive method to estimate immunologic disease activity [8, 9].  $^{111}\text{In}$  is rather expensive and must be ordered a day or two ahead of scheduled procedure, on the other hand, generator produced  $^{99m}\text{Tc}$  is considerably less expensive than

the cyclotron produced <sup>111</sup>In and possesses physical characteristics ( $t_{1/2}$ : 6h;  $\gamma$ -140: 91%) that are highly suitable for scintigraphic imaging.

The scintigraphy with <sup>99m</sup>Tc-HYNIC-Octreotide (<sup>99m</sup>Tc-TOC) has been used to visualize somatostatin receptor-expressing tumors, such as medullary thyroid carcinoma, pulmonary nodules, carcinoid syndrome, pancreatic cancer, and pituitary tumor [10-12]. We herein report a longitudinal and follow-up of Graves' orbital <sup>99m</sup>Tc-TOC scans in patients with GO before and after steroid treatment. The aim of the current study was to evaluate the potential role of orbital <sup>99m</sup>Tc-TOC uptake in predicting the response to corticosteroid therapy in patients with Graves' ophthalmopathy.

## Materials and methods

### Subjects

46 patients (17 males and 29 females; aged 21–55 yr; mean 38 yr) with moderately to severe Graves' ophthalmopathy were recruited. All patients were 2c class according to the NOSPECS classification [13, 14]. They were all in euthyroid status (twenty-three not taking medication, eleven receiving methimazole therapy, twelve taking L-T<sub>4</sub> supplementation for hypothyroidism) for at least 3 months, and did not receive immunosuppressive therapy, orbital surgery, orbital radiotherapy, or somatostatin analogs treatment within the previous year. Before entering the study, diabetes mellitus was excluded by a standard oral glucose tolerance test (75 g p.o.) and gastric lesions were excluded by hemocult analysis. General clinical conditions and blood glucose were carefully monitored throughout the treatment in all patients. Four volunteers without eye disease or Graves' disease were included as normal groups (NG). Informed consents were obtained from GO patients and control subjects and the study was approved by the Ethics Committee of Xijing Hospital, the forth military medical university.

To evaluate the response of therapy, <sup>99m</sup>Tc-TOC SPECT/CT was performed on two occasions for each case. First, it was performed in the beginning of this study. A second scintigraphy was performed 3 months later. In all 46 patients, 35 patients were administrated prednisolone (10mg, po, tid for 3 months), 11 patients in con-

trol group were not gained any treatment. In addition, A clinical activity score (CAS) [4] was employed to assess the activity of the ophthalmopathy for all 46 patients before and after 3 months. Progression or improvement of ophthalmopathy was assessed by changes in at least two major criteria (variations in proptosis and lid width of 2 mm or greater, the presence or absence of diplopia).

### Methods

Hydrazinonicotinyl-Tyr<sup>3</sup>-octreotide (HYNIC-TOC) was purchased from a commercially available kit (GL Biochem Ltd, Shanghai, China). <sup>99m</sup>Tc-pertechnetate was obtained from a commercial <sup>99</sup>Mo/<sup>99m</sup>Tc generator (Gao Tong Isotope Corporation, Chengdu, China). <sup>99m</sup>Tc-HYNIC-TOC was synthesized as previously described [15]. Quality controls were performed on labeled peptide before the injection. More than 95% of the radioactivity was peptide bound in injectable preparations.

Planar and SPECT/CT images of head were acquired using a double-head camera (GE, hawk-eye VG5.0, USA). The camera was equipped with high-resolution, lower-energy collimators, window setting at 140 keV, width at 10%. SPECT images were acquired using a 128×128 pixel matrices, zoom 1, multiple views over 180° at 40s per view with an angle of 3° per step. All patients were imaged at 4 h after intravenous injection of 555 MBq <sup>99m</sup>Tc-TOC. Fusion image of the SPECT and diagnostic CT scans were sequentially performed.

Orbital images were quantified by region of interest (ROI) analysis. Semi-quantitative evaluation of retrobulbar uptake was performed with irregular ROIs which were placed over the orbits (O) and the reference area over the occipital area (OC). Irregular ROIs were manually drawn in SPECT reconstruction by the same and experienced observer, who was blind to all patients. The O/OC ratio was calculated by dividing the counts of the orbit by those of the occipital ROIs.

### Statistical analysis

All values were expressed as mean ± sem. Comparisons between values before and after therapy were made using two-sided, two-sample *t*-test or Mann-Whitney U-test. Correlations

**Table 1.** Proptosis, lid aperture, orbit-to-occipital (O/OC) ratio and CAS in 22 GO patients before and after prednisolone treatment.

	prednisolone treatment		p
	Before	After	
<sup>99m</sup> Tc-TOC O/OC Ratio 4 h postinjection (n=22)	1.6 (1.4-1.8)	1.2 (1.05-1.3)	0.004
Proptosis (n=22; mm)	22 (18-24)	19 (15-22)	0.01
Lid aperture (n=22; mm)	12 (10-14)	10 (7-11)	0.01
CAS	4.3±0.7	3.1±0.8	0.03

**Table 2.** Base-line characteristics of all patients with Graves' ophthalmopathy.

characteristics	responders (n=22)	non-responders (n=13)	control patients (n=11)
Sex			
Male	7	4	3
Female	15	9	8
Age (yr)			
Mean	34	33	31
Range	15-55	16-63	17-49
Range of duration of thyroid disease (month)	3-15	5-14	4-13
Mean thyroid volume (ml)	29	33	32
Proptosis (mm)	22±2	22±1	22±2
Lid width (mm)	12±1	12±2	12±2
Serum TSH receptor antibody (U/liter)	45±69	48±56	47±61

among various parameters were calculated using Spearman's test. The two-sample Wilcoxon test was applied to compare the values of both patients and controls. *P* values of less than 0.05 were considered to be statistically significant.

### Results

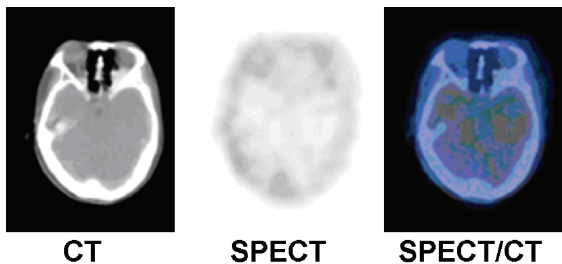
In 22 of 35 (63%) patients with Graves' ophthalmopathy, a response to prednisolone was observed after 3mo of follow up period. Responders to treatment showed improvement in proptosis (median from 22, ranging 18-24 to 19 mm, ranging 15-22, *P* < 0.05), lid aperture (median from 12, ranging 10-14 vs. to 10 mm, ranging 7-11, *P* < 0.05), respectively (Table 1). For 13 patients with GO, no response to prednisolone was observed. For 11 control patients, 2 patients showed improvement in proptosis and lid aperture (*P* < 0.05), however, the other 9 patients have not any changes (*P* > 0.05). No significant differences were found in baseline characteristics (e.g., age, gender, duration of eye or thyroid disease, thyroid volume, Proptosis, Lid

width and Serum TSH receptor antibody) for all 46 patients (Table 2). However, the average CAS in responder group was significantly higher than that in non-responders (*P* < 0.05). As well as, there was statistic difference of the CAS between 9 and 2 patients in the 11 patients of control groups 3 months later.

In the normal group, there was no obvious uptake of <sup>99m</sup>Tc-TOC in the orbital area (O/OC ratio 1.16±0.04) (Figure 1). Before prednisolone, the uptake of <sup>99m</sup>Tc-TOC was significantly higher in 22 patients (O/OC ratio 1.64±0.13) than in 13 patients (O/OC ratio 1.15±0.06) and in 4 normal groups (*P* < 0.05). A significant decrease of O/OC ratio was observed between pretreatment and post-treatment in 22 patients (1.64±0.13 vs. 1.21±0.09, *P* < 0.05). The O/OC ratio after steroid treatment of the responders group is similar to that of the CG (1.16±0.04 vs. 1.21 ± 0.09, *P* > 0.05). No significant change of O/OC ratio was found in 13 patient with GO between pre- and post-treatment *P* < 0.05 (Figure 2). In the 11 patients groups, <sup>99m</sup>Tc-TOC intensively accumulated in the beginning of this study (O/

OC ratio  $1.58 \pm 0.15$ ). Three months later, a significant change of O/OC ratio was found between 9 and 2 ( $1.61 \pm 0.08$  vs.  $1.23 \pm 0.19$ ,  $P < 0.05$ ).

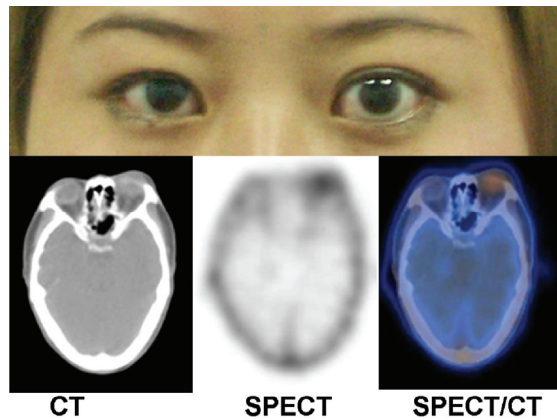
In our study, a significant correlation was observed between O/OC ratio and CAS value ( $r = 0.61$ ,  $P < 0.02$ ). No correlations were found between orbital <sup>99m</sup>Tc-TOC uptake and duration of thyroid disease, or thyroid peroxidase antibody titers. No significant side effects were observed during injecting <sup>99m</sup>Tc-TOC. In addition, the corticosteroid treatment was easily tolerated, except for 2 (2/35) patients who complained of overweight.



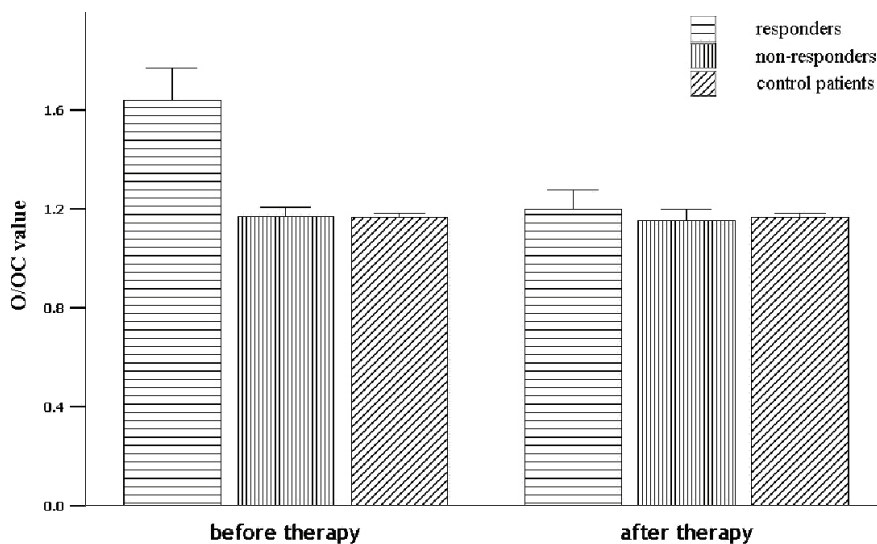
**Figure 1.** Octreotide scan (transversal slices of CT, SPECT and SPECT/CT fusion imaging through the orbit 4 h after intravenous injection of <sup>99m</sup>Tc-EDDA/HYNIC-TOC) of a normal control patient.

**Discussion**

Graves' ophthalmopathy is the most frequent extrathyroidal manifestation of Graves' disease with autoimmune mechanism which is still incompletely understood. The epidemiologic data provided evidence that severe, infiltrative orbitopathy is present in 3-5% of Graves' disease patients, the quality of life of whom is impaired even in individuals with mild form of this disease.



**Figure 3.** The GO patient complained left eye swelling, slightly redness, and diplopia. Octreotide scan (transversal slices of CT, SPECT and SPECT/CT fusion imaging through the orbit 4 h after intravenous injection of <sup>99m</sup>Tc-EDDA/HYNIC-TOC) showed markedly increased <sup>99m</sup>Tc-EDDA/HYNIC-TOC uptake in left orbit compared with right orbit.



**Figure 2.** Orbit-to-Occipital (O/OC) ratio at 4 h after intravenous injection of <sup>99m</sup>Tc-EDDA/HYNIC-TOC in 22 GO patient, 13 GO patient and 4 controls.

Since immunosuppressive therapy would be successful in the early active phase, while surgery is indicated for the end phase of the disease [1, 16]. The definition of the clinical phase of GO in the individual patient is closely correlate to the selection of the most appropriate treatment. Unfortunately, no objectively tested and approved method for disease activity estimation is currently available [3-5]. Of the nuclear medicine techniques, orbital uptake of <sup>111</sup>In-octreotide and other radiopharmaceutical agents have been applied [8, 9, 17]. As shown, <sup>99m</sup>Tc-TOC, a promising new radiopharmaceutical, has also been applied both preclinical and clinical [10-12]. The study performed at our institution using <sup>99m</sup>Tc-TOC showed that SSTR scintigraphy may be a valuable method for staging.

This prospective study demonstrated marked orbital accumulation of <sup>99m</sup>Tc-TOC in 22 GO patients in contrast to 13 GO and 4 controls. In addition, all 22 patients with positive SRS results showed higher activity score and clinical improvement, whereas 13 patients had no improvement after 3 months of treatment. We demonstrated the good correlation of orbital <sup>99m</sup>Tc-TOC scintigraph with CAS, which were reported by Moncayo et al [18]. During the evaluation of orbital disease activity, the disease duration may be considered as a determinant of therapeutic outcome assuming that short disease duration might indicate active disease.

However, using only this data may be insufficient because it was found that a good response to immunosuppression was not correlated with disease duration in our study, which was also reported by earlier study [19]. Additionally, it was to compare between the disease duration of the responders and the nonresponders and controls, and no correlation was detected between the disease duration and orbital <sup>99m</sup>Tc-TOC accumulation.

As we have known, parts of GO is self-limiting, the self-limiting nature of the disease may contribute to their clinical and scintigraphical results, but it may different with individual variation. Our study confirmed that only minority patients (2/11) showed improve (negative SRS and lower CAS), whereas majority patients (9/11) were not obtained clinical improvement (positive SRS and higher CAS). So, we believe that immunosuppressive treatment can provide both clinical and scintigraphical improvement in

selected cases and orbital <sup>99m</sup>Tc-TOC scintigraphy can be used as a disease activity parameter that predicts and monitors the clinical response to immunosuppressive treatment in patients with GO.

In fact, histology is the gold standard for disease activity in GO patients. But it is difficult and invasive to collect the orbit specimen of each GO patient. Gabriel et al. reported that co-registration of SPECT and diagnostic CT using a cost-effective immobilization device provides excellent accuracy for tumor detection of endocrine malignancies and is superior to SPECT and CT alone [20]. The value of our study is to identify the anatomical structures depicted with <sup>99m</sup>Tc-TOC in patients with GO by means of SPECT and CT image fusion analysis. Thus, in the absence of histology, because of a favorable target-to-background ratio and fusion imaging of SPECT/CT in this study, orbital <sup>99m</sup>Tc-TOC fusion imaging is able to determine the pathological phase of Graves' disease, giving a high positive scan in the active early phase and a low positive or negative scan in the stable end phase of the disease. It was also confirmed by the case (**Figure 3**), which showed that scintigraphy images were consistent with the apparent orbit findings of inflammation.

Concerning correlation between SRS score and CAS value, in contrary with our results, no significant correlation was observed by Annamaria Colao et al [21]. Others' studies [9, 18] have been reported similar outcome with ours. The results of the treatment seem to largely depend on time or modality of administration, and time of follow-up. So, further study is needed to elucidate the precise role of <sup>99m</sup>Tc-TOC in the treatment response of GO through adjusting time of administration or follow-up.

In conclusion, The results of the current study demonstrated that orbital <sup>99m</sup>Tc- HYNIC-TOC SPECT/CT scan may be useful as a diagnostic tool for recognizing the early active phase from the late stable phase of the disease and to predict the response to corticosteroid treatment in Graves' ophthalmopathy. In fact, the technique could be also a useful tool for physicians not familiar with CAS determination.

#### Acknowledgments

The authors acknowledge the technical assistance from Drs. Guoquan Li, Xiaoyan Liang, and

Jin Zeng. There are no conflicts of interest in our work.

**Address correspondence to:** Dr. Jing Wang, Department of Nuclear Medicine, Xijing Hospital, Fourth Military Medical University, Xi'an, Shaanxi, 710032, China Tel: +86-18935913632; Fax: +86-0991-4991757; E-mail: zhaorongweiran@yahoo.com.cn

## References

- [1] Jacobson DH, Gorman CA. Endocrine ophthalmopathy: current ideas concerning etiology, pathogenesis and treatment. *Endocr Rev* 1984; 5: 200-220.
- [2] Trokel SL, Jacobiec FA. Correlation of CT scanning and pathological features of ophthalmic Graves disease. *Ophthalmology* 1981; 88: 553-564.
- [3] Bartley GB, Gorman CA. Diagnostic criteria for Graves' ophthalmopathy. *Am J Ophthalmol* 1995; 119: 792-795.
- [4] Mourits MP, Prummel MF, Wiersinga WM, Koornneef L. Clinical activity score as a guide in the management of patients with Graves' ophthalmopathy. *Clin Endocrinol* 1997; 47: 9-14.
- [5] Just M, Kahaly G, Higer HP, Rösler HP, Kutzner J, Beyer J, Thelen M. Graves ophthalmopathy: role of MR imaging in radiation therapy. *Radiology* 1991; 179: 187-190.
- [6] Pasquali D, Notaro A, Bonavolonta' G, Vassallo P, Bonavolonta` A, Sinisi AA. Somatostatin receptor genes are expressed in lymphocytes from retroorbital tissues in Graves' disease. *Endocrinology* 2000; 25: 63-71.
- [7] Van Hagen PM, Krenning EP, Kwekkeboom DJ, Reubi JC, Anker-Lugtenburg PJ, Lowenberg B, Lamberts SW. Somatostatin and the immune and haematopoietic system: A review. *Eur J Clin Invest* 1994; 24: 91-99.
- [8] Pasquali D, Notaro A, Bonavolonta'G, Vassallo P, Bellastella A, Sinisi AA. Somatostatin receptor genes are expressed in lymphocytes from retro-orbital tissues in Graves'disease. *J Clin Endocr Metab* 2002; 87: 5125-5129.
- [9] Kahaly G, Diaz M, Hahn K, Beyer J and Bockisch A. Indium-111-pentetreotide scintigraphy in Graves' ophthalmopathy. *J Nucl Med* 1995; 36: 550-554.
- [10] Parisella M, D'Alessandria C, van de Bossche B, Chianelli M, Ronga G, Papini E, Mikolajczak R, Letizia C, De Toma G, Veneziani A, Scopinaro F, Signore A. <sup>99m</sup>Tc-EDDA/HYNIC-TOC in the management of medullary thyroid carcinoma. *Cancer Biother Radio* 2004; 19: 211-217.
- [11] Płachcińska A, Mikolajczak R, Maecke HR, Michalski A, Rzeszutek K, Kozak J, Kuśmierk J. <sup>99m</sup>Tc-EDDA/HYNIC-TOC scintigraphy in the differential diagnosis of solitary pulmonary nodules. *Eur J Nucl Med Mol Imaging* 2004; 31: 1005-1010.
- [12] Decristoforo C, Mather SJ, Cholewinski W, Donnemiller E, Riccabona G, Moncayo R. C, Mather SJ, Cholewinski W, Donnemiller E, Riccabona G, Moncayo R. Tc-EDDA/HYNIC-TOC: a new <sup>99m</sup>Tc-labelled radiopharmaceutical for imaging somatostatin receptor-positive tumours: first clinical results and intra-patient. *Eur J Nucl Med Mol Imaging* 2000; 27: 1318-1325.
- [13] Werner SC. Modification of the classification of the eye changes of Graves' disease: recommendation of the ad hoc committee of the American Thyroid Association. *J Clin Endocr Metab* 1977; 44: 203-204.
- [14] Prummel MF, Bakker A, Wiersinga WM, Baldeschi L, Mourits MP, Kendall-Taylor P, Perros P, Neoh C, Dickinson AJ, Lazarus JH, Lane CM, Heufelder AE, Kahaly GJ, Pitz S, Orgiazzi J, Hullo A, Pinchera A, Marcocci C, Sartini MS, Rocchi R, Nardi M, Krassas GE, Halkias A. Multi-center study on the characteristics and treatment strategies of patients with Graves' orbitopathy: the first European Group on Graves' Orbitopathy experience. *Eur J Endocrinol* 2003; 148: 491-495.
- [15] Decristoforo C, Melendez-Alafort L, Sosabowski JK, Mather SJ. <sup>99m</sup>Tc-HYNIC-[Tyr3]-octreotide for imaging somatostatin-receptor-positive tumors: preclinical evaluation and comparison with <sup>111</sup>In-octreotide. *J Nucl Med* 2000; 41: 1114-1119.
- [16] Burch HB, Wartofsky L. Graves' ophthalmopathy: current concepts regarding pathogenesis and management. *Endocr Rev* 1993; 14: 747-793.
- [17] Galuska L, Varga J, Szucs-Farkas Z, Burman KD, Nagy EV. Differences in SPET analysis of thyroid-associated orbitopathy. *Eur J Nucl Med Mol Imaging* 2004; 31: 793-795.
- [18] Moncayo R, Baldissera I, Decristoforo C, Kendler D, Donnemiller E. Evaluation of Immunological Mechanisms Mediating Thyroid-Associated Ophthalmopathy by Radionuclide Imaging Using the Somatostatin Analog <sup>111</sup>In-Octreotide. *Thyroid* 1997; 7: 21-29.
- [19] Gerding MN, Prummel MF, Wiersinga WM. Assessment of disease activity in Graves' ophthalmopathy by orbital ultrasonography and clinical parameters. *Clin Endocrinol* 2000; 52: 641-646.
- [20] Gabriel M, Hausler F, Bale R, Moncayo R, Decristoforo C, Kovacs P, Virgolin I. Image fusion analysis of Tc-99m-HYNIC-Tyr(3)-octreotide SPECT and diagnostic CT using an immobilisation device with external markers in patients with endocrine tumours. *Eur J Nucl Med Mol Imaging* 2005; 32: 1440-1451.
- [21] Colao A, Lastoria S, Ferone D, Pivonello R, Paolo EM, Vassallo P, Bonavolonta'G, Muto P, Lombardi G, Fenzi G. Orbital Scintigraphy with [<sup>111</sup>In-Diethylenetriamine Pentaacetic Acid-D-Phe1]-Octreotide Predicts the Clinical Response to Corticosteroid Therapy in Patients with Graves' Ophthalmopathy. *J Clin Endocr Metab* 1998; 83: 3790-3794.