

## Original Article

# The role of PET/CT in decreasing inter-observer variability in treatment planning and evaluation of response for cervical cancer

Ajay Tejwani<sup>1</sup>, Amir Lavaf<sup>1</sup>, Kapila Parikh<sup>1</sup>, Bahaa Mokhtar<sup>1</sup>, Uma Swamy<sup>2</sup>, Joana Emmolo<sup>3</sup>, Adel Guirguis<sup>1</sup>, Hani Ashamalla<sup>1,4</sup>

<sup>1</sup>Department of Radiation Oncology, New York Methodist Hospital, Brooklyn, New York; <sup>2</sup>North Florida Cancer Institute, Gainesville, Florida; <sup>3</sup>Department of Radiation Oncology, Overlook Medical Center, Summit, New Jersey; <sup>4</sup>Weill Cornell School of Medicine, New York, New York, USA

Received March 20, 2012; accepted April 23, 2012; Epub July 10, 2012; Published July 30, 2012

**Abstract:** We have previously introduced anatomic biologic contouring (ABC) with PET/CT, using a distinct “halo” to unify contouring methods in treatment planning for lung and head and neck cancers. The objective of this study is to assess the utility of PET/CT in planning and treatment response for cervical cancer. Forty-two patients with stages II-III B cervix cancer were planned for irradiation using PET/CT. A CT-based Gross Tumor Volume (GTV-CT) was delineated by two independent observers while the PET remained obscured. The Planning Target Volume (PTV) was obtained by adding a 1.5 cm margin around the GTV. The same volumes were recontoured using PET/CT data and termed GTV-ABC and PTV-ABC, respectively. The values of GTV-CT and GTV-ABC and the absolute differences between the two observers were analyzed. Additionally, 23 of these patients had PET/CT performed 3 months after treatment. The anatomic biologic value (ABV) was calculated using the product of maximum diameter and mean SUV of the cervical tumor. The pre- and post-treatment ABVs were compared. A “halo” was observed around areas of maximal SUV uptake. The mean halo SUV was  $1.91 \pm 0.56$  (SD). The mean halo thickness was  $2.12 \pm 0.5$  (SD) mm. Inter-observer GTV variability decreased from a mean volume difference of  $55.36 \text{ cm}^3$  in CT-based planning to  $12.29 \text{ cm}^3$  in PET/CT-based planning with a respective decrease in standard deviation (SD) from 55.78 to 10.24 ( $p < 0.001$ ). Comparison of mean pre-treatment and post-treatment ABV's revealed a decrease of ABV from 48.2 to 7.8 ( $p < 0.001$ ). PET/CT is a valuable tool in radiation therapy planning and evaluation of treatment response for cervical cancer. A clearly visualized “halo” was successfully implemented in GTV contouring in cervical cancer, resulting in decreased inter-observer variability in planning. PET/CT has the ability to quantify treatment response using anatomic biologic value.

**Keywords:** Cervical cancer, positron emission tomography, PET/CT, treatment planning, inter-observer variability

## Introduction

Positron emission tomography (PET) with the glucose analog [<sup>18</sup>F] fluoro-2-deoxy-D-glucose (FDG) has been accepted as a valuable tool for the staging of cervical cancer [1-3], but the use of PET/CT in radiation treatment planning is still not clearly defined. This has left many radiation oncologists reluctant to use highly conformal radiation techniques, such as Intensity Modulated Radiation Therapy (IMRT) to treat this disease. IMRT represents a technology that allows highly conformal, high dose radiotherapy to be offered to specific treatment volumes. It has gained widespread acceptance in other cancer

sites, such as prostate and head and neck cancers. The Radiation Therapy Oncology Group led an international collaboration of cooperative groups in the development of a consensus about the clinical target volume (CTV) for endometrial and cervical cancers to be used in IMRT. The groups included the Radiation Therapy Oncology Group, Gynecologic Oncology Group, National Cancer Institute of Canada, European Society of Therapeutic Radiology and Oncology, and American College of Radiology Imaging Network [4]. The consensus detailed the CTV in the adjuvant setting however no guidelines for conformal therapy were offered for the definitive setting. The patterns of care study [5] recom-

mended L4/5 as the upper border for the conventional pelvic fields; with no adjustments given for a large uterine system due to benign reasons e.g. fibroids. Moreover, in patients where brachytherapy is either unfeasible or declined by the patient, the CTV employed for conformal radiation therapy (CRT) or IMRT is also vaguely defined.

Further complicating treatment volume definitions is the inherent variability between physicians in designing "optimal" volumes in cervical cancer [6]. We designed gross treatment volume (GTV) directly on PET/CT images using a previously defined Anatomic Biologic Contour (ABC). We advocated the use of the anatomic biologic volume to represent the contoured GTV when PET/CT is used [7, 8]. In this study, we prospectively address defining a standard treatment volume using PET/CT images, assessing the reduction in variability between CT-based GTV (GTV-CT) and PET/CT-based ABC treatment volumes (GTV-ABC) among different clinicians, and evaluating clinical response using "anatomic biologic value" (ABV) defined as a product of mean standard uptake value (SUV) and maximum tumor diameter.

### Materials and methods

Forty-two patients with stages II-IIIb cervical cancer were planned for radiotherapy using a fully integrated PET/CT device. While the PET data remained obscured, a CT-based Gross Tumor Volume (GTV-CT) was delineated by two independent observers (radiation oncologists). The Planning Target Volume (PTV) was obtained by adding a 1.5 cm margin around the GTV. The same volumes were recontoured using PET/CT data and termed GTV-ABC and PTV-ABC, correspondingly. All patients were treated with a combination of chemotherapy and radiotherapy. Radiotherapy was given externally followed by intracavity brachytherapy to a total dose of 85 Gy to point A.

#### *PET/CT simulation protocol*

We used the GE-Discovery-ST which combines a light speed CT 16-slice, in-line with PET BGO detectors. OS-EM is used for the reconstruction algorithm. Slice smoothing is performed via posterior filter (5.14 mm) and loop filter (4.69 mm), while the slice thickness is 3.75mm. Full Width Half Maximum (FWHM) for 1 cm is 4.8 mm and

for 10 cm is 6.3 mm. Three cross laser pointers and a flat top table have been integrated with the machine for simulation purposes. Thermoplastic or vacuum-molded immobilization devices needed for conformal radiation therapy (CRT) were custom fabricated. Patients were then injected with a standard dose of 10 mCi  $^{18}\text{F}$ -FDG, and left in the designated "quiet room" in the radiation oncology suite for an uptake period of 1 hour. After this time period, patients were escorted to the PET/CT scanner in the adjacent room (10 feet), and placed on the PET/CT machine in the treatment position utilizing the previously constructed immobilization devices. For the sake of reproducibility, an anterior and two lateral reference points are tattooed on the patient using the laser cross-marks. A full body PET/CT scan was then performed. The scan was electronically transmitted to Xeleris and Eclipse treatment planning work stations. Coregistration is performed automatically. Fused PET/CT images were adjusted to a window of 28,000 Bq/ml, while the level was adjusted at 17,000 Bq/ml; these parameters resulted in a major concordance between the treatment planning images and the PET/CT scan without the need to vary the PET threshold.

#### *Treatment volume determination*

Each FDG-PET study was reviewed with the interpreting nuclear radiologist before tumor volumes were contoured. For the sake of comparing CT-based treatment planning to PET/CT-based planning, treatment volumes were contoured independently. Two physicians, blinded to the results of PET, contoured the gross tumor volumes (GTV) from the CT data sets; a GTV (GTV-CT) was first contoured using only the CT data. The GTV-CT was defined per CT data only as the gross tumor visualized on the CT simulation and primary areas considered to contain disease as determined by the treating physician (which includes cervix and adjacent uterine tissue; given the difficulty to contour cervix separately from uterus); and any lymph nodes with a cross sectional diameter of 1 cm or greater. GTV-ABC was then defined separately using fully fused PET/CT imaging as the PET-enhancing gross tumor and/or any lymph node with an average SUV of 2.5 or greater (regardless of any deficiency in adequate nodal size criteria for malignancy as visualized by CT images alone). The "anatomic biologic halo" was recognized as the edge to be used for delineation of the GTV-

ABC as seen in **Figure 1**.

An assessment of the degree of correlation between GTV-ABC and GTV-CT was then performed. Inter-observer variability was estimated between both radiation oncologists for each patient. Additionally, we also recorded the Anatomic Biologic Value (ABV), defined as the product of mean SUV multiplied by the diameter of GTV-ABC; this was recorded to compare pre- and post-therapy values.

#### Statistical considerations

The values of GTV-CT and GTV-ABC variables for observers 1 and 2, the mean, and the absolute differences of planned treatment volumes between the two observers were analyzed. Wilcoxon Signed Rank tests and Sign tests for numerical data were utilized. For numerical parameters, the mean values are given  $\pm$  one standard deviation. STATA software package was used for statistical analysis.

#### Results

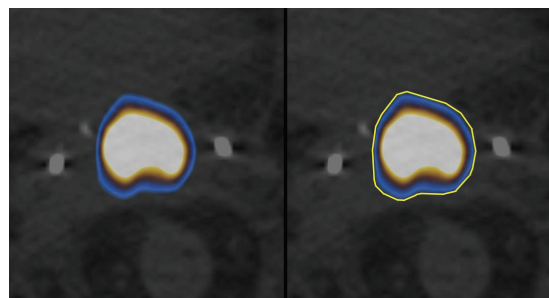
Forty-two patients with stages II-IIIb cervical cancer underwent planning CT and PET/CT for radiotherapy planning. Median patient age was 74 years (range 52-82), and median Karnofsky performance status (KPS) was 70. All patient images were evaluated by both radiation oncologists separately.

#### *The significance of the “Anatomic Biologic Halo”*

The same halo that we previously described in lung cancer cases [7, 8] was also observed around areas of maximal SUV uptake. The halo was identified by its distinct color at the periphery of the maximal areas of SUV uptake (**Figure 1**). The mean halo thickness was  $2.12 \pm 0.5$  (SD) mm. The mean halo SUV was  $1.91 \pm 0.6$ . This halo was always included in the contoured GTV-ABC. The halo's distinct color and slim wall allowed easy utility for contouring without the need to check the SUV reading in successive patients.

#### *Magnitude of inter-observer variability*

Inter-observer GTV variability decreased from a mean volume difference of 55.36 cm<sup>3</sup> in CT-based planning to 12.29 cm<sup>3</sup> in PET/CT-based planning with a respective decrease in standard



**Figure 1.** Example of “Anatomic Biologic Halo” observed around areas of maximal SUV uptake in Figure 1A. The halo was identified by its distinct color at the periphery of the maximal areas of SUV uptake. This halo was always included in the contoured GTV-ABC seen in yellow in Figure 1B. The halo's distinct color and slim wall allowed easy utility for contouring without the need to check the SUV reading in successive patients.

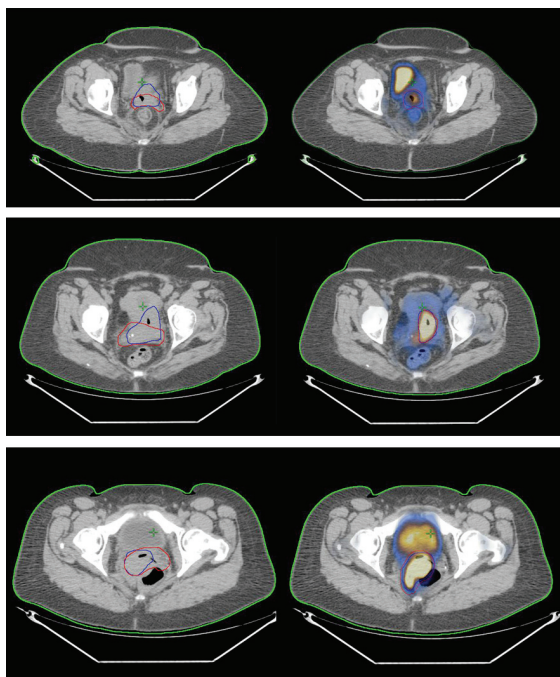
deviation (SD) from 55.78 to 10.24 ( $p < 0.001$ ). **Figure 2** demonstrates modification of GTV using PET/CT in comparison to CT planning in three examples.

#### *Measuring response with Anatomic Biologic Volume (ABV)*

Twenty-three patients had post-treatment PET/CT at 3 months following completion of radiation. Comparison of mean pre-treatment and post-treatment ABV's in this subset revealed a decrease of ABV from 48.2 to 7.8 ( $p < 0.001$ ). Patients with complete response (no residual tumor and no SUV uptake) had a mean pre-treatment ABV of 40.8 compared to 56.3 in those with partial response ( $p = 0.3$ ). All results are summarized in **Table 1**.

#### Discussion

A clearly visualized halo was successfully implemented in GTV contouring in cervical cancer, resulting in decreased inter-observer variability in radiation therapy planning. Additionally, PET/CT has the ability to quantify treatment response using anatomic biologic value. PET/CT remains an important clinical tool in staging for newly diagnosed cervical cancer [9, 10]. Still its utility and role in treatment planning has yet to be fully elucidated, as it is currently being incorporated into investigational studies [11]. Consensus among members of the Society of Gynecologic Oncologists show that the use of PET/CT



**Figure 2.** Three examples of CT-Based and PET/CT-Based planning for three different patients. A CT-based Gross Tumor Volume (GTV-CT) was first contoured using only the CT data by two independent observers. Observer 1 and 2's contours are indicated by the red and blue contours on each of the scans, respectively. A PET/CT Anatomic Biologic Contour (GTV-ABC) was then defined separately using fully fused PET/CT imaging. In all three cases, it is evident that the contours become increasingly concordant with the addition of PET/CT planning and utilization of the anatomic biologic halo.

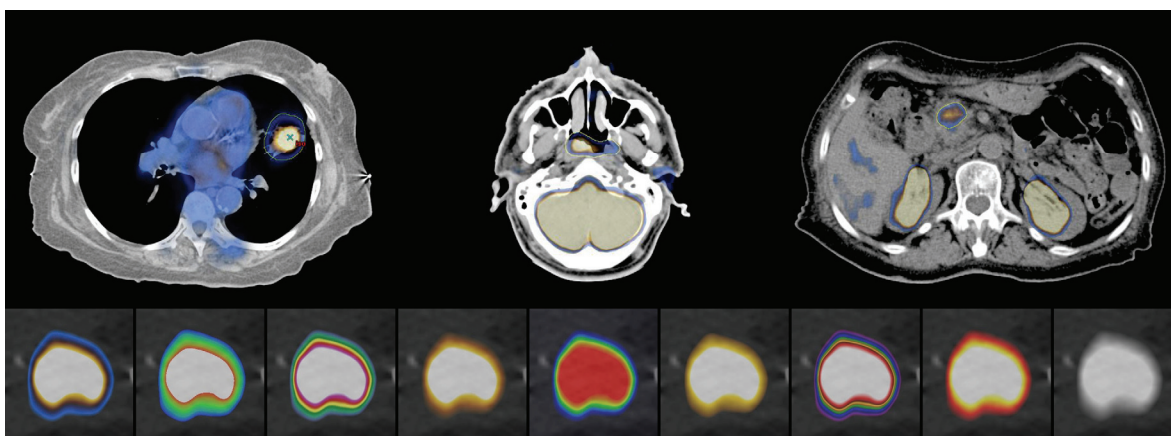
in patients with cervical cancer remains highly underutilized [12]. Our study aimed to reveal strengths of PET/CT compared to standard CT-based treatment planning by identifying a more specific GTV.

Our results suggest a large difference in independent radiation oncologists' GTV's when based on CT-based planning. Planning with PET/CT to create the GTV-ABC resulted in increase concordance by the two radiation oncologists. Difficulty with PET/CT-based planning is rooted in inter-institutional variability in defining the threshold for delineating malignant disease according to physiologic images. A variety of tumor criteria for identifying GTV have been previously described. A series of publications have arbitrarily advocated the FDG-avid volume as the region encompassed by the 50% intensity level relative to the tumor maximum intensity [13, 14]. Others have used auto-contours of SUV levels of 2.5 to delineate tumor [15]. Another issue complicating PET/CT is that the threshold of PET images can and often needs to be adjusted on a case-by-case basis and can introduce variability among independent observers [16].

In addition to this study, we have previously described [7, 8] the use of an anatomic biologic volume to represent the contoured GTV which was derived from a "halo" found on PET/CT. As we saw in all three studies, this halo was used to contour the PET/CT-based GTV with a de-

**Table 1.** Summary of results of Anatomic Biologic Contouring listing characteristics of the "Halo", the difference in variability of CT-based versus PET/CT-based planning and the "Anatomic Biologic Value".

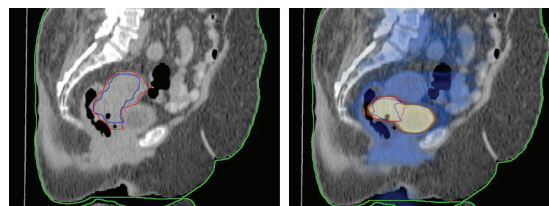
"Halo" Characteristics		
Mean Halo Thickness (mm) ± standard deviation		2.12 ± 0.50
Mean Standard Uptake Value (SUV) ± standard deviation		1.91 ± 0.56
Interobserver Variability		
	Volume Difference (cm <sup>3</sup> ) ± standard deviation	p-value
<i>CT-based Planning</i>		
CT-GTV Among Observer 1 and 2	55.36 ± 55.78	
<i>PET-CT-based Planning</i>		
ABC-GTV Among Observer 1 and 2	12.29 ± 10.24	<0.001
Anatomic Biologic Value (mean SUV x max diameter in cm)		
<i>Pre-treatment</i>		
	48.2	
Complete responders	40.8	
Partial responders	56.3	
<i>Post treatment</i>		
	7.8	<0.001



**Figure 3.** The “Anatomic Biologic Halo” visualized in a variety of sites: lung (A), nasopharynx (B), and pancreas (C). Also seen at the bottom of the figure (D) is the reproducibility of the halo in all PET visualization filters. The 1<sup>st</sup> box on the left represents the filter used in this study for all patients.

crease in interobserver GTV variability. This halo was irrespective of threshold level and has been reproduced in a variety of sites and viewing parameters (Figure 3). In PET/CT, electron-positron interaction result in two 511 keV gamma photons being emitted at 180 degrees to each other; hence, it is possible to localize their source along a straight line of coincidence. We believe the halo is due to a differential photon attenuation cause by the difference in tissue density at the interface of the tumor cells and surround normal tissue. This differential attenuation results in significant uptake in the tumor itself, then a rim characterized by a lack of signal registration, followed by a halo of signal registration, incorrectly localized from the tumor perimeter. We do not believe the halo is of biological significance. It is simply a physical property of photon attenuation and localization inherent in PET/CT registration.

Current practice guidelines among radiation oncologists for external beam radiotherapy delineate the superior border of the pelvic field at L4/L5 [5]. Inferiorly the border is at least 3-4 cm below the lowest extent of cervical or vaginal disease. Lateral borders are placed 1.5-2 cm lateral to the bony margins of the true pelvis. These borders have historically been used to ensure coverage of potential soft tissue tumor extent, lymph node drainage, and pathways of regional spread. These landmarks were rooted in skeletal anatomy seen on radiographs before the advent of CT and PET technology. It is already observed in contouring GTV for IMRT



**Figure 4.** Sagittal view of reduction of contour volume when PET-CT based planning used for cervical cancer (B) in comparison to volumes drawn with CT alone (A). Observer 1 and 2's contours are indicated by the red and blue contours on each of the scans, respectively.

plans, that cervix and adjacent 2-3 cm of uterine tissues are used [17]. PET/CT has been shown to be highly sensitive and specific for locoregional and metastatic spread of cervical cancer with a negative predictive value of 96% [3]. The SUV level of the tumor at diagnosis by PET has been correlated as a sensitive biomarker of treatment response and prognosis [18]. With sophisticated modalities in evaluating anatomy and extent of disease in addition to the utility of IMRT, the necessity in covering the entire pelvis in early-stage cervical cancer comes in to question. An example of the reduction in volume of contours drawn on PET/CT in comparison to CT alone is shown in the sagittal plan in Figure 4. In a study of 611 patients with cervical cancer who underwent radical hysterectomy with bilateral salpingo-oophorectomy, uterus involvement was found in 12.1% of the specimens [19]. Evaluation of operative speci-

mens of 230 patients with squamous cell carcinoma who underwent radical hysterectomy with pelvic lymphadenectomy revealed that extension beyond the cervix to the anterior parametria was in 23% of the cases and into the uterosacral ligaments in about 15% of the cases. Paracervical extension observed in 26% of the cases was related to the maximum depth of stromal invasion [20].

IMRT has had a definitive role in a variety of pelvic malignancies, but until recently its use in cervical cancer has not been completely defined, likely secondary to difficulty delineating tumor volume and organ motion. However, whenever IMRT is utilized, PET/CT seems an essential adjunct to aid planning. Kidd and associates evaluated the role of IMRT in treating a group of locally advanced cervical cancer, all IMRT patients had PET/CT simulation prior to treatment. The IMRT group showed significantly improved overall and cause-specific survival [17]. IMRT use in cervical cancer has been demonstrated to produce equivalent or better results in treatment of cervical cancer with single institution experience [12]. Using PET/CT simulation for tumor delineation and the natural history of disease progression, IMRT is the logical progression to obtain similar tumor control with less toxicity. FDG-PET will be a crucial component in delineating clinically relevant and reproducible tumor volumes in cervical CA given the difficulty of tumor volume visualization on CT alone.

**Address correspondence to:** Dr. Ajay Tejwani, New York Methodist Hospital, Department of Radiation Oncology, 506 Sixth St, Miner Basement, Brooklyn, NY 11215. Tel: (718) 780-3677; Fax: (718) 780-3637; E-mail: ajaytejwani@gmail.com

## References

- [1] Bjurberg M, Kjellén E, Ohlsson T, Ridderheim M, Brun E. FDG-PET in cervical cancer: staging, re-staging and follow-up. *Acta Obstet Gynecol Scand* 2007; 86: 1385-1391.
- [2] Bural GG, Shriaknathan S, Houseni M, Alavi A. FDG-PET is useful in staging and follow-up of primary uterine cervical lymphoma. *Clin Nucl Med* 2007; 32: 748-750.
- [3] Loft A, Berthelsen AK, Roed H, Ottosen C, Lundvall L, Knudsen J, Hojgaard L, Engelholm SA. The diagnostic value of PET/CT scanning in patients with cervical cancer: a prospective study. *Gynecol Oncol* 2007; 106: 29-34.
- [4] Small W, Mell LK, Anderson P, Creutzberg C, De Los Santos J, Gaffney D, Jhingran A, Portelance L, Scheffter T, Iyer R, Varia M, Winter K, Mundt AJ. Consensus guidelines for delineation of clinical target volume for intensity-modulated pelvic radiotherapy in postoperative treatment of endometrial and cervical cancer. *Int J Radiat Oncol Biol Phys* 2007; 71: 428-434.
- [5] Gaffney DK, Du Bois A, Narayan K, Reed N, Toita T, Pignata S, Blake P, Portelance L, Sadoyze A, Potter R, Colombo A, Randall M, Mirza MR, Trimble EL. Practice patterns of radiotherapy in cervical cancer among member groups of the Gynecologic Cancer Inter-group (GCIG). *Int J Radiat Oncol Biol Phys* 2007; 68: 485-490.
- [6] Wu DH, Mayr NA, Karatas R, Adli M, Edwards SM, Wolff JD, Movahed A, Montebello JF, Yuh WT. Interobserver variation in cervical cancer tumor delineation for image-based radiotherapy planning among and within different specialties. *J Appl Clin Med Phys* 2005; 6: 106-110.
- [7] Ashamalla H, Guirgus A, Bieniek E, Rafla S, Evola A, Goswami G, Oldroyd R, Mokhtar B, Parikh K. The impact of positron emission tomography/computed tomography in edge delineation of gross tumor volume for head and neck cancers. *Int J Radiat Oncol Biol Phys* 2007; 68: 388-395.
- [8] Ashamalla H, Rafla S, Parikh K, Mokhtar B, Goswami G, Kambam S, Abdel-Davem H, Guirgus A, Ross P, Evola A. The contribution of integrated PET/CT to the evolving definition of treatment volumes in radiation treatment planning in lung cancer. *Int J Radiat Oncol Biol Phys* 2005; 63: 1016-1023.
- [9] Kumar R, Chauhan A, Jana S, Dadparvar S. Positron emission tomography in gynecological malignancies. *Expert Rev Anticancer Ther* 2006; 6: 1033-1044.
- [10] Rajendran JG, Greer BE. Expanding role of positron emission tomography in cancer of the uterine cervix. *J Natl Compr Canc Netw* 2006; 4: 463-469.
- [11] Wolfson AH. Magnetic resonance imaging and positron-emission tomography imaging in the 21<sup>st</sup> century as tools for the evaluation and management of patients with invasive cervical carcinoma. *Semin Radiat Oncol* 2006; 16: 186-191.
- [12] Kizer NT, Zigelboim I, Case AS, Dewdney SB, Thaker PH, Massad LS. The role of PET/CT in the management of patients with cervical cancer: practice patterns of the members of the Society of Gynecologic Oncologists. *Gynecol Oncol* 2009; 114: 310-314.
- [13] Mah K, Caldwell CB, Ung YC, Danjoux CE, Balogh JM, Ganguli SN, Ehrlich LE, Tirone. The impact of (18)FDG-PET on target and critical organs in CT-based treatment planning of patients with poorly defined non-small cell lung carcinoma: a prospective study. *Int J Ra-*

## PET/CT planning in cervical cancer

- diat *Oncol Biol Phys* 2002; 52: 339-350.
- [14] Nestle U, Walter K, Schmidt S, Licht N, Nieder C, Motaref B, Hellwig D, Niewald M, Ukena D, Kirsch CM, Sybrecht GW, Schnabel K. 18F-deoxyglucose positron emission tomography (FDG-PET) for the planning of radiotherapy in lung cancer: high impact in patients with atelectasis. *Int J Radiat Oncol Biol Phys* 1999; 44: 593-597.
- [15] Paulino AC, Johnstone PA. FDG-PET in radiotherapy treatment planning: Pandora's box? *Int J Radiat Oncol Biol Phys* 2004; 59: 4-5.
- [16] Riegel AC, Berson AM, Destian S, Ng T, Tena LB, Mitnick RJ, Wong PS. Variability of gross tumor volume delineation in head-and-neck cancer using CT and PET/CT fusion. *Int J Radiat Oncol Biol Phys* 2006; 65: 726-732.
- [17] Kidd EA, Siegel BA, Dehdashti F, Rader JS, Muttic S, Mutch DG, Powell MA, Grigsby PW. Clinical outcomes of definitive intensity-modulated radiation therapy with fluorodeoxyglucose-positron emission tomography simulation in patients with locally advanced cervical. *Int J Radiat Oncol Biol Phys* 2010; 77: 1085-1091.
- [18] Kidd EA, Siegel BA, Dehdashti F, Grigsby PW. The standardized uptake value for F-18 flurodeoxyglucose is as sensitive predictive biomarker for cervical cancer treatment response and survival. *Cancer* 2007; 110: 1738-1744.
- [19] Kim MJ, Chung HH, Kim JW, Park NH, Song YS, Kang SB. Uterine corpus involvement as well as histologic type is an independent predictor of ovarian metastasis in uterine cervical cancer. *J Gynecol Oncol* 2008; 19: 181-184.
- [20] Landoni F, Bocciolone L, Perego P, Maneo A, Bratina G, Mangioni C. Cancer of the cervix, FIGO stages IB and IIA: patterns of local growth and paracervical extension. *Int J Gynecol Cancer* 1995; 5: 329-334.