

Original Article

Diagnostic performance of PET/MR in the evaluation of active inflammation in Crohn disease

Onofrio Antonio Catalano^{1,2,8}, Vincent Wu², Umar Mahmood⁴, Alberto Signore^{5,8}, Mark Vangel³, Andrea Soricelli⁶, Marco Salvatore⁷, Debra Gervais², Bruce R Rosen¹

¹Martinos Center for Biomedical Imaging, Department of Radiology, Massachusetts General Hospital, Harvard Medical School, 149 13th Street Charlestown #2301, Boston 02129, MA, USA; ²Abdominal Imaging, ³Biostatistics Center, Department of Radiology, Massachusetts General Hospital, Harvard Medical School, 55 Fruit St, Boston 02114, MA, USA; ⁴Precision Medicine, Martinos Center for Biomedical Imaging, Department of Radiology, Massachusetts General Hospital, Harvard Medical School, 149 13th Street Charlestown #2301, Boston 02129, MA, USA; ⁵Department of Nuclear Medicine, University of Rome "La Sapienza", Via di Grottarossa, 1035, 00189, Roma, Italy; ⁶Department of Radiology, University of Naples Parthenope, Via Acton 20, 80131, Naples, Italy; ⁷Department of Radiology and Nuclear Medicine, IRCCS-SDN, Via Gianturco 113, Napoli, 80131, Italy; ⁸Nuclear Medicine and Molecular Imaging, University Medical Center Groningen, Hanzeplein 1, Groningen, The Netherlands

Received October 22, 2017; Accepted December 29, 2017; Epub February 5, 2018; Published February 15, 2018

Abstract: This study investigates the performance of PET/MR versus each sub-modality alone in the assessment of active inflammation in patients with Crohn disease, when compared to surgery as standard of reference. Sensitivity for detecting active inflammation was 91.5% for PET, 80% for MR, and 88% for PET/MR. Specificity for active inflammation was 74% for PET, 87% for MR, and 93% for PET/MR. Diagnostic accuracy was 84% for PET, 83% for MR, and 91% for PET/MR. In conclusion, PET/MR is significantly more accurate than either sub-modality alone and more specific than PET alone in the detection of active inflammation in patients with Crohn disease.

Keywords: PET/MR, Crohn disease, inflammation, active inflammation

Introduction

Crohn disease is a chronic granulomatous inflammatory disorder that affects the gastrointestinal tract and is characterized by mucosal and transmural inflammation [1]. Although Crohn disease is often inflammatory in nature at its early stages, its behavior tends to evolve over time, resulting in complications such as stricturing or penetrating disease [2].

In current practice, the diagnostic gold standard for Crohn disease is endoscopy with biopsies. Nonetheless, endoscopic techniques are invasive with limited small bowel evaluation, and they provide only intraluminal mucosal visualization [3]. As a result, non-invasive imaging has increasingly played an important role in the management of Crohn disease. In particular, cross-sectioning imaging allows for assessment of the entire length of the bowel, extent of disease, extramural findings, and extraintesti-

nal manifestations [4]. Complications such as fistulas, strictures, and abscesses are also better characterized on imaging and profoundly influence clinical management [5]. After the initial diagnosis, imaging follow-up is essential to assess for disease activity, treatment response and the development of complications.

The ability to detect and localize active inflammation on imaging has important management implications. For instance, inflammatory strictures are typically treated with medical therapy, whereas fibrotic non-inflammatory strictures are treated with surgical resection [6]. Furthermore, modern immunomodulators (e.g., infliximab) for Crohn disease, designed to inhibit pro-inflammatory cytokines, have been proven effective in treating cases of active inflammation [7]. However due to associated economic costs and potential side effects, their usage might benefit from precise assessment of active inflammation before and during treatment.

¹⁸F-Fludeoxyglucose (FDG) positron emission tomography (PET) localizes and quantifies FDG uptake in tissues of increased metabolic activity, such as neoplasms and areas of inflammation [8]. PET has been shown in prior studies to be useful in the detection of inflammation in Crohn disease, especially in the pediatric population [9, 10]. In addition, positron emission tomography/computed tomography (PET/CT) improves the interpretation and localization of FDG uptake, thereby reducing false positive results [11]. A disadvantage of PET/CT is ionizing radiation, which is especially important in Crohn disease patient population that features a large percentage of children and young adults [12].

Hybrid positron emission tomography/magnetic resonance (PET/MR) has emerged as a promising modality in various applications. For example, PET/MR was demonstrated to be superior to PET/CT in the characterization of malignancies in the central nervous system [13, 14] and body [15-17]. The benefits of PET/MR over PET/CT derive from PET/MR's capability to synchronously acquire PET and MR data, from excellent soft tissue signal-to-noise and contrast-to-noise ratios of MR, and from additional functional imaging capabilities (e.g., diffusion-weighted imaging) [14, 18]. Studies also have shown that PET/MR results in a 20%-73% reduction in radiation exposure compared to PET/CT [19, 20].

Recent literature has described PET/MR in the evaluation of Crohn disease. One study reported the feasibility in using PET/MR acquired imaging biomarkers to differentiate between fibrotic and inflammatory strictures [21]. Another study showed that PET/MR is more accurate than PET/CT in assessing extra-luminal disease in patients with Crohn disease [22]. Nonetheless, comparisons in classification performances between PET/MR with each sub-modality alone in the assessment of bowel inflammation have remained unexplored.

In this study, we aim to investigate the performance of PET/MR versus each sub-modality alone, namely PET alone and MR alone, in the assessment of active inflammation in patients with Crohn disease, when compared to surgery as standard of reference.

Materials and methods

Subject selection

Subjects were identified from retrospectively reviewed clinical data of 43 consecutive patients who underwent PET/MR enterography for Crohn disease between December 2012 and July 2016. Among these patients, 32 of them underwent abdominal surgery within 8 weeks after the date of their PET/MR. Based on the availability of complete surgical records, 21 of these patients were selected to be included in this study.

PET/MR enterography protocol

In preparation for PET/MR, patients fasted for at least six hours before imaging. Two hours before imaging, patients began to drink at least two liters of a polyethylene-glycol based negative oral contrast solution. Ninety minutes before imaging, ¹⁸F-FDG (mean dose, 4.44 MBq per kilogram of body weight; range, 370-400 MBq) was injected intravenously.

Five minutes before PET/MR imaging, patients received 20 mg of intravenous Joscine N-butylbromure [Buscopan, Boehringer Ingelheim, Milan, Italy]. All patients were scanned on an integrated PET/MR system (mMR, Siemens, Erlangen, Germany). Two body coils (each with 12 channels) were combined to extend coverage of the entire abdomen. Patients were then imaged from the level of the mid-thigh to the diaphragm.

The following MR sequences were simultaneously acquired with PET (co-acquisition): coronal short time inversion recovery (STIR), axial T2-weighted half Fourier acquisition single shot turbo spin echo (HASTE), coronal T1-weighted Dixon, and axial diffusion weighted imaging (DWI). PET/MR co-acquisition enabled temporal and spatial matching of the MR and PET data. After completion of these co-acquisition sequences, the following stand-alone breath-hold MR sequences were performed: coronal T2-weighted HASTE, axial T1-weighted dual gradient echo (GE), and axial and coronal non-contrast and dynamic contrast enhanced (CE) T1-weighted volumetric interpolated breath hold examination (VIBE).

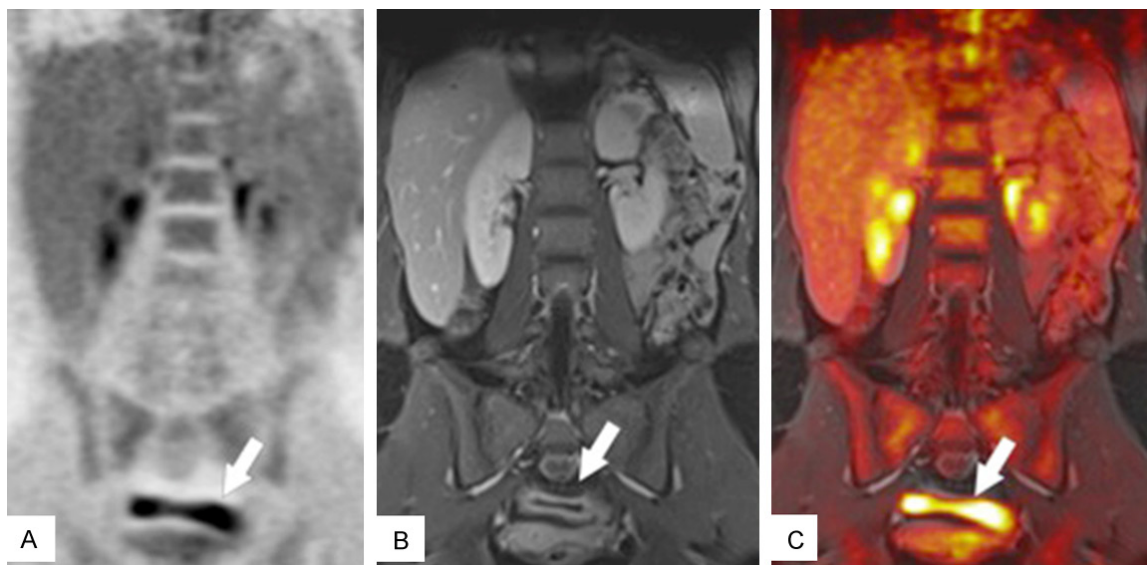


Figure 1. Concordance of PET and MR in correctly identifying active inflammation. Coronal PET (A), coronal CE-VIBE (B), fused PET/MR (C). An actively inflamed bowel loop (arrow) demonstrates wall thickening, pronounced enhancement, and marked FDG uptake (arrow).

Image analysis

A dedicated workstation (SyngoVia, Siemens, Erlangen, Germany) was used for image interpretation. Acquired images were divided into three categories: PET alone images, MR alone images, and combined PET/MR images. Each set of images was presented in a random order, at least 4 weeks apart, to two experienced radiologists (O.A.C and A.S with 18 and 30 years of experience, respectively). Readers were blinded to the surgical descriptions but were informed of the diagnosis of Crohn disease.

PET alone images were evaluated in the coronal and axial planes. MR alone images were evaluated using the following sequences: coronal STIR, axial DWI, coronal portal venous phase CE VIBE, axial delayed CE VIBE, and axial and coronal T2-weighted HASTE. Combined PET/MR images were evaluated using coronal and axial PET images along with the following MR sequences: coronal STIR, axial DWI, coronal portal venous phase CE VIBE, axial delayed CE VIBE, and axial and coronal T2-weighted HASTE. PET/MR images were evaluated both before and after co-registration and fusion.

For analysis, the gastrointestinal tract was divided into five segments: stomach plus duodenum, jejunum, proximal ileum, distal ileum, and colon. Each segment was classified as either positive or negative for acute inflammation. The imaging criteria for acute inflamma-

tion were: (a) increased FDG uptake with SUV-max ≥ 4 for PET; (b) bowel wall thickening > 3 mm, increased signal on T2 weighted/STIR images, and brisk post-contrast enhancement for MR; and (c) PET SUVmax ≥ 4 plus at least one of the MR criteria reported above for combined PET/MR interpretations. Similar MR criteria have been proposed in prior studies for the assessment of active bowel inflammation [23, 24].

Standard of reference

Surgical reports from operations performed within 8 weeks from the PET/MR study were used as the standard of reference for confirming the diagnosis of active bowel inflammation.

Statistical analysis

The sensitivity, specificity, and accuracy of the imaging modalities to detect active bowel inflammation were calculated in this study. Statistical differences between these measures were evaluated by the McNemar's test using the "R" statistics package (version 3.1.10; R Foundation, Vienna, Austria). *P*-values < 0.05 were considered statistically significant.

Results

A total of 105 bowel segments were identified and evaluated among the 21 patients included

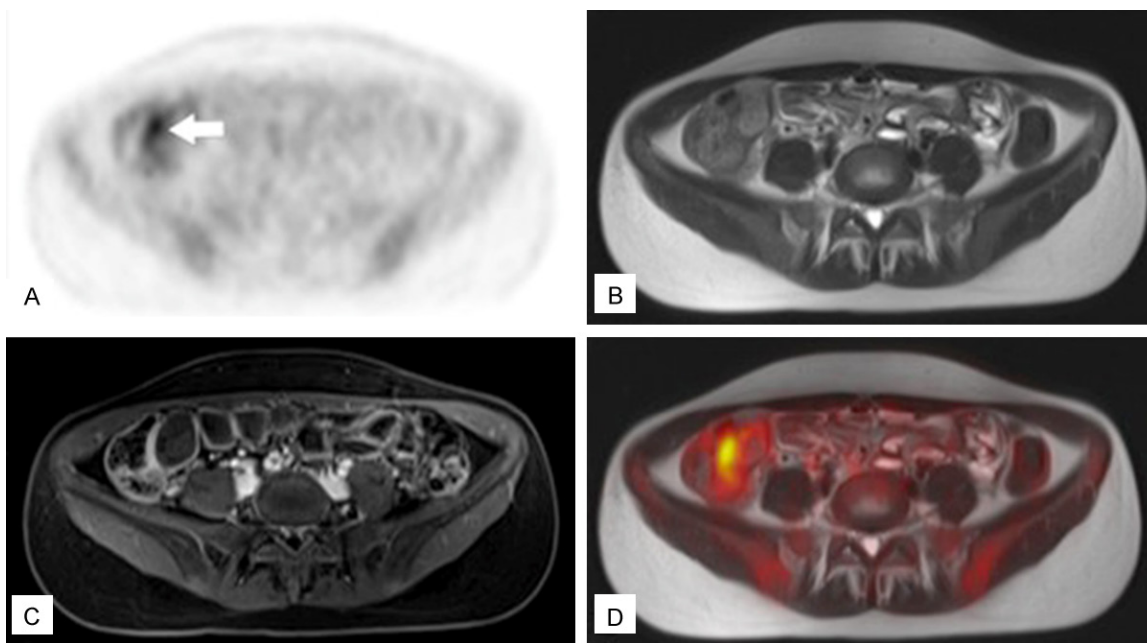


Figure 2. False positive PET case. Axial PET (A), axial T2-weighted HASTE (B), axial CE-VIBE (C), and fused PET/MR (D). A focal area of marked FDG uptake was identified in the distal ileum/ileocecal valve (arrow). However, no bowel wall thickening or hyperenhancement was seen in this region on MR. Additionally, no active bowel inflammation was observed in this region during surgery.

in this study. Image-based active inflammation was identified in 66/105 bowel segments on PET, 53/105 bowel segments on MR, and 55/105 bowel segments on PET/MR. On the basis of surgical reports, 59/105 bowel segments were positive for active inflammation; accordingly, the number of (a) true positive bowel segments (TP) were 54 in PET, 47 in MR, 52 in PET/MR (**Figure 1**); (b) true negative (TN) bowel segments were 34 in PET, 40 in MR, and 43 in PET/MR; (c) false positive (FP) bowel segments were 12 in PET, 6 in MR, and 3 in PET/MR; (d) and false negative (FN) bowel segments were 5 in PET, 12 in MR, and 7 in PET/MR. Representative false positive PET and MR cases are illustrated in **Figures 2** and **3**, respectively.

Sensitivity for detecting active inflammation was 91.5% for PET, 80% for MR, and 88% for PET/MR. The sensitivity of PET alone was significant higher than that of MR alone ($P = 0.02$). While the sensitivity for PET/MR was slightly lower than that of PET alone, the difference was not statistically significant ($P = 0.48$). PET/MR was more sensitive in detecting active inflammation compared to MR alone, but this was not shown to be statistically significant ($P = 0.08$).

On the other hand, the specificity for active inflammation was 74% for PET, 87% for MR, and 93% for PET/MR. When compared to PET alone, the higher specificities seen with PET/MR and MR alone were statistically significant ($P = 0.04$ and $P = 0.01$ respectively). Although PET/MR exhibited a higher specificity compared to MR alone, this difference was not statistically significant ($P = 0.37$).

Lastly, diagnostic accuracies were 84% for PET, 83% for MR, and 91% for PET/MR. The higher accuracy seen in PET/MR in identifying active inflammation was statistically significant compared to PET alone and MR alone ($P = 0.02$ and $P = 0.01$ respectively). When comparing diagnostic accuracies between PET alone and MR alone, no statistically significant difference was found ($P = 1.00$).

Discussion

This study, to the best of our knowledge, is the first to have investigated the diagnostic performance of PET/MR in the evaluation of active inflammation in Crohn disease when compared to intraoperative findings as standard of reference.

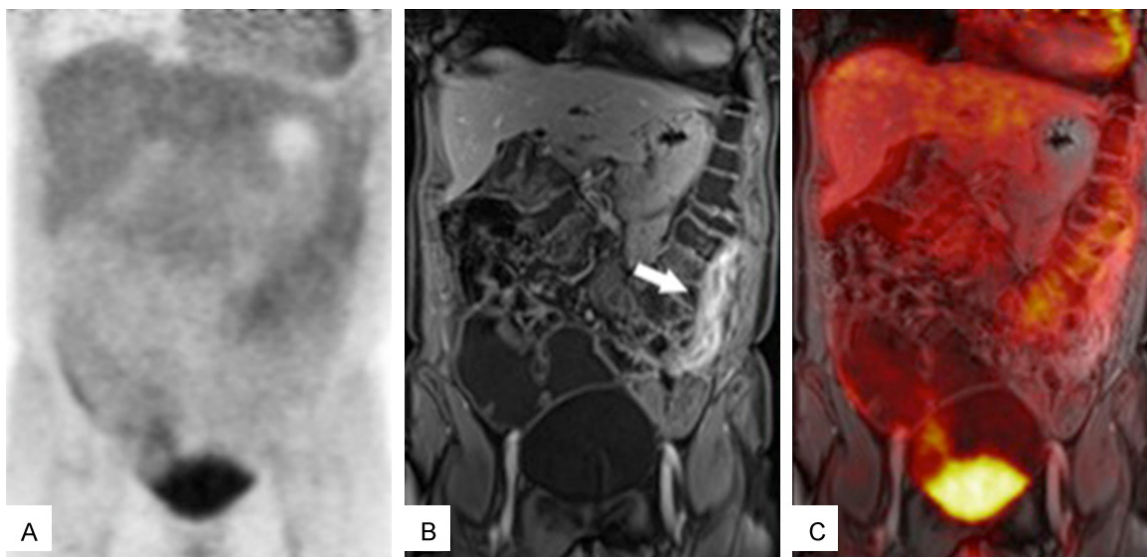


Figure 3. False positive MR case. Coronal PET (A), coronal CE-VIBE (B), and fused PET/MR (C). A segment of bowel wall thickening with abnormal hyperenhancement was identified in the left lower quadrant of the abdomen on MR (arrow). However, no FDG uptake in this region was detected on PET. Additionally, no active bowel inflammation was observed during surgery.

PET/CT has been shown to be a useful modality in identifying bowel segments with active inflammation. In particular, one meta-analysis paper revealed that PET/CT findings of bowel inflammation have correlated well with endoscopy results in IBD patients [25]. The combination of functional data from PET and morphological data from CT has been shown to predict response of Crohn disease patients to medical treatment. For example, one study suggested that abnormal segments of bowel enhancement on CT without FDG avidity was significantly associated with failure of medical therapy [26]. PET/CT has also been utilized to monitor treatment response in IBD patients, in which the degree of active inflammation as detected on PET/CT decreased after medical treatment and correlated with symptom improvement [27].

Similar to PET/CT, PET/MR combines functional and morphological data to potentially better assess the extent and location of disease than either sub-modality alone [28, 29]. PET/MR offers several advantages over PET/CT. Notably, MR has superior soft tissue signal-to-noise ratio and contrast-to-noise ratio when compared to CT. Signal intensity on T2 weighted images has been shown to reliably correlate with signs of active inflammation in Crohn disease while using endoscopy as a standard of

reference [23]. Furthermore, PET/MR is associated with a reduction in radiation dose to patients. This is especially important in Crohn disease patients who are typically young and are subject to multiple serial imaging studies throughout their lifetimes [30]. Compared to sequential acquisition in standard PET/CT, PET/MR coacquisition also enables more accurate spatial and temporal matching of MR anatomy with PET data [31]. Simultaneous PET/MR imaging is distinctly advantageous in bowel evaluation because sequential acquisition, intrinsic to PET/CT, can result in miss-registration artifacts due to motion and peristalsis [32].

Currently, there are only a few studies that describe the clinical utility of PET/MR within the context of IBD. In Crohn disease, PET/MR was shown to reliably differentiate between fibrotic versus inflammatory strictures [21] and accurately detect extra-luminal disease [22], while another group reported the utility of PET/MR in the identification of subclinical inflammation in ulcerative colitis [24]. These studies highlight the potential role that PET/MR might play in managing patients affected by chronic inflammatory bowel disease.

In our study, the results of the diagnostic performance of MR alone were similar to those of

a prior MR study that showed that T2-weighted and post-contrast enhancement images had a sensitivity of 80% and specificity of 98% in the differentiation of normal versus inflamed bowel segments, when compared to a surgical histopathology standard [33].

We found that PET was significantly more sensitive than MR in the detection of active inflammation. The high sensitivity (54-100%) of PET in detecting active inflammation in Crohn disease has been proven in previous studies and resulted in the well-known capability of PET to detect hypermetabolic activity at a molecular level [28, 29, 34]. This is advantageous in several diseases where PET demonstrates pathology well before detectable morphologic changes occur [35]. Our results also showed that PET was significantly less specific than MR in assessing for active inflammation. However this is a well-known limitation of PET, with reported specificity ranging 50-65% [10, 36], that is explained, at least in part, by the highly variable physiologic FDG uptake in the gastrointestinal tract [37]. These findings illustrate the importance of using information from both PET and MR in the evaluation of bowel inflammation and might explain why, in our study, PET/MR was significantly more specific than PET alone in detecting active bowel inflammation.

Additionally, PET/MR was shown in our study to be more accurate than either PET or MR alone. MR alone imaging may suffer from false-positive findings, with false-positive rates ranging from 7 to 21% as reported in prior studies [38, 39]. In particular, false-positive findings could stem from collapsed bowel loops that are mistakenly interpreted as bowel wall thickening/enhancement with abnormal MR signal [40]. Collapsed but normal bowel loops can also at times exhibit restricted diffusion and may be incorrectly diagnosed [40]. In our experience, with the added information provided by PET, the lack of FDG uptake would help us correctly classify these collapsed bowel loop segments as non-inflamed. On the other hand, MR alone imaging may also suffer from false-negative findings, with false-negative rates ranging from 10% to 21% in reported literature [38, 41]. For instance, false-negative findings can be seen in cases of mild inflammatory bowel disease [41], or in the presence of over-

distended bowel loops that may be misinterpreted as normal [40]. All in all, FDG uptake information as provided by PET may aid in the detection of active inflammation.

There were some limitations in our study design. First, this was a retrospective study conducted in a single center with a small sample size. Second, the use of a surgical standard of reference may have created a selection bias that recruited patients with more severe disease than the general Crohn disease population. Third, our study did not include follow-up data that may have allowed for the analysis of prognostic significance of PET/MR findings.

Conclusion

Our study shows that PET/MR is more accurate than either sub-modality alone and more specific than PET alone in the detection of active inflammation. PET/MR might improve diagnostic accuracy in evaluating for active Crohn disease, and thereby potentially play a role in the management and treatment monitoring for these patients.

Disclosure of conflict of interest

None.

Address correspondence to: Dr. Onofrio Antonio Catalano, Department of Radiology, Massachusetts General Hospital, 55 Fruit St, White Building 240, Boston 02114, MA, USA. Tel: 617-726-8396; Fax: 617-726-1818; E-mail: onofriocatalano@yahoo.it

References

- [1] Sleisenger M, Feldman M, Friedman L and Brandt L. Sleisenger and Fordtran's gastrointestinal and liver disease: pathophysiology, diagnosis, management. Philadelphia, PA: Saunders. Elsevier; 2010.
- [2] Papi C, Festa V, Fagnani C, Stazi A, Antonelli G, Moretti A, Koch M and Capurso L. Evolution of clinical behaviour in Crohn's disease: predictive factors of penetrating complications. *Dig Liver Dis* 2005; 37: 247-253.
- [3] Hara AK, Leighton JA, Heigh RI, Sharma VK, Silva AC, De Petris G, Hentz JG and Fleischer DE. Crohn disease of the small bowel: preliminary comparison among CT enterography, capsule endoscopy, small-bowel follow-through, and ileoscopy. *Radiology* 2006; 238: 128-134.
- [4] Bruining DH, Siddiki HA, Fletcher JG, Tremaine WJ, Sandborn WJ and Loftus EV. Prevalence of

- penetrating disease and extraintestinal manifestations of Crohn's disease detected with CT enterography. *Inflamm Bowel Dis* 2008; 14: 1701-1706.
- [5] Panes J, Bouhnik Y, Reinisch W, Stoker J, Taylor S, Baumgart D, Danese S, Halligan S, Marincek B and Matos C. Imaging techniques for assessment of inflammatory bowel disease: joint ECCO and ESGAR evidence-based consensus guidelines. *J Crohns Colitis* 2013; 7: 556-585.
- [6] Lenze F, Wessling J, Bremer J, Ullerich H, Spieker T, Weckesser M, Gonschorrek S, Kannengießner K, Rijcken E and Heidemann J. Detection and differentiation of inflammatory versus fibromatous Crohn's disease strictures: Prospective comparison of 18F-FDG-PET/CT, MR-enteroclysis, and transabdominal ultrasound versus endoscopic/histologic evaluation. *Inflamm Bowel Dis* 2012; 18: 2252-2260.
- [7] Dignass A, Van Assche G, Lindsay J, Lémann M, Söderholm J, Colombel J, Danese S, D'Hoore A, Gassull M and Gomollón F. The second European evidence-based consensus on the diagnosis and management of Crohn's disease: current management. *J Crohns Colitis* 2010; 4: 28-62.
- [8] Love C, Tomas MB, Tronco GG and Palestro CJ. FDG PET of infection and inflammation. *Radiographics* 2005; 25: 1357-1368.
- [9] Berthold L, Steiner D, Scholz D, Alzen G and Zimmer KP. Imaging of chronic inflammatory bowel disease with 18F-FDG PET in children and adolescents. *Klin Padiatr* 2013; 225: 212-217.
- [10] Löffler M, Weckesser M, Franzius C, Schober O and Zimmer KP. High diagnostic value of 18F-FDG-PET in pediatric patients with chronic inflammatory bowel disease. *Ann N Y Acad Sci* 2006; 1072: 379-385.
- [11] Kamel EM, Thumshirn M, Truninger K, Schiessner M, Fried M, Padberg B, Schneiter D, Stoeckli SJ, von Schulthess GK and Stumpe KD. Significance of incidental 18F-FDG accumulations in the gastrointestinal tract in PET/CT: correlation with endoscopic and histopathologic results. *J Nucl Med* 2004; 45: 1804-1810.
- [12] Loftus EV. Clinical epidemiology of inflammatory bowel disease: incidence, prevalence, and environmental influences. *Gastroenterology* 2004; 126: 1504-1517.
- [13] Kjær A, Loft A, Law I, Berthelsen AK, Borgwardt L, Löfgren J, Johnbeck CB, Hansen AE, Keller S and Holm S. PET/MRI in cancer patients: first experiences and vision from Copenhagen. *MAGMA* 2013; 26: 37-47.
- [14] Pichler BJ, Kolb A, Nägele T and Schlemmer HP. PET/MRI: paving the way for the next generation of clinical multimodality imaging applications. *J Nucl Med* 2010; 51: 333-336.
- [15] Catalano O, Nicolai E, Rosen B, Luongo A, Catalano M, Iannace C, Guimaraes A, Vangel M, Mahmood U and Soricelli A. Comparison of CE-FDG-PET/CT with CE-FDG-PET/MR in the evaluation of osseous metastases in breast cancer patients. *Br J Cancer* 2015; 112: 1452-1460.
- [16] Kang B, Lee JM, Song YS, Woo S, Hur BY, Jeon JH and Paeng JC. Added value of integrated whole-body PET/MRI for evaluation of colorectal cancer: comparison with contrast-enhanced MDCT. *AJR Am J Roentgenol* 2016; 206: W10-W20.
- [17] Lee DH, Lee JM, Hur BY, Joo I, Yi NJ, Suh KS, Kang KW and Han JK. Colorectal cancer liver metastases: diagnostic performance and prognostic value of PET/MR Imaging. *Radiology* 2016; 280: 782-792.
- [18] Jadvar H and Colletti PM. Competitive advantage of PET/MRI. *Eur J Radiol* 2014; 83: 84-94.
- [19] Atkinson W, Catana C, Abramson JS, Arabasz G, McDermott S, Catalano O, Muse V, Blake MA, Barnes J and Shelly M. Hybrid FDG-PET/MR compared to FDG-PET/CT in adult lymphoma patients. *Abdom Radiol (NY)* 2016; 41: 1338-1348.
- [20] Schäfer JF, Gatidis S, Schmidt H, Gückel B, Bezrukov I, Pfannenbergl CA, Reimold M, Ebinger M, Fuchs J and Claussen CD. Simultaneous whole-body PET/MR imaging in comparison to PET/CT in pediatric oncology: initial results. *Radiology* 2014; 273: 220-231.
- [21] Catalano OA, Gee MS, Nicolai E, Selvaggi F, Pellino G, Cuocolo A, Luongo A, Catalano M, Rosen BR and Gervais D. Evaluation of quantitative PET/MR enterography biomarkers for discrimination of inflammatory strictures from fibrotic strictures in Crohn disease. *Radiology* 2015; 278: 792-800.
- [22] Pellino G, Nicolai E, Catalano OA, Campione S, D'Armiento FP, Salvatore M, Cuocolo A and Selvaggi F. PET/MR versus PET/CT imaging: impact on the clinical management of small-bowel Crohn's disease. *J Crohns Colitis* 2015; 10: 277-285.
- [23] Rimola J, Rodríguez S, García-Bosch O, Ordás I, Ayala E, Aceituno M, Pellisé M, Ayuso C, Ricart E and Donoso L. Magnetic resonance for assessment of disease activity and severity in ileocolonic Crohn's disease. *Gut* 2009; 58: 1113-1120.
- [24] Shih IL, Wei SC, Yen RF, Chang CC, Ko CL, Lin BR, Shun CT, Liu KL, Wong JM and Chang YC. PET/MRI for evaluating subclinical inflammation of ulcerative colitis. *J Magn Reson Imaging* 2017; [Epub ahead of print].
- [25] Treglia G, Quartuccio N, Sadeghi R, Farchione A, Caldarella C, Bertagna F, Fania P and Cistaro A. Diagnostic performance of Fluorine-18-Fluorodeoxyglucose positron emission tomography in patients with chronic inflammatory bowel disease: a systematic review and a meta-analysis. *J Crohns Colitis* 2013; 7: 345-354.

PET/MR of active Crohn disease

- [26] Ahmadi A, Li Q, Muller K, Collins D, Valentine JF, Drane W and Polyak S. Diagnostic value of noninvasive combined fluorine-18 labeled fluoro-2-deoxy-D-glucose positron emission tomography and computed tomography enterography in active Crohn's disease. *Inflamm Bowel Dis* 2010; 16: 974-981.
- [27] Spier BJ, Perlman SB, Jaskowiak CJ and Reichelderfer M. PET/CT in the evaluation of inflammatory bowel disease: studies in patients before and after treatment. *Mol Imaging Biol* 2010; 12: 85-88.
- [28] Louis E, Ancion G, Colard A, Spote V, Belaiche J and Hustinx R. Noninvasive assessment of Crohn's disease intestinal lesions with 18F-FDG PET/CT. *J Nucl Med* 2007; 48: 1053-1059.
- [29] Shyn PB, Morteale KJ, Britz-Cunningham SH, Friedman S, Odze RD, Burakoff R, Goldberg JE, Erturk M and Silverman SG. Low-dose 18F-FDG PET/CT enterography: improving on CT enterography assessment of patients with Crohn disease. *J Nucl Med* 2010; 51: 1841-1848.
- [30] Beiderwellen K, Kinner S, Gomez B, Lenga L, Bellendorf A, Heusch P, Umutlu L, Langhorst J, Ruenzi M and Gerken G. Hybrid imaging of the bowel using PET/MR enterography: feasibility and first results. *Eur J Radiol* 2016; 85: 414-421.
- [31] Catalano OA, Rosen BR, Sahani DV, Hahn PF, Guimaraes AR, Vangel MG, Nicolai E, Soricelli A and Salvatore M. Clinical impact of PET/MR imaging in patients with cancer undergoing same-day PET/CT: initial experience in 134 patients-a hypothesis-generating exploratory study. *Radiology* 2013; 269: 857-869.
- [32] Roy P, Lee JK, Sheikh A and Lin W. Quantitative comparison of misregistration in abdominal and pelvic organs between PET/MRI and PET/CT: effect of mode of acquisition and type of sequence on different organs. *AJR Am J Roentgenol* 2015; 205: 1295-1305.
- [33] Schmid-Tannwald C, Schmid-Tannwald CM, Morelli JN, Albert NL, Braunagel M, Trumm C, Reiser MF, Ertl-Wagner B and Rist C. The role of diffusion-weighted MRI in assessment of inflammatory bowel disease. *Abdom Radiol (NY)* 2016; 41: 1484-1494.
- [34] Neurath M, Vehling D, Schunk K, Holtmann M, Brockmann H, Helisch A, Orth T, Schreckenberger M, Galle P and Bartenstein P. Noninvasive assessment of Crohn's disease activity: a comparison of 18F-fluorodeoxyglucose positron emission tomography, hydromagnetic resonance imaging, and granulocyte scintigraphy with labeled antibodies. *Am J Gastroenterol* 2002; 97: 1978-65.
- [35] Daldrup-Link HE, Franzius C, Link TM, Laukamp D, Sciuk J, Jürgens H, Schober O and Rummeny EJ. Whole-body MR imaging for detection of bone metastases in children and young adults: comparison with skeletal scintigraphy and FDG PET. *AJR Am J Roentgenol* 2001; 177: 229-236.
- [36] Lemberg DA, Issenman RM, Cawdron R, Green T, Mernagh J, Skehan SJ, Nahmias C and Jacobson K. Positron emission tomography in the investigation of pediatric inflammatory bowel disease. *Inflamm Bowel Dis* 2005; 11: 733-738.
- [37] Long NM and Smith CS. Causes and imaging features of false positives and false negatives on 18F-PET/CT in oncologic imaging. *Insights Imaging* 2011; 2: 679-698.
- [38] Kim KJ, Lee Y, Park SH, Kang BK, Seo N, Yang SK, Ye BD, Park SH, Kim SY and Baek S. Diffusion-weighted MR enterography for evaluating Crohn's disease: how does it add diagnostically to conventional MR enterography? *Inflamm Bowel Dis* 2015; 21: 101-109.
- [39] Seo N, Park SH, Kim KJ, Kang BK, Lee Y, Yang SK, Ye BD, Park SH, Kim SY and Baek S. MR enterography for the evaluation of small-bowel inflammation in Crohn disease by using diffusion-weighted imaging without intravenous contrast material: a prospective noninferiority study. *Radiology* 2015; 278: 762-772.
- [40] Neubauer H, Pabst T, Dick A, Machann W, Evangelista L, Wirth C, Köstler H, Hahn D and Beer M. Small-bowel MRI in children and young adults with Crohn disease: retrospective head-to-head comparison of contrast-enhanced and diffusion-weighted MRI. *Pediatr Radiol* 2013; 43: 103-114.
- [41] Ziech ML, Hummel TZ, Smets AM, Nievelstein RA, Lavini C, Caan MW, Nederveen AJ, Roelofs JJ, Bipat S and Benninga MA. Accuracy of abdominal ultrasound and MRI for detection of Crohn disease and ulcerative colitis in children. *Pediatr Radiol* 2014; 44: 1370-1378.