

## Original Article

# Impact of sentinel lymph node biopsy in newly diagnosed invasive breast cancer patients with suspicious node: a comparative accuracy survey of fine-needle aspiration biopsy versus core-needle biopsy

Adheesh Bhandari<sup>1\*</sup>, Erjie Xia<sup>1\*</sup>, Yinghao Wang<sup>1</sup>, Namita Sindan<sup>2</sup>, Ranjan Kc<sup>3</sup>, Yaoyao Guan<sup>4</sup>, Yueh-Lung Lin<sup>4</sup>, Xiaoshang Wang<sup>5</sup>, Xiaohua Zhang<sup>1</sup>, Ouchen Wang<sup>1</sup>

<sup>1</sup>Department of Thyroid and Breast Surgery, The First Affiliated Hospital of Wenzhou Medical University, Wenzhou 325000, Zhejiang, PR China; <sup>2</sup>Department of Reproductive Health Center, Second Affiliated Hospital of Wenzhou Medical University, Wenzhou 325000, Zhejiang, PR China; <sup>3</sup>Department of Cellular and Molecular Medicine, Lerner Research Institute, Cleveland Clinic, OH 44120, USA; <sup>4</sup>Mathematical Sciences, University of Nottingham, Ningbo 325000, Zhejiang, PR China; <sup>5</sup>School of International Studies, Wenzhou Medical University, Wenzhou 325000, Zhejiang, PR China. \*Equal contributors.

Received February 16, 2018; Accepted May 16, 2018; Epub June 15, 2018; Published June 30, 2018

**Abstract:** Comparing diagnostic accuracy study between ultrasonography (US) guided fine-needle aspiration biopsy (FNAB) and core-needle biopsy (CNB) of the Sentinel lymph nodes (SLNs) in newly diagnosed invasive breast cancer patients. We selected 289 newly diagnosed invasive breast cancer patients from June 2015 to July 2017. Ultrasound (US) guided fine-needle aspiration cytology (FNA) and core-needle biopsy (CNB) was performed to identify patients with suspicious sentinel lymph node (SLN). Patients with a cortical thickness > 2 mm or atypical morphological characteristics were recommended FNA and CNB. Axillary lymph node dissection (ALND) was applied to patients with biopsy-proven metastasis, and sentinel lymph node biopsy (SLNB) was applied to FNA or CNB negative patients. ALND was also performed when SNB is positive. Out of 289 patients, only 131 patients met final study criteria. Lymph node status was evaluated by FNA, CNB, SLND, and ALND. Among 131 patients, 45 were deemed positive for metastasis and 86 were determined to be negative with CNB, whereas 38 were deemed positive for metastasis and 93 were determined to be negative by using FNAB. CNB was used to correctly identify seven axillae as positive for metastasis that were deemed negative by using FNAB. There were no positive FNAB results in axillae that were negative for metastasis with CNB. All patients underwent SLNB and those with biopsy-proved axillary metastases were assigned directly to ALND as the primary staging procedure. The final histopathologic assessment indicated that 50 (38.2%) of the 131 axillae studied had axillary LN metastases. Axillary US-guided CNB was used to correctly identify 45 (90.0%) of the 50 LN-positive axillae, whereas axillary US-guided FNAB was used to correctly identify 38 (76.0%,  $P < 0.001$ ). There were no false-positive results. CNB netted 5 false-negative results, and FNAB resulted in 12. There was significantly different accuracy between different diagnostic tools. In our study, we demonstrated that CNB is a more reliable approach than FNA for the preoperative diagnosis of SLN metastasis.

**Keywords:** Fine-needle aspiration, core needle biopsy, breast cancer, sentinel lymph node, combined approach, carbon nanoparticles suspension injection, radioisotope suspension injection

## Introduction

Breast cancer is believed one of the most common malignancies in women. Sentinel lymph node (SLN) biopsy has become a normal method for assessing the axilla in clinically lymph node-negative patients with breast cancer [1, 2]. The advantages of SLN biopsies in avoiding the incidence of complete axillary lymph node

dissection while providing correct staging information have been well-documented [3-5]. SLN is defined as the first lymph node that receives lymphatic drainage from a tumor, and therefore, if they are present, is most likely to have micro-metastasized lymph nodes.

Breast cancer axillary staging is an important part of breast cancer surgery. Previous evi-

## A comparative accuracy survey of FNA versus CNB

dence was obtained by complete axillary lymph node dissection (ALND) which is a high-incidence surgery. Since the 1990s, the use of less aggressive Sentinel Lymph Node Biopsy (SNB) has resulted in a lower incidence of accurate staging [6-8].

Sentinel lymph node biopsy (SLNB) is a standard surgical procedure evaluated in the axillary of patients with invasive breast cancer. Sentinel lymph node (SLN) metastasis is usually determined by cryo-section or blot cytology of hematoxylin and eosin; however, the differences in sensitivity and protocol among these in-diagnosis methods are small [9, 10].

The current axillary staging standard is for sentinel lymph node biopsy (SLNB). Usually, only LN patients who have a positive SLNB result in further care, otherwise they do not need the usual ALND [11, 12]. Less aggressive axillary surgery is advantageous to avoid the risk of reduced arm stiffness, pain, paraneesthesia, and lymphedema [13]. Lately, due to the improvement of the ultrasound potential, ultrasound-guided biopsy has been used to identify patients with armpit metastases prior to surgery. Biopsy diagnosis of metastatic axillary disease allows the surgeon to perform ALND directly, saving the cost and time required to perform the SNB. Furthermore, Axillary metastases may suggest a broader staging assessment and may make patients more suitable candidates for neoadjuvant chemotherapy. Some of the past studies have well documented the sensitivity and specificity of ultrasound-guided axillary biopsies [6-8, 14-17].

The aim of this study is to find the accuracy of preoperative diagnostic tools FNAC and CNB for staging sentinel LNs.

### Patients and methods

#### Patients

The present study involved 289 female patients, aged 28-82 years, diagnosed with operable early invasive breast carcinoma, with any histological tumor subtype and with indications for SNB during surgery. These women had been managed at the First Affiliated Hospital of Wenzhou Medical University (Zhejiang, China) from May 2015 to September 2017. 158 patients were excluded from the study. Exclusion criteria were: (1) Multifocal

multicentric cancer, (2) Axillary lymph node metastases on preoperative ultrasound, (3) Previous breast biopsy and radiation, (4) Refusal to participate in the study.

This study obtained ethical approval from the Institutional Review Board of First Affiliated Hospital of Wenzhou Medical University (approval no. 2012-57). In addition, the medical directors' offices of the hospital granted permission to use the patients' data for this study. All data had no personal identifiers and were kept confidential and therefore did not require informed consent.

#### Methods

During a biopsy, a  $\gamma$  probe (Neoprobe 2000, Dublin, Ohio, USA) was used to trace the sentinel lymph node (SLN). A Toshiba Diagnostic Ultrasound System (NEMIO SSA-550A), 8.0 to 12.0 MHz imaging frequency and with a 12.0 L linear probe was used. Ultrasound-guided FNA and CNB of ALNs were made for sentinel lymph node (SLN), distinctive of benign or suspicious ultra-sonographic nodal mass and morphological structures. The extracted sample contents were spread onto a glass slide for cellular distension. CNB sample was placed in 10% Formalin solution before sending it to the lab for paraffin test. The SLN was obtained during the planned surgical procedure for each patient, following its position by Carbon Nano Particles (Black Patent Dye) injection and Radioisotopes lymphoscintigraphy scan. The SLN was sent for histopathological investigation to the laboratory for more tests. The same pathologist inspected CNB, FNA, with SLN histopathology and paraffin test results obtained during operation and it is considered as the "Gold Standard" sample to estimate the performance of FNA and CNB.

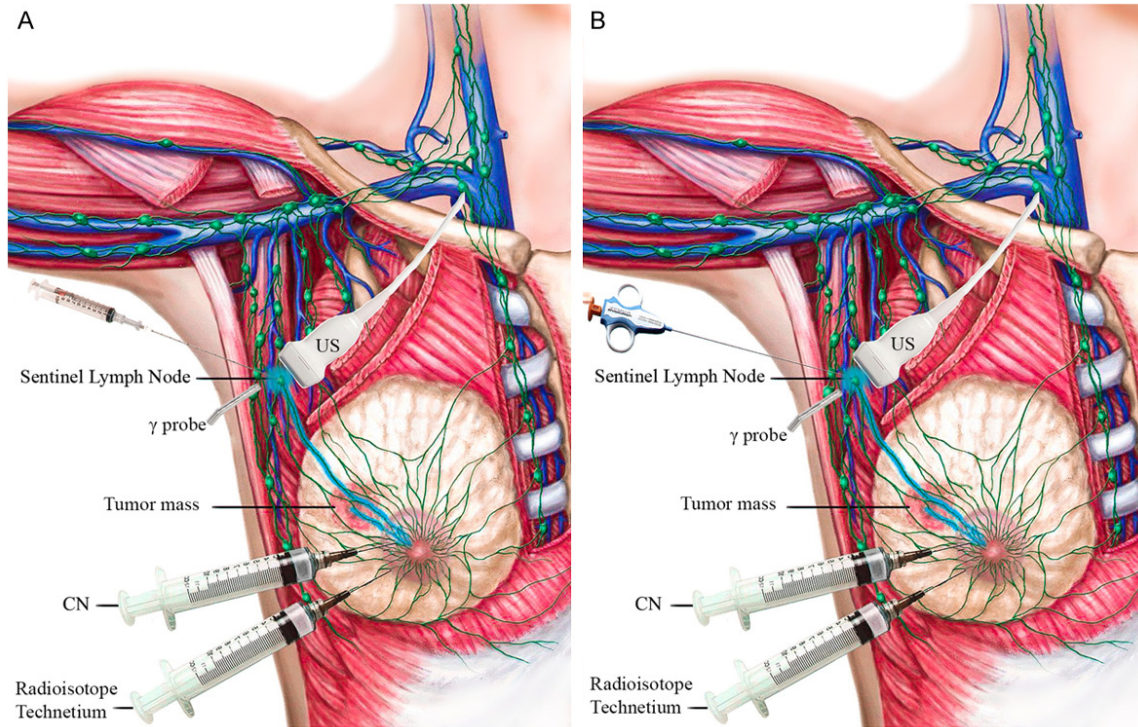
#### Statistical analysis

Statistical analysis was done using SPSS software (SPSS, version 22; SPSS, IBM Corp. Armonk, NY, USA). Sensitivity, Specificity, positive and negative predictive values and overall accuracy were calculated by OpenEpi [18].

#### *SLN gamma detection probe and ultrasound, fine-needle aspiration, and core needle biopsy*

A  $\gamma$  detection photon probe (Neoprobe 2000, Dublin, Ohio, U.S.A) having energy peak set at

## A comparative accuracy survey of FNA versus CNB



**Figure 1.** A. Showing Ultrasound-guided Fine Needle Aspiration Biopsy (FNAB) of sentinel lymph node using a 21- or 22-gauge needle attached to a 10-mL syringe. B. Ultrasound-guided Core Needle Biopsy (CNB) of sentinel lymph node using automated CNB gun with a 16 G needle (TT1611 16 G × 11 cm, Temno Evolution™, CareFusion, North Fairway Drive, USA) (Figure primary source gammaprobe.com).

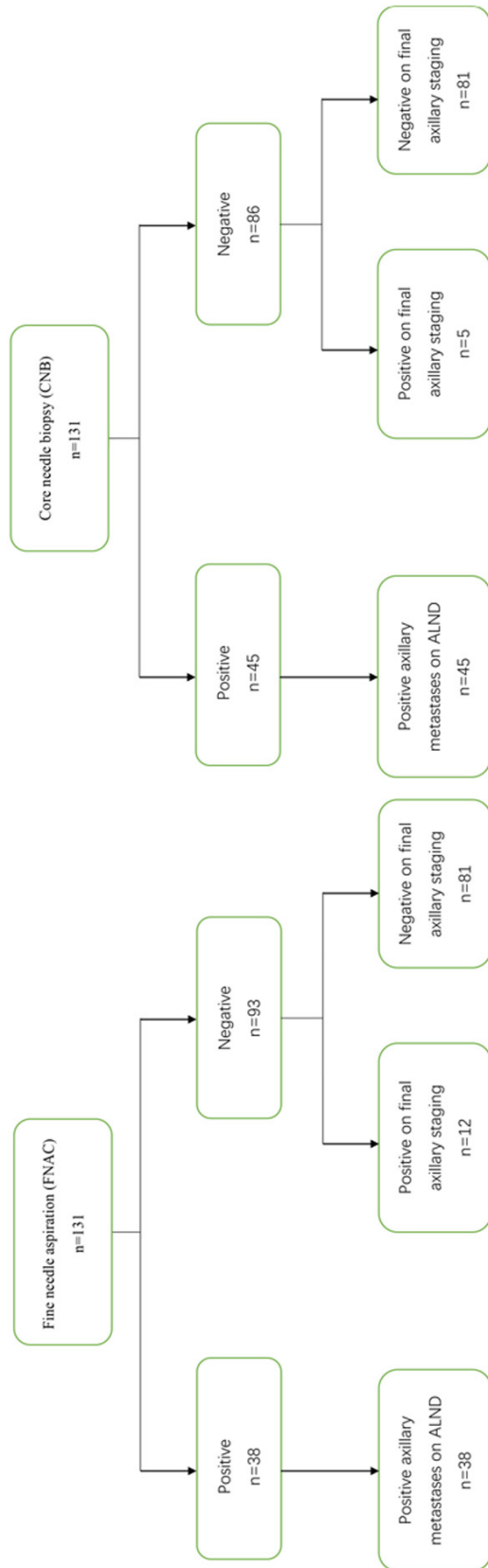
140 keV-20% window was used to localize the radioactive SLN intraoperatively and then with the use of 10-16 MHz matrix linear array transducer on the Toshiba diagnostic US (NEMIO SSA-550A), the axilla ipsilateral to the newly diagnosed invasive breast cancer patients was thoroughly examined. Local anesthetic was given intradermally and subcutaneously prior to CNB process. During US assessment, extra care was paid to the typical site of the sentinel LN at the axillary tail area. A biopsy sample was obtained from the most suspicious sentinel LN if the cortical thickness exceeded 2 mm (**Figure 1**) or if the LN had any of the following abnormal morphologic characteristics: eccentric or lobulated cortex, any concentric or eccentric thickening larger than 2 mm, absent or dislocated fatty hilum, a longitudinal axis-to-transverse axis ratio fewer than 2, or a cortex-to-hilum ratio more than 1.

Primary, FNAB of the LN was performed with local anesthesia by the 21G-gauge needle attached to a 10-ml normal syringe. The needle was inserted into the area to be sampled and

repeatedly redirected to the cortex and sub-capsular area while suction was applied. Subsequently, 16-gauge CNBs were obtained from the related area by using a CNB gun with a 16 G core biopsy needle (TT1611 16 G × 11 cm, Temno Evolution™, CareFusion, North Fairway Drive, USA) or 16 G core biopsy needle (FC16 G × 100 mm, Dr. J Fine Core, Nagano, Gyoda City, Japan). Either two or three sample that macroscopically contained solid non-fatty tissue were obtained. Additional biopsies were allowed at the preference of the Oncologist performing the biopsy if the first biopsy findings were interpreted as possibly non-representative. FNA and CNB sample obtained during procedure showed Carbon Nanoparticle injection suspension (black in color) staining, which confirms that it is the sentinel lymph node (**Figure 3**).

Patients who were biopsied for metastasis underwent complete ALND, whereas those with negative FNA or CNB received SNB. FNA and CNB were completed by two oncologists specializing in the diagnosis and treatment of

## A comparative accuracy survey of FNA versus CNB



**Figure 2.** Schematic diagram of percutaneous biopsy results by types and surgical staging.

breast cancer between 2015 and 2017. They have 8 and 23 years of experience in the preoperative diagnosis and interventional breast imaging of FNA and CNB.

The FNA cytology and CNB paraffin test results of all the cases of ultrasound detected abnormal sentinel lymph nodes was compared with the final histopathologic status after SNB. Problems such as hematoma, pain, and bleeding were assessed at the process of FNA and CNB. Papanicolaou and Giemsa stains were used to stain the smears and evaluated by a skilled pathologist. When atypical epithelial cells were seen, cytokeratin was then used to stain the smears. FNA and CNB groups both are used for diagnostic accuracy for sentinel lymph node status.

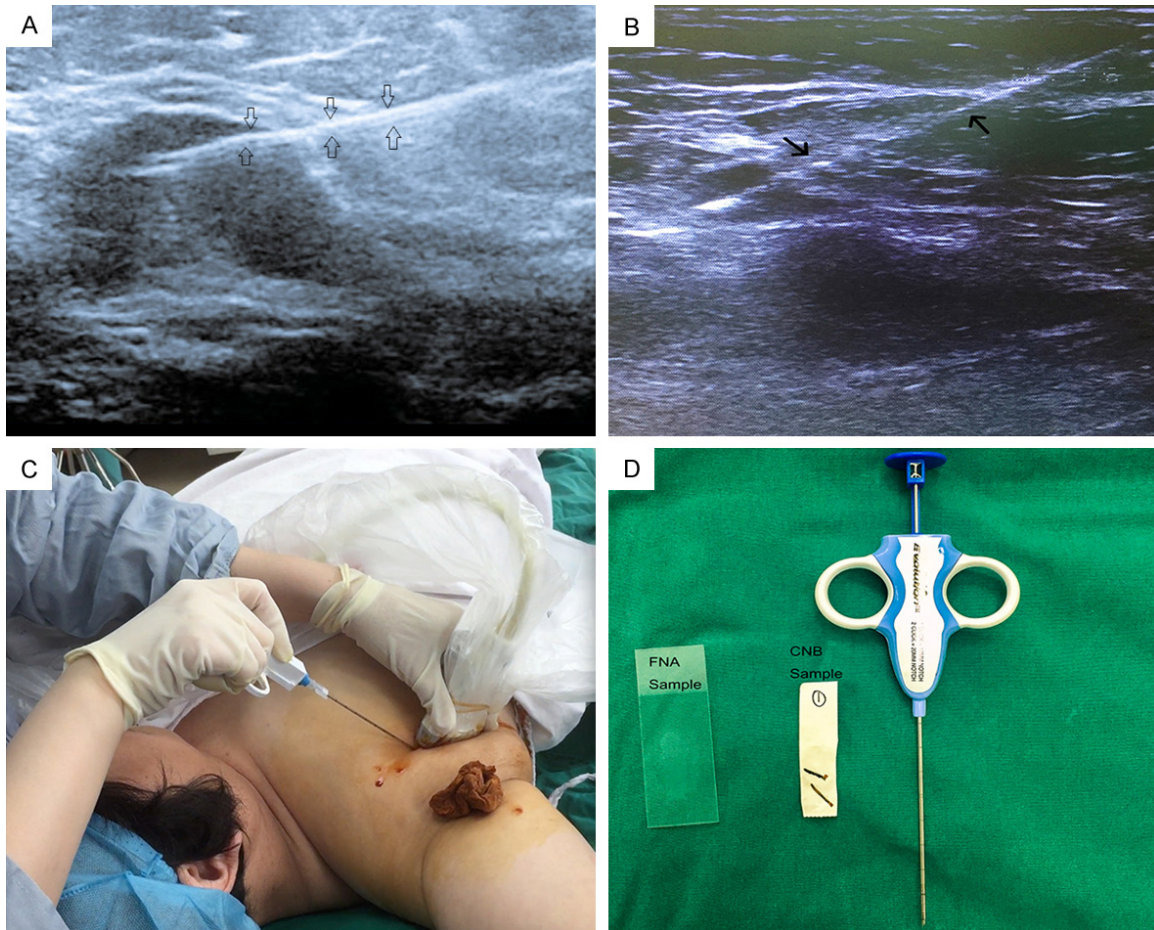### Identification process of sentinel lymph node

*Dye, radioisotopes or a combination of both (dye and radioisotopes):* Blue dye was used to identify SLNs [19, 20], radioisotopes [21-23], or combining both blue dye and radioisotopes [24]. However, the debate continues as towards which is the best [25, 26]. In different studies, Cox et al. [27] found that blue dye could improve to identify SLNs in 80% and radioisotopes in 89% of patients. Using the combination of blue dye and radioisotopes improved the success rate to 96%. Cody et al. [28] reported that the SLNs using blue dye showed 81%, radioisotopes showed 87% success rate in patients and combined technique showed 95% success rate. Japanese Breast Cancer Society reported that, among 94% patients, SLNs were identified successfully using the combined technique by only using blue dye alone got the success rate of 74% of the patients [29]. Likewise, Cody [30] and Miltenburg et al. [31] both explained a using combined technique rather than with blue dye or radioisotope alone the identification rate of SLNs was higher. This advancement in the identification rate may affect retrospective learning by surgeons, however, it may also be involved with an exact advantage of the combined technique.

The radioisotope tracer's ideal size for the SLN identification had continued to be controversial [26]. One of the prime difficulties is that minute particle of radioisotope tracers may pass through the SLN and label secondary nodes additionally. A particle size of 3-30 nm is con-



## A comparative accuracy survey of FNA versus CNB



**Figure 3.** A. The ultrasound-guided FNA shows open specimen collection trough of the suspicious Sentinel Lymph Node (SLN). (Arrows indicating FNA needle). B. The ultrasonography-guided CNB shows open specimen collection trough of the suspicious Sentinel Lymph Node (SLN). (Arrows indicating Core Needle Biopsy needle). C. Ultrasound-guided freehand technique to extract sentinel lymph node biopsy. D. FNA and CNB specimens' samples of Sentinel Lymph Node (SLN) (Black stained).

sidered efficacious for lymphoscintigraphy, but the perfect radioisotope tracer for SLN visualization is pellucidly different from a particulate tracer optimized for the visualization of all the lymph nodes by measures of scintigraphy [32-34]. Whereas the large radioisotope particle tracers, appears to pass across to secondary nodes barely, nevertheless, they show less uptake at the injection site.

With the various reports in the higher success rate of combined technology, we also used it in our patients and it helped us to find accurate SLNs during FNA and CNB under  $\gamma$  probe followed by ultrasound which helped during surgery to locate SLN (**Figure 1**). As for dye, we used Carbon Nanoparticle (CN) suspension injection and  $^{99m}\text{Tc}$ -radiolabelled colloidal albumin as radioisotopes. CN suspension injection was used in the form of a standard CN suspen-

sion injection 1 ml: 50 mg. Carbon nanoparticles were better to a combination of gamma probe and blue dye in SLNs identification ratio [35]. During comparison, data from Yuan et al.'s [36] study reported all the patent blue-dyed nodes lost the color rapidly when the time of injection exceeds 6 h before surgery.

No finding of carbon nanoparticle is detected in the blood circulation leading to no side effects of the human body. The Carbon Nanoparticle (CN) suspension does not enter the blood circulation and has no toxic side effects on the human body [37]. Compared with traditional dye, carbon nanoparticles (CN) have the advantages of a long retention time in the lymph system, low toxicity, and exclusion from blood circulation. The remaining CNs are captured by macrophages and excreted through the kidneys, lungs, and intestines after a few months

## A comparative accuracy survey of FNA versus CNB

[38]. Further, CNs do not interfere with pathological examination of stained tissue because they cannot be detected with optical microscopy due to their small size. Hence, we used CN suspension injection instead of methylene blue dye because it shows better stability and operability for the SLN detection, as well as it stains for a longer duration. Normally our patients undergo surgery 2-3 days after FNA and CNB procedure of SLN. The suspension comprises Nano-sized carbon particles with an average diameter of 150 nm. The cell gap between capillary endothelial cells is 20-50 nm and the capillary lymphatic endothelial cell gap is 120-500 nm with a hypoplasia of the basement membrane. In recent years, they have received considerable interest, especially with respect to their potential utilization of lymphatic mapping. Due to the molecular size and permeability Carbon nanoparticles selectively enter the lymphatic vessels rather than blood capillaries. When injected into the tissues around the tumor, carbon nanoparticles are promptly engulfed by macrophages and then pass through the lymphatic vessels to the SLNs, thus staining them black. Due to less access to the blood circulation, carbon nanoparticles have no harmful side effects on our body. Paganelli et al. [39] demonstrated that by using large particle colloidal albumin, the SLN can be easily identified rather than small particle radioisotopes.

*Optimal time for radioisotope and carbon nanoparticle (CN) suspension injection:* The radioisotope tracer runs to and settles in the SLN, generating the "hot spot" in contrast with the adjacent tissues. If the time is ample to permit the radioisotope to transfer into the SLN, the injection time is not so serious. The reasonable time period for picking up the SLNs is 2-24 hours from the time after injecting the radioisotope injection [39-45]. Other authors [23, 39, 40, 43, 45, 46] have also stated that SLN biopsy is likely to be done even the day after injection. This is very appropriate for surgeons with a busy operating roster [45]. CN suspension injection was injected 30 minutes-1 hour before the FNA and CNB and whole breast massage was given for 8-10 minutes.

### Complications

Our main concern in performing FNAB and CNB is to avoid blood vessels or nerves damage

because lymph nodes are often located nearby. In our experience with more than 2000 biopsies, there have been no major complications. A biopsy device with controllable needle action should be used, with a sharp anatomical understanding and good proficiencies for guiding the needle, to avoid significant difficulties. The patient might complain of a sharp radiating pain on insertion of the needle, indicating possible contact with a nerve, choosing a slightly different direction for the approach invariably resolves the problem. Use of the inferolateral-to-superomedial approach with the patient's ipsilateral arm raised but not fully extended allows most sampling to be done parallel to major vessels.

### Results

Out of 289 newly diagnosed invasive breast cancers only 131 patients met final study criteria. Lymph node status was evaluated by FNA, CNB, SLND, and ALND. Demographics and pathology features between the two groups were shown in **Table 1**.

Among 131 patients, 45 were deemed positive for metastasis and 86 were determined to be negative with CNB, whereas 38 were deemed positive for metastasis and 93 were determined to be negative by using FNAB (**Figure 2**). CNB was used to correctly identify seven axillae as positive for metastasis that were deemed negative by using FNAB. There were no positive FNAB results in axillae that were negative for metastasis with CNB. All patients underwent SLNB and these with biopsy-proved axillary metastases were assigned directly to ALND as the primary staging procedure.

The final histopathologic assessment indicated 50 (38.2%) of the 131 axillae studied had axillary LN metastases. Axillary US-guided CNB was used to correctly identify 45 (90.0%) of the 50 LN-positive axillae, whereas axillary US-guided FNAB was used to correctly identify 38 (76.0%,  $P < 0.001$ , **Figure 2**). There were no false-positive results. CNB netted 5 false-negative results, and FNAB resulted in 12 (**Table 2**), which is analogous to earlier studies and its outcomes (**Table 3**).

### Discussion

SLNB is an ideal criterion for axillary staging of the breast cancer. It is the first lymph node in a

## A comparative accuracy survey of FNA versus CNB

**Table 1.** Patient and tumor characteristics

Characteristic	Datum (%)
Total no. of patients	131
Age (y)	
Mean	53.1
Range	28-82
T category	
T1	74 (56.5)
T2	52 (39.7)
T3	4 (3.1)
T4	1 (0.8)
N category	
N0	81 (61.8)
N1	47 (35.9)
N2	1 (0.8)
N3	2 (1.5)
Stage	
1	81 (61.8)
2	46 (35.1)
3	4 (3.1)
4	0 (0.0)
Definitive histologic finding	
Ductal	120 (91.6)
Lobular	2 (1.5)
Mixed	6 (4.6)
Other	3 (2.3)
Grade	
1	38 (29.0)
2	71 (54.2)
3	22 (16.8)

regional basin to receive lymphatic drainage from the location of the primary tumor. In patients with positive ALNs, regional control is of great significance. ALND can accomplish both goals but it is recognized as the most morbid part of BC surgery. SLNB is an alternative to ALND for staging axilla in early breast cancer patients with minimum morbidity.

SLN biopsy is a trusty means for normal level standard level I/II axillary dissection. The key component of the lymphatic mapping is permitting the axillary nodes to assess. Lymph node metastasis occurs because of the presence of a regional metastatic disease. The SLN reflects the histopathological status of the whole axilla, therefore if we find the SNL is negative, which indicates that the nodal basin is negative as well. Morton's team tested the SNL biopsy with more than 500 melanoma patients in 1992.

They removed the sentinel node successful and along with the remaining regional lymph nodes [47]. The pathology of the sentinel node showed 99% accuracy of remaining regional nodal status. Other institutes authorized complete lymphadenectomy and histopathological examination, addition to follow-up to distinguish potential recurrences in undissected nodal basins shadowing a negative sentinel node biopsy [48-50]. Giuliano et al. [19] also showed that the experience with SNL biopsy for breast cancer, by using vital blue dye injection, it was proven by histopathological examination of the non-SLNs [51]. By using a technetium sulfur colloid injection and operating a handheld  $\gamma$ -probe for detection, Krag et al. [22] stated a primary series of breast cancer SLN biopsies.

Lately, several randomized clinical trials the SOUND [52] and NCT 01821768 [53] randomized amongst SNB and non-SNB following negative US/FNA findings including the early breast cancer patients. Such trials revealed the prerequisite for SNB in cases with negative ultrasound (US)-guided fine-needle aspiration cytology (FNA) of doubtful LNs. In these trials, many clinical tools were used to identify negative axillary node status. For example, the palpation of the axilla, the US imaging using or computed tomography (CT), or intervention with FNA for suspicious LNs. Hence, a significant thought for an exclusion of SNB or ALND differs on an extremely accurate preoperative staging for axillary LNs assessment.

Our study shows that core biopsy had greater sensitivity than FNA in detecting metastasis and it could approach statistical significance. Our study also reported three vital findings. Primary, the high accuracy rate of CNB between preoperative diagnostic axillary staging and final histological findings, representing the superiority of CNB over FNA. Following, the objective predictors of decisive pathological negative node status were related to the clinical characteristics of breast cancer and the investigative means used to assess the axillary LNs. Lastly, our study also found that CNB for axillary staging in terms of safety and simplicity was parallel to FNA procedure.

In this present experiment of US findings, we established there was abnormal LNs among the breast cancer patients. While a negative



## A comparative accuracy survey of FNA versus CNB

**Table 2.** Diagnostic performance of FNAB, and CNB for evaluation of axillary LN status

Measure	FNAB (%) (95% CI)	CNB (%) (95% CI)
Sensitivity	76.0 (38/50) [62.6, 85.7]	90.0 (45/50) [78.6, 95.7]
Specificity	100.0 (81/81) [95.5, 100]	100.0 (81/81) [95.5, 100]
Negative predictive value	100.0 [90.8, 100]	100.0 [87.1, 100]
Positive predictive value	87.1 [78.8, 92.5]	94.2 [87.1, 97.5]
Overall accuracy	90.8 (119/131) [84.7, 94.7]	96.2 (126/131) [91.4, 98.4]

**Table 3.** Review of previous studies

Study	Type of Biopsy	N	Sensitivity (%)	Specificity (%)
Krishnamurthy et al. [14]	FNA	106	86.4	100
Kuenen-Boumeester et al. [72]	FNA	183	57	96
Rao et al. [61]	FNA	22	75	100
Schiettecatte et al. [73]	FNA	148	50	100
Podkrajsek et al. [16]	FNA	49	84	91
Damera et al. [64]	CNB	54	42	100
Topal et al. [15]	CNB	39	90	100
Nori et al. [74]	CNB	31	91.6	100
Rautiainen et al. [75]	CNB	66	88.2	100
Topps et al. [76]	CNB	275	58.7	98.4

CNB result had a comparatively lower rate of positive LNs and a lower rate of non-SLN metastasis than patients with a negative FNA.

The precision of FNA and CNB contrasted with the last histological analysis of LNs was 90.8% in FNA while 96.2% in CNB. Precisely, sensitivity was 76.0% in FNA, 90.0% in CNB and positive predictive value of FNA 87.2% and CNB 94.2% as shown in **Table 2**.

Our experiment involved several skilled surgeons and involvement of a variety of sampling devices to stimulate actual clinical practice. Axillary node FNA is technically easy to perform for one skilled in image-guided procedures. However, to enable an optimal interpretation, the surgeons must acquire an aspirate that is both adequate in the amount of material and at the same time not overly bloody. It is undetermined why there were fewer false negative results when multiple FNA entries were attained, as the total number of needle excursions likely did not differ greatly. Perhaps the chance of accomplishing a better sample was improved by using different entry sites or attaining less blood mixed with cells from the node. The number of slides used, the actual number of excursions and length of procedure were not recorded, which could have affected the re-

sults. In some institutes, a pathologist is present when cytologic samples are acquired and can request extra sampling if the specimen is expected suboptimal; the presence of a pathologist at the period of sampling could have improved from FNA and CNB. In our hospital, immunostains may be used to aid in interpretation when FNA alone is performed. Our pathologists have extensive experience in cytopathology but in this study, there were no immunostains used in the cytologic evaluation; because the pathologists knew that additional tissue would be studied by core biopsy, a reason that may have decreased the sensitivity of FNA. Amongst patients with breast cancer, US-guided core needle biopsy of axillary lymph nodes can yield a high accuracy rate with no substantial complications.

The size of a best lymphatic tracer should be (in the range of 50-200 nm) big enough to remain in the sentinel lymph nodes, small enough to allow its entry into the lymphatic capillaries while long enough for proper SLN visualization and imaging without being transferred to the higher tier nodes early [54-56]. For the SLNs to be properly recognized during the surgical procedure, the Nano-sized carbon particles with a diameter of 150 nm pass easily through the lymphatic capillaries and also allow accumulation in the lymph nodes for the longer duration. In comparison, the molecules of blue dyes are pretty small (< 2 nm), allowing the easy shipping across the sentinel lymph nodes, which has the highest possibility of the false negative rate because of the rapid washing of the blue dye [57]. The carbon Nanoparticles have an important application clinically. Thus, it is far better to use carbon nanoparticles than the blue dye in SLN biopsy because it is preserved for a longer time in SLNs. The blue dyes quickly



## A comparative accuracy survey of FNA versus CNB

diffuse through SLNs and may be retained in the level II or even level III or even on non-sentinel lymph nodes instead of being retained in the true sentinel lymph nodes. As a result, during the biopsy of SLNs using the blue dye, there might be an incorrect diagnosis, leading to unnecessary excision of more nodes and a false-negative staging. Carbon nanoparticles are retained in the SLNs thus reducing the false negative detection. In comparison to the blue dye, Carbon nanoparticles detection is more reliable and convincing because the dye is more liable to last for a lengthier time [35]. We used both Carbon Nanoparticle suspension injection and radioisotope in our patients and it helped us to find accurate SLNs during FNA and CNB under  $\gamma$  probe followed by ultrasound which helped during surgery to locate SLN. Additionally, gamma probe has its radioactive content that provides the surgeon a sense of focus and allows detection of non-visible nodes. There is increasing evidence in the literature to support better results when both detection methods are combined, compared with the use of these techniques alone [28]. Cserni and associates [58] reported that combined technique has advantages like higher identification rate, higher accuracy level, and a lower false negative rate.

In our study core biopsy had no more morbidity than FNA, even with the largest gauge device. Use of a biopsy device with a nonthrow option should diminish the chance of vascular injury. Nevertheless, patients whose suspect node was immediately adjacent to a vessel or profound and difficult to access were not asked to participate in the study and hence were not subjected to core biopsy. Despite statistically significant difference observed in the number of patients reporting pain being greater during core than FNA, the majority of patients tolerated the pain equally well during both procedures, and we do not believe this should be a factor in deciding which procedure to perform. Both FNA and core biopsy were least sensitive when the node appearance was least abnormal. This can be due to difficulty in choosing the appropriate node for sampling or due to smaller metastatic deposits in the sampled node.

Limitations of our study included its small size, in particular, the small size of subgroups of needle types and number of samples obtained.

Although there may have been some selection bias due to excluding patients with nodes not suited to a core biopsy, the goal of the study was to compare the two methods when both were possible. In all cases, the core biopsy was performed after the FNA, with additional lidocaine, which may have minimized the pain associated with core biopsy. FNA was always performed first because of concern that core biopsy might cause sufficient bleeding to have to abort the second sampling procedure, but the bleeding was not a substantial problem. An additional limitation of our study was some of the false negative biopsy results can probably be accredited to a failure to identify the SLN under the US. Earlier reports have shown that the SLN was not always targeted at preoperative US-guided biopsy subsequently only 64-78% of the LNs that underwent CNB corresponded to the SLN removed at surgery [59, 60]. Previous studies reported that morphologically normal-appearing nodes had lymph node metastases with positivity ranging from 26 to 52% [61-64].

In our routine daily practice, we believe that the combined procedure helps to retain experience in the cytology of solid organs and provide maximum sensitivity and specificity. FNAB and CNB techniques should not be considered mutually exclusive, but as two different diagnostic modalities that complement one another [65-68]. The benefits of the combined procedures are summarized in **Table 4**. As shown by other investigators, the utilization of both aspirate smears and core tissue biopsy material are complementary and have added value compared to either one alone [65-67].

An earlier study which was held in 2016 included new primary breast cancer cases on the ipsilateral side that were subjected for the US-guided axillary biopsies in a two-year time duration with results compared to the decisive histopathology from SLNB or ANC. They were able to find the association for CNB but not statistically suggestive in favor of either method [69]. According to the latest review, it didn't report absolute superiority of CNB over FNAC while reporting the experiences of the cytopathologists to have a likely influence to report the differences in the procedures [70]. Undoubtedly, this explains that the operator's skills and techniques are likely to have an

# A comparative accuracy survey of FNA versus CNB

**Table 4.** Advantages of the combined approach FNA and CNB

---

Increases the accuracy of diagnosis, especially in small lesions
Provides more material for additional ancillary studies
Both FNAB and CNB are complementary to each other and allow better interpretation of morphology and architecture
Increases the sensitivity and the specificity of either approach alone
More convenient to the patient
More satisfaction for clinicians who are still hesitant to manage their patients based on cytological material alone
It builds greater experience in cytology for those pathologists who believe more in tissue diagnosis
It helps when there are very complex lesions, such as composite malignancies

---

important part. A retrospective study reported 69.1% sensitivity of CNB and specificity of 100% (n = 650) as an outcome, 33% of patients didn't undergo SLNB [71].

The main focus of our research was tissue sampling techniques guided by ultrasound hence we included, only consecutive cancer patients who underwent US scans which introduced a selection bias. To conclude, in cases of newly diagnosed invasive breast cancer patients when accurate preoperative staging of the axilla is needed. The CNB should be encouraged as the first line biopsy method as CNB is more sensitive than FNAB.

## Conclusion

In summary, this current study demonstrated that in the breast cancer patients, preoperative US-guided CNB biopsy of SLNs can get a high accuracy rate with no substantial complications than FNAC. Since many SLNs are situated in the lower axillary region, core needle biopsy of these nodes can be carried out very safely. Even for axillary lymph nodes located immediately adjacent to major vessels, core needle biopsy can be performed by choosing the approach with care and using a biopsy device with controllable needle action. It is extremely crucial to obtain sufficient samples, accurate targeting of the thickened cortex and visual assessment of the sample. A clear knowledge of anatomy and good skills for handling the needle are important for avoiding significant complications. Furthermore, studies would be beneficial to quantify the role of the operator's proficiency in accomplishing these investigations with patients undergoing US-guided CNB or FNA cytology.

## Acknowledgements

This study was funded by the Key Project of Science and Technology Innovation Team of

Zhejiang Province (2013TD10) and the National Natural Science Foundation of China (No. 81372380). We thank Dr. Shixu Lv, Dr. Jie You, Dr. Ye Lechi Ye, Dr. Yizuo Chen, Dr. Yili Zhou and Dr. Zhiqiang Ye for support.

## Disclosure of conflict of interest

None.

## Abbreviations

CNB, core needle biopsy; FNAC, fine needle aspiration cytology; CN, carbon Nanoparticle; US, ultrasound; ALND, axillary lymph node dissection; SLNB, sentinel lymph node biopsy; ALNs, axillary lymph nodes; BC, breast cancer.

**Address correspondence to:** Drs. Ouchen Wang and Xiaohua Zhang, Department of Thyroid and Breast Surgery, The First Affiliated Hospital of Wenzhou Medical University, Nanbai Xiang, Wenzhou 325000, Zhejiang, PR China. Tel: 0086-13957706099; E-mail: woc863@hotmail.com (OCW); Tel: 0086-13600671188; E-mail: oncology\_zhang@outlook.com (XHZ)

## References

- [1] Veronesi U, Paganelli G, Viale G, Luini A, Zurrada S, Galimberti V, Intra M, Veronesi P, Robertson C, Maisonneuve P, Renne G, De Cicco C, De Lucia F and Gennari R. A randomized comparison of sentinel-node biopsy with routine axillary dissection in breast cancer. *N Engl J Med* 2003; 349: 546-553.
- [2] Giuliano AE, Dale PS, Turner RR, Morton DL, Evans SW and Krasne DL. Improved axillary staging of breast cancer with sentinel lymphadenectomy. *Ann Surg* 1995; 222: 394-399; discussion 399-401.
- [3] Blanchard DK, Donohue JH, Reynolds C and Grant CS. Relapse and morbidity in patients undergoing sentinel lymph node biopsy alone or with axillary dissection for breast cancer. *Arch Surg* 2003; 138: 482-487; discussion 487-488.

## A comparative accuracy survey of FNA versus CNB

- [4] Ivens D, Hoe AL, Podd TJ, Hamilton CR, Taylor I and Royle GT. Assessment of morbidity from complete axillary dissection. *Br J Cancer* 1992; 66: 136-138.
- [5] Sener SF, Winchester DJ, Martz CH, Feldman JL, Cavanaugh JA, Winchester DP, Weigel B, Bonnefoi K, Kirby K and Morehead C. Lymphedema after sentinel lymphadenectomy for breast carcinoma. *Cancer* 2001; 92: 748-752.
- [6] Lucci A, McCall LM, Beitsch PD, Whitworth PW, Reintgen DS, Blumencranz PW, Leitch AM, Saha S, Hunt KK, Giuliano AE; American College of Surgeons Oncology Group. Surgical complications associated with sentinel lymph node dissection (SLND) plus axillary lymph node dissection compared with SLND alone in the American College of Surgeons Oncology Group Trial Z0011. *J Clin Oncol* 2007; 25: 3657-3663.
- [7] Burak WE, Hollenbeck ST, Zervos EE, Hock KL, Kemp LC and Young DC. Sentinel lymph node biopsy results in less postoperative morbidity compared with axillary lymph node dissection for breast cancer. *Am J Surg* 2002; 183: 23-27.
- [8] Haid A, Kuehn T, Konstantiniuk P, Koberle-Wuhrer R, Knauer M, Kreienberg R and Zimmermann G. Shoulder-arm morbidity following axillary dissection and sentinel node only biopsy for breast cancer. *Eur J Surg Oncol* 2002; 28: 705-710.
- [9] Pathmanathan N, Jones W, Salisbury E and Bilous M. Intraoperative imprint cytology of sentinel lymph nodes in breast cancer: initial experience and lessons learnt in establishing a new practice. *Pathology* 2006; 38: 321-327.
- [10] Tanis PJ, Boom RP, Koops HS, Faneyte IF, Peterse JL, Nieweg OE, Rutgers EJ, Tiebosch AT and Kroon BB. Frozen section investigation of the sentinel node in malignant melanoma and breast cancer. *Ann Surg Oncol* 2001; 8: 222-226.
- [11] Fisher B, Jeong JH, Anderson S, Bryant J, Fisher ER and Wolmark N. Twenty-five-year follow-up of a randomized trial comparing radical mastectomy, total mastectomy, and total mastectomy followed by irradiation. *N Engl J Med* 2002; 347: 567-575.
- [12] Goldhirsch A, Wood WC, Coates AS, Gelber RD, Thurlimann B, Senn HJ; Panel members. Strategies for subtypes—dealing with the diversity of breast cancer: highlights of the St. Gallen international expert consensus on the primary therapy of early breast cancer 2011. *Ann Oncol* 2011; 22: 1736-1747.
- [13] Carlson GW and Wood WC. Management of axillary lymph node metastasis in breast cancer: making progress. *JAMA* 2011; 305: 606-607.
- [14] Krishnamurthy S, Sneige N, Bedi DG, Edieken BS, Fornage BD, Kuerer HM, Singletary SE and Hunt KK. Role of ultrasound-guided fine-needle aspiration of indeterminate and suspicious axillary lymph nodes in the initial staging of breast carcinoma. *Cancer* 2002; 95: 982-988.
- [15] Topal U, Punar S, Tasdelen I and Adim SB. Role of ultrasound-guided core needle biopsy of axillary lymph nodes in the initial staging of breast carcinoma. *Eur J Radiol* 2005; 56: 382-385.
- [16] Podkrajsek M, Music MM, Kadivec M, Zgajnar J, Besic N, Pogacnik A and Hocevar M. Role of ultrasound in the preoperative staging of patients with breast cancer. *Eur Radiol* 2005; 15: 1044-1050.
- [17] Khan A, Sabel MS, Nees A, Diehl KM, Cimmino VM, Kleer CG, Schott AF, Hayes DF, Chang AE and Newman LA. Comprehensive axillary evaluation in neoadjuvant chemotherapy patients with ultrasonography and sentinel lymph node biopsy. *Ann Surg Oncol* 2005; 12: 697-704.
- [18] Sullivan KM, Dean A and Soe MM. OpenEpi: a web-based epidemiologic and statistical calculator for public health. *Public Health Rep* 2009; 124: 471-474.
- [19] Giuliano AE, Kirgan DM, Guenther JM and Morton DL. Lymphatic mapping and sentinel lymphadenectomy for breast cancer. *Ann Surg* 1994; 220: 391-398; discussion 398-401.
- [20] Giuliano AE. Sentinel lymphadenectomy in primary breast carcinoma: an alternative to routine axillary dissection. *J Surg Oncol* 1996; 62: 75-77.
- [21] Krag D, Weaver D, Ashikaga T, Moffat F, Klimberg VS, Shriver C, Feldman S, Kusminsky R, Gadd M, Kuhn J, Harlow S and Beitsch P. The sentinel node in breast cancer—a multicenter validation study. *N Engl J Med* 1998; 339: 941-946.
- [22] Krag DN, Weaver DL, Alex JC and Fairbank JT. Surgical resection and radiolocalization of the sentinel lymph node in breast cancer using a gamma probe. *Surg Oncol* 1993; 2: 335-339; discussion 340.
- [23] Veronesi U, Paganelli G, Galimberti V, Viale G, Zurrida S, Bedoni M, Costa A, de Cicco C, Geraghty JG, Luini A, Sacchini V and Veronesi P. Sentinel-node biopsy to avoid axillary dissection in breast cancer with clinically negative lymph-nodes. *Lancet* 1997; 349: 1864-1867.
- [24] Albertini JJ, Lyman GH, Cox C, Yeatman T, Balducci L, Ku N, Shivers S, Berman C, Wells K, Rapaport D, Shons A, Horton J, Greenberg H, Nicosia S, Clark R, Cantor A and Reintgen DS. Lymphatic mapping and sentinel node biopsy in the patient with breast cancer. *JAMA* 1996; 276: 1818-1822.
- [25] Morrow M, Rademaker AW, Bethke KP, Talamonti MS, Dawes LG, Clauson J and Hansen N. Learning sentinel node biopsy: results of a



## A comparative accuracy survey of FNA versus CNB

- prospective randomized trial of two techniques. *Surgery* 1999; 126: 714-720; discussion 720-712.
- [26] Noguchi M. Sentinel lymph node biopsy as an alternative to routine axillary lymph node dissection in breast cancer patients. *J Surg Oncol* 2001; 76: 144-156.
- [27] Cox CE, Bass SS, McCann CR, Ku NN, Berman C, Durand K, Bolano M, Wang J, Peltz E, Cox S, Salud C, Reintgen DS and Lyman GH. Lymphatic mapping and sentinel lymph node biopsy in patients with breast cancer. *Annu Rev Med* 2000; 51: 525-542.
- [28] Cody HS 3rd, Fey J, Akhurst T, Fazzari M, Mazumdar M, Yeung H, Yeh SD and Borgen PI. Complementarity of blue dye and isotope in sentinel node localization for breast cancer: univariate and multivariate analysis of 966 procedures. *Ann Surg Oncol* 2001; 8: 13-19.
- [29] Noguchi M, Motomura K, Imoto S, Miyauchi M, Sato K, Iwata H, Ohta M, Kurosumi M and Tsugawa K. A multicenter validation study of sentinel lymph node biopsy by the Japanese Breast Cancer Society. *Breast Cancer Res Treat* 2000; 63: 31-40.
- [30] Cody HS 3rd. Sentinel lymph node mapping in breast cancer. *Breast Cancer* 1999; 6: 13-22.
- [31] Miltenburg DM, Miller C, Karamlou TB and Brunnicardi FC. Meta-analysis of sentinel lymph node biopsy in breast cancer. *J Surg Res* 1999; 84: 138-142.
- [32] Strand SE and Persson BR. Quantitative lymphoscintigraphy I: basic concepts for optimal uptake of radiocolloids in the parasternal lymph nodes of rabbits. *J Nucl Med* 1979; 20: 1038-1046.
- [33] Keshtgar MR and Ell PJ. Sentinel lymph node detection and imaging. *Eur J Nucl Med* 1999; 26: 57-67.
- [34] Gulec SA, Moffat FL, Carroll RG and Krag DN. Gamma probe guided sentinel node biopsy in breast cancer. *Q J Nucl Med* 1997; 41: 251-261.
- [35] Wu X, Lin Q, Chen G, Lu J, Zeng Y, Chen X and Yan J. Sentinel lymph node detection using carbon nanoparticles in patients with early breast cancer. *PLoS One* 2015; 10: e0135714.
- [36] Yuan SH, Xiong Y, Wei M, Yan XJ, Zhang HZ, Zeng YX and Liang LZ. Sentinel lymph node detection using methylene blue in patients with early stage cervical cancer. *Gynecol Oncol* 2007; 106: 147-152.
- [37] Zhu J, Tian W, Xu Z, Jiang K, Sun H, Wang P, Huang T, Guo Z, Zhang H, Liu S, Zhang Y, Cheng R, Zhao D, Fan Y, Li X, Qin J, Zhao W and Su A. Expert consensus statement on parathyroid protection in thyroidectomy. *Ann Transl Med* 2015; 3: 230.
- [38] BeruBe K, Balharry D, Sexton K, Koshy L and Jones T. Combustion-derived nanoparticles: mechanisms of pulmonary toxicity. *Clin Exp Pharmacol Physiol* 2007; 34: 1044-1050.
- [39] Paganelli G, De Cicco C, Cremonesi M, Prisco G, Calza P, Luini A, Zucali P and Veronesi U. Optimized sentinel node scintigraphy in breast cancer. *Q J Nucl Med* 1998; 42: 49-53.
- [40] Pijpers R, Meijer S, Hoekstra OS, Collet GJ, Comans EF, Boom RP, van Diest PJ and Teule GJ. Impact of lymphoscintigraphy on sentinel node identification with technetium-99m-colloidal albumin in breast cancer. *J Nucl Med* 1997; 38: 366-368.
- [41] Schneebaum S, Stadler J, Cohen M, Yaniv D, Baron J and Skornick Y. Gamma probe-guided sentinel node biopsy—optimal timing for injection. *Eur J Surg Oncol* 1998; 24: 515-519.
- [42] Uren RF, Howman-Giles RB, Thompson JF, Malouf D, Ramsey-Stewart G, Niesche FW and Renwick SB. Mammary lymphoscintigraphy in breast cancer. *J Nucl Med* 1995; 36: 1775-1780.
- [43] Borgstein PJ, Pijpers R, Comans EF, van Diest PJ, Boom RP and Meijer S. Sentinel lymph node biopsy in breast cancer: guidelines and pitfalls of lymphoscintigraphy and gamma probe detection. *J Am Coll Surg* 1998; 186: 275-283.
- [44] Winchester DJ, Sener SF, Winchester DP, Perlman RM, Goldschmidt RA, Motykie G, Martz CH, Rabbitt SL, Brenin D, Stull MA and Moulthrop JM. Sentinel lymphadenectomy for breast cancer: experience with 180 consecutive patients: efficacy of filtered technetium 99m sulphur colloid with overnight migration time. *J Am Coll Surg* 1999; 188: 597-603.
- [45] Yeung HW, Cody IH, Turlakow A, Riedel ER, Fey J, Gonen M, Nunez R, Yeh SD and Larson SM. Lymphoscintigraphy and sentinel node localization in breast cancer patients: a comparison between 1-day and 2-day protocols. *J Nucl Med* 2001; 42: 420-423.
- [46] Veronesi U, Paganelli G, Viale G, Galimberti V, Luini A, Zurrada S, Robertson C, Sacchini V, Veronesi P, Orvieto E, De Cicco C, Intra M, Tosi G and Scarpa D. Sentinel lymph node biopsy and axillary dissection in breast cancer: results in a large series. *J Natl Cancer Inst* 1999; 91: 368-373.
- [47] Morton DL, Wen DR, Wong JH, Economou JS, Cagle LA, Storm FK, Foshag LJ and Cochran AJ. Technical details of intraoperative lymphatic mapping for early stage melanoma. *Arch Surg* 1992; 127: 392-399.
- [48] Gershenwald JE, Colome MI, Lee JE, Mansfield PF, Tseng C, Lee JJ, Balch CM and Ross MI. Patterns of recurrence following a negative senti-

## A comparative accuracy survey of FNA versus CNB

- nel lymph node biopsy in 243 patients with stage I or II melanoma. *J Clin Oncol* 1998; 16: 2253-2260.
- [49] Morton DL, Wen DR, Foshag LJ, Essner R and Cochran A. Intraoperative lymphatic mapping and selective cervical lymphadenectomy for early-stage melanomas of the head and neck. *J Clin Oncol* 1993; 11: 1751-1756.
- [50] Ramnath EM, Kamath D, Brobeil A, Stall A, Kamath VV, Cruse CW, Glass F, Messina J, Fenske N, Berman C, Ross ML, Cantor A, Cuthbertson D and Reintgen DS. Lymphatic mapping for melanoma: long-term results of regional nodal sampling with radioguided surgery. *Cancer Control* 1997; 4: 483-490.
- [51] Turner RR, Ollila DW, Krasne DL and Giuliano AE. Histopathologic validation of the sentinel lymph node hypothesis for breast carcinoma. *Ann Surg* 1997; 226: 271-276; discussion 276-278.
- [52] Gentilini O and Veronesi U. Abandoning sentinel lymph node biopsy in early breast cancer? A new trial in progress at the European Institute of Oncology of Milan (SOUND: sentinel node vs observation after axillary UltraSound). *Breast* 2012; 21: 678-681.
- [53] Cyr AE, Tucker N, Ademuyiwa F, Margenthaler JA, Aft RL, Eberlein TJ, Appleton CM, Zoberi I, Thomas MA, Gao F and Gillanders WE. Successful completion of the pilot phase of a randomized controlled trial comparing sentinel lymph node biopsy to no further axillary staging in patients with clinical T1-T2 n0 breast cancer and normal axillary ultrasound. *J Am Coll Surg* 2016; 223: 399-407.
- [54] Cong L, Takeda M, Hamanaka Y, Gonda K, Watanabe M, Kumasaka M, Kobayashi Y, Kobayashi M and Ohuchi N. Uniform silica coated fluorescent nanoparticles: synthetic method, improved light stability and application to visualize lymph network tracer. *PLoS One* 2010; 5: e13167.
- [55] Johnson L, Charles-Edwards G and Douek M. Nanoparticles in sentinel lymph node assessment in breast cancer. *Cancers (Basel)* 2010; 2: 1884-1894.
- [56] Cousins A, Thompson SK, Wedding AB and Thierry B. Clinical relevance of novel imaging technologies for sentinel lymph node identification and staging. *Biotechnol Adv* 2014; 32: 269-279.
- [57] Sohrabnezhad S, Pourahmad A and Sadjadi MA. New methylene blue incorporated in mordenite zeolite as humidity sensor material. *Materials Letters* 2007; 61: 2311-2314.
- [58] Cserni G, Rajtar M, Boross G, Sinko M, Svebis M and Baltas B. Comparison of vital dye-guided lymphatic mapping and dye plus gamma probe-guided sentinel node biopsy in breast cancer. *World J Surg* 2002; 26: 592-597.
- [59] Britton PD, Goud A, Godward S, Barter S, Freeman A, Gaskarth M, Rajan P, Sinnatamby R, Slattery J, Provenzano E, O'Donovan M, Pinder S, Benson JR, Forouhi P and Wishart GC. Use of ultrasound-guided axillary node core biopsy in staging of early breast cancer. *Eur Radiol* 2009; 19: 561-569.
- [60] Britton PD, Provenzano E, Barter S, Gaskarth M, Goud A, Moyle P, Sinnatamby R, Wallis M, Benson JR, Forouhi P and Wishart GC. Ultrasound guided percutaneous axillary lymph node core biopsy: how often is the sentinel lymph node being biopsied? *Breast* 2009; 18: 13-16.
- [61] Rao R, Lilley L, Andrews V, Radford L and Ulissey M. Axillary staging by percutaneous biopsy: sensitivity of fine-needle aspiration versus core needle biopsy. *Ann Surg Oncol* 2009; 16: 1170-1175.
- [62] Vassallo P, Wernecke K, Roos N and Peters PE. Differentiation of benign from malignant superficial lymphadenopathy: the role of high-resolution US. *Radiology* 1992; 183: 215-220.
- [63] van Rijk MC, Deurloo EE, Nieweg OE, Gilhuijs KG, Peterse JL, Rutgers EJ, Kroger R and Kroon BB. Ultrasonography and fine-needle aspiration cytology can spare breast cancer patients unnecessary sentinel lymph node biopsy. *Ann Surg Oncol* 2006; 13: 31-35.
- [64] Damera A, Evans AJ, Cornford EJ, Wilson AR, Burrell HC, James JJ, Pinder SE, Ellis IO, Lee AH and Macmillan RD. Diagnosis of axillary nodal metastases by ultrasound-guided core biopsy in primary operable breast cancer. *Br J Cancer* 2003; 89: 1310-1313.
- [65] Kurita T, Tsuchiya S, Watarai Y, Yamamoto Y, Harada O, Yanagihara K, Iida S, Yamashita K, Haga SS and Uchida E. Roles of fine-needle aspiration and core needle biopsy in the diagnosis of breast cancer. *Breast Cancer* 2012; 19: 23-29.
- [66] Garg S, Mohan H, Bal A, Attri AK and Kochhar S. A comparative analysis of core needle biopsy and fine-needle aspiration cytology in the evaluation of palpable and mammographically detected suspicious breast lesions. *Diagn Cytopathol* 2007; 35: 681-689.
- [67] Hatada T, Ishii H, Ichii S, Okada K, Fujiwara Y and Yamamura T. Diagnostic value of ultrasound-guided fine-needle aspiration biopsy, core-needle biopsy, and evaluation of combined use in the diagnosis of breast lesions. *J Am Coll Surg* 2000; 190: 299-303.
- [68] Kocjan G, Bourgain C, Fassina A, Hagmar B, Herbert A, Kapila K, Kardum-Skelin I, Kloboves-Prevodnik V, Krishnamurthy S, Koutselini H, Majak B, Olszewski W, Onal B, Pohar-Marinsek Z, Shabalova I, Smith J, Tani E, Vielh P, Wiener H, Schenck U and Schmitt F. The role of breast FNAC in diagnosis and clinical manage-

## A comparative accuracy survey of FNA versus CNB

- ment: a survey of current practice. *Cytopathology* 2008; 19: 271-278.
- [69] Zosimas D, Lykoudis PM and Vashisht R. Pre-operative ultrasound guided percutaneous axillary biopsy in breast cancer patients: fine needle aspiration cytology versus core biopsy. *Ann Ital Chir* 2016; 87: 509-516.
- [70] Mitra S and Dey P. Fine-needle aspiration and core biopsy in the diagnosis of breast lesions: a comparison and review of the literature. *Cytojournal* 2016; 13: 18.
- [71] Garcia-Ortega MJ, Benito MA, Vahamonde EF, Torres PR, Velasco AB and Paredes MM. Pre-treatment axillary ultrasonography and core biopsy in patients with suspected breast cancer: diagnostic accuracy and impact on management. *Eur J Radiol* 2011; 79: 64-72.
- [72] Kuenen-Boumeester V, Menke-Pluymers M, de Kanter AY, Obdeijn IM, Urich D and Van Der Kwast TH. Ultrasound-guided fine needle aspiration cytology of axillary lymph nodes in breast cancer patients. A preoperative staging procedure. *Eur J Cancer* 2003; 39: 170-174.
- [73] Schiettecatte A, Bourgain C, Breucq C, Buls N, De Wilde V and de Mey J. Initial axillary staging of breast cancer using ultrasound-guided fine needle aspiration: a liquid-based cytology study. *Cytopathology* 2011; 22: 30-35.
- [74] Nori J, Vanzi E, Bazzocchi M, Bufalini FN, Distantante V, Branconi F and Susini T. Role of axillary ultrasound examination in the selection of breast cancer patients for sentinel node biopsy. *Am J Surg* 2007; 193: 16-20.
- [75] Rautiainen S, Masarwah A, Sudah M, Sutela A, Pelkonen O, Joukainen S, Sironen R, Karja V and Vanninen R. Axillary lymph node biopsy in newly diagnosed invasive breast cancer: comparative accuracy of fine-needle aspiration biopsy versus core-needle biopsy. *Radiology* 2013; 269: 54-60.
- [76] Topps A, Clay V, Absar M, Howe M, Lim Y, Johnson R and Bundred N. The sensitivity of pre-operative axillary staging in breast cancer: comparison of invasive lobular and ductal carcinoma. *Eur J Surg Oncol* 2014; 40: 813-817.