

Original Article

Tomographic analysis of the temporomandibular joint in patients with arthritis: a case of disease translation in Yucatan, Mexico

Celia Mendiburu-Zavala¹, María-Elena Camargo-Riqué¹, Ricardo Peñaloza-Cuevas¹, Rubén Cárdenas-Erosa¹, Miguel Lara-Flores², Víctor M Castaño²

¹Facultad de Odontología, Universidad Autónoma de Yucatán, México; ²Universidad Nacional Autónoma de México, México

Received December 15, 2016; Accepted May 5, 2017; Epub January 15, 2019; Published January 30, 2019

Abstract: Computed tomography imaging of the temporomandibular joint was carried out in 22 previously-diagnosed arthritis patients (3 men, 19 women). This descriptive, cross-sectional observational, qualitative study allowed to characterize the type of condylar morphology condition, the space between temporomandibular joint, the erosion of the cortical and osteophytes formation. The joint characteristics found were cortical erosion, osteophytes and decrease of joint space, which reveals, for the first time in the literature, a correlation between arthritis and temporomandibular joint disease.

Keywords: Temporomandibular joint, arthritis, computed tomography

Introduction

The most frequently occurring inflammatory rheumatic diseases in the human population, mostly amongst young adults, are rheumatoid arthritis (RA), ankylosing spondylitis (AS) and drop. Indeed, the prevalence of rheumatoid arthritis has increased worldwide, being, in the specific case of Mexico from 0.3% up to 1% [1].

The disabilities produced by these diseases directly affect the quality of life of the patients, their working capacity and their ability for proper social functioning. According to data from the Mexican Social Security Institute, the dorsopathies and astrosis are the main causes for the external consultation in the first level medical units, consistently representing the second leading causes for disability pensions. The intensive use of health services due to musculoskeletal diseases, represent as significant impact on the economy and society of a country, either through direct costs (treatment of the disease itself) or indirect costs (decrease in productivity) [2].

The Temporomandibular Joint (TMJ), can be affected by rheumatoid arthritis (RA), osteoar-

thritis (OA), juvenile idiopathic arthritis (JIA) and anquilosant spondilitis (AS). The TMJ is a ginglymoartrodial joint [3, 4], consisting of the mandibular condyle (MC), mandibular fossa and articular eminence of temporal bone of the skull base. The MC is in perpendicular position with respect to the mandibular ramus and symmetrically positioned within the mandibular fossa. The joint space is uniform [5]. This sinovial joint is different to the rest of the body, because the TMJ surface is coated with fibrocartilage, instead of the hyaline cartilage [3, 4]. Its growth is central, requiring two joints [4]. Its location is under the fibrocartilage of the MC, and this is vulnerable to inflammatory damage. The destruction of the fibrocartilage caused by the OA, can produce a limitation of mandibular development and growth [6].

Temporomandibular disorders (TMD) are rather common, affecting, at some point of their lifespan, to the 28% of the population, through a heterogeneous group of disorders, which are usually classified into myogenic and arthrogenos, although often a combination of both. The joint causes of the TMD include internal degeneration of the articular disc, degenerative and

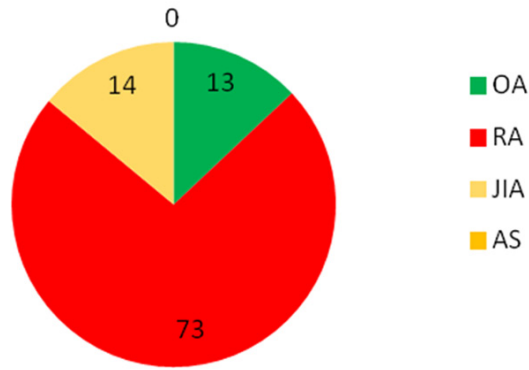


Figure 1. Types of arthritis present in the 22 subjects studied. Merida, Yucatan, Mexico. 2015-2016. Source: measuring instrument.

inflammatory arthropathy and, less frequently, ankylosis and neoplastic conditions [5, 7].

Accordingly, conventional radiography, computed tomography (CT), magnetic resonance imaging (MRI), and ultrasound, are routinely and successfully used for detection of secondary resorption of the MC in arthritis [8]. The CT can provide information beyond the two-dimensional images obtained by radiographic methods. The three-dimensional images offered by the CT, allow to clarify the relationship between the symptoms of the TMD and skeletal anomalies. Also CT helps to detect bone destruction, which cannot be observed by conventional radiography methods. This information may guide the diagnosis of the TMD [9], for CT, can detect alterations on soft and hard tissue, providing a detailed imaging of the temporal bone and skull base. The axial section is most appropriate to identify the symmetry between condyles on anterior and medial-lateral aspects. This allows measuring the actual dimensions of the condyles. The sagittal image is best to assess the relationship condyle-fossa. Mandibular fossa depth can be determined by this technique, as well [7].

The American Academy of Orofacial Pain divides the TMD into congenital and developmental disorders, dislocation, inflammatory conditions, arthritis, ankylosis and fracture. This classification bears similarity to that of joint disorders, but the joint surface of TMJ is covered by fibrous connective tissue, rather than hyaline [10]. The bone erosion is often associated to disc displacement, mainly affecting the MC. Less frequently, the erosions in TMJ are part of the any inflammatory system

arthropathy, like in juvenile chronic arthritis, RA, AS and psoriatic arthritis [11].

Based on computed tomography cone beam (CTCB) images, the bone changes in MC are classified, according to Koyama [12] as:

- a) Type N: no proliferation or thinning of the cortical surface of the condyle, showing typical morphology.
- b) Type F: contour of the anterior and/or posterior-superior portion of the MC flattened.
- c) Type E: change in proliferation or partial hypodense with or without irregularities on the cortical surface of the MC.
- d) Type D: contour deformity of the MC, as pointed surface without proliferation or partial hypodense in condylar surface.
- e) Type S: combination of type D and E.

Bone changes in glenoid fossa are classified as “positives” with presence of flattening, erosion and/or sclerosis in any of the TMJs, or as “negative” if the glenoid fossa is normal in both TMJs. The changes in joint spaces are classified as “positives” in the presence of deviation of joint space, including increase, decrease or bone contact between the head of the MC and the mandibular fossa at any TMJ, or “negative”, if the joint space was normal in both TMJs [13].

Accordingly, the objective of this present study was to correlate the computed tomography imaging characteristics of the temporomandibular joint of in patients diagnosed with arthritis, as an example of disease methodologies translation.

Materials and methods

The sampling universe of this descriptive, transversal and observational study consisted of patients from the rehabilitation clinic of the School of Dentistry at the University of Yucatán, México. The sample size and inclusion criteria were: 3 male and 19 female patients, who were previously diagnosed with some type of arthritis, and who agreed to participate voluntarily, after being carefully informed, by signature or fingerprint on the corresponding control card. The study variables were: sex, age, type of arthritis, radiological characteristics, degree of affection of the condylar morphology, TMJ

Temporomandibular joint in patients with arthritis

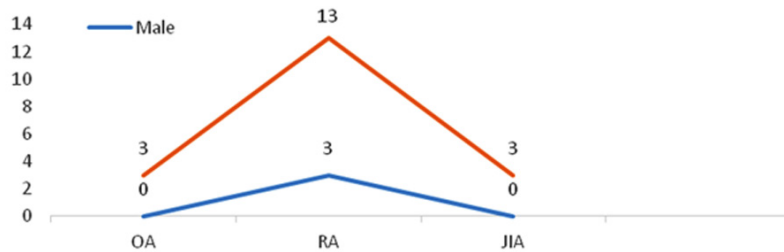


Figure 2. Types of arthritis by sex of 22 subjects studied. Merida, Yucatan, Mexico. 2015-2016. Source: measuring instrument.

space, cortical erosion and formation of osteophytes [12]. Patients with any type of neurological disease were excluded. In case of minors, or persons with different capacities, the parent's or tutor's consent was asked for their voluntary participation in the present study.

The patient was informed that the CT would had no cost for her/him, as well as on the nature of the study, the time and purpose of the investigation, the "Cone Beam" method details (which only takes 12 s). A lead apron, according to the Official Mexican Standard # 229 NOM-229-SSA1-2002 SEGOB/Health Secretary [14] for radiological protection was supplied in each case. Also, all potential inconveniences and to be reasonably expected were detailed to all subjects of the study, as well as the benefits of it.

A questionnaire, through a direct interview (or with parents or tutors in the cases of minors), that included demographic and personal data (age, sex, telephone, address, etc.), and questions on their disease and/or health status, was applied to each person. The CT were obtained ensuring the maximum safety, while observing the images of the TMJ, to verify any morphological or degenerative change, osteophytes, bone cysts, etc. All data obtained were added in the research card and analyzed and interpreted by descriptive statistics, including mean value, standard deviation and single correlation among variables.

Results

As for the types of arthritis, it was determined that no patient had AE, and RA was the most prevalent (**Figure 1**). All types of arthritis were more common in women than in men; the most frequent was the RA and this affected 6 times more women than men (**Figure 2**). The most

common affectations were cortical erosion, followed by osteophytes, which occurred mostly in the bilateral subcortical areas and observed as decompositions and irregular surfaces (**Table 1**).

As for the degree of the erosion MC with CBCT, according to the Koyama criteria (34), it was found that bilateral involvement of the MCs was mostly present in OA and JIA. The most frequent degree was 5, indicating severe erosion of both MC, as changes in the structure of the glenoid fossa. In the RMC, the most common grade was 5 and grade 2 in the LMC (**Table 2**).

The MC erosion was present in all patients with different types of arthritis, affecting both MCs, more frequently in the case of RA and unilaterally in JIA and OA (**Figure 3**). **Figures 4-8** show the changes of the temporomandibular joint in the patients with arthritis.

Discussion

A previous study in the State of Yucatan, Mexico on patients with arthritis [15] found that the prevalence OA was 5.8% and 4.7% of RA. This present investigation, revealed that RA had a prevalence of 72.72% and OA 13.63% because patients who took part in the study group had been already diagnosed with some type of arthritis, whereas the above study included only a rural community with a heterogeneous group of subjects, where healthy subjects and arthritis patients could not be distinguished.

A more recent study reports that the RA was identified as the third in prevalence in different types of arthritis [16], which does not agree with our findings, where the RA was the first in prevalence.

A study of Polymorphism in a Mexican population with rheumatoid arthritis and osteoporosis [1] found that the prevalence of RA in Mexican adult population is of 1%, being more common in women (2 to 3 with respect every affected man). However, this could not compared with the present study, since most patients attended by the clinic of restorative dentistry where we performed the analysis, are mostly women.

Temporomandibular joint in patients with arthritis

Table 1. TMJ imaging characteristics in different types of the arthritis of the 22 subjects studied. Merida, Yucatan, Mexico. 2015-2016

| Pathology | Type of arthritis | | | | Place | |
|---------------------------|-------------------|------------|-------------|-------------|-------------|------------|
| | RA n = (%) | OA n = (%) | JIA n = (%) | RMC n = (%) | LMC n = (%) | B n = (%) |
| Cortical erosion | 14 (63.63) | 3 (13.63) | 3 (13.63) | 2 (9.09) | 3 (13.63) | 15 (68.18) |
| Osteophytes | 14 (63.63) | 3 (13.63) | 3 (13.63) | 2 (9.09) | 5 (22.72) | 13 (59.09) |
| Subcortical decomposition | 11 (50) | 3 (13.63) | 3 (13.63) | 3 (13.63) | 6 (27.27) | 9 (40.90) |
| Irregular surface | 13 (59.09) | 3 (13.63) | 3 (13.63) | 2 (9.09) | 4 (18.18) | 13 (59.09) |

RA: Rheumatoid arthritis; OA: Osteoarthritis; RMC: Right mandibular condyle; LMC: Left mandibular condyle; B: Bilateral. Source: Measuring instrument and TC.

Table 2. Degree of bone involvement in the mandibular condyle according Koyama, in different types of arthritis of the 22 subjects studied. Mérida, Yucatan, Mexico. 2015-2016. Source: Measuring instrument

| Condyle affected | Degree of involvement | | | | |
|------------------|-----------------------|---|---|---|----|
| | 1 | 2 | 3 | 4 | 5 |
| LMC | 0 | 1 | 0 | 4 | 4 |
| RMC | 1 | 4 | 1 | 1 | 2 |
| Bilateral | 1 | 3 | 0 | 2 | 7 |
| Total | 2 | 8 | 1 | 7 | 13 |

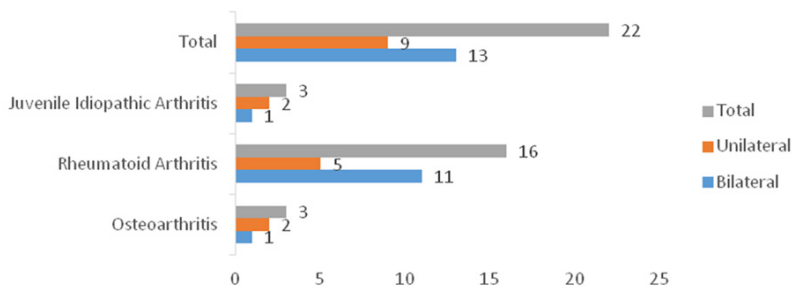


Figure 3. Presence of erosion in the mandibular condyle in different types of arthritis of the 22 subjects studied. Merida, Yucatan, Mexico. 2015-2016. Source: Measuring instrument.

A 2010 study [6] found that the TMJ affected 43-70% of the cases. In this present research, it was found that the 100% of JIA patients had some degree of involvement in the TMJ imagenological, probably due to the small number of patients in the sample. Several studies have correlated the involvement of the TMJ in patients with JIA [17], in which arthritis was unilateral in 26% of cases and 74% bilateral. This is at odds with the results obtained in this present study, where 100% showed erosion in cortical, osteophytes with irregular surface bilaterally, although the subcortical decomposition was only present in the two TMJs in 66.66% of

the subjects studied and in 33.33% condylar involvement was unilaterally found.

An Indian investigation on OA patients [18], found that the prevalence is higher in women (70%) and found that radiographic findings are flattening the front of the MC, decreased inclination of the temporal eminence and osteophytes. This is consistent with the results obtained in this present study, in which patients with OA presented osteophytes, cortical erosion, decomposition of subcortical bone and irregular surface, although unlike [18], these features were presented in 100% of the population and the prevalence in women it was also of a 100%. In addition, the results were similar to other

reports [19], where they found the same characteristics in a bearing case with OA and where the use of CTCB was suggested due to greater accuracy in detecting bone changes.

Conclusions

Our results show the effect of arthritis on the TMJ that, despite not being one of the joints with the highest percentage of degeneration, can cause difficulties for the mouth opening mechanism, pain, muscle stiffness and, therefore, masticatory deficiency, which directly affects nutrition and general health of the patient.

Temporomandibular joint in patients with arthritis

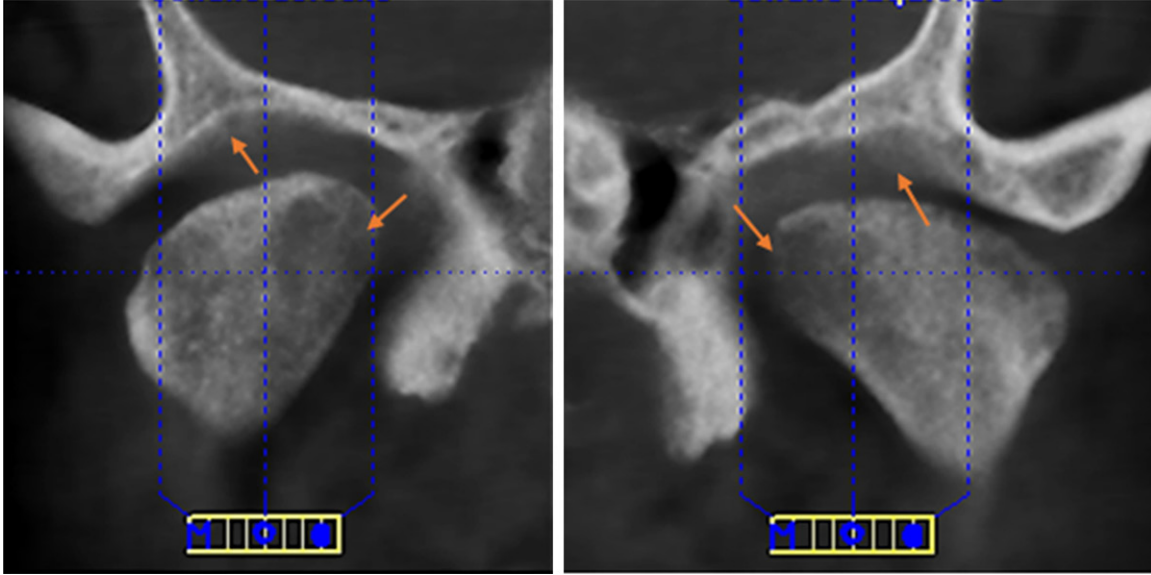


Figure 4. CT images of Male 60 years old. Left hand side: right condyle. Right hand side: left condyle. Observe the erosion in both temporalis.

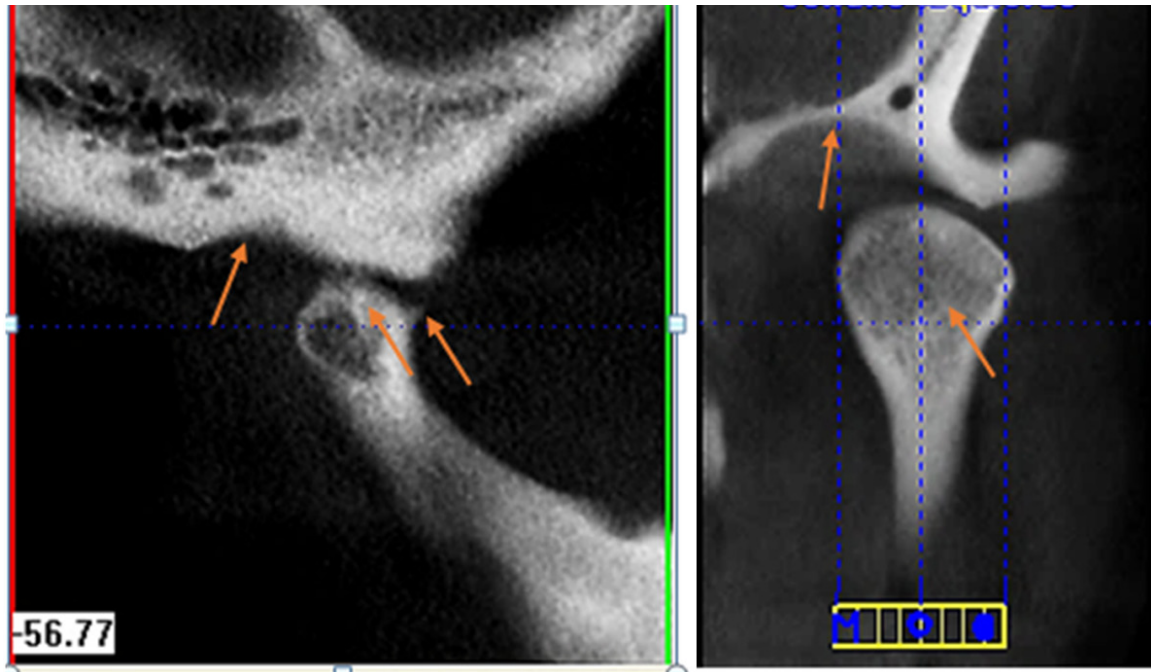


Figure 5. CT images of Female 56 years old. Left hand side: right condyle. Right hand side: left condyle. Observe the erosion in both temporalis. Flattening condyle and temporal law. Osteophyte in right condyle. Osteophytes in temporal and left condyle.

The simple methodology presented in this study show how it is possible to translate the procedures of a standard odontological treatment to the diagnosis of potential arthritis, without more sophisticated, dedicated equip-

ment. The use of the CTCB is only justified for a more accurate diagnosis due to its three-dimensional images where we can see more detail of the affected joint surfaces. It also requires less time of exposure to radiation.

Temporomandibular joint in patients with arthritis

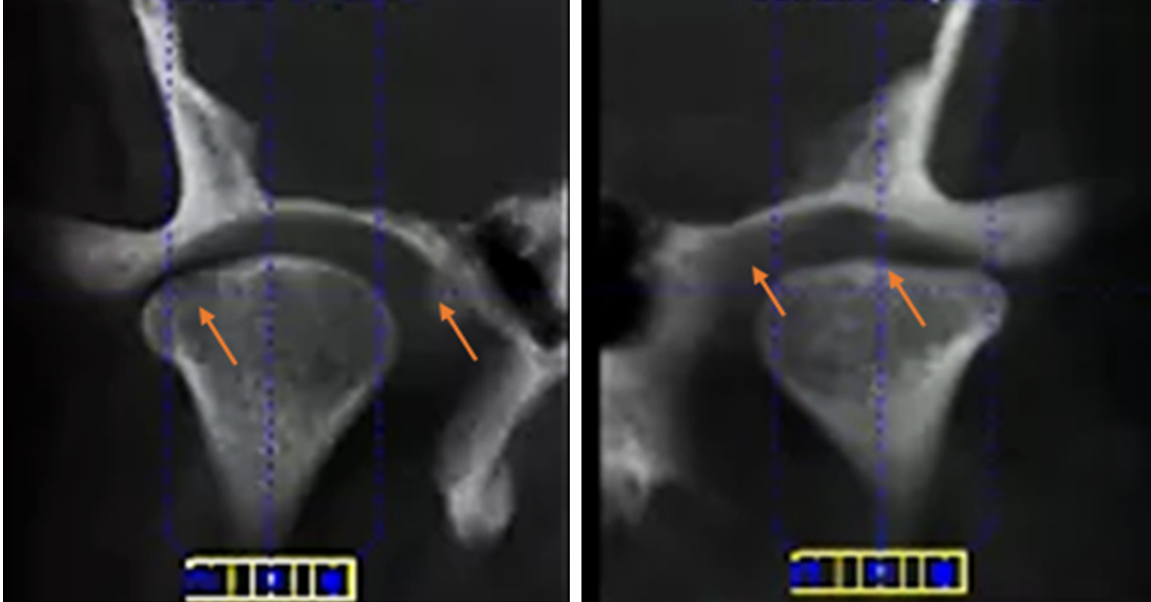


Figure 6. CT images of Female 48 years old. Left hand side: right condyle. Right hand side: left condyle. Observe the erosion in both temporalis. Bone loss in cortical bone on the right side, osteophytes on the right temporal. The left condyle is flattened and with temporal erosion.

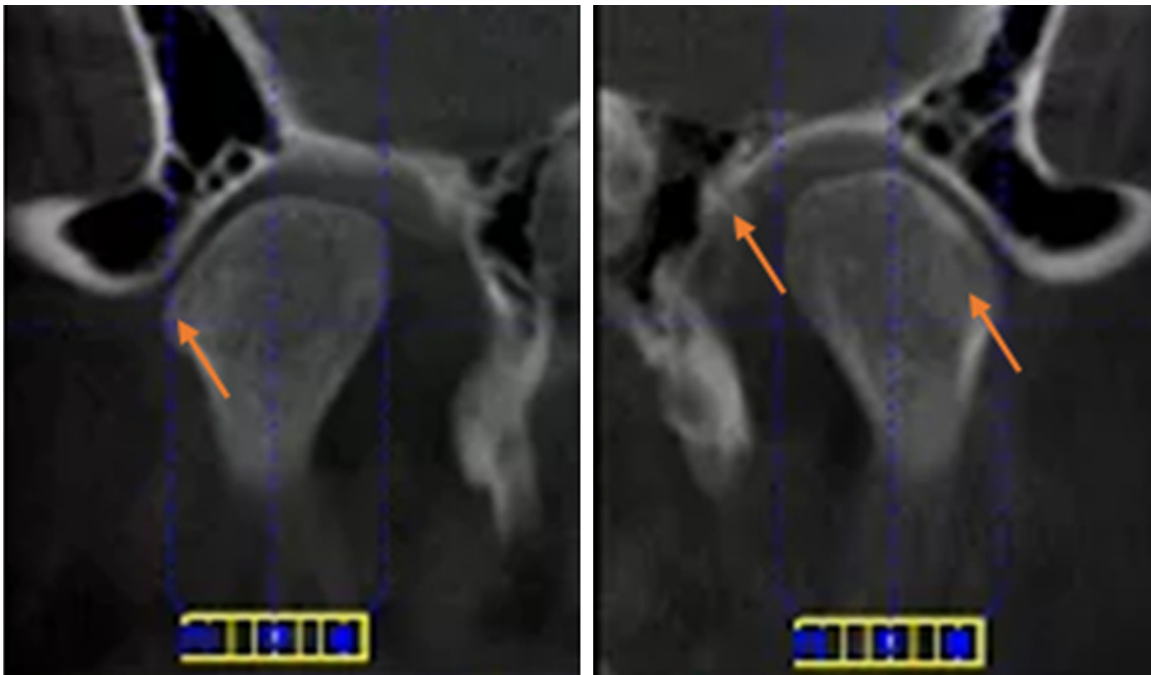


Figure 7. CT images of Female 52 years old. Left hand side: right condyle. Right hand side: left condyle. Osteophyte in the right condyle. Condylar erosion and bone erosion on left temporal.

By observing the anatomical surfaces affected by different types of arthritis, it is feasible to guide the patient to an oral rehabilitation, avoiding further degeneration and long term effects.

Acknowledgements

This research was funded completely by the Universidad Autonoma de Yucatán.

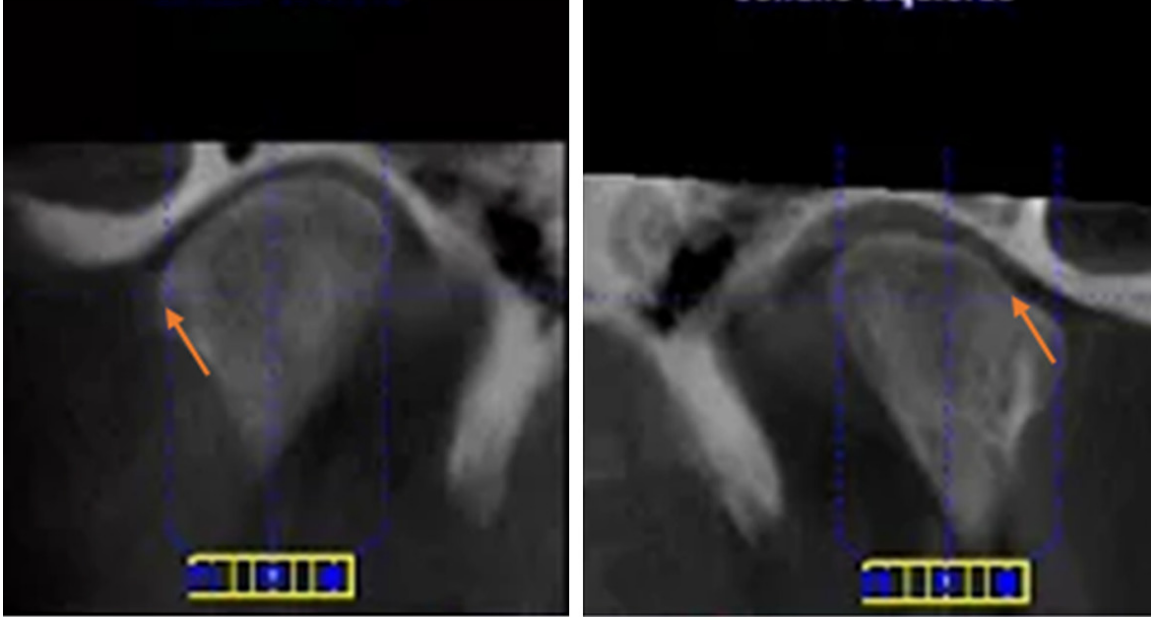


Figure 8. CT images of Male 77 years old. Left hand side: right condyle. Right hand side: left condyle. Left temporal bone and condyle erosion. Right condyle erosion.

All the authors agree on this publication.

Disclosure of conflict of interest

None.

Authors' contribution

CEMZ, MLF and VMC: data analysis and preparation of manuscript; CEMZ, RPC, MECR and RCE: experimental and clinical experiments; CEMZ and VMC: experimental design.

Address correspondence to: Celia Mendiburu-Zavala, Facultad de Odontología, Universidad Autónoma de Yucatán, Calle 25 No, 84 Fracc. Loma Bonita, Xcumpich, Merida 972015, Yucatan, Mexico. Tel: (521) 9992-92-31-84; E-mail: cel_mendi@hotmail.com; Victor M Castaño, Universidad Nacional Autónoma de México, México. E-mail: vmcastano@unam.mx

References

[1] Zavala-Cerna MG, Moran-Moguel MC, Cornejo-Toledo JA, Gonzalez-Montoya NG, Sanchez-Corona J, Salazar-Paramo M, Nava-Zavala AH, Aguilar-Chavez EA, Alcaraz-Lopez MF, Gonzalez-Sanchez AG, Gonzalez-Lopez L, Gamez-Nava JI. Osteoprotegerin polymorphisms in a Mexican population with rheumatoid arthritis and generalized osteoporosis: A preliminary report. *J Immunol Res* 2015; 2015: 376197.

[2] Garfias-Rojas O, Bohórquez-López A, Godínez Rocha A. Perfil epidemiológico de la invalidez. *Rev Med IMSS* 2000; 38: 101-111.

[3] Alomar X, Medrano J, Cabratosa J, Clavero JA, Lorente M, Serra I, Monill JM, Salvador A. Anatomy of the temporomandibular joint. *Semin Ultrasound CT MRI* 2007; 28: 170-183.

[4] Stankovic S, Vlaikovic S, Boskovic M, Radenkovic G, Antic'e V, Jevremovic D. Morphological and biomechanical features of the temporomandibular joint disc: An overview of recent findings. *Archiv of Oral Biol* 2013; 58: 1475-1482.

[5] Guralnick W, Kaban LB, Merrill RG. Temporomandibular joint afflictions. *N Engl J Med* 1978; 299: 123-129.

[6] Sánchez-Effio KI, Paes da Silva LM, Ramos-Fernandez, Pereira-Dutrac ME, Marcucci M, de Oliveira JX. Juvenile idiopathic arthritis with involvement of the temporomandibular joint: the role of image examinations. *Rev Odonto Ciênc* 2010; 25: 104-107.

[7] Okur A, Özkiris M, Kapusuz Z, Karaçavus S, Saydam L. Characteristics of articular fosa and condyle in patients with temporomandibular joint complaint. *Eur Rev Med Pharmacol Sci* 2012; 16: 2131-2135.

[8] Arabshahi B, Cron RQ. Temporomandibular joint arthritis in juvenile idiopathic arthritis: the forgotten joint. *Curr Opin Rheumatol* 2006; 18: 490-505.

[9] Yunn-Sheng H, Schneiderman E, Harper R. The temporomandibular joint in juvenile rheumatoid arthritis: Part II. Relationship between

Temporomandibular joint in patients with arthritis

- computed tomographic and clinical findings. *Pediatr Dent* 1996; 18: 312-319.
- [10] Ramos-Remus C, Major P, Gomez-Vargas A, Petrikowski G, Hernandez-Chavez A, Gonzalez-Marin E, Russell AS. Temporomandibular joint osseous morphology in a consecutive sample of ankylosing spondylitis patients. *Ann Rheum Dis* 1997; 56: 103-107.
- [11] Boeddinghaus R, Whyte A. Computed tomography of the temporomandibular joint. *J Med Imag Radiat Oncol* 2013; 57: 448-454.
- [12] Koyama J, Nishiyama H, Hayashi T. Follow-up study of condylar bony changes using helical computed tomography in patients with temporomandibular disorder. *Dentomaxillofac Radiol* 2007; 36: 472-477.
- [13] Su N, Liu Y, Yang X, Luo Z, Shi Z. Correlation between bony changes measured with cone beam computed tomography and clinical dysfunction index in patients with temporomandibular joint osteoarthritis. *J Cranio-Maxillo-Facial Sur* 2014; 42: 1402-1440.
- [14] SEGOB/Secretaria de Salud. Modificación del numeral 6 de la Norma Oficial Mexicana NOM-229-SSA1-2002, Salud ambiental. Requisitos técnicos para las instalaciones, responsabilidades sanitarias, especificaciones técnicas para los equipos y protección radiológica en establecimientos de diagnóstico médico con rayos X. *Diario Oficial de la Federación* [on line] 2011 [Access april 25ft, 2017]. Available in: <http://www.economia-noms.gob.mx/normas/noms/2006/229ssa1.pdf>
- [15] Álvarez-Nemegyei J, Nuño-Gutierrez B, Alcocer-Sanchez JA. Enfermedades reumáticas y discapacidad laboral en población adulta rural. *Rev Med IMSS* 2005; 43: 287-292.
- [16] Álvarez-Nemegyei J, Peláez-Ballestas I, Sanin LH, Cardiel M, Ramírez A, Goycochea MV. Prevalence of musculoskeletal pain and rheumatic diseases in the southeastern region of Mexico. A COPCORD-Based community survey. *J Rheumatol* 2011; 38.
- [17] Stoll ML, Sharpe T, Beukelman T, Good J, Young D, Cron RQ. Risk factors for temporomandibular joint arthritis in children with juvenile idiopathic arthritis. *J Rheumatol* 2012; 39: 1114-1141.
- [18] Kalladka M, Quek S, Heir G, Eliav e, Mupparapu M, Viswanath A. Temporomandibular joint osteoarthritis: diagnosis and long-term conservative management: a topic review. *J Indian Prosthodont Soc* 2014; 14: 6-15.
- [19] Ferrazzo KL, Osório LB, Ferrazzo VA. Case report CT images of a severe TMJ osteoarthritis and differential diagnosis with other joint disorders. *Case Rep Dent* 2013; 2013: 242685.