

Original Article

Comparative analysis of three types of titanium mesh cages for anterior cervical single-level corpectomy and fusion in term of postoperative subsidence

Hangyu Ji^{1*}, Xinhui Xie^{2*}, Suyang Zhuang^{2*}, Cong Zhang², Linghan Xie¹, Xiaotao Wu^{1,2}

¹School of Medicine, Southeast University, Nanjing, China; ²The Department of Orthopedics, Zhongda Hospital of Southeast University, Nanjing, China. *Equal contributors.

Received July 14, 2020; Accepted September 20, 2020; Epub October 15, 2020; Published October 30, 2020

Abstract: A titanium mesh cage (TMC) is a common device used for interbody fusion in anterior cervical corpectomy and fusion (ACCF) surgery, with postoperative subsidence being a common complication. Among the many influencing factors, there is a paucity of research on the end-covers of the TMC. A total of 62 patients with cervical spondylotic myelopathy were treated with single-level ACCF. TMC without end-covers (group A), traditional TMC with end-covers (group B) and new TMC with end-covers (group C) were used as the fusion device. We evaluated the surgery time, intraoperative blood loss, postoperative drainage volume, postoperative fusion, falling height of the fused segment, cervical curvature and severe subsidence rate (the number of falling height of the fused segment > 3 mm/total surgical cases in the group). In addition, the Japanese Orthopaedic Association score was used for neurological status assessment and a 10-point Visual Analog Scale for postoperative neck pain. The results showed that the falling height of the fused segment in group A (1.9 ± 0.6 mm) was significantly greater than in group B (0.9 ± 0.2 mm) and group C (0.8 ± 0.3 mm). The area of the end-covers increased gradually in group A, group B and group C, while the severe subsidence rate of group A (8/20, 40%), group B (5/22, 23%) and group C (2/20, 10%) gradually decreased. The surgery time and blood loss in group B (116.4 ± 12.2 min, 183.5 ± 36.4 mL) were higher than those in group A (90.22 ± 5.60 min, 110.4 ± 20.8 mL) and group C (92.8 ± 8.47 min, 114 ± 24.0 mL). These results showed that there was a correlation between the postoperative subsidence and the end-covers of TMC. The larger the end-cover area was, the lower the severe postoperative subsidence rate was. In addition, the design of the end-covers extending inward was more conducive to the operation.

Keywords: Cervical, corpectomy, subsidence, titanium mesh cage, end-cover

Introduction

Cervical spondylotic myelopathy (CSM) is a common degenerative disease of the cervical vertebrae, which causes spinal cord compression, leading to serious consequences. Surgery is the most important treatment strategy for CSM, particularly anterior cervical corpectomy and fusion (ACCF) being the most important form of surgery due to its superior clinical outcome [1]. At present, a titanium mesh cage (TMC) with autogenous bone is the main choice of interbody fusion device in ACCF. Postoperative subsidence of the TMC is one of the most common complications, which can cause loosening and displacement of internal plants, neck pain and other related problems [2, 3]. There are many reasons that can account for the subsidence of TMC, including the patient's

age, osteoporosis, excessive expansion between vertebrae during an operation, improper trimming of the TMC, and so on [4-6]. The end-covers of a TMC is also an important factor. Previous studies have shown that a TMC with end-cover reduced the postoperative subsidence rate and neck pain compared to a TMC without end-covers [4]. When the end-covers are designed to match the shape of the adjacent endplate, the subsidence of TMC is reduced [7]. These findings indicated that the end-covers of a TMC may be very important in preventing postoperative subsidence, but to date there is no clear correlation. The question remains whether we can reduce postoperative subsidence by changing the end-cover design. At present, there is a lack of relevant research, therefore, we aimed to improve the design of the traditional TMC with end-covers,

Comparison of three TMCs subsidence




Figure 1. (A) shows a TMC without end-covers, (B) shows a traditional TMC with end-covers, (C) shows a new TMC with end-covers. (A-1, B-1, C-1) are lateral views, (A-2, B-2, C-2) are top views, (A-3, B-3, C-3) are bottom views.

and compared the clinical and imaging results among the three types (a TMC without end-covers, a traditional TMC with end-covers and a new TMC with end-covers). The purpose of the present study was to investigate the relationship between postoperative subsidence and the TMC end-covers.

Material and methods

Description of the 3 types of TMC

A TMC without end-covers is a hollow reticulated cylinder fabricated from titanium alloy. There is no special design at both ends, which

could be trimmed according to the length requirements (**Figure 1A**). The traditional TMC with end-covers is also a titanium alloy hollow reticulated cylinder, both ends of which are covered by an annular end-cover extending outwards for 2 mm. The surface of the end-covers was designed to be serrated to prevent the TMC from slipping. The leading edge of the upper end-cover had a bulge, and the lower end-cover was inclined up and down by 10° . In order to avoid the end-cover protruding backwards and pressing the spinal cord, the rear edge was designed to be flush with the outer edge of the cylinder (**Figure 1B**). The new TMC

Comparison of three TMCs subsidence

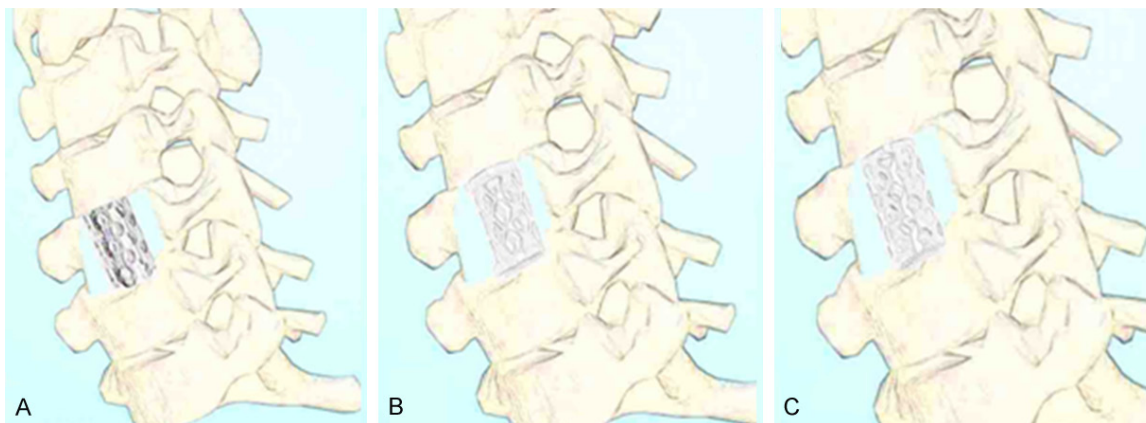


Figure 2. The 3 types of TMC were placed in the decompression groove after subtotal vertebral body resection. (A) TMC without end-covers, (B) traditional TMC with end-covers which protruded outwards, (C) new type of TMC with end-covers flush with the outer edge of the body.

with end-covers was similar to the traditional one, but its end-covers were designed to extend 2 mm inwards and the outer edge was flush with the cylinder. The surface of the new TMC with end-covers was completely covered by serrations and the lower end-cover was designed with an arc-shaped inclination of 10° , so that it fitted more closely with the upper end plate of the lower vertebral body (**Figure 1C**). The 3 types of TMCs had different sizes, which could be selected according to the operation requirements.

From January 2017 to December 2018, a total of 62 patients with CSM underwent single-level ACCF. All the patients were treated consecutively and alternately with a TMC without end-covers (group A), a traditional TMC with end-covers (group B) or a new TMC with end-covers (group C), according to the order of admission. All the TMCs were produced by China Weigao Instrument Co. Ltd. The inclusion criteria for the study were: (1) spinal cord compression caused by intervertebral disc herniation, osteophyte proliferation or ossification of the posterior longitudinal ligament and the range of lesion involved in the distance between the adjacent intervertebral spaces; (2) strict conservative treatment was ineffective (conservative treatment for at least 6 months) and nerve injury was gradually aggravated; (3) T value of bone mineral density was > -2.5 . The exclusion criteria were: (1) patients with osteoporosis whose T value of bone mineral density was ≤ -2.5 ; (2) ossification of posterior longitudinal ligament of cervical vertebrae over more than

2 intervertebral spaces; (3) developmental cervical spinal stenosis; (4) ossification of the cervical ligamentum flavum; (5) patients with non-degenerative diseases such as cervical fracture, infection, tumor, ankylosing spondylitis, etc.; (6) mental disorders. All data were collected and reviewed by an independent observer who was not directly involved in the medical and nursing work of the patients.

Operation procedures

The cervical vertebrae were exposed through the Smith Robinson approach on the right side under endotracheal anesthesia. C-arm fluoroscopy was used to determine the target vertebral body. After the intervertebral discs adjacent to the target vertebral body were removed, the target vertebral body was cut to the front of the dura mater. The cut vertebral bodies were cut into bone fragments and placed into TMC as bone graft material. The TMC filled with autogenous bone was implanted into the decompression groove (**Figure 2**). Finally, a titanium plate was used for fixation. All patients wore a neck circumference for 1 month.

Outcome assessment

The patients were followed-up for at least 12 months and received X-ray and CT scans to evaluate the subsidence of the TMC, cervical curvature and the fusion of the operative segments. A severe subsidence of TMC was defined at 12 months after the operation as the height by which the fused segment decreased

Comparison of three TMCs subsidence

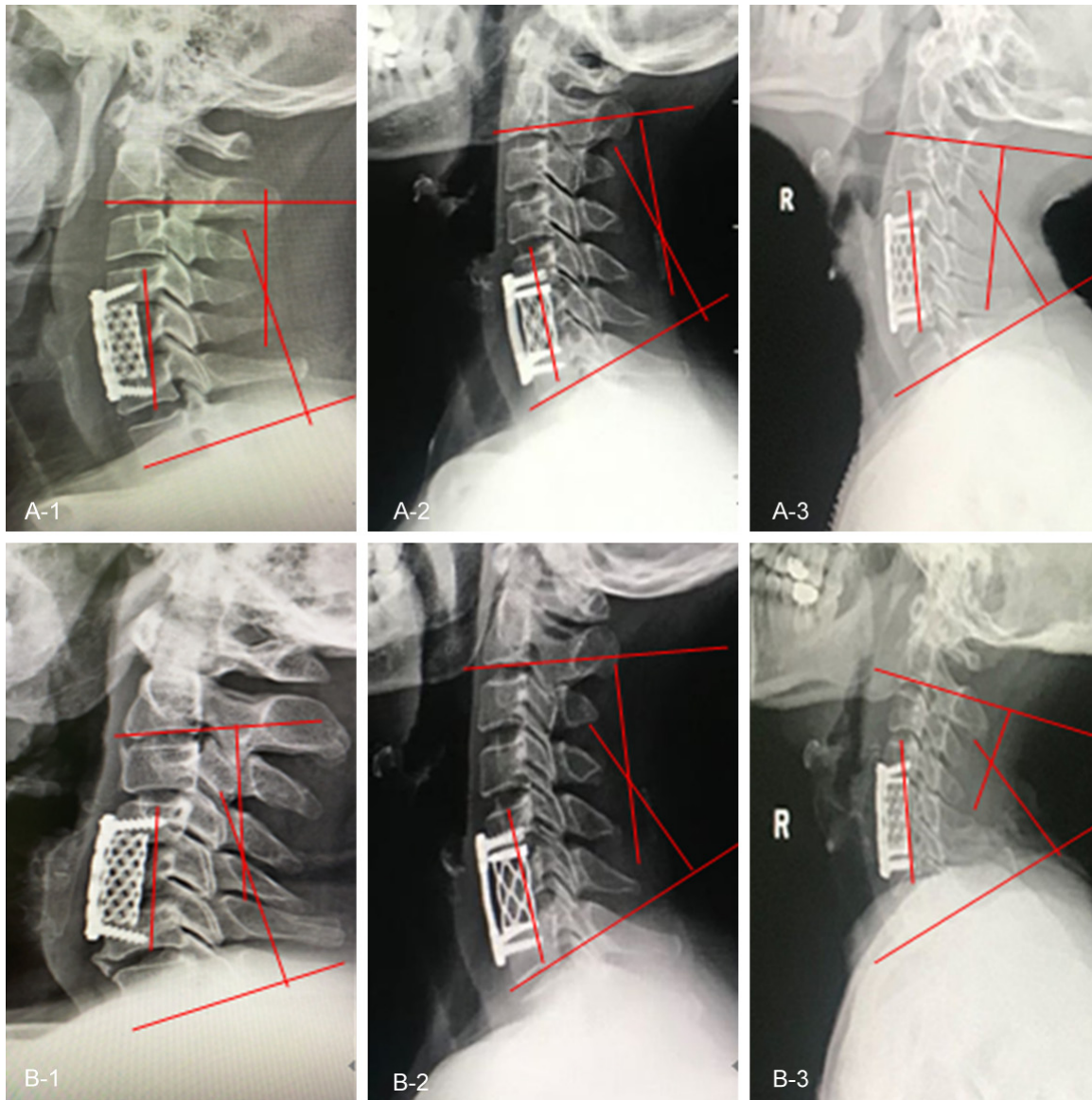


Figure 3. A-1, A-2, A-3. Show the height of the fused segment and the curvature of the cervical vertebra, 1 day after operation, with TMC without end-covers, traditional TMC with end-covers and new TMC with end-covers. B-1, B-2, B-3. Show images 1 year after the operation with TMC without end-cover, traditional TMC with end-covers and new TMC with end-covers. It can be seen that the subsidence of TMC without end-covers was more obvious and accompanied by the displacement of TMC.

by ≥ 3 mm compared to day 1 after the operation. The height of the fused segment was defined as the line between the midpoint of the upper and lower endplates of the adjacent vertebrae [8]. Evaluation of cervical curvature was based on the C2-C7 Cobb angle (Figure 3). Interbody fusion was defined as the fusion of mature bone trabeculae across the TMC and the adjacent upper and lower endplates [9]. The Japanese Orthopaedic Association (JOA) scoring system was used to evaluate functions

of the nervous system [10]. Postoperative neck pain was graded using a 10-point visual analog scale (VAS) [11]. All data were collected and reviewed by an independent, experienced spine surgeon and a radiologist (Figure 4).

Statistical analysis

SPSS (ver. 23.0) was used for all statistical analyses. Measurement data was expressed as the mean \pm standard deviation. One-way

Comparison of three TMCs subsidence

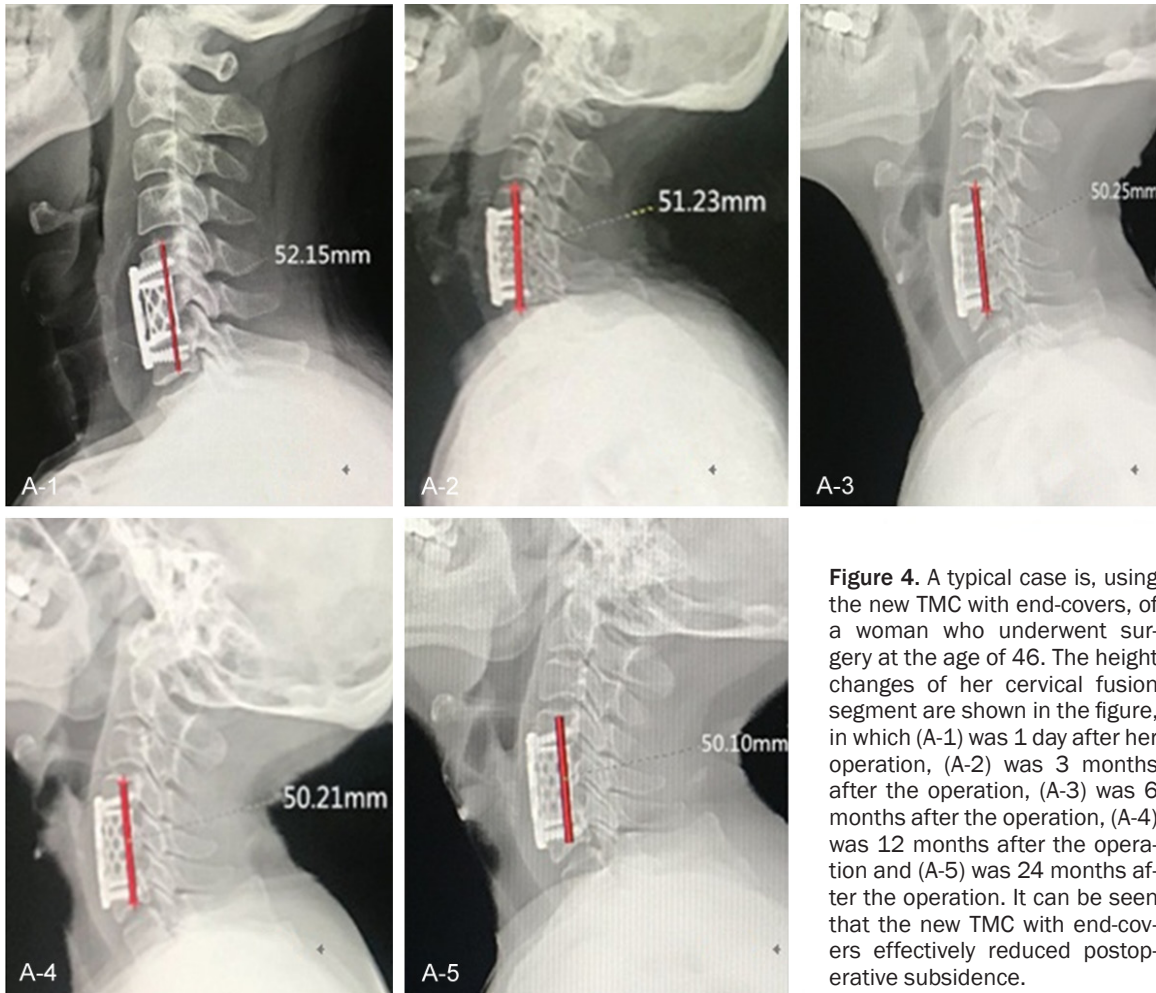


Figure 4. A typical case is, using the new TMC with end-covers, of a woman who underwent surgery at the age of 46. The height changes of her cervical fusion segment are shown in the figure, in which (A-1) was 1 day after her operation, (A-2) was 3 months after the operation, (A-3) was 6 months after the operation, (A-4) was 12 months after the operation and (A-5) was 24 months after the operation. It can be seen that the new TMC with end-covers effectively reduced postoperative subsidence.

ANOVA was used for multi-group (group A, group B and group C) comparisons and the SNK-q method was used for further pairwise comparisons (group A vs B, A vs C, B vs C). Student's t test was used to compare the preoperative and postoperative data (cervical curvature, JOA score, VAS score). A chi-squared test was used to compare counting data (gender and resection segment) among group A, B and C. The significance level was set at $P < 0.05$.

Results

Comparison of preoperative data among 3 groups

Among the three groups, 20 cases were treated with TMC without end-covers (group A); 10 males and 10 females, age range 39-66 years, average age 63.45 ± 2.60 years. There were 22 patients in the traditional TMC with

end-covers group (group B); comprised of 10 males and 12 females, age range 40-68 years, average age 64.4 ± 2.3 years. A total of 20 cases were treated with the new TMC with end-covers (group C); 9 males and 11 females, age range was 42-71 years, average age 64.4 ± 2.3 years. Vertebral resection segment: in group A, 2 cases were C4, 10 cases were C5, 8 cases were C6; in group B, 2 cases were C4, 9 cases were C5, 11 cases were C6; in group C, 2 cases were C4, 9 cases were C5, 9 cases were C6, and there was no statistical differences between the 3 groups (**Table 1**).

Comparison of intraoperative and postoperative data among 3 groups

The average surgery time of group A (90.22 ± 5.60 min) and group C (92.8 ± 8.47 min) was shorter than for group B (116.4 ± 12.2 min, $P < 0.05$). The quantity of blood loss in group A (110.4 ± 20.8 mL) and group C (114 ± 24.0

Comparison of three TMCs subsidence

Table 1. Comparison of preoperative data of 3 groups

Items	Group A (n = 20)	Group B (n = 22)	Group C (n = 20)	F value	P value	A vs B P value	A vs C P value	B vs C P value
Age (year)	60.45 ± 3.2	64.4 ± 2.28	63.45 ± 2.60	1.723	0.232	0.132	0.651	0.254
Gender	20	22	20		0.940	0.768	0.752	0.976
male	10	10	9					
female	10	12	11					
Resection segment	C4 2 C5 10 C6 8	C4 2 C5 9 C6 11	C4 2 C5 9 C6 9		0.979	0.806	0.946	0.949

Table 2. Comparison of intraoperative and postoperative data in 3 groups

Items	Group A (n = 20)	Group B (n = 22)	Group C (n = 20)	F value	P value	A vs B P value	A vs C P value	B vs C P value
Surgery time (min)	90.22 ± 5.60	116.4 ± 12.2	92.8 ± 8.47	7.436	0.012	0.015	0.675	0.033
Blood loss (ml)	110.4 ± 20.8	183.5 ± 36.4	114 ± 24.0	6.548	0.018	0.023	0.851	0.033
Postoperative drainage (ml)	121.4 ± 21.3	136.2 ± 26.6	124 ± 19.8	0.362	0.706	0.488	0.882	0.556
hospital stay (day)	5.8 ± 0.62	6.1 ± 0.55	6.35 ± 0.81	0.508	0.618	0.554	0.386	0.674
infection	0	0	0					

mL) was less than in group B (183.5 ± 36.4 mL, $P < 0.05$). There was no significant difference between the three groups in terms of postoperative drainage and hospital stay. It should be noted that there were no cases of infection in the three groups (**Table 2**).

Comparison of clinical and imaging data among 3 groups

In this study, all patients were followed up for 12 to 24 months, with an average of 18 months. All decompression segments achieved bony fusion. There were no complications such as spinal cord injury, cerebrospinal fluid leakage, esophageal fistula, wound infection or internal fixation displacement. In the postoperative follow-up, the falling height of the fused segment in group A (1.9 ± 0.6 mm) was significantly greater than in group B (0.9 ± 0.2 mm) and group C (0.8 ± 0.3 mm). The severe subsidence rate of TMC in group A (8/20, 40%) was higher than that in groups B (5/22, 23%) and C (2/20, 10%), with the rate in group B being higher than in group C. The cervical curvature and postoperative neck pain at the final follow-up were all improved compared with that of pre-operation ($P < 0.05$), with no significant differences between the 3 groups ($P < 0.05$). Similarly, the JOA scores of the 3 groups at the final follow-ups were higher than those at pre-operation ($P < 0.05$). The improvements

of group B and C were more obvious than group A ($P < 0.05$) (**Table 3**).

Discussion

In the surgical treatment of CSM, ACCF is one of the most common operations [12]. It can directly decompress the compressed spinal cord and restore and maintain the height of the vertebral body and the curvature of the cervical vertebra [13-15]. There are many types of interbody fusion devices available, from the initial autogenous iliac bone to the currently used TMCs [16, 17]. At present, a TMC with autogenous bone is the most common choice for interbody fusion [18, 19]. It has many advantages, such as avoiding the complications of pain, hematoma and infection at the bone extraction site during autogenous iliac bone transplantation [20-22]. The subsidence of a TMC is one of the most common complications, although the clinical significance of which remains controversial [23-25], but theoretically, maintaining the height of the TMC is of clear significance for the recovery and maintenance of cervical curvature and intervertebral height. In this way, the stenosis in the intervertebral foramen and degeneration of the ligamentum flavum can be prevented from causing the recompression of the spinal cord and nerve roots [26, 27]. There are many reasons for the subsidence of TMC [28, 29], but the

Comparison of three TMCs subsidence

Table 3. Comparison of clinical and imaging data of 3 groups

Items	Group A (n = 20)	Group B (n = 22)	Group C (n = 20)	F value	P value	A vs B P value	A vs C P value	B vs C P value
Falling height of fused segment (mm)	1.9 ± 0.6	0.9 ± 0.2	0.8 ± 0.3	6.796	0.016	0.034	0.030	0.648
Severe subsidence	8	5	2					
Cervical curvature								
preoperation	6.4 ± 1.2	6.2 ± 1.2	5.8 ± 1.6	0.154	0.859	0.845	0.622	0.741
final follow-up	9.1 ± 1.1	9.8 ± 1.4	9.5 ± 1.3	0.228	0.800	0.521	0.698	0.795
P value	0.028	0.015	0.021					
JOA score								
preoperation	8.8 ± 1.3	9.1 ± 1.6	9 ± 1.8	0.028	0.972	0.809	0.881	0.945
final follow-up	12 ± 1.3	14.8 ± 1.3	15 ± 1.5	4.497	0.044	0.039	0.040	0.867
P value	0.024	0.003	0.004					
VAS score								
preoperation	6.3 ± 1.5	6.8 ± 1.2	6.4 ± 1.4	0.112	0.896	0.668	0.935	0.720
final follow-up	3.1 ± 1.4	2.3 ± 1.7	2.0 ± 1.5	0.410	0.676	0.552	0.389	0.826
P value	0.036	0.010	0.010					

end-cover is also a factor that cannot be ignored. We found that the height of the fusion segment was significantly decreased in the patient group treated with TMCs without end-covers compared to the group who received TMCs with end-covers. Accordingly, the severe subsidence rate of the former was significantly higher than that of the latter. This finding may be due to the lack of an end-cover in the former device, resulting in less area of contact between the TMC and the vertebral endplate. At the same time, we also found that the severe subsidence rate of the new TMC with end-covers was lower than that of the traditional implant. The contact area of the same type of TMC with end-covers was larger than without end-covers and the new TMC with end-covers was bigger than the traditional implant. Compared with the new TMC with end-covers, the posterior edge of the traditional implant was less than 1/4 or so, which resulted in the contact area with the adjacent vertebral body being significantly less than with the former. In addition, the traditional TMC was designed for point contact at the front edge of the end-cover, which may increase the local pressure. There was a clear relationship between the area of the TMC end-cover and severe postoperative subsidence. The larger the area of the end-cover, the lower the severe subsidence of the TMC. We also found that the end-cover of the new TMC should not be enlarged without limit. It would produce a decrease in the inner diameter and contact area between the bone graft and endplate, leading to the fusion rate

of the decompression segment being decreased. However, the critical value of the end-cover area extending inwards needs further study.

During an operation, the surgery times and blood losses in the group given the traditional TMC with end-covers were significantly more than those who received treatment with TMCs without end-covers and the new TMCs with end-covers. According to relevant research, the cervical vertebrae of Chinese people is smaller than that of European and American people [30]; however, it should be noted that the traditional TMC with end-covers was designed with reference to the anatomical data of Europeans and Americans. Therefore, when the traditional TMC with end-covers was implanted into the decompression groove of the vertebral body, because the outer edge of the end cover was 2 mm longer than the diameter of the TMC body, the implant technology needed stricter control. It required that both sides of the TMC were parallel to the decompression groove. If the edge of the end-covers protruded from the anterior edge of the vertebral body, it was not conducive to the placement of the titanium plate, which could lead to incompatibility between the titanium plate and the vertebral body. If there was rotation of the TMC during the implantation operation, leading to the edge of the end-cover protruding from the posterior edge of the vertebral body, it may well compress the spinal cord or nerve roots, producing serious clinical consequences for the patient. However, if the small TMC was replaced, the

Comparison of three TMCs subsidence

height and curvature of the cervical spine could not be restored well, which may lead to a poor postoperative patient experience. The above procedures in longer exposure times and more bleeding, but at the same time indicated that the extension of the end-cover inwards was a reasonable compromise. The new TMC design is worth recommending because of the increased area of the end-covers and being more conducive during the operation. Due to our short observation time and small number of cases, further studies will be needed to evaluate the long-term subsidence and related complications of the new TMCs with end-covers.

Acknowledgements

We acknowledge all the patients who participated in this study. Supported by the National Natural Science Foundation of China (CN): 81-572109.

Disclosure of conflict of interest

None.

Address correspondence to: Dr. Xiaotao Wu, The Department of Orthopedics, Zhongda Hospital of Southeast University, Dingjiaqiao 87, Gulou District, Nanjing 210009, China. E-mail: wuxiaotao-spine@seu.edu.cn

References

- [1] Ouyang P, Lu T, He X, Gao Z, Cai X and Jin Z. Biomechanical comparison of integrated fixation cage versus anterior cervical plate and cage in anterior cervical corpectomy and fusion (ACCF): a finite element analysis. *Med Sci Monit* 2019; 25: 1489-1498.
- [2] Chun HJ, Oh SH, Yi HJ and Ko Y. Efficacy and durability of the titanium mesh cage spacer combined with transarticular screw fixation for atlantoaxial instability in rheumatoid arthritis patients. *Spine (Phila Pa 1976)* 2009; 34: 2384-8.
- [3] Katz AD, Mancini N, Karukonda T, Cote M and Moss IL. Comparative and predictor analysis of 30-day readmission, reoperation, and morbidity in patients undergoing multilevel ACDF versus single and multilevel ACCF using the ACS-NSQIP dataset. *Spine (Phila Pa 1976)* 2019; 44: E1379-E1387.
- [4] Hur JW, Ryu KS, Ahn S, Kim JS, Chung HJ and Song MS. Comparative analysis of 2 different types of titanium mesh cage for single-level anterior cervical corpectomy and fusion in terms of postoperative subsidence and sagittal alignment. *Clin Spine Surg* 2020; 33: E8-E13.
- [5] Chen G, Xin B, Yin M, Fan T, Wang J, Wang T, Bai G, Xiao J and Liu T. Biomechanical analysis of a novel height-adjustable nano-hydroxyapatite/polyamide-66 vertebral body: a finite element study. *J Orthop Surg Res* 2019; 14: 368.
- [6] Du Y, Li L, Peng H, Zheng H, Cao S, Lv G, Yang A, Li H and Liu T. A spray-filming self-healing hydrogel fabricated from modified sodium alginate and gelatin as a bacterial barrier. *Macromol Biosci* 2019; 20: e1900303.
- [7] Yang S, Yang D, Ma L, Wang H and Ding W. Clinical efficacy of laminectomy with instrumented fixation in treatment of adjacent segmental disease following ACCF surgery: a retrospective observational study of 48 patients. *Sci Rep* 2019; 9: 6551.
- [8] Yu F, Miao J, Liao X, Wang X, Chen Y and Chen D. Evaluation of a new type of titanium mesh cage versus the traditional titanium mesh cage for single-level, anterior cervical corpectomy and fusion. *Eur Spine J* 2013; 22: 2891-6.
- [9] Nakase H, Park YS, Kimura H, Sakaki T and Morimoto T. Complications and long-term follow-up results in titanium mesh cage reconstruction after cervical corpectomy. *J Spinal Disord Tech* 2006; 19: 353-7.
- [10] Wen Z, Lu T, Wang Y, Liang H, Gao Z and He X. Anterior cervical corpectomy and fusion and anterior cervical discectomy and fusion using titanium mesh cages for treatment of degenerative cervical pathologies: a literature review. *Med Sci Monit* 2018; 24: 6398-6404.
- [11] Daubs MD. Early failures following cervical corpectomy reconstruction with titanium mesh cages and anterior plating. *Spine (Phila Pa 1976)* 2005; 30: 1402-6.
- [12] Kasliwal MK and O'Toole JE. Clinical experience using polyetheretherketone (PEEK) intervertebral structural cage for anterior cervical corpectomy and fusion. *J Clin Neurosci* 2014; 21: 217-20.
- [13] Missori P, Domenicucci M and Marruzzo D. Clinical effects of posterior longitudinal ligament removal and wide anterior cervical corpectomy for spondylosis. *World Neurosurg* 2018; 113: e761-e768.
- [14] Zeng J, Duan Y, Yang Y, Wang B, Hong Y, Lou J, Ning N and Liu H. Anterior corpectomy and reconstruction using dynamic cervical plate and titanium mesh cage for cervical spondylotic myelopathy: a minimum 5-year follow-up study. *Medicine (Baltimore)* 2018; 97: e9724.
- [15] Sasso RC, Ruggiero RA, Reilly TM and Hall PV. Early reconstruction failures after multilevel cervical corpectomy. *Spine (Phila Pa 1976)* 2003; 28: 140-2.

Comparison of three TMCs subsidence

- [16] Lu T, Liu C, Yang B, Liu J, Zhang F, Wang D, Li H and He X. Single-level anterior cervical corpectomy and fusion using a new 3d-printed anatomy-adaptive titanium mesh cage for treatment of cervical spondylotic myelopathy and ossification of the posterior longitudinal ligament: a retrospective case series study. *Med Sci Monit* 2017; 23: 3105-3114.
- [17] Yang X, Chen Q, Liu L, Song Y, Kong Q, Zeng J, Xue Y and Ren C. Comparison of anterior cervical fusion by titanium mesh cage versus nano-hydroxyapatite/polyamide cage following single-level corpectomy. *Int Orthop* 2013; 37: 2421-7.
- [18] Chen Y, Chen D, Guo Y, Wang X, Lu X, He Z and Yuan W. Subsidence of titanium mesh cage: a study based on 300 cases. *J Spinal Disord Tech* 2008; 21: 489-92.
- [19] Kanayama M, Hashimoto T, Shigenobu K, Oha F, Ishida T and Yamane S. Pitfalls of anterior cervical fusion using titanium mesh and local autograft. *J Spinal Disord Tech* 2003; 16: 513-8.
- [20] Zhang Y, Liu H, Yang H and Pi B. Anterior cervical corpectomy and fusion versus discectomy and fusion for the treatment of two-level cervical spondylotic myelopathy: analysis of sagittal balance and axial symptoms. *Int Orthop* 2018; 42: 1877-1882.
- [21] Theologis AA, Lansdown D, McClellan RT, Chou D and Pekmezci M. Multilevel corpectomy with anterior column reconstruction and plating for subaxial cervical osteomyelitis. *Spine (Phila Pa 1976)* 2016; 41: E1088-95.
- [22] Niedzielak TR, Palmer J and Malloy JP. Clinical comparison of surgical constructs for anterior cervical corpectomy and fusion in patients with cervical spondylotic myelopathy or ossified posterior longitudinal ligament: a systematic review and meta-analysis. *Clin Spine Surg* 2018; 31: 247-260.
- [23] Miao D, Zhang B, Lei T and Shen Y. Clinical efficacy of anterior partial corpectomy and titanium mesh fusion and internal fixation for treatment of old fracture dislocation of the lower cervical spine. *Med Sci Monit* 2017; 23: 5675-5682.
- [24] Sarkar S and Rajshekhar V. Long-term sustainability of functional improvement following central corpectomy for cervical spondylotic myelopathy and ossification of posterior longitudinal ligament. *Spine (Phila Pa 1976)* 2018; 43: E703-E711.
- [25] Shaw KA, Griffith M, Mottern ET, Gloystein DM and Devine JG. Preventing construct subsidence following cervical corpectomy: the bump-stop technique. *Asian Spine J* 2018; 12: 156-161.
- [26] Liu X, Chen Y, Yang H, Li T, Xu H, Xu B and Chen D. The application of a new type of titanium mesh cage in hybrid anterior decompression and fusion technique for the treatment of continuously three-level cervical spondylotic myelopathy. *Eur Spine J* 2017; 26: 122-130.
- [27] Ji C, Yu S, Yan N, Wang J, Hou F, Hou T and Cai W. Risk factors for subsidence of titanium mesh cage following single-level anterior cervical corpectomy and fusion. *BMC Musculoskelet Disord* 2020; 21: 32.
- [28] Weber MH, Fortin M, Shen J, Tay B, Hu SS, Berven S, Burch S, Chou D, Ames C and Deviren V. Graft subsidence and revision rates following anterior cervical corpectomy: a clinical study comparing different interbody cages. *Clin Spine Surg* 2017; 30: E1239-E1245.
- [29] Wu J, Luo D, Ye X, Luo X, Yan L and Qian H. Anatomy-related risk factors for the subsidence of titanium mesh cage in cervical reconstruction after one-level corpectomy. *Int J Clin Exp Med* 2015; 8: 7405-11.
- [30] Yao Q, Yin P, Khan K, Tsai T, Li J, Hai Y, Tang P and Li G. Differences of the morphology of subaxial cervical spine endplates between Chinese and White Men and Women. *Biomed Res Int* 2018; 2018: 2854175.