

Original Article

Pediculoplasty combined with vertebroplasty for the treatment of Kummell's disease without neurological impairment: robot-assisted and fluoroscopy-guided

Biao Wang, Yuhang Wang, Qinpeng Zhao, He Zhao, Yongyuan Zhang, Yi Zhan, Liang Yan, Dingjun Hao

Department of Spine Surgery, Honghui Hospital, Xi'an Jiaotong University College of Medicine, No. 76 Nanguo Road, Xi'an 710054, Shaanxi, China

Received May 3, 2020; Accepted November 20, 2020; Epub December 15, 2020; Published December 30, 2020

Abstract: With the development of radiology and minimally invasive technology, vertebroplasty has become the mainstream treatment for Kummell's disease. However, the catastrophic complication of bone cement displacement appears occasionally. We use robot-assisted pediculoplasty combined with vertebroplasty to avoid such complications. From January 2015 to January 2018, 87 patients suffering from thoracolumbar Kummell's disease without neurological symptoms were treated by robot-assisted pediculoplasty combined with vertebroplasty. Pediculoplasty as a "bridge" allows the bone cement at the anterior edge of the vertebral body to be fixed in the vertebral body through the intrapedicular cement, which can effectively prevent bone cement displacement. The clinical efficacy was evaluated based on the statistical analysis results of vertebral body index (VBI), Cobb angle, visual analogue scale (VAS), and Oswestry disability index (ODI) at 3, 6, 12, 18, and 24 months after treatment. The average operation time was 85.23 ± 10.48 min, and the average volume of cement injected was 4.97 ± 0.66 ml. The patients' preoperative VBI, Cobb angle, VAS and ODI scores were 62.01 ± 11.32 , $33.78 \pm 11.99^\circ$, 7.47 ± 0.82 , and 78.37 ± 7.14 , respectively. The postoperative measurements were 87.06 ± 4.45 , $16.57 \pm 6.46^\circ$, 2.89 ± 0.95 , and 46.91 ± 8.44 . At the last follow-up, the outcomes were 86.82 ± 4.27 , $16.72 \pm 6.22^\circ$, 1.75 ± 0.69 , and 20.48 ± 4.48 , respectively. There was significant difference between the preoperative and postoperative data, as well as the preoperative and the last follow-up data ($P < 0.05$). The four evaluation indexes improved by 65.3%, 50.5%, 76.6%, and 73.9%, respectively. This 2-year follow-up study shows robot-assisted and fluoroscopy-guided pediculoplasty combined with vertebroplasty has a good short and medium-term therapeutic effect on patients with Kummell's disease without neurological impairment. This technique effectively prevents cement displacement and achieves rapid pain relief, with satisfactory vertebral body height restoration, and kyphotic deformity improvement.

Keywords: Pediculoplasty, vertebroplasty, Kummell's disease, fluoroscopy-guided, robot-assisted

Introduction

In 1891, German physician Kummell proposed a delayed osteonecrosis of the vertebral body after spinal trauma, and since then scholars have called this type of disease "Kummell's disease" [1]. This disease is often seen in patients with osteoporosis, who develop painful, progressive kyphotic deformity after experiencing minor trauma and going through an asymptomatic period [2-5]. In the past, Kummell's disease failed to attract scholars' attention due to its rarity and the limitations in imaging diagnostic techniques. From the initial report in 1891 to 2010, only 14 articles were published, and

most of them were simple case reports [4]. More recently years, with the rising global age, the number of patients with Kummell's disease has increased. The disease has garnered more and more attention from scholars and has become a new research hotspot in spinal diseases.

At present, the pathogenic mechanism of Kummell's disease is still not fully understood. As the pathological and vertebral vascular anatomical research progresses, a mechanistic hypothesis based on intravertebral pseudarthrosis formation and vertebral avascular necrosis after osteoporotic fractures has been

Pediculoplasty combined with vertebroplasty

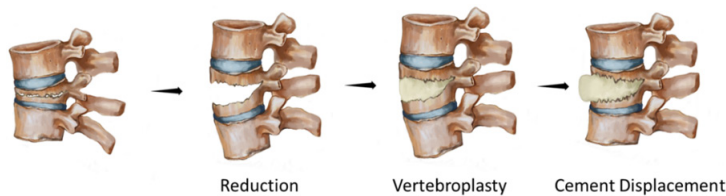


Figure 1. Schematic diagram of cement displacement after vertebroplasty in Kummell's disease.

gradually formed, and the vertebral avascular necrosis hypothesis has been accepted by most scholars [6-9]. Percutaneous vertebroplasty was originally introduced in France in 1987 by interventional neuroradiologist Galibert [10], and is widely used to treat pain-related spinal disorders, including Kummell's disease [3, 4, 11]. Vertebroplasty has become the mainstream modality for the treatment of Kummell's disease without neurological impairment due to its ability to better relieve the pain, alleviate kyphotic deformity, and restore physiological curvature of the spine [12-14]. However, the catastrophic complication of bone cement displacement after vertebroplasty often occurs (Figure 1), and once it occurs, it is refractory to conservatively treat and must be treated with complex revision surgery [15-19]. This complication is a disaster not only for the patient but also for the physician, and it may be accompanied by annoying medical disputes.

To avoid bone cement displacement, we used robot-assisted percutaneous pediculoplasty combined with vertebroplasty to treat Kummell's disease without neurological impairment. To our knowledge, this is the first report of this treatment technique being applied in the treatment of Kummell's disease. Pediculoplasty consists of the injection of polymethylmethacrylate into the pedicles, as a technique derived from vertebroplasty [20-22]. Theoretically, pediculoplasty combined with vertebroplasty allows the bone cement at the anterior edge of the vertebral body to be fixed in the vertebral body through the intrapedicular bone cement, so that the bone cement can be integrally connected with the normal bone tissue, which can effectively prevent bone cement displacement. Thus, the aims of our retrospectively observational study were to evaluate (a) whether robot-assisted and fluoroscopy-guided pediculoplasty combined with vertebroplasty can avoid bone cement displacement and (b) the safety

and effectiveness of this novel treatment strategy.

Materials and methods

Patients

This retrospective data evaluation research was approved by the institutional review board of our hospital (approval number: 2019-01007), and all patients gave written informed consent.

From January 2015 to January 2018, 87 patients with thoracolumbar Kummell's disease without neurological symptoms were included in this study. All patients had single-segment Kummell's disease and were treated with robot-assisted pediculoplasty combined with vertebroplasty (87 vertebrae in total). There were 21 males and 66 females, aged 63-85 years (mean 72.72 ± 5.62 years). The lumbar spine bone density T score of patients measured by dual-energy X-ray absorptiometry was -2.5 to -5.2, with an average of -3.19 ± 0.57 . The diseased vertebral segments were T11 in nine cases, T12 in 39 cases, L1 in 35 cases, and L2 in four cases. A total of 51 patients had comorbidities (37 patients had one comorbidity, 9 patients had two comorbidities, and five patients had more than three comorbidities). Specifically, 21 patients had diabetes, 38 had hypertension, and 11 had coronary heart disease. Seventy-five (86%) patients had a history of minor trauma and mild back pain, who returned to normal life after a brief rest and symptomatic treatment. After an asymptomatic period of 4-12 months (mean 7.67 ± 2.27 months), the patients experienced progressive lower back pain. The symptoms of all patients were mainly manifested as severe back or lower back pain during postural change, 79 patients (91%) had the most severe pain when turning on the bed, and eight patients (9%) had the most significant pain when changing from sitting to standing.

Inclusion and exclusion criteria

Inclusion criteria were as follows: (a) single-segment Kummell's disease; (b) bone density T score less than -2.5; (c) severe back or lower back pain without neurological impairment; (d) intact bilateral pedicles. Exclusion criteria were

Pediculoplasty combined with vertebroplasty

as follows: (a) combined neurological symptoms; (b) lesions involving multiple vertebrae; (c) other combined diseases, such as spinal metastases, spondylocace, and lumbar spondylolisthesis, that can lead to lower back pain; (d) no osteoporosis; (e) congenital absence, deformity, or damage of the pedicle of the diseased vertebra; (f) not robot-assisted surgery; (g) follow-up time less than 2 years.

Preoperative preparation

A comprehensive assessment of the patients' general condition was performed. Standard anteroposterior and lateral radiographs, dynamic lateral x-ray films, computed tomography (CT) imaging (included sagittal and coronal reconstruction), and magnetic resonance imaging (MRI) were used to evaluate the defects in the peripheral wall of the vertebra, especially the defect in the posterior and anterior wall. The CT results were used to plan the surgical approach and the path of bone cement injection within the supporting software of the robot (Renaissance). Patients fasted for 6 hours before the operation and did not drink within 4 hours before the operation. Patients received intravenous cefazolin sodium of 2.0 g at 30 minutes before the surgery, and 0.6 g of clindamycin was given to those allergic to cephalosporins.

Surgical procedure

Anesthesia and positioning: After general anesthesia, the patient took the prone position. Cushions were placed under the patient's chest and anterior superior iliac spines to suspend the abdomen. Under lateral C-arm fluoroscopy, the operating table was adjusted so that the patient was in an appropriate hyperextension position, and manual reduction was used to obtain the best vertebral height recovery.

Robot-assisted bone cement trocar placement: The surgical protocol was input into the Renaissance system. The tracker was fixed at the spinous process of the adjacent vertebral body at the head end of the diseased vertebra, the T-Hover fixation frame system was installed, and the C-arm was used for the anteroposterior and oblique views of fluoroscopy, which were imported into the computer to match the preoperative CT image data. After registration of the diseased vertebra was completed, the error

rate was evaluated, and the planned puncture path was finely adjusted. The Renaissance system actively adjusted the posture of the robot, and the surgeon connected the robotic arm as prompted. According to the distance from the posterior edge of the vertebral body to the surface of the body in the planned path, a guide needle was drilled in using a depth-limiting electric drill. C-arm fluoroscopy was used to verify the accuracy of the position of the guide needle. If there was deviation in the position, it was necessary to make an immediate adjustment. When the guide needle was in the proper position, the bone cement trocar was installed under the guidance of the guide needle, and C-arm fluoroscopy was used again to verify the accuracy of the position of the bone cement trocar.

Fluoroscopy-guided vertebroplasty and pediculoplasty: After verifying that the trocar was in a satisfactory position, it was used to puncture towards the anterior edge of the vertebral body into the intravertebral vacuum cleft. When the bone cement was in the wire-drawing stage, an appropriate volume of bone cement was slowly injected into the cleft under anteroposterior and lateral X-ray fluoroscopy. After the intravertebral space was fully filled, the vertebroplasty was completed. Then bone cement at the toothpaste-like stage was injected continuously under lateral X-ray fluoroscopic monitoring. The trocar was slowly retracted dorsally while the bone cement was slowly injected, and the two procedures were coordinated. When the trocar retreated through the entire pedicle and was close to the initial puncture site, the cement injection was stopped, and the pediculoplasty was completed. The trocar was removed after the bone cement was completely cured. The schematic diagram and photographs of actual operation are shown in **Figures 2 and 3**.

Postoperative treatment

After awakening from general anesthesia, patients were observed for symptoms of nerve damage. The patient rested in bed until the first postoperative day and got out of bed under the protection of a thoracolumbar brace. The patient was observed for the presence or absence of irritation symptoms of the corresponding nerve root after getting out of bed.

Pediculoplasty combined with vertebroplasty

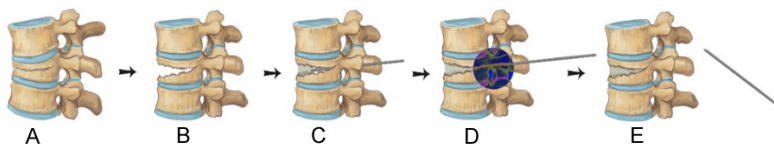


Figure 2. Schematic diagram of Kummell's disease treated by pediculoplasty combined with vertebroplasty. A: Vertebral collapse and kyphosis due to Kummell's disease; B: After reduction of collapsed vertebrae and correction of deformity with hyperextension, formed bone deficiency at the anterior border of vertebrae; C: Bone cement filled intravertebral vacuum cleft through vertebroplasty; D: Continue injection of cement to complete the pediculoplasty; E: Pull out the trocar after the cement solidified.

Postoperative functional exercise methods and precautions were instructed by rehabilitation physicians. The patient was discharged after the condition was stable. After discharge, the patient continued to wear the brace for protection for 12 weeks and used anti-osteoporosis treatments such as calcium, vitamin D3, and bisphosphonates under the guidance of an osteoporosis physician.

Follow-up assessment

Postoperative follow-up and review were conducted at 3, 6, 12, 18, and 24 months after operation. X-ray or CT was used to evaluate whether there was bone cement displacement. The change in vertebral body index (VBI, the relationship between the anterior and posterior wall heights of the diseased vertebra $\times 100\%$) of the patient was measured to evaluate the improvement in postoperative vertebral body height. The change in the Cobb angle (angle defined by the upper endplate of the first vertebra above the diseased one and by the lower endplate of the first vertebra below the diseased one) of the patient was measured to evaluate the correction of kyphotic deformity. Pain relief and functional recovery were assessed by comparing the visual analogue scale (VAS) score (0: no pain at all; 10: worst pain imaginable) and Oswestry disability index (ODI) (0%: best functional state; 100%: worst functional state) score.

Statistical analysis

The paired t-test was used to compare the imaging parameters, VAS score, and ODI score of the 87 patients before the surgery, after the surgery, one year after the surgery and at the last follow-up. Statistical analysis was performed using a statistical software package

(SPSS for Windows, release 21.0; IBM, Armonk, NY), and $P < 0.05$ was considered to indicate a statistically significant difference.

Results

Surgical results and complications

The operation was successfully completed in all 87

patients. The mean duration of the operation was 85.23 ± 10.48 minutes (70-115 minutes), and the mean cement injection volume was 4.97 ± 0.66 mL (4-6 mL). Eighty-three patients received successful puncture in a single attempt with the assistance of the robot, while four patients had failure to target the puncture to the intravertebral cleft due to a poor sagittal angle. After adjustment, the puncture was satisfactory, without pedicle inner wall injury occurred. The accuracy of robot-assisted puncture was 95.4%. Cement leakage occurred in seven patients (8.0%), with leakage from the anterior margin of the vertebral body in four patients, leakage from paravertebral veins in two patients, and small leakage from the lateral wall of the pedicle in one patient, but there was no intraspinal and foraminal leakage. None of the 87 patients had nerve root irritation symptoms after they got out of bed. Seventy-two patients (82.8%) were discharged on the first postoperative day, and the other 15 patients (17.2%) on the second postoperative day. All patients had good wound healing, and there was no delayed wound healing, infection, or hematoma formation.

Follow-up results

During the 2-year follow-up, none of the patients had delayed bone cement displacement, and none of the patients underwent revision surgery.

In terms of the improvement of the vertebral body height, VBI improved from 62.01 ± 11.32 preoperatively to 87.06 ± 4.45 postoperatively ($P = 0.000$), and the improvement rate was 65.9%. Although the VBI decreased slightly during the follow-up, reaching 86.82 ± 4.27 at the final follow-up, the difference was not statistically significant compared with postoperatively

Pediculoplasty combined with vertebroplasty

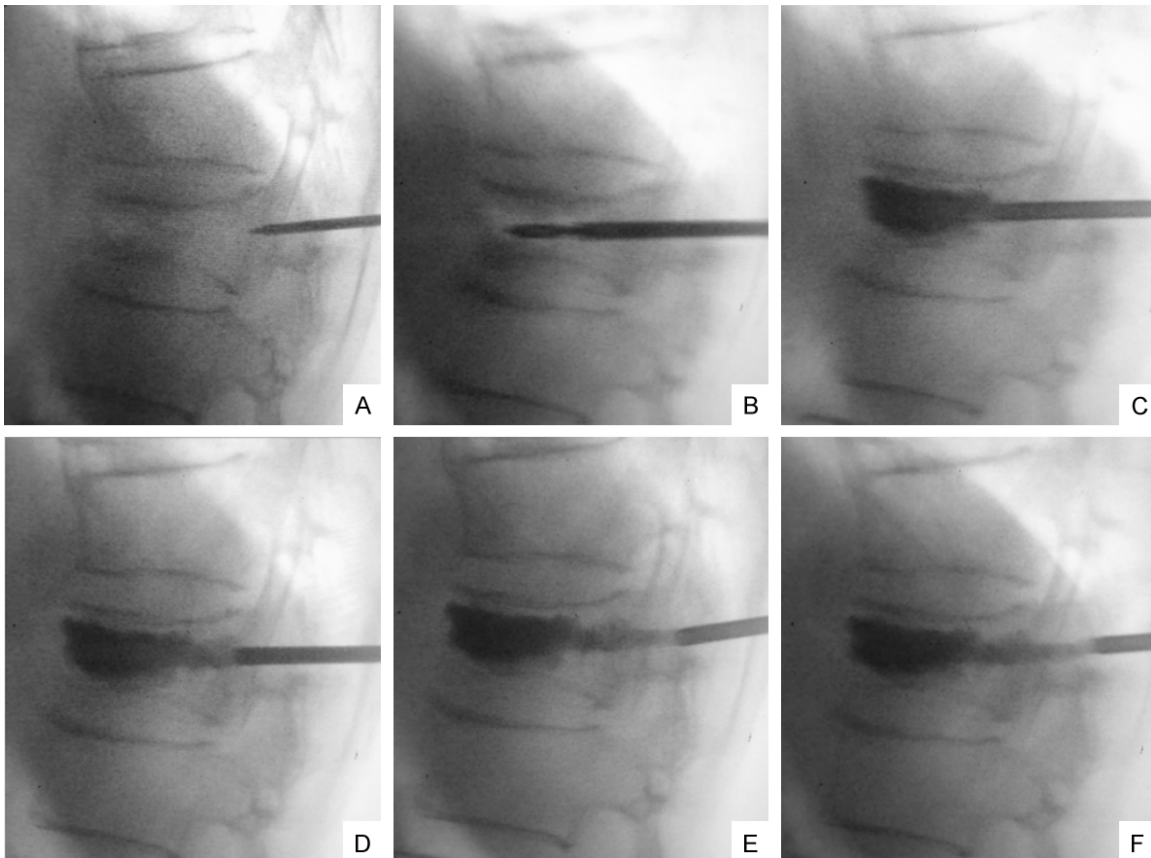


Figure 3. An example of treatment diagram. A: With robot-assisted, the trocar was punctured to the posterior edge of vertebral body and its accuracy was verified; B: Target punctured the trocar into the intravertebral vacuum cleft; C: Injected appropriate amount of bone cement to complete vertebroplasty; D-F: The trocar was slowly retracted dorsally while the bone cement was slowly injected, until the completion of pediculoplasty.

Table 1. The statistical analysis of VBI in 87 patients

Pari	Paired Differences					t	P
	Mean	Std. Deviation	Std. Error Mean	95% Confidence Interval of the Difference			
				Lower	Upper		
Pre. - Post.	-25.05862	7.71384	.82701	-26.70266	-23.41458	-30.300	.000
Pre. - 1 year	-24.84943	8.04552	.86257	-26.56416	-23.13469	-28.809	.000
Pre. - 2 years	-24.81839	8.12234	.87081	-26.54950	-23.08728	-28.500	.000
Post. - 1 year	.20920	1.10996	.11900	-.02737	.44576	1.758	.082
Post. - 2 years	.24023	1.17419	.12589	-.01002	.49048	1.908	.060
1 year - 2 years	.03103	.40038	.04293	-.05430	.11637	.723	.472

and one year after the surgery (86.86 ± 4.33) ($P = 0.060$; $P = 0.472$). The VBI improvement rate was 65.3% at the final follow-up (**Table 1**).

In terms of the evaluation of the correction of kyphotic deformity, the Cobb angle was corrected from $33.78 \pm 11.99^\circ$ preoperatively to $16.57 \pm 6.46^\circ$ postoperatively ($P = 0.000$), and

the postoperative correction rate was 50.9%. The thoracolumbar kyphotic angle was slightly increased at the final follow-up, with an average of $16.72 \pm 6.22^\circ$, but there was no significant difference compared with postoperatively and one year after the surgery ($16.69 \pm 6.20^\circ$) ($P = 0.091$; $P = 0.516$). The correction rate was 50.5% at the final follow-up (**Table 2**).

Pediculoplasty combined with vertebroplasty

Table 2. The statistical analysis of Cobb angle in 87 patients

Pari	Paired Differences					t	P
	Mean	Std. Deviation	Std. Error Mean	95% Confidence Interval of the Difference			
				Lower	Upper		
Pre. - Post.	17.20690	6.21726	.66656	15.88182	18.53198	25.814	.000
Pre. - 1 year	17.09195	6.42783	.68914	15.72200	18.46191	24.802	.000
Pre. - 2 years	17.05747	6.39105	.68519	15.69535	18.41959	24.894	.000
Post. - 1 year	-.11494	.82723	.08869	-.29125	.06136	-1.296	.198
Post. - 2 years	-.14943	.81453	.08733	-.32303	.02417	-1.711	.091
1 year - 2 years	-.03448	.49293	.05285	-.13954	.07058	-.652	.516

Table 3. The statistical analysis of VAS score in 87 patients

Pari	Paired Differences					t	P
	Mean	Std. Deviation	Std. Error Mean	95% Confidence Interval of the Difference			
				Lower	Upper		
Pre. - Post.	4.58621	1.20611	.12931	4.32915	4.84326	35.467	.000
Pre. - 1 year	5.64368	.93978	.10075	5.44338	5.84397	56.014	.000
Pre. - 2 years	5.72414	1.03080	.11051	5.50444	5.94383	51.796	.000
Post. - 1 year	1.05747	.98070	.10514	.84846	1.26649	10.058	.000
Post. - 2 years	1.13793	1.06937	.11465	.91002	1.36584	9.925	.000
1 year - 2 years	.08046	.55444	.05944	-.03771	.19863	1.354	.179

Table 4. The statistical analysis of ODI score in 87 patients

Pari	Paired Differences					t	P
	Mean	Std. Deviation	Std. Error Mean	95% Confidence Interval of the Difference			
				Lower	Upper		
Pre. - Post.	31.45977	7.25900	.77825	29.91267	33.00687	40.424	.000
Pre. - 1 year	57.72414	7.44701	.79840	56.13697	59.31131	72.300	.000
Pre. - 2 years	57.88506	7.44815	.79853	56.29764	59.47247	72.490	.000
Post. - 1 year	26.26437	7.88207	.84505	24.58447	27.94426	31.080	.000
Post. - 2 years	26.42529	7.80970	.83729	24.76081	28.08976	31.561	.000
1 year - 2 years	.16092	1.33707	.14335	-.12405	.44589	1.123	.265

The VAS score and the ODI score of the patients were improved from 7.47 ± 0.82 and 78.37 ± 7.14 points preoperatively to 2.89 ± 0.95 and 46.91 ± 8.44 points postoperatively, 1.83 ± 0.73 and 20.64 ± 4.57 points at one year, and 1.75 ± 0.69 and 20.48 ± 4.48 points at the final follow-up, respectively. The differences in each score between preoperatively, postoperatively, and at the last follow-up had statistical significance ($P < 0.05$, **Tables 3, 4**), while the comparison between the data at one year and the final follow-up had no statistical significance ($P = 0.179$; $P = 0.265$). Among them, the lower back pain and the thoracolumbar function were improved by approximately 61.3% and 40.1%

at discharge, respectively. The lower back pain and the thoracolumbar function were improved by approximately 65.1% and 56.3%, respectively, from postoperatively to the final follow-up. The overall improvement of the lower back pain and the thoracolumbar function in patients after the treatment was approximately 76.6% and 73.9%, respectively (**Tables 3, 4**). A typical case was shown in **Figures 4-6**.

Discussion

In recent years, as the population ages, the number of patients with Kummell's disease has also shown an increasing trend [23, 24].

Pediculoplasty combined with vertebroplasty

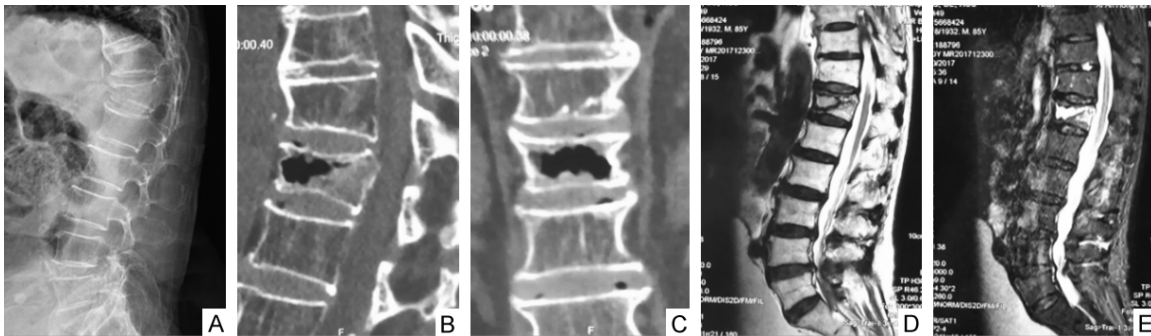


Figure 4. An 85-year-old male patient with T12 vertebral Kummell's disease. A: X-ray showed T12 vertebral collapse and kyphosis with VBI 53.8 and Cobb angle 38°; B and C: After postural reduction, CT examination showed that intravertebral vacuum cleft and bone deficiency at vertebral anterior border in T12 vertebrae. D and E: MRI showed that the intravertebral vacuum cleft in T12 vertebrae with edema signal.

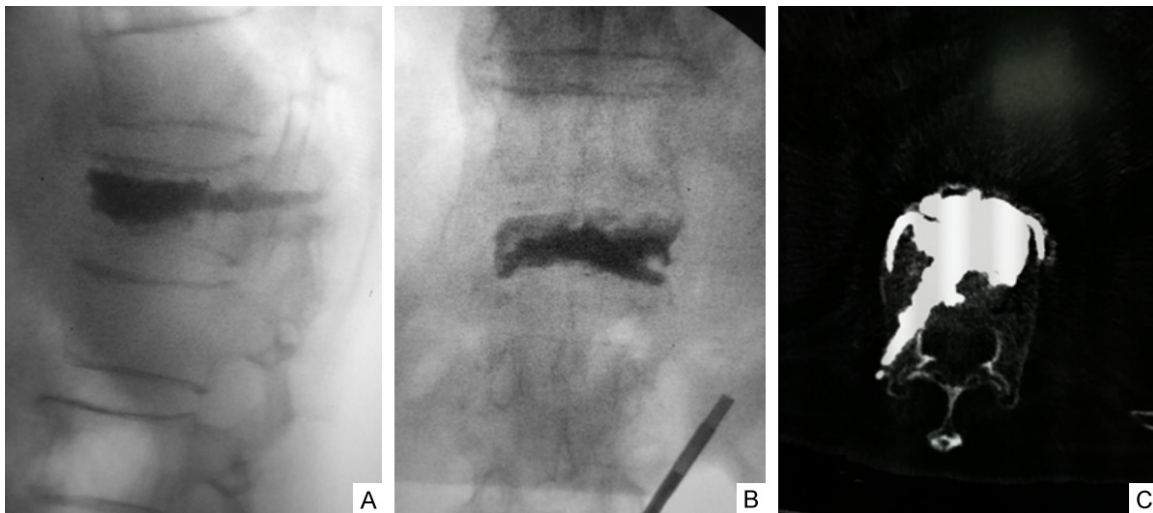


Figure 5. The patient treated by pediculoplasty combined with vertebroplasty. A and B: Postoperative X-ray showed bone cement was well distributed in IVC, bilateral vertebrae and pedicle, with VBI and Cobb angle changed to 86.1 and 22° respectively; C: Postoperative CT not only showed that the distribution of bone cement was good, but also the cement of vertebroplasty and pediculoplasty were linked together. The bone cement at the anterior edge of vertebral body continued to the whole pedicle through pediculoplasty.

Surgical intervention has become the preferred method for the treatment of Kummell's disease, and conservative treatment has gradually become an adjuvant therapy to surgical treatment due to its poor efficacy and the inability of patients to tolerate persistent progressive pain [24, 25]. Although vertebroplasty can satisfactorily relieve pain and improve kyphotic deformity and has become one of the most important modalities for the treatment of Kummell's disease, the surgical treatment approaches for Kummell's disease remain controversial in clinical practice. Various surgical methods, such as kyphoplasty, percutaneous fixation combined with vertebroplasty, open reduction, posterior

osteotomy, and anterior vertebrectomy, have all been reported in the literature [26-28]. In this paper, we present this novel surgical approach of robot-assisted pediculoplasty combined with vertebroplasty.

In 2002, pediculoplasty was first described by Gailloud to treat two cases of lytic pedicle lesions and complete pain relief was achieved [20]. Pediculoplasty is derived from vertebroplasty on the basis of the same pathologic mechanism, and as a technique also consists of the injection of PMMA into pedicles. Although pediculoplasty has been used in clinical practice for more than a decade, its application is

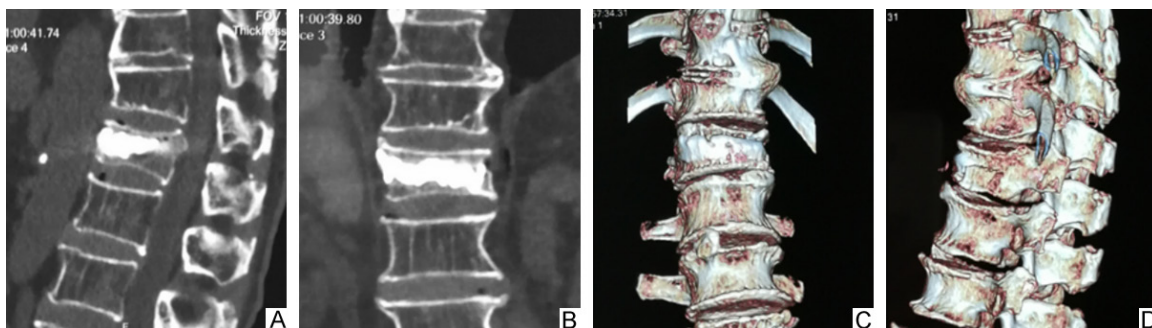


Figure 6. Postoperative follow-up imaging results of the patients. A and B: At the 1-year follow-up, sagittal and coronal CT examination showed that the position of bone cement in intravertebral vacuum cleft was good without displacement; C and D: At the 2-year follow-up, the position of bone cement was still well without displacement, and VBI and Cobb angle maintained at 85.3 and 21°.

still limited to pedicle fractures and lytic vertebral pedicle lesions, and its application in the treatment of Kummell's disease has not been reported [20-22, 29-31]. For pedicle fractures and lytic pedicle lesions, the purpose of pediculoplasty is to fix the pedicle, restore the stability of the damaged pedicle, and provide rapid pain relief. However, the purpose of its application in Kummell's disease is completely different.

The loss of spinal stability in Kummell's disease and the pain in patients is caused by its characteristic pathological change, the intravertebral vacuum cleft (IVC), but has nothing to do with the pedicle [24, 32]. IVC is a dead space formed by necrotic bone tissue that has been confirmed by pathology, and filling this dead space by vertebroplasty can achieve the goal of reconstructing spinal stability and relieving pain in patients. However, after bone cement is injected to fill the IVC dead space, it is very difficult for bone cement to penetrate into the normal trabecular bone structure, and the bone cement only occupies the cleft but has no mechanical interlocking or biocompatibility with the surrounding bone tissues, so the two are in a nonunion state. The inability of the two to fuse significantly increases the likelihood of cement displacement [16-18]. In this study, our purpose in using pediculoplasty was to integrate the bone cement and the surrounding bone tissue by interlocking. After completing vertebroplasty, bone cement was continuously injected until it penetrated the normal bone tissue of the entire pedicle, so that the bone cement in the IVC was connected to the whole vertebral body through the bone cement in the pedicle, thus avoiding the risk of bone cement displacement.

To achieve this goal, the injection of bone cement should not be interrupted at the end of vertebroplasty, but must continue till pediculoplasty is completed, which can ensure that the bone cement used for vertebroplasty and the bone cement used for pediculoplasty are connected. This is different from the pediculoplasty described by Eyheremendy et al. [22], where the cement can be injected either continuously or separately after vertebroplasty. Among our 87 patients, no one had delayed postoperative cement displacement, which strongly demonstrates the effectiveness of the pediculoplasty using this continuous injection technique. Through this two-year follow-up evaluation, it was evident that all of the imaging parameters of the patients had significantly improved. In terms of the vertebral body height, the VBI improved by 65.3%. For kyphotic deformity, the Cobb angle was corrected from the preoperative $33.78 \pm 11.99^\circ$ to $16.72 \pm 6.22^\circ$ at the final follow-up, and improvement rate was 50.5%. At the same time, the VAS for the lower back pain of patients had a 76.6% improvement, and the ODI for the thoracolumbar function had a 73.9% improvement. The clinical outcome was satisfactory. The results of this study demonstrate that the application of pediculoplasty combined with vertebroplasty for the treatment of Kummell's disease is safe and feasible.

According to our treatment experience, the greatest technical difficulty lies in the accuracy of bone cement trocar placement and the prevention of bone cement leakage, as this can lead to serious complications. First, it must be ensured that the trocar is targeted to the IVC; the IVC is the source of patient's pain, and good filling of the IVC with bone cement can relieve

Pediculoplasty combined with vertebroplasty

the pain and achieve satisfactory results. Second, it is necessary to ensure the integrity of the inner wall of the pedicle during the operation; damage to the inner wall may lead to leakage in the spinal canal or at the nerve root foramen during the subsequent cement injection, giving the patient symptoms of nerve damage, at which point the surgeon often has to do open surgery to remove the bone cement causing nerve compression. Tomasian et al. [30] suggested that bone cement tended to be distributed into the spinal canal due to its lower impedance when pediculoplasty was performed. Among the 51 patients treated with pediculoplasty by Martin et al. [21], 6% had intraspinal leakage, and 2% had foraminal leakage. Fortunately, the amount of bone cement injected into patients was small, and no symptoms of neurological damage occurred.

In view of the above, we used robot-assisted technology and proposed relevant precautions to avoid nerve injury caused by damage to the pedicle inner wall and bone cement leakage. The specifics included the following. (a) The puncture path was planned before the operation, and adjustments were made after intraoperative image matching, to ensure that the puncture path would not injure the inner wall of the pedicle. (b) The accuracy was verified twice during the placement of the guide needle and the trocar before cement injection. When the tip of the puncture needle reached the posterior edge of the vertebral body under the guidance of the lateral X-ray fluoroscopy, anteroposterior X-ray fluoroscopy was used to make sure that the tip of the puncture needle was within the projection of the pedicle and did not break through the medial edge. If intraoperative CT examination is available, the accuracy may be even higher when intraoperative CT scan is performed after the completion of the procedure. However, due to some limitations, we did not perform this examination in this group of patients; (c) We tried to make a successful puncture in a single attempt and avoid repeated punctures that would increase the risk of bone cement leakage. By using robot-assisted technology, our one-time success rate of puncture was 95.4%, and patients who failed all had a successful second puncture. Generally, the success rate of robot-assisted puncture was still satisfactory. (d) General anesthesia rather than local anesthesia was used. Under general

anesthesia, the patient had better postural reduction and held still, which improved the accuracy of the robot when it was in use. (e) An appropriate bone cement curing stage must be chosen for bone cement injection. When performing vertebroplasty, to obtain better bone cement distribution, the injection should be done during the wire-drawing stage. When the bone cement is too viscous, it may lead to poor bone cement bilateral distribution. When performing pediculoplasty, if the bone cement is too diluted, it may lead to bone cement leakage and nerve injury. Excessively viscous bone cement may separate during injection and cannot be connected with the bone cement of vertebroplasty, resulting in a poor effect on preventing bone cement displacement. Therefore, toothpaste-like bone cement should be selected for the treatment with pediculoplasty.

In this study, the relief of pain in patients was mainly the effect of vertebroplasty. Most studies have confirmed that the efficacy of unilateral vertebroplasty is similar to bilateral technique [11, 33]. For patients with Kummell's disease, the unilateral technique is sufficient to achieve a good bilateral cement distribution because of the low intravertebral pressure and low resistance to cement filling [26]. All 87 patients were successfully treated with the unilateral technique. We believe that the unilateral technique has the advantages of lower risk of cement leakage, shorter operation time, lower radiation exposure rate, good patient tolerance, and most importantly pediculoplasty only needs to be performed once. Theoretically, bilateral pediculoplasty combined with vertebroplasty has a better ability to avoid bone cement displacement, which is a natural deficiency of the unilateral technique. However, none of the patients had bone cement displacement after two-year follow-up, which indirectly suggests that the strength of unilateral technique to prevent the displacement of bone cement is enough, and the clinical goal of treatment can be achieved.

This study has the following shortcomings as a retrospective study of the early clinical application of robot-assisted pediculoplasty combined with vertebroplasty in the treatment of Kummell's disease without neurological impairment. First, the patients included in this study were all with single-segment Kummell's dis-

ease, but there are also some patients with multi-segment Kummell's disease. The results of this study cannot be widely applied to patients with multi-segment Kummell's disease. Second, while the follow-up period of 2-year in the present study was on par with most existing literatures, a longer follow-up (i.e. 5 years) might enable us to have a better understanding on the long-term effect of this novel surgical treatment. Third, although our sample was larger than that of any other relevant study, 87 patients is not many, which may limit the generalizability of the results of this study, so studies with larger samples are needed. In addition, this study lacks a control group (such as a pedicle screw fixation group, vertebroplasty alone group, etc.), and potential confounding factors such as the surgeon's habits and surgical conditions cannot be excluded. Completely randomized controlled studies with long follow-up and multicenter studies are still needed, which will eventually lay a solid clinical data foundation for the promotion of this technology.

In summary, it is safe and feasible to treat Kummell's disease without neurological impairment using robot-assisted pediculoplasty combined with vertebroplasty. This technique effectively prevents bone cement displacement and achieves rapid pain relief, with satisfactory vertebral body height restoration, and kyphotic deformity improvement.

Acknowledgements

This work was supported by the National Natural Science Foundation of China (No. 81802167), Natural Science Research Plan in Shaanxi Province of China (No. 2019JM197), and Sanitation and Health Research Fund of Shaanxi Province (2018E001).

Disclosure of conflict of interest

None.

Address correspondence to: Dr. Dingjun Hao, Department of Spine Surgery, Honghui Hospital, Xi'an Jiaotong University College of Medicine, No. 76 Nanguo Road, Xi'an 710054, Shaanxi, China. E-mail: dingjunhao@163.com

References

[1] Kummell H. Die rare fizierende Ostitis der Wirbelkorper. *Deutsche Med* 1895; 21: 180-181.

- [2] Matzaroglou C, Georgiou CS, Assimakopoulos K, Giannakenas C, Karageorgos A, Saridis A, Kafchitsas K and Wilke HJ. Kummell's disease: pathophysiology, diagnosis, treatment and the role of nuclear medicine. *Rationale according to our experience. Hell J Nucl Med* 2011; 14: 291-299.
- [3] Chen L, Dong R, Gu Y and Feng Y. Comparison between balloon kyphoplasty and short segmental fixation combined with vertebroplasty in the treatment of Kummell's disease. *Pain Physician* 2015; 18: 373-381.
- [4] Masala S, Nano G, Mammucari M and Simonetti G. Kummel disease treatment by unipedicular vertebral augmentation using curved injection cannula. *Cardiovasc Intervent Radiol* 2011; 34: 1014-1020.
- [5] Lee SH, Kim ES and Eoh W. Cement augmented anterior reconstruction with short posterior instrumentation: a less invasive surgical option for Kummell's disease with cord compression. *J Clin Neurosci* 2011; 18: 509-514.
- [6] Yu CW, Hsu CY, Shih TT, Chen BB and Fu CJ. Vertebral osteonecrosis: MR imaging findings and related changes on adjacent levels. *AJNR Am J Neuroradiol* 2007; 28: 42-47.
- [7] Kim DY, Lee SH, Jang JS, Chung SK and Lee HY. Intravertebral vacuum phenomenon in osteoporotic compression fracture: report of 67 cases with quantitative evaluation of intravertebral instability. *J Neurosurg* 2004; 100 Suppl: 24-31.
- [8] Hasegawa K, Homma T, Uchiyama S and Takahashi H. Vertebral pseudarthrosis in the osteoporotic spine. *Spine (Phila Pa 1976)* 1998; 23: 2201-2206.
- [9] Matzaroglou C, Georgiou CS, Assimakopoulos K, Saridis A, Khudiaev AT and Giannakenas C. Kummell's disease: a rare spine entity in a young adult. *Hell J Nucl Med* 2010; 13: 52-55.
- [10] Galibert P, Deramond H, Rosat P and Le Gars D. Note préliminaire sur le traitement des angiomes vertébraux par vertébroplastie acrylique percutanée Preliminary note on the treatment of vertebral angioma by percutaneous acrylic vertebroplasty. *Neurochirurgie* 1987; 33: 166-168.
- [11] Wang B, Guo H, Yuan L, Huang D, Zhang H and Hao D. A prospective randomized controlled study comparing the pain relief in patients with osteoporotic vertebral compression fractures with the use of vertebroplasty or facet blocking. *Eur Spine J* 2016; 25: 3486-3494.
- [12] Peh WC, Gelbart MS, Gilula LA and Peck DD. Percutaneous vertebroplasty: treatment of painful vertebral compression fractures with intraosseous vacuum phenomena. *AJR Am J Roentgenol* 2003; 180: 1411-1417.
- [13] Ma R, Chow R and Shen FH. Kummell's disease: delayed post-traumatic osteonecrosis of

Pediculoplasty combined with vertebroplasty

- the vertebral body. *Eur Spine J* 2010; 19: 1065-1070.
- [14] Liu F, Chen Z, Lou C, Yu W, Zheng L, He D and Zhu K. Anterior reconstruction versus posterior osteotomy in treating Kümmell's disease with neurological deficits: a systematic review. *Acta Orthop Traumatol Turc* 2018; 52: 283-288.
- [15] Krauss M, Hirschfelder H, Tomandi B, Lichti G and Bär I. Kyphosis reduction and the rate of cement leaks after vertebroplasty of intravertebral clefts. *Eur Radiol* 2006; 16: 1015-1021.
- [16] Nagad P, Rawall S, Kundnani V, Mohan K, Patil SS and Nene A. Postvertebroplasty instability. *J Neurosurg Spine* 2012; 16: 387-393.
- [17] Tsai TT, Chen WJ, Lai PL, Chen LH, Niu CC, Fu TS and Wong CB. Polymethylmethacrylate cement dislodgment following percutaneous vertebroplasty: a case report. *Spine (Phila Pa 1976)* 2003; 28: E457-E460.
- [18] Jeong YH, Lee CJ, Yeon JT, Bae J, Choi E, Lee PB and Nahm FS. Insufficient penetration of bone cement into the trabecular bone: a potential risk for delayed bone cement displacement after kyphoplasty? *Reg Anesth Pain Med* 2016; 41: 616-618.
- [19] Kim JE, Choi SS, Lee MK, Lee DK and Cho SI. Failed percutaneous vertebroplasty due to insufficient correction of intravertebral instability in Kummell's disease: a case report. *Pain Pract* 2017; 17: 1109-1114.
- [20] Gailloud P, Beauchamp NJ, Martin JB and Murphy KJ. Percutaneous pediculoplasty: polymethylmethacrylate injection into lytic vertebral pedicle lesions. *J Vasc Interv Radiol* 2002; 13: 517-521.
- [21] Martin JB, Wetzel SG, Seium Y, Dietrich PY, Somon T, Gailloud P, Payer M, Kelekis A and Ruefenacht DA. Percutaneous vertebroplasty in metastatic disease: transpedicular access and treatment of lysed pedicles—initial experience. *Radiology* 2003; 229: 593-597.
- [22] Eyheremendy EP, De Luca SE and Sanabria E. Percutaneous pediculoplasty in osteoporotic compression fractures. *J Vasc Interv Radiol* 2004; 15: 869-874.
- [23] Li KC, Li AF, Hsieh CH, Liao TH and Chen CH. Another option to treat Kümmell's disease with cord compression. *Eur Spine J* 2007; 16: 1479-1487.
- [24] Nickell LT, Schucany WG and Opatowsky MJ. Kummell disease. *Proc (Bayl Univ Med Cent)* 2013; 26: 300-301.
- [25] Fabbriani G, Pirro M, Floridi P, Callarelli L, Manfredelli MR, Scarponi AM and Mannarino E. Osteoanabolic therapy: a non-surgical option of treatment for Kümmell's disease? *Rheumatol Int* 2012; 32: 1371-1374.
- [26] Xiong XM, Sun YL, Song SM, Yang MY, Zhou J, Wan D, Deng XG and Shi HG. Efficacy of unilateral transverse process-pedicle and bilateral puncture techniques in percutaneous kyphoplasty for Kummell disease. *Exp Ther Med* 2019; 18: 3615-3621.
- [27] Liu F, Chen Z, Lou C, Yu W, Zheng L, He D and Zhu K. Anterior reconstruction versus posterior osteotomy in treating Kümmell's disease with neurological deficits: a systematic review. *Acta Orthop Traumatol Turc* 2018; 52: 283-288.
- [28] Kim HS and Heo DH. Percutaneous pedicle screw fixation with polymethylmethacrylate augmentation for the treatment of thoracolumbar intravertebral pseudoarthrosis associated with Kummell's osteonecrosis. *Biomed Res Int* 2016; 2016: 3878063.
- [29] Ke ZY, Wang Y, Zhong YL, Chen L and Deng ZL. Percutaneous vertebroplasty combined with percutaneous pediculoplasty for lytic vertebral body and pedicle lesions of metastatic tumors. *Pain Physician* 2015; 18: E347-E353.
- [30] Tomasian A, Wallace AN and Jennings JW. Pediculoplasty: novel steep anteroposterior projection fluoroscopy for imaging guidance. *J Vasc Interv Radiol* 2016; 27: 924-926.
- [31] Singh J, Baker MD, Morris PP and Whitlow CT. Percutaneous pediculoplasty for traumatic pedicle fracture. A technical case report. *Interv Neuroradiol* 2012; 18: 221-226.
- [32] He D, Yu W, Chen Z, Li L, Zhu K and Fan S. Pathogenesis of the intravertebral vacuum of Kümmell's disease. *Exp Ther Med* 2016; 12: 879-882.
- [33] Sun H and Li C. Comparison of unilateral and bilateral percutaneous vertebroplasty for osteoporotic vertebral compression fractures: a systematic review and meta-analysis. *J Orthop Surg Res* 2016; 11: 156.