

## Original Article

# The clinical study of CBCT imaging technology in the restoration of upper anterior teeth of the elderly

Sixuan Liu<sup>1\*</sup>, Suyu Wang<sup>2\*</sup>, Yabin Du<sup>3</sup>, Wanjun Zhang<sup>3</sup>, Xiuqing Cui<sup>2</sup>, Jinmei Xing<sup>2</sup>, Yanjing Zang<sup>2</sup>

<sup>1</sup>Department of Stomatology, Civil Aviation General Hospital, Beijing, China; <sup>2</sup>Geriatric Department, <sup>3</sup>Department of Stomatology, Second Hospital Baoding City, Baoding, China. \*Equal contributors.

Received February 5, 2021; Accepted February 25, 2021; Epub June 15, 2021; Published June 30, 2021

**Abstract:** Objective: To evaluate and analyze the clinical effect of CBCT imaging technology on the restoration of upper anterior teeth of the elderly. Methods: 36 elderly patients with upper anterior teeth loss in our hospital from January 2018 to January 2020 were selected for implant restoration. Patients were equally randomized into a curved tomographic restoration group (TR group) and a CBCT restoration group (CR group). Patients in the two groups underwent traditional implant restoration. Then we compared and analyzed the implant migration, the adjustment time of first wearing, and the success rate of axial gingival recession and restoration satisfaction of patients in the two groups. Results: The neck offset and the root offset of the implants in the CR group was  $(0.77\pm 0.15)$  mm and  $(0.83\pm 0.17)$  mm, respectively, which were significantly lower than  $(1.25\pm 0.27)$  mm and  $(1.73\pm 0.29)$  mm in the TR group ( $t=6.593$ ,  $t=11.359$ , all  $P<0.01$ ). The initial wearing adjustment time of patients in the CR group [ $(8.73\pm 1.94)$  min] was significantly less than  $(18.79\pm 4.85)$  min in the TR group ( $t=8.171$ ,  $P<0.01$ ); the CR group had a significantly higher success rate of axial gingival recession as compared to the CR group (94.44% vs 61.11%,  $\chi^2=6.0857$ ,  $P<0.05$ ); The restoration satisfaction rate of patients in the CR group was 100%, which was significantly higher than 77.78% of the TR group ( $\chi^2=8.7429$ ,  $P<0.05$ ). Conclusion: The CBCT imaging technology has a significant clinical effect on the restoration of the upper anterior teeth of the elderly, which effectively reduces the deviation of implant placement, shorten the adjustment time of their initial wearing, and greatly improves the success rate of axial gingival recession, effectively guarantees the long-term stability and aesthetics of dental implant restoration, and significantly enhances the satisfaction of patients.

**Keywords:** Elderly, upper anterior teeth restoration, CBCT imaging technology, clinical effect

## Introduction

A variety of body functions are aging over time and degrade. Dental problems such as loose tooth, tooth loss, etc. always afflict the elderly [1]. The upper anterior teeth loss is very common among the elderly, which not only causes physical pain and affects their appearance, but also adversely influences their quality of life [2, 3]. Implant restoration technology is clinically common in the treatment of tooth loss due to its good fixed effect and aesthetics [4]. With the advance of implantation and care about aesthetics, now more and more patients prefer to take the restoration of their upper anterior teeth [5]. During the implant restoration, good restoration effect and function of the implant depend upon sufficient bone mass on the lip and tongue side. However, teeth loss in the

upper anterior tooth area leads to poor bone mass, and the upper anterior tooth area, as an aesthetic area, needs restoring with skilled implant operation. Therefore, the implant of upper anterior tooth area is difficult in oral clinical research [6, 7]. Although the traditional implant restoration of upper anterior teeth was mostly operated by dentists with rich clinical experience, it is difficult to achieve the ideal effect in clinical practice [8]. In recent years, there have been many advances in clinical imaging technology. Dentists perform preoperative diagnosis and design by means of accurate imaging technology, which effectively improves the treatment effect of implant restoration in the upper anterior tooth area [9]. There are diverse common clinical imaging techniques such as curved tomography, spiral CT, cone beam CT (CBCT), etc. Curved tomography is

## CBCT imaging technology in the restoration of upper anterior teeth

used for routine inspection in clinical implant restoration because of low radiation dose, easy operation, panoramic projection, low cost, etc. [10]. As a new technology in dental implants, CBCT demonstrates the advantages of low radiation dose, high resolution, short projection time, low cost, etc., and increasingly applied in dental treatments such as dental implants [11, 12]. In this study, 36 elderly patients with upper anterior teeth loss in our hospital from January 2018 to January 2020 who intended to take implant restorations were selected, and we aimed to investigate the clinical effect of CBCT imaging technology on the restoration of the upper anterior teeth of the elderly.

### Materials and methods

#### *General materials*

We selected 36 elderly patients with upper anterior teeth loss in our hospital from January 2018 to January 2020 who were planned for implant restoration. According to the principle of randomization, all patients were equally randomized into a curved tomographic restoration group (TR group) and a CBCT restoration group (CR group).

#### *Inclusion/exclusion criteria*

Inclusion criteria: 1) This study was approved by the ethics committee of our hospital; 2) Patients were volunteered to participate in this study and sign the "Informed Consent Letter"; 3) Patients requested implant restoration; 4) Patients with complete bone plate of lip side; 5) Patients whose alveolar point absorption in the implant area was less than 1/3; 6) Patients with high compliance.

Exclusion criteria: 1) Patients with oral inflammation; 2) Patients with cognitive or mental disorders; 3) Patients with poor dental occlusion; 4) Patients with contraindications to implantation.

#### *Methods*

Patients in the TR group were examined by curved tomographic imaging technology. The midline of the patient's face was perpendicular to the ground, and the auditory orbital line was parallel to the ground. The images were projected with a curved tomography equipment

(Instrumentarium Dental I, Finland) that was set at 66 KV and 8 mA, with 15.8 s of exposure, and were produced in TIFF format. Software that comes with the curved tomography was applied to measure the bone height and quality of the edentulous area.

The CR group was examined with CBCT imaging technology. The midline of the patient's face was perpendicular to the ground, and the orbital line was parallel to the ground. CBCT (Green Smart, South Korea) was used to scan and set at 110 KV and 8 mA, with 3.8 s of exposure. And dentists separated the upper jaws from lower jaws and fixed them. Software Ez3D2009 was applied to measure the bone height, thickness and quality of the edentulous area and to simulate the implantation outcome.

Patients in the two groups received traditional implant restorations. Dentists designed the implant plan based on the imaging examinations. After routine oral cleaning and local anesthesia with articaine, the palatal side in the alveolar ridge crest of the edentulous area was selected as the lateral gap, and the labial distal gingival papilla of the adjacent teeth were selected as a loose incision. After the flap was opened, dentists reamed and made a cavity, and then placed the implant according to the designed implant plan. Next dentists installed the healing abutment and began to stitch the incision with absorbable sutures at the mesial and distal gingival papilla. In the end, dentists took pictures by means of CBCT. After 10 days, dentists removed the sutures and restored partial dentures. After three months of implantation, patients in the two groups tried on dentures, and dentists assisted in adjusting the restoration and ensured that dentures had no contact with the protruding and lateral sides. After adjustment, dentists polished the teeth and closed the screw holes.

#### *Observation indexes*

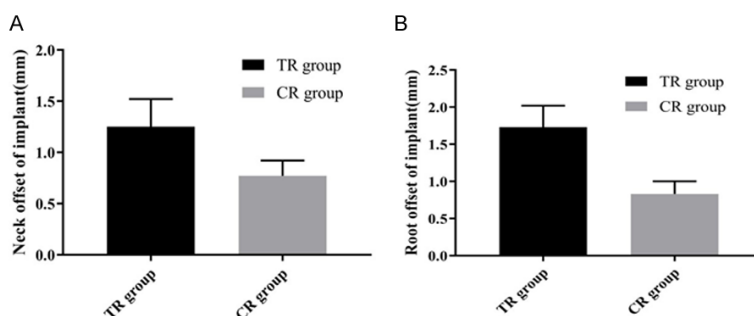
Implant deviation: CBCT was used to take pictures after implantation, and measure the root and neck deviation of the preoperative simulated implant point.

Adjustment time for first wearing: we recorded the average time that it took to adjust the restoration in each unit to satisfactory occlusion,

# CBCT imaging technology in the restoration of upper anterior teeth

**Table 1.** Comparison of general materials

Factors		TR group (n=18)	CR group (n=18)	$\chi^2/t$	p
Gender	Male	11	10	0.1143	0.869
	Female	7	8		
Ages (years old)		67.24±1.47	66.89±1.39	0.734	0.965
Upper anterior teeth loss (numbers)		3.24±1.42	3.17±1.37	0.151	0.931
BMI (kg/m <sup>2</sup> )		22.42±2.18	21.95±2.05	0.666	0.165
Education	Primary school	9	8	0.2805	0.974
	Middle school/vocational school	7	9		
	Three years diploma/above	2	1		



**Figure 1.** Comparison of neck offset of implants and implant root offset in two groups. Note: A. The X-axis represents the TR group, CR group and other groups, and the Y-axis represents the neck offset of implants. It is seen from **Figure 1** that the neck offset of the TR group was significantly higher than that of the CR group. B. The X-axis represents the TR group and CR group, and the Y-axis represents the root offset of implants. It is seen from the picture that the root offset of the TR group was significantly higher than that of the CR group.

edge tightness, and adjacency at the first wearing.

**Axial gingival recession:** Patients were followed up for 6-12 months. During the follow-up, the implant axial gingival recession of patients was evaluated. And its evaluation criteria were classified into A, B, C, and D. A meant that the gingival recession hadn't reached the membranous gingival joint; B meant that the gingival recession had reached the membranous gingival joint; C meant that the gingival recession has reached or exceeded the membranous gingival joint, without loss of alveolar bone soft and hard tissue; D meant the gingival recession reached or exceeded the membranous gingival joint, and combined with alveolar bone soft and hard tissue defects. The success rate of axial gingival recession = A/total cases × 100%.

**Restoration satisfaction:** A self-made questionnaire was used to evaluate the satisfaction with

the restoration effect, which was divided into very satisfied, relatively satisfied, satisfied, and dissatisfied.

### Statistical methods

All the data were analyzed and processed by SPSS19.0 software. The measurement data were expressed as  $(\bar{x} \pm s)$  with t-test for comparison, and the enumeration data were expressed as percentage with  $\chi^2$  for comparison.  $P < 0.05$  was statistically significant. Graph-Pad prism 8 software was used to draw graphics.

## Results

### Comparison of general data

The general data like age and the like were compared between the two groups ( $P > 0.05$ ). See **Table 1**.

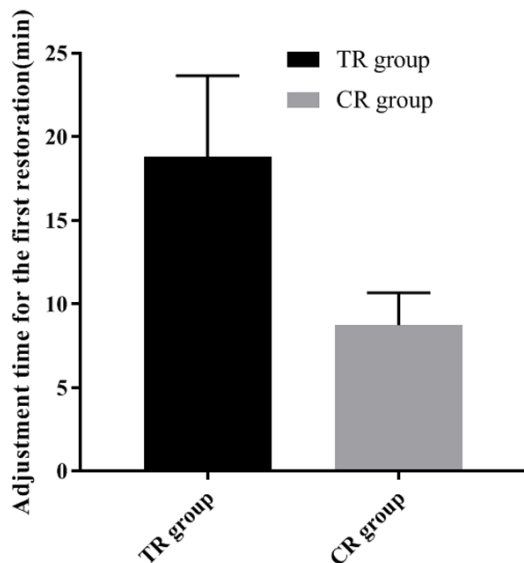
### Implant deviation

The neck offset and the root offset of the implants in the CR group was  $(0.77 \pm 0.15)$  mm and  $(0.83 \pm 0.17)$  mm, respectively, which was significantly lower than  $(1.25 \pm 0.27)$  mm and  $(1.73 \pm 0.29)$  mm in the TR group ( $t = 6.593$ ,  $t = 11.359$ ,  $P < 0.01$ ). See **Figure 1A**, **1B** for details.

### The adjustment time for initial wearing

Patients in the CR group spent shorter adjustment time on initial wearing as compared to the

## CBCT imaging technology in the restoration of upper anterior teeth



**Figure 2.** Comparison of the first adjustment time of patients in the two groups wearing restoration. Note: The X-axis represents TR group, CR group and other groups. It is seen from the picture that the adjustment time for the initial wearing in the TR group was significantly longer than that in the CR group.

TR group [(8.73±1.94) min vs (18.79±4.85) min,  $t=8.171$ ,  $P<0.01$ ]. See **Figure 2** for details.

### *Axial gingival margin recession and restoration satisfaction*

The CR group had a significantly higher success rate of axial gingival margin retraction of implants as compared to the TR group (94.44% vs 61.11%,  $\chi^2=6.0857$ ,  $P<0.05$ ). See **Table 2** for details.

The restoration satisfaction of patients in the CR group was 100%, which was significantly higher than 77.78% in the TR group ( $\chi^2=8.7429$ ,  $P<0.05$ ). See **Table 2** for details.

### **Discussion**

While aging, the dental problems such as loose teeth, teeth loss, etc. will always afflict the elderly. As the implant restoration technology advances, more and more elderly patients are receiving dental implant restoration to improve their facial beauty, chewing ability and quality of life. Dental implant restoration treatment is restoration-oriented, and the appearance of soft tissues around implants and the appearance of the restoration are almost as natural as

their own teeth, and ensures the long-term stability and health of osseointegration [13]. However, in the implant restoration, the restoration of the upper anterior tooth area has always been a medical difficulty. With the advance of implantation and care about aesthetics, now more and more patients prefer to take the restoration of their upper anterior teeth [5]. During the implant restoration, good restoration effect and function of the implant depend upon sufficient bone mass on the lip and tongue side. However, teeth loss in the upper anterior tooth area leads to poor bone mass, and teeth loss, especially multiple teeth loss, causes dentists not to have a reference for the placement during the treatment, leading to increased risk of deviation [14]. During the operation, implanting it in the accurate position and direction is the basis for the successful restoration of the upper anterior tooth area. Therefore, in general, experienced dentists conduct the restoration of the upper anterior tooth area and make pre-operative diagnosis and design by means of the accurate imaging technology, which is of great significance to improve the implant's success rate and treatment effects [15]. CBCT features low radiation dose, high resolution, short projection time, low cost, etc. It has become more widely used in oral treatments such as dental implants.

In this study, 36 elderly patients with upper anterior teeth loss in our hospital from January 2018 to January 2020 who were planned for implant restorations were selected, so as to explore and analyze the clinical effect of CBCT imaging technology on the restoration of the upper anterior teeth of the elderly. All patients were equally classified and then given CBCT and curved tomography respectively to assist dentists with the preoperative diagnosis and the treatment design of the upper anterior tooth restoration. The results showed that the neck offset and the root offset of implants in the CR group was (0.77±0.15) mm and (0.83±0.17) mm, respectively, which was significantly lower than (1.25±0.27) mm and (1.73±0.29) mm in the TR group ( $t=6.593$ ,  $t=11.359$ ,  $P<0.01$ ), consistent with those of Agnieszka Srebrzyńska-Witek and others [16]. He mentioned in his study that the neck offset of implants in the experimental group was (0.85±0.19) mm, which was significantly smaller than (1.28±

## CBCT imaging technology in the restoration of upper anterior teeth

**Table 2.** Comparison of success rate of axial gingival margin retraction of implants and restoration satisfaction of patients

Group	TR group (n=18)	CR group (n=18)	$\chi^2$	p
Total success rate of axial gingival margin retraction of implants	61.11%	94.44%	6.0857	0.001
A	11 (61.11%)	17 (94.44%)		
B	4 (22.22%)	1 (5.56%)		
C	3 (16.67%)	0 (0.00%)		
D	0 (0.00%)	0 (0.00%)		
Total patient satisfaction	77.78%	100%	8.7429	0.023
Very Satisfied	3 (16.67%)	7 (38.89%)		
Relatively satisfied	5 (27.78%)	9 (50.00%)		
Satisfied	6 (33.33%)	2 (11.11%)		
Dissatisfied	4 (22.22%)	0 (0.00%)		

0.22) mm in the control group ( $P < 0.05$ ), and the experimental group has significantly smaller root offset of implants as compared to the control group [(0.91±0.20) mm vs (1.75±0.31) mm,  $P < 0.05$ ]. It suggested that CBCT imaging technology instructed dentists to accurately complete the placement of implants in the restoration of the upper anterior teeth in the elderly and kept implants in ideal direction and position, so as to effectively improve the long-term stability of implants. Statistical analysis revealed that the CR group spent considerably shorter adjustment time on initial wearing as compared to the TR group [(8.73±1.94) min vs (18.79±4.85) min,  $t=8.171$ ,  $P < 0.01$ ], and the CR group had significantly higher restoration satisfaction than the TR group (100% vs 77.78%,  $\chi^2=8.7429$ ,  $P < 0.05$ ), which was consistent with a great many foreign studies [17-19]. In the meantime, it suggested that CBCT technology assisted dentists in designing restoration more accurately, so as to ensure the tightness and long-term stability of restoration, improved the restoration effect and shortened the adjustment time, which was of positive significance to improve satisfaction. Studies have also found that during the implant placement, the oblique direction of the lips affected the protrusion of the later restoration. If the angle was too large, it would cause the repulsion between the restoration and adjacent teeth and then affect the aesthetics. If the bone mass on the labial and buccal sides was insufficient, it would shrink the lip-side gums of implants during bone resorption, resulting in the exposure or even falling off of the implants.

Therefore, accurate imaging tests are necessary for preoperative evaluation to design a perfect and accurate surgical plan, which plays a key role in reducing gingival shrinkage of implants and improving aesthetics [20]. After 6-12-months of follow-up, it was found that the success rate of axial gingival margin recession in the CR group was 94.44%, which was significantly higher than 61.11% in the TR group ( $\chi^2=6.0857$ ,  $P < 0.05$ ). It confirmed the role of comprehensive dental evaluation and improving surgical plan CBCT was playing in the restoration of upper anterior tooth in the elderly, which effectively improved the success rate of axial gingival margin recession and kept restoration in the long-term stability. This study demonstrated that CBCT imaging technology has significant clinical effects in the restoration of upper anterior teeth of the elderly, avoiding the deviation of implants and shortening the adjustment time of initial wear. The success rate of axial gingival recession is improved, and the long-term stability and aesthetics of implant restoration are effectively ensured. However, the limitation of this study is that it did not conduct long-term follow-up observations on the life use of elderly patients, and the impact of implant restoration on the quality of life of the elderly. In the future, the number of cases will be expanded and the patients will be followed up for long-term investigation.

In summary, CBCT imaging technology has a significant clinical application effect on the restoration of the upper anterior tooth area in the elderly. The comprehensive dental evaluation



## CBCT imaging technology in the restoration of upper anterior teeth

through CBCT is beneficial to fully perfect the surgical plan. In the meantime, it effectively reduces the offset deviation of implants, shortens the adjustment time for the initial wearing, and greatly improves the success rate of axial gingival margin recession, which provides the basis for the long-term stability of dental restoration. Therefore, the restoration satisfaction significantly increased and this treatment is worthy of clinical application.

### Disclosure of conflict of interest

None.

**Address correspondence to:** Yanjing Zang, Geriatric Department, Second Hospital, Baoding City, 338 West Dongfeng Road, Baoding, China. Tel: +86-17732288606; E-mail: zangyanjing0815@163.com

### References

- [1] Vidal-Manyari PA, Arriola-Guillén LE, Jimenez-Valdivia LM, Dias-Da Silveira HL and Boessio-Vizzotto M. Upper airways evaluation in young adults with an anterior open bite: a CBCT retrospective controlled and cross-sectional study. *Int Orthod* 2020; 18: 276-285.
- [2] Arriola-Guillén LE, Valera-Montoya IS, Rodríguez-Cárdenas YA, Ruíz-Mora GA, Castillo AA and Janson G. Incisor root length in individuals with and without anterior open bite: a comparative CBCT study. *Dental Press J Orthod* 2020; 25: 23e1-23e7.
- [3] Gallichan N, Albadri S, Dixon C and Jorgenson K. Trends in CBCT current practice within three UK paediatric dental departments. *Eur Arch Paediatr Dent* 2020; 21: 537-542.
- [4] Fagundes PC, Pereira EHL and Reis RE. Iterative taxonomic study of *Pareiorhaphis hystrix* (Siluriformes, Loricariidae) suggests a single, yet phenotypically variable, species in south Brazil. *PLoS One* 2020; 15: e0237160.
- [5] Silveira BT, Fernandes KS, Trivino T, Dos Santos LYF and de Freitas CF. Assessment of the relationship between size, shape and volume of the sella turcica in class II and III patients prior to orthognathic surgery. *Surg Radiol Anat* 2020; 42: 577-582.
- [6] Tayebi Meybodi A, Borba Moreira L, Zhao X, Lawton MT and Preul MC. Transcavernous Approach to the upper basilar and retroclival area-cadaveric surgical simulation video: 2-dimensional operative video. *Oper Neurosurg (Hagerstown)* 2019; 17: E251.
- [7] Friedli L, Kloukos D, Kanavakis G, Halazonetis D and Gkantidis N. The effect of threshold level on bone segmentation of cranial base structures from CT and CBCT images. *Sci Rep* 2020; 10: 7361.
- [8] Ghoneima A, Cho H, Farouk K and Kula K. Accuracy and reliability of landmark-based, surface-based and voxel-based 3D cone-beam computed tomography superimposition methods. *Orthod Craniofac Res* 2017; 20: 227-236.
- [9] Jegham H, Masmoudi R, Ouertani H, Blouza I, Turki S and Khattech MB. Ridge augmentation with titanium mesh: a case report. *J Stomatol Oral Maxillofac Surg* 2017; 118: 181-186.
- [10] Kutlu HB, Goyushov S, Calisan B and Tözüm TF. Transplantation of autogenous bone block with an osseointegrated implant: seedling technique with twelve-month follow-up. *J Craniofac Surg* 2018; 29: e467-e471.
- [11] Bazina M, Cevidanes L, Ruellas A, Valiathan M, Quereshy F, Syed A, Wu R and Palomo JM. Precision and reliability of Dolphin 3-dimensional voxel-based superimposition. *Am J Orthod Dentofacial Orthop* 2018; 153: 599-606.
- [12] Kurrek A, Troedhan A and Konschake M. Contemporary CBCT diagnostics-discovery of a new artery with possible impact on surgical planning: the anterior superior palatal alveolar artery. *Surg Radiol Anat* 2018; 40: 1147-1158.
- [13] Frumkin N, Via S and Klinger A. Evaluation of the width of the alveolar bone in subjects with different gingival biotypes: a prospective cohort study using cone beam computed tomography. *Quintessence Int* 2017; 48: 209-216.
- [14] Sönmez G, Kamburoğlu K and Gülşahı A. Accuracy of high-resolution ultrasound (US) for gingival soft tissue thickness measurement in edentulous patients prior to implant placement. *Dentomaxillofac Radiol* 2020; 30: 20200309.
- [15] Raber A, Kula K and Ghoneima A. Three-dimensional evaluation of labial alveolar bone overlying the maxillary and mandibular incisors in different skeletal classifications of malocclusion. *Int Orthod* 2019; 17: 287-295.
- [16] Srebrzyńska-Witek A, Koszowski R, Różyto-Kalinowska I and Piskórz M. CBCT for estimation of the cemento-enamel junction and crestal bone of anterior teeth. *Open Med (Wars)* 2020; 15: 774-781.
- [17] Matsumura T, Ishida Y, Kawabe A and Ono T. Quantitative analysis of the relationship between maxillary incisors and the incisive canal by cone-beam computed tomography in an adult Japanese population. *Prog Orthod* 2017; 18: 24.
- [18] Lee AMH and Poon CY. The clinical effectiveness of alveolar ridge preservation in the maxillary anterior esthetic zone-a retrospective study. *J Esthet Restor Dent* 2017; 29: 137-145.

## CBCT imaging technology in the restoration of upper anterior teeth

- [19] Hatta W, Gotoda T, Koike T and Masamune A. Management following endoscopic resection in elderly patients with early-stage upper gastrointestinal neoplasia. *Dig Endosc* 2020; 32: 861-873.
- [20] Liu Q, Ding L, Qiu X and Meng F. Updated evaluation of endoscopic submucosal dissection versus surgery for early gastric cancer: a systematic review and meta-analysis. *Int J Surg* 2020; 73: 28-41.