

Original Article

Relationship between ultrasound values and pathology and metastasis in patients with breast cancer

Jilin Gan¹, Zhiwei Zhang²

¹Department of Ultrasound, Hangzhou Fuyang Women and Children Hospital, Hangzhou 311400, Zhejiang, China;

²Galactophore Department, Hangzhou Fuyang Women and Children Hospital, Hangzhou 311400, Zhejiang, China

Received February 1, 2021; Accepted April 23, 2021; Epub July 15, 2021; Published July 30, 2021

Abstract: Purpose: This study was designed to investigate the relationship between ultrasound values of breast cancer and its pathology and metastasis. Methods: A retrospective study was conducted on 80 patients diagnosed with breast cancer by pathologic examination in our hospital. The tumor size, tumor type, tumor grade, and the presence of distant metastasis were recorded. Vascular invasion, molecular subtype, pathobiologic indicators, and other measures were analyzed to explore the correlation between ultrasound measurements and pathology and metastasis in breast cancer patients. Result: The proportion of ultrasound scores did not differ significantly among the groups ($P > 0.05$). The enrolled subjects were grouped according to tumor types (intraductal carcinoma, invasive ductal carcinoma, invasive lobular carcinoma, and special types), tumor grade (grade 1-3), metastasis, vascular invasion, and pathobiologic indicators (positive or negative ER/PR and HER-2 expression). These factors affected the ultrasound scores of breast cancer patients, resulting in significant differences in the proportions of scores between the groups ($P < 0.05$). Conclusion: The ultrasound scores of breast cancer are closely related to its pathologic changes, and this has implications for the types of pathological tissues, biologic indicators, and presence of metastasis. Therefore, ultrasound values may be useful as a primary pathologic screening method for breast cancer patients.

Keywords: Breast cancer, ultrasound values, pathology, metastasis, correlation analysis

Introduction

Breast cancer is a malignant tumor originating from the glandular epithelial tissue of the breast [1]. Changes in lifestyle and dietary habits have elevated the incidence of breast cancer year by year. Data show that the annual numbers of new cases of breast cancer worldwide increased from 641,000 in 1980 to 1.7 million in 2012, with an average annual increase of 3.1% [2], and some researchers have predicted that new cases of breast cancer in China will reach 250,000 in 2021 [3]. Early clinical symptoms of breast cancer are subtle, thus hard to notice. Advanced breast cancer may show symptoms such as lumps, skin changes, and axillary lymph node metastasis, which causes a heavy burden on health of individuals. Thus timely and accurate determination of lesion types is of great significance for subsequent treatment [4, 5].

Currently, breast cancer is mainly diagnosed by pathologic examination and imaging tests,

among which, pathologic examination is invasive and has a long detection period [6]. In contrast, imaging tests have the advantages of rapid detection, being non-invasive, and reproducibility. For example, Doppler ultrasound tests have the advantages of high accuracy and resolution, and have been promoted clinically as a common imaging tool for breast diseases and play an important role in the diagnosis and treatment of breast cancer [7]. A review of imaging tests for breast cancer has found that 2D ultrasound images and color Doppler have evolved into effective techniques for early detection and diagnosis of breast cancer, and if high-frequency 2D ultrasound is combined with color Doppler ultrasound, it is possible to analyze breast lesions not only morphologically but also in terms of blood flow, which has a better diagnostic accuracy [8].

Although ultrasound has been widely used in the diagnosis and differentiation of breast disease, the correlation between ultrasound measures and pathologic and metastatic character-

istics of breast cancer has not been fully explored. By retrospective analysis, we compared clinically diagnosed breast cancer patients according to molecular subtype, metastasis, pathologic characteristics, etc., and preliminarily demonstrated the feasibility of ultrasound values to assess the pathologic and metastatic characteristics of patients with breast cancer.

Materials and methods

Baseline data

This was a retrospective study and data were collected from 80 patients with primary breast cancer admitted to the Breast Surgery Department from January 2018 to January 2020. All patients were female with unilateral onset, aged 29-73 years, with a median age of (50.19±2.39) years. All enrolled patients underwent bilateral breast ultrasound and the presence of masses was confirmed before surgery, and the presence of breast cancer was confirmed by postoperative pathology. This study received the approval of the medical ethics committee of Hangzhou Fuyang Women and Children Hospital. All subjects signed the informed consent before participating in the study.

Inclusion criteria: (1) preoperative presence of breast masses was confirmed by bilateral breast ultrasound; (2) the diagnosis of breast cancer was confirmed by postoperative pathology; (3) patients had complete medical data.

Exclusion criteria: (1) those who had received interventional treatment such as chemotherapy or radiotherapy before surgery; (2) those whose ultrasound test or postoperative pathology was not performed in our hospital; (3) pregnant or lactating women; (4) those with recurrent, metastatic breast cancer or breast cancer with local infection; (5) those with other concurrent malignancies.

Intervention methods

All subjects received ultrasound examination using ALOKA ARIETTA 70 (HITACHI, Japan). Patients lay in a supine position, with arms raised above the head, fully exposing the diseased breast and the ipsilateral axilla, and then the detection started from the central region of the patient's breast by an ultrasound high-frequency probe (8-10 MHz). First, we set the

detection mode to two-dimensional ultrasonography to observe the lesion repeatedly and multi-sectionally, and record the size, contour, boundary and internal echo of the mass. After completion of the two-dimensional ultrasonography, we switched the detection mode to ultrasound elastography mode, and performed a second round of detection to determine whether the mass was metastatic, tumor grading, and other indicators in detail.

Histopathological detection. Diseased tissues of the study subjects were obtained and embedded with paraffin, 4- μ m sections were made and stained with H&E for histopathological analysis. Histological evaluation was performed with reference to the 2003 World Health Organization (WHO) classification of breast pathology [9]. Whether tumor cells produced infiltration into surrounding adipose and fibrous tissues, whether tumor cells showed restricted growth, and whether there was interruption of normal breast tissues were determined.

Outcome measurement

Ultrasound scoring criteria: The scoring of lesion hardness on ultrasound elastography was carried out according to the Itot scoring method [10], and the hardness of the examined tissue could be distinguished according to the ultrasound color, 1: the lesion and its surrounding tissue were pink; 2: purple or interspersed with green; 3: predominantly green and interspersed with yellow; 4: predominantly yellow and interspersed with red, and 5: predominantly red. With the increase in the score, the hardness of the examined tissue also increased, with a score of < 3 considered as benign and ≥ 3 as malignant.

Histopathologic and testing criteria for lesions: According to WHO Classification of Breast Tumors (2003), the pathologic types are classified as ductal carcinoma, invasive ductal carcinoma, invasive lobular carcinoma, and special types. Tumor grading was performed according to Bloom-Richardson [11] grading standards. The lesions were graded as 1-3 according to cell morphology. Lymph node metastasis or vascular metastasis was determined with reference to pathologic testing. The expression of ER, PR, and HER-2 were detected with the same type of paraffin specimens used in pathologic testing. ER and PR staining were positive if the nucleus of breast cancer cells showed

Ultrasound values and breast cancer pathology and metastasis

Table 1. Correlation analysis between tumor size and ultrasound score [n (%)]

Tumor diameter	n	Ultrasound score		
		3 points	4 points	5 points
< 1 cm	15	2 (13.33)	3 (20.00)	10 (66.67)
1-2 cm	34	2 (5.88)	15 (44.12)	17 (50.00)
> 2 cm	31	8 (25.81)	10 (32.26)	13 (41.94)
F	-	2.228		
P	-	0.311		

Table 2. Correlation analysis between tumor type and ultrasound score [n (%)]

Tumor type	n	Ultrasound score		
		3 points	4 points	5 points
Intraductal cancer	14	3 (21.43)	6 (42.86)	5 (35.71)
Infiltrative ductal carcinoma	31	5 (16.13)	11 (35.48)	15 (48.39)
Invasive lobular carcinoma	21	2 (9.52)	6 (28.57)	13 (61.90)
Special type	14	2 (14.29)	5 (35.71)	7 (50.00)
F	-	6.669		
P	-	< 0.001		

Table 3. Correlation analysis between tumor grade and ultrasound score [n (%)]

Tumor grade	n	Ultrasound score		
		3 points	4 points	5 points
Level 1	15	6 (40.00)	4 (26.67)	5 (33.33)
Level 2	36	4 (11.11)	17 (47.22)	15 (41.67)
Level 3	29	2 (6.90)	7 (24.14)	20 (68.97)
F	-	10.198		
P	-	< 0.001		

brownish yellow, while HER-2 was positive when cell membrane showed brownish yellow. The molecular subtypes were divided into Luminal A, Luminal B, and triple negative type.

Statistical methods

The collected data were analyzed with SPSS 22.0 [12]. The measured data were expressed as ($\bar{x} \pm s$), and the independent samples t-test was used for the comparison between- and within-group. The counted data were expressed as [n (%)], and the χ^2 test was used for inter- and intra-group comparison. ANVOA was applied for the comparison of multiple points within groups. A value of $P < 0.05$ was considered significant. All statistical graphs were prepared using GraphPad Prism 8.

Results

Correlation analysis between tumor size and ultrasound score

A total of 80 lesions were detected in 80 patients. Ultrasound detection revealed that 15 cases of < 1 cm accounted for 18.75%, 34 cases of 1-2 cm accounted for 42.50%, and 31 cases of > 2 cm accounted for 38.75%. Ultrasound test results showed that 12 cases had a score of 3, 28 cases had a score of 4, and 40 cases had a score of 5. There was little difference in the proportion of ultrasound scores in patients with different tumor diameters ($P > 0.05$), suggesting tumor diameters had no significant effect on the ultrasound scores of breast cancer (Table 1).

Correlation analysis of tumor staging and ultrasound score

The pathologic examination showed that the percentage of 4 scores was the highest in intraductal carcinoma (42.86%), the percentage of 5 scores was the highest in invasive ductal carcinoma (48.39%), the percentage of 5 scores was the highest in invasive lobular carcinoma (61.90%), and the percentage

of 5 scores was the highest in special types (50.00%), with significant differences in the percentage of ultrasound sonographic scores among different tumor staging ($P < 0.05$) (Table 2).

Correlation analysis of tumor grade and ultrasound score

Among the 80 patients included in the study, 15 patients with grade 1 accounted for 18.75%, 36 patients with grade 2 accounted for 45.00%, and 29 patients with grade 3 accounted for 36.25%. The percentage of 3 was the highest in grade 1 (40.00%), the percentage of 4 was the highest in grade 2 (47.22%), and the percentage of 5 was the highest in grade 3 (68.97%), suggesting significant differences

Ultrasound values and breast cancer pathology and metastasis

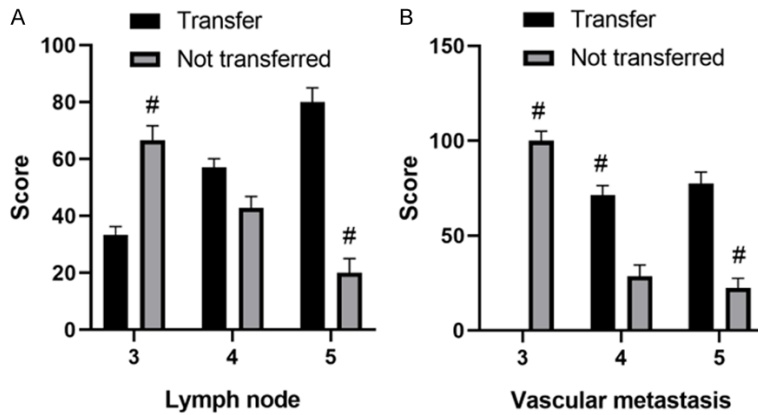


Figure 1. Correlation analysis between lymph node metastasis and vascular invasion and ultrasound sonographic scores. Lymph node metastasis (A); Vascular metastasis (B). # $P < 0.05$.

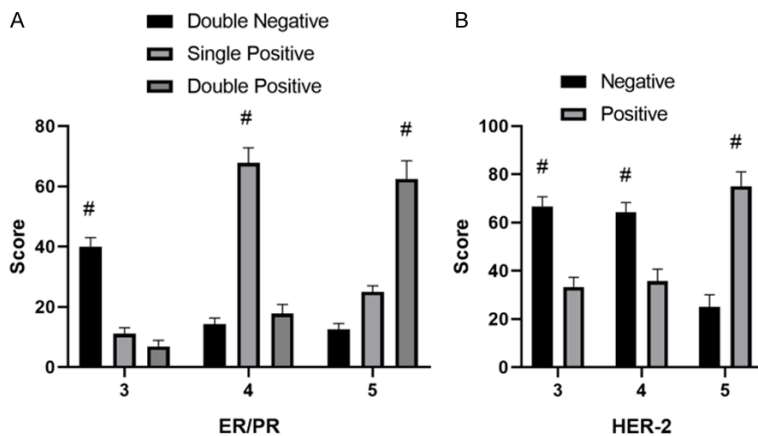


Figure 2. Correlation analysis between pathobiologic indicators and ultrasound score. ER/PR (A); HER-2 (B). # $P < 0.05$.

among patients with different tumor grades ($P < 0.05$) (Table 3).

Correlation analysis of lymph node metastasis and vascular invasion with ultrasound scores

A total of 52 patients (65.00%) had lymph node metastases, and 80% of patients with lymph node metastases were scored 5, followed by 4 and 3 (33%), showing a significant difference between groups ($P < 0.05$). A total of 51 patients had vascular metastases, accounting for 63.75%, with ultrasound scores showing significant difference between groups ($P < 0.05$) (Figure 1).

Correlation of pathobiologic indicators with ultrasound scores

As for ER/PR indicators, the double-positive patients showed the highest percentage of 5

scores (62.50%) and the lowest percentage of 3 scores (6.90%) ($P < 0.05$). The ER/PR test results of patients with different ultrasound scores were significantly different ($P < 0.05$). Among the patients with positive HER-2 expression, the ultrasound score of 5 points accounted for the highest percentage (75.00%), while 3 points was 33.33%, showing significant differences between groups ($P < 0.05$) (Figure 2).

Correlation between molecular subtype and ultrasound score

Molecular subtype analysis revealed that the highest percentage of Luminal A was 41.67% in those with an ultrasound score of 3, 42.86% in those with a score of 4, and 37.50% in both Luminal A and Luminal B in patients with a score of 5. This suggests there was no difference in ultrasound sonographic scores among patients with different molecular subtypes ($P > 0.05$) (Table 4).

Discussion

Breast cancer is one of the common malignant tumors in women [13], which is induced by genetic mutation and leads to abnormal proliferation of breast epithelial cells. The abnormal proliferation of cancer cells destroys the surrounding normal tissues and changes the normal structure of the breast [14]. Breast cancer mainly occurs in women aged 40-60 years. Genetic factors, ionizing radiation, and unhealthy diet have raised the incidence of breast cancer [15]. Since the symptoms of breast cancer are not obvious at the early stage, the condition is easily neglected, leading to delay in treatment and high mortality rate, so early diagnosis and treatment are of great significance to the prognosis of patients [16]. Imaging tests including ultrasound, magnetic resonance imaging (MRI), and mammography are of great value in the diagnosis and identification of

Ultrasound values and breast cancer pathology and metastasis

Table 4. Correlation analysis between molecular subtype and ultrasound scores [n (%)]

Ultrasound score	n	Molecular subtype		
		Luminal A	Luminal B	Triple negative
3 points	12	5 (41.67)	4 (33.33)	3 (20.00)
4 points	28	12 (42.86)	10 (35.71)	6 (21.43)
5 points	40	15 (37.50)	15 (37.50)	10 (25.00)
F	-		0.228	
P	-		0.767	

breast diseases, but traditional X-ray tests are less accurate. It has been found that X-ray tests have a misdiagnosis rate of 50% for breast cancer, and their sensitivity also decreases as the density of the breast increases [17].

In this study, we analyzed the correlation between ultrasonographic measures and the pathology and metastasis to demonstrate the feasibility of determining the pathologic features of breast cancer by ultrasonography. The results showed that there was little difference in ultrasound scores between subgroups of breast cancer patients with different tumor diameters. Clinical practice has found that the larger the diameter of a tumor, theoretically, the faster it proliferates. The little difference in ultrasound scores in this study may be due to the small sample size [18]. This study also analyzed the correlation between different tumor types and ultrasound scores. The results showed that there were significant differences in ultrasound scores in patients with ductal carcinoma, lobular carcinoma, and other types of lesions. A prospective study of 127 breast cancer patients has shown that patients with invasive lobular carcinoma and invasive ductal carcinoma have significant differences in ultrasound burrs, calcification, morphology, and rear echo attenuation. Highly differentiated breast cancer lesions are also different in blood flow and morphology, indicating a clear correlation between breast cancer ultrasound scores and histopathology, which is consistent with the results of this study [19]. A study showed that 84.71% of breast cancer tissues exhibited internal echogenic inhomogeneity and 70.41% of breast cancer patients had lesions with features such as burrs and indistinct margins, while the features of internal echogenicity varied widely among different types of breast cancer [20]. The pathologic types of breast cancer are usually classified as invasive ductal carcinoma,

invasive lobular carcinoma, intraductal carcinoma, lobular carcinoma in situ, etc. These showed significance in the severity of malignancy and prognosis and were also directly evidenced by the differences in ultrasound score. We speculate that the reasons are related to the different severity of malignancy of the lesions.

We also found that patients with the presence of lymph node metastases or vascular metastases tend to have higher scores, with 80.00% and 20.00% of 5 scores for lymph node metastases and no metastases, respectively. This suggests that breast cancer patients with metastases have a significantly higher chance of developing distant metastases. An analysis of the correlation between ultrasound performance and axillary lymph node metastasis in 144 breast cancer patients showed that blood flow Adler grading was closely related to axillary lymph node metastasis, and ultrasound was of great value in predicting the presence of axillary lymph node metastasis in breast cancer preoperatively [21]. Another study has found that the pathologic morphology of the edge of invasive breast cancer is caused by malignant cells breaking through the basement membrane and infiltrating into the interstitium. Therefore, its ultrasound results have a typical burr shape, which is also indicative of malignant transformation and can be used as a clinical diagnostic criterion [22]. This is similar to the results of this study. It is speculated that ultrasound detection has the advantages of non-invasiveness, good reproducibility, high resolution, and high accuracy, and ultrasound detection can identify the nature of the tumor by assessing the blood flow signal of the tumor in addition to observing the location, morphology, margin, and internal morphology. Breast cancer with distant metastasis often implies a higher risk of malignancy and invasiveness, which is reflected in ultrasound image features such as burr-like signs and unclear borders. This provides important references for the qualitative diagnosis of breast cancer [23, 24]. Finally, it was also found in this study that molecular indicators have good feasibility in assessing the pathological characteristics of breast cancer, which has actually been verified in the clinical setting [25]. ER, PR and HER-2 have been used as important indicators for the prognostic assessment of breast can-

cer, and previous studies have indicated that HER-2 is closely correlated with tumor blood flow abundance, and HER-2 positive cases tend to imply more abundant blood flow (67.2%) [26, 27]. This suggests that biomarkers of breast cancer patients are closely related to their ultrasound values.

In conclusion, ultrasound manifestations of breast cancer are closely related to its pathologic changes, namely, histologic type, molecular subtype, biologic indicators, and the presence of metastases. Ultrasound measures can be considered as a primary screening tool for breast cancer. The shortcoming of this study is the interference by subjective factors. This is inevitable when collecting ultrasound sonographic scores and various case data, which requires strengthening of quality control to eliminate errors.

Disclosure of conflict of interest

None.

Address correspondence to: Jilin Gan, Department of Ultrasound, Hangzhou Fuyang Women and Children Hospital, Hangzhou 311400, Zhejiang, China. Tel: +86-13732235899; E-mail: GanJiLin3027@163.com

References

- [1] Kolak A, Kamińska M, Sygit K, Budny A, Surdyka D, Kukiełka-Budny B and Burdan F. Primary and secondary prevention of breast cancer. *Ann Agric Environ Med* 2017; 24: 549-553.
- [2] Yang X, Wang H and Jiao B. Mammary gland stem cells and their application in breast cancer. *Oncotarget* 2017; 8: 10675-10691.
- [3] Seely JM and Alhassan T. Screening for breast cancer in 2018-what should we be doing today? *Curr Oncol* 2018; 25: S115-S124.
- [4] Funke M. Diagnostic imaging of breast cancer: an update. *Radiologe* 2016; 56: 921-938.
- [5] Rodgers KM, Udesky JO, Rudel RA and Brody JG. Environmental chemicals and breast cancer: an updated review of epidemiological literature informed by biological mechanisms. *Environ Res* 2018; 160: 152-182.
- [6] Siu AL. Screening for breast cancer: U.S. preventive services task force recommendation statement. *Ann Intern Med* 2016; 164: 279-296.
- [7] Weaver O and Leung JWT. Biomarkers and imaging of breast cancer. *AJR Am J Roentgenol* 2018; 210: 271-278.
- [8] Guo R, Lu G, Qin B and Fei B. Ultrasound imaging technologies for breast cancer detection and management: a review. *Ultrasound Med Biol* 2018; 44: 37-70.
- [9] McDonald ES, Clark AS, Tchou J, Zhang P and Freedman GM. Clinical diagnosis and management of breast cancer. *J Nucl Med* 2016; 57 Suppl 1: 9s-16s.
- [10] Nyayapathi N and Xia J. Photoacoustic imaging of breast cancer: a mini review of system design and image features. *J Biomed Opt* 2019; 24: 1-13.
- [11] Jafari SH, Saadatpour Z, Salmaninejad A, Momeni F, Mokhtari M, Nahand JS, Rahmati M, Mirzaei H and Kianmehr M. Breast cancer diagnosis: imaging techniques and biochemical markers. *J Cell Physiol* 2018; 233: 5200-5213.
- [12] Merino Bonilla JA, Torres Tabanera M and Ros Mendoza LH. Breast cancer in the 21st century: from early detection to new therapies. *Radiologia* 2017; 59: 368-379.
- [13] Kirova YM and Chen JY. Breast cancer: is radiotherapy of internal mammary nodes the “state of the art” or “reheating the cold dish”? About a discussion, review of the literature and own opinion. *Cancer Radiother* 2017; 21: 226-227.
- [14] Delort L, Bougaret L, Cholet J, Vermerie M, Billard H, Decombat C, Bourgne C, Berger M, Dumontet C and Caldefie-Chezet F. Hormonal therapy resistance and breast cancer: involvement of adipocytes and leptin. *Nutrients* 2019; 11: 2839.
- [15] Fiorica JV. Breast cancer screening, mammography, and other modalities. *Clin Obstet Gynecol* 2016; 59: 688-709.
- [16] Hughes K and Watson CJ. The multifaceted role of STAT3 in mammary gland involution and breast cancer. *Int J Mol Sci* 2018; 19: 1695.
- [17] Patel S, Delikat A, Liao J and Chetlen AL. Pre- and post-magnetic resonance imaging features of suspicious internal mammary lymph nodes in breast cancer patients receiving neoadjuvant therapy: are any imaging features predictive of malignancy? *Breast J* 2018; 24: 997-1000.
- [18] Rauch GM and Adrada BE. Comparison of breast MR imaging with molecular breast imaging in breast cancer screening, diagnosis, staging, and treatment response evaluation. *Magn Reson Imaging Clin N Am* 2018; 26: 273-280.
- [19] DiCorpo D, Tiwari A, Tang R, Griffin M, Aftreth O, Bautista P, Hughes K, Gershenfeld N and Michaelson J. The role of Micro-CT in imaging breast cancer specimens. *Breast Cancer Res Treat* 2020; 180: 343-357.
- [20] Adrada BE, Candelaria R and Rauch GM. MRI for the staging and evaluation of response to

Ultrasound values and breast cancer pathology and metastasis

- therapy in breast cancer. *Top Magn Reson Imaging* 2017; 26: 211-218.
- [21] Geisel J, Raghu M and Hooley R. The role of ultrasound in breast cancer screening: the case for and against ultrasound. *Semin Ultrasound CT MR* 2018; 39: 25-34.
- [22] Sood R, Rositch AF, Shakoob D, Ambinder E, Pool KL, Pollack E, Mollura DJ, Mullen LA and Harvey SC. Ultrasound for breast cancer detection globally: a systematic review and meta-analysis. *J Glob Oncol* 2019; 5: 1-17.
- [23] Guo Q, Dong Z, Zhang L, Ning C, Li Z, Wang D, Liu C, Zhao M and Tian J. Ultrasound features of breast cancer for predicting axillary lymph node metastasis. *J Ultrasound Med* 2018; 37: 1354-1353.
- [24] Luo WQ, Huang QX, Huang XW, Hu HT, Zeng FQ and Wang W. Predicting breast cancer in breast imaging reporting and data system (BI-RADS) ultrasound category 4 or 5 lesions: a nomogram combining radiomics and BI-RADS. *Sci Rep* 2019; 9: 11921.
- [25] Kwon BR, Chang JM, Kim SY, Lee SH, Kim SY, Lee SM, Cho N and Moon WK. Automated breast ultrasound system for breast cancer evaluation: diagnostic performance of the two-view scan technique in women with small breasts. *Korean J Radiol* 2020; 21: 25-32.
- [26] Guo Q, Zhang L, Di Z, Ning C, Dong Z, Li Z, Wang D, Liu C, Zhao M and Tian J. Assessing risk category of breast cancer by ultrasound imaging characteristics. *Ultrasound Med Biol* 2018; 44: 815-824.
- [27] Banys-Paluchowski M, Gruber IV, Hartkopf A, Paluchowski P, Krawczyk N, Marx M, Brucker S and Hahn M. Axillary ultrasound for prediction of response to neoadjuvant therapy in the context of surgical strategies to axillary dissection in primary breast cancer: a systematic review of the current literature. *Arch Gynecol Obstet* 2020; 301: 341-353.