Am J Transl Res 2021;13(7):8228-8234
www.ajtr.org /ISSN:1943-8141/AJTR0132302

Original Article

The safety of iodixanol in interventional therapy for patients of different ages with cerebrovascular diseases

Wanjie Geng, Qing Yang, Wei Wang, Qiduo Yin

Department of Neurology, Taihe County People's Hospital, Fuyang, Anhui Province, China

Received February 22, 2021; Accepted March 28, 2021; Epub July 15, 2021; Published July 30, 2021

Abstract: Objective: We aimed to explore the therapeutic effect and safety of iodixanol in interventional therapy for patients of different ages with cerebrovascular diseases. Methods: A total of 132 patients undergoing interventional therapy for cerebrovascular diseases in our hospital were analyzed retrospectively. The patients were divided into the young adult group (≤44 years old, 44 cases), the middle-aged adult group (45-59 years old, 48 cases), and the older adult group (≥60 years old, 40 cases). All patients were treated with iodixsanol as the contrast agent for cerebrovascular interventional therapy. The patients' renal function (serum creatinine (SCr) and blood urea nitrogen (BUN) levels) before and after treatment and the incidence of adverse reactions were compared among the three groups. Results: At 48 h before operation, 2 h after operation and 48 h after operation, the levels of SCr and BUN in the older adult group were higher than those in the young adult group (all P<0.001), whereas the levels of SCr and BUN were similar between the older adult group and the middle-aged adult group and between the middle-aged adult group and the young adult group (all P>0.05). Within each group, the levels of SCR and BUN at 48 h before operation did not differ from those at 2 h and 48 h after operation (all P>0.05). No intergroup differences were found in the incidences of adverse reactions after using iodixanol for cerebrovascular interventional therapy (all P>0.05). Conclusion: Iodixanol as a contrast medium shows good safety in interventional therapy for patients of different ages with cerebrovascular diseases; additionally, it has no significant impact on the renal function of patients and it leads to a low incidence of adverse reactions.

Keywords: Cerebrovascular intervention, iodixanol, renal function, adverse reaction

Introduction

Cerebrovascular diseases, such as cerebral aneurysm, cerebral embolism, and cerebral infarction, are common and frequently-occurring diseases. The incidence rate of cerebrovascular diseases has been rising each year and the disease can be life-threatening [1, 2]. With the development of medical technology, interventional therapy has been increasingly applied in the diagnosis and treatment of cerebrovascular diseases. Cerebrovascular interventional therapy is currently favored by the majority of clinicians as it is safe, minimally invasive, and can lead to a relatively low incidence of complications a well as having a rapid postoperative recovery [3].

However, with the wide application of cerebrovascular interventional technology, the safety of contrast agents used in the interventional procedure is now getting people's attention [4]. So far, nonionic iodinated contrast agents have almost replaced ionic iodinated agents, and contrast agents have progressed from high-osmolar agents to iso-osmolar agents and low-osmolar agents, which helps to reduce the occurrence of adverse reactions significantly. However, there are still some reports on the adverse reactions caused by the contrast agent in various examinations and treatments [5, 6].

In recent years, Iodixanol is a commonly used contrast agent in different interventional therapies. Compared with traditional contrast agents, such as iohexol and iopromide, iodixanol has less impact on renal function and can cause lower incidences of adverse reactions [7]. Although the safety of iodixanol in a variety of interventional therapies (for example, CT

imaging, coronary angiography, and cholangiography) has been verified by clinical studies, studies on the effect and safety of iodixanol in interventional therapy for cerebrovascular diseases are few [8-10]. Therefore, in this study, we aimed to explore the effect and safety of iodixanol in interventional therapy for patients of different ages with cerebrovascular diseases, in an effort to provide more theoretical basis and guidance for the application of iodixanol in cerebrovascular interventional therapy.

Materials and methods

Participants

In this retrospective study, we analyzed the clinical data of 132 patients who received interventional therapy for cerebrovascular diseases in our hospital between February 2019 and July 2020. The study was approved by the Ethics Committee of our hospital.

Inclusion criteria were: (1) patients with complete clinical data; (2) patients aged between 18 and 75 years old; (3) patients who underwent cerebrovascular interventional therapy for the first time; (4) patients who received iodixanol as the contrast agent in the interventional therapy, and patients who had no history of allergy to an iodine-containing contrast medium.

Exclusion criteria: (1) patients with incomplete clinical data; (2) patients who did not stop taking metformin, diuretics, or other related drugs 72 h before the interventional therapy according to the manufacturer's instructions of iodixanol; (3) patients with a severe neurological deficit, Hunt-Hess grade ≥III, cognitive dysfunction, or mental disease; (4) patients with tumor, severe infection, or dysfunction of important organs; (5) patients who needed angiographic intervention again for treatment or examination within 48 h after cerebrovascular interventional therapy.

According to different ages, the patients were divided into the young adult group (≤44 years old, 44 cases), the middle-aged adult group (45-59 years old, 48 cases), and the old adult group (≥60 years old, 40 cases).

Outcome measures

The levels of renal function markers, serum creatinine (SCr), and blood urea nitrogen (BUN), at 48 h before operation, 2 h after operation, and 48 h after operation with iodixanol as the contrast agent were observed and analyzed in the three groups as the main outcome measures.

The incidence of adverse reactions after the use of iodixanol for cerebrovascular interventional therapy was analyzed in the three groups as the secondary outcome measures.

Evaluation criteria

The diagnostic criteria for contrast-induced nephropathy (CIN) were as follows [11]. (1) Compared with the SCr level before the use of contrast agent, the SCr level increased by 25% or 44.2 μmol/L in the patients at 2 h and 48 h after the administration of the contrast agent; (2) There were abnormalities in the levels SCr or BUN (SCR ≥150 μmol/L, BUN ≥9 mmol/L) after using the contrast agent.

According to some literature, adverse reactions after the use of iodixanol included [12]. (1) Mild adverse reactions: fever, nausea, vomiting, local urticaria, etc. (2) Moderate adverse reactions: chest tightness, shortness of breath, facial redness and swelling, generalized urticaria, etc. (3) Severe adverse reactions: pale face, profuse sweating, dyspnea, disturbance of consciousness, low blood pressure, shock, etc.

An acute adverse reaction was defined as an adverse reaction occurring within one hour after injection of the contrast agent. A delayed adverse reaction was defined as an adverse reaction occurring from one hour to one week after injection of the contrast agent [13].

Statistical analysis

SPSS 26.0 was applied for data analysis. Measurement data were expressed as mean ± standard deviation. The independent samples t-test was used for comparison between groups, and one-way analysis of variance was conducted for pairwise comparison. Count data were presented as number or percentage and were examined by χ^2 test. $P<0.05$ indicated a statistically significant difference.

Table 1. Baseline data in the three groups (n, $\bar{x}$±sd)

Baseline data	Yung adult group (n=44)	Middle-aged adult group (n=48)	Older adult group (n=40)	χ^2/t/F	P
Age (years)	38.1±5.1	53.8±5.7	65.2±7.4	210.821	<0.001
Male/female (n)	18/26	20/28	17/27	0.944	0.624
BMI (kg/m²)	23.98±2.56	24.23±2.77	24.12±2.68	0.101	0.905
Presence of high blood pressure (n)	24	26	30	5.234	0.073
Presence of diabetes (n)	16	20	20	1.613	0.446
Presence of chronic kidney disease (n)	10	14	16	3.006	0.222
Presence of cardiovascular disease (n)	14	22	23	5.630	0.060
Presence of hypercholesterolemia (n)	20	26	20	0.697	0.706
History of smoking (n)	22	28	26	0.852	0.653
History of drinking (n)	14	22	23	5.630	0.060
Medication history (n)					
Antidiabetic agents	14	17	16	0.613	0.736
ACEI/ARB	12	14	15	1.150	0.563
Diuretics	10	28	27	19.298	<0.001
Lipid-lowering agents	18	22	17	0.238	0.888
Antiplatelet drugs	16	22	17	0.863	0.649
Anticoagulant	6	10	10	1.772	0.412
Type of interventional treatment (n)					
Internal carotid artery stent implantation	18	21	15		
Vertebral artery stent implantation	20	17	16	3.042	0.804
Subclavian artery stent implantation	5	7	8		
Middle cerebral artery stent implantation	1	3	1		

Note: BMI: body mass index; ACEI: angiotensin-converting enzyme inhibitor; ARB: angiotensin receptor blocker.

Results

Baseline data

Differences were observed in age and number of patients who had a history of taking diuretics among the three groups (all P<0.001), whereas no intergroup differences were found in other baseline data as shown in **Table 1** (all P>0.05).

Comparison of the three groups in the perioperative period

There were differences in the number of patients who received hydration before and after operation among the three groups (all P<0.01). No intergroup differences were observed in the surgical approach, preoperative hydration volume, operation duration, postoperative hydration volume, the method for iodixanol injection, and dosage of iodixanol (all P>0.05). See **Table 2**.

Renal function of the three groups before and after the operation

At 48 h before operation, 2 h after operation, and 48 h after operation, the levels of SCr and BUN in the older adult group were higher than those in the young adult group (all P<0.001), whereas the levels of SCr and BUN were similar between the older adult group and the middle-aged adult group and between the middle-aged adult group and the young adult group (all P>0.05). The levels of SCR and BUN at 48 h before operation did not differ from those at 2 h and 48 h after operation within each group (all P>0.05). See **Table 3** and **Figures 1**, **2**.

Incidences of adverse reactions in the three groups after the operation

There were 5 cases (3.79%) of adverse reactions after the interventional therapy with iodixanol as a contrast medium, including 4 cases of acute adverse reactions and 1 case of

Table 2. Comparison of the three groups in the perioperative period (n, %, $\bar{x}\pm$sd)

	Yung adult group (n=44)	Middle-aged adult group (n=48)	Older adult group (n=40)	χ^2/t/F	P
Surgical approach					
Femoral artery	43 (97.72)	45 (93.75)	36 (90.00)		
Radial artery	1 (2.27)	2 (4.17)	2 (5.00)	2.890	0.576
Brachial artery	0 (0.00)	1 (2.08)	2 (5.00)		
Preoperative hydration (n, %)	14 (31.82)	26 (54.17)	28 (70.00)	12.442	0.002
Preoperative hydration volume (mL, $\bar{x}\pm$sd)	502.32±332.68	512.88±343.12	528.68±360.73	0.062	0.940
Operation duration (h, $\bar{x}\pm$sd)	1.53±0.53	1.62±0.58	1.64±0.62	0.446	0.641
Postopeartive hydration (n, %)	16 (36.36)	30 (62.50)	34 (85.00)	20.873	<0.001
Postopeartive hydration volume (mL, $\bar{x}\pm$sd)	730.62±452.38	742.64±472.86	750.96±486.95	0.020	0.980
Methods for iodixanol injection (n, %)				2.074	0.354
Manual injection	32 (72.73)	39 (81.25)	34 (85.00)		
Mechanical injection	12 (27.27)	9 (18.75)	6 (15.00)		
Dosage of iodixanol (mL, $\bar{x}\pm$sd)	152.64±58.14	149.68±55.32	139.78±52.94	0.610	0.545

Table 3. Renal function of the three groups before and after the operation ($\bar{x}\pm$sd)

Group	SCr (μmol/L)	BUN (mmol/L)
Yung adult group (n=44)		
At 48 h before operation	56.35±19.32	5.32±1.29
At 2 h after operation	54.84±17.17	4.92±1.38
At 48 h after operation	54.62±18.26	4.85±1.24
Middle-aged adult group (n=48)		
At 48 h before operation	63.24±21.41	5.85±1.44
At 2 h after operation	62.14±22.38	5.75±1.46
At 48 h after operation	60.94±20.15	5.62±1.53
Older adult group (n=40)		
At 48 h before operation	71.82±21.45***	6.40±1.39***
At 2 h after operation	69.54±20.85***	6.22±1.43***
At 48 h after operation	69.12±22.46***	6.21±1.53***

Note: SCr: serum creatinine; BUN: blood urea nitrogen. Compared with the young adult group, ***P<0.001.

delayed adverse reaction. Among the 4 cases of acute adverse reactions, there were 3 cases of mild adverse reactions and 1 case of moderate adverse reaction. The case of delayed adverse reaction was a mild reaction. There were no severe adverse reactions in the three groups, and there were no intergroup differences in the incidence of adverse reactions (all P>0.05). See **Table 4**.

Discussion

With the rapid development and application of angiography, the safety of contrast medium used in angiography is now getting the attention of clinicians. Iodixanol is a non-ionic isosmotic contrast agent, which has been widely used in various types of angiographic examination and treatment. However, there is a lack of large-scale study on the safety of iodixanol in interventional therapy for patients of different ages with cerebrovascular diseases.

In this study, at 48 h before the operation, the SCr and BUN levels in the older-adult group were much higher than those in the middle-aged and the young adult groups. This result is related to the fact that older age is a major factor for renal function decline [14]. Meanwhile, the baseline data showed that the number of patients in the older adult group who had a history of taking diuretics was higher than those in the middle-aged and the young adult groups. Some studies have demonstrated that the use of various medications including diuretics may aggravate the renal function of patients and increase the levels of SCr and BUN [15]. Therefore, older age and a history of taking diuretics may be the reasons for the high levels of SCr and BUN in the older-adult group in this study.

Contrast-induced acute kidney injury (AKI) is one of the common causes of AKI, clinically. Some studies have indicated that contrast-induced AKI is related to various factors such

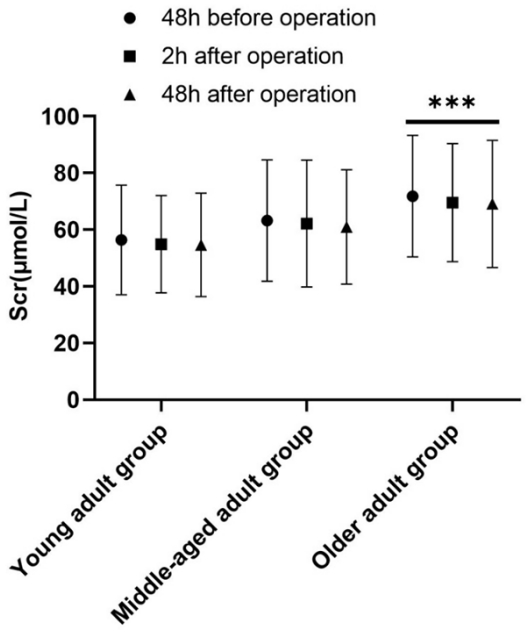

Figure 1. Levels of SCr in the three groups before and after the operation. Compared with the young adult group, ***P<0.001. SCr: serum creatinine.

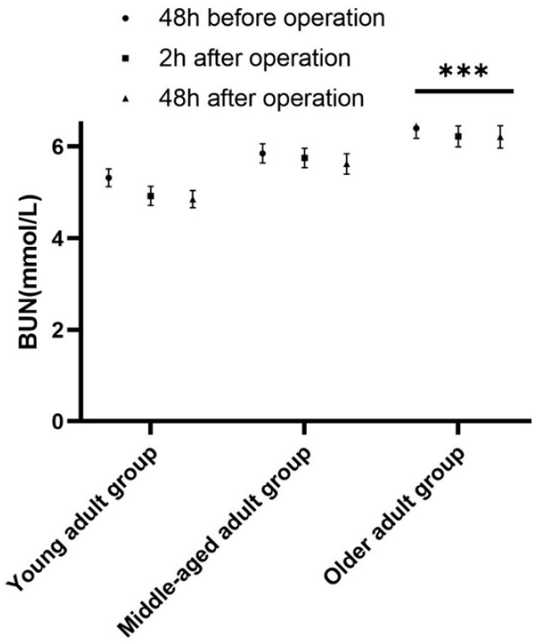

Figure 2. Levels of BUN in the three groups before and after the operation. BUN: blood urea nitrogen. Compared with the young adult group, ***P<0.001.

as the patient's age, renal function, and type of contrast agent used in the therapy [16]. One study reported that the use of iodixanol in percutaneous coronary intervention does not affect the incidence rate of AKI in patients complicated with chronic kidney disease at 72 h after the interventional therapy [17]. Another study demonstrated that the use of iodixanol in cerebral angiography and interventional therapy does not affect the renal function of the patients, and no case of postoperative AKI was observed in their study [18]. In the present study, the levels of SCr and BNU in the three groups at 2 h and 48 h after the interventional therapy were similar to those at 48 h before the operation, and there was no case of AKI that occurred. These results are consistent with the previous studies, suggesting that iodixanol for cerebrovascular interventional therapy is safe and does not increase the levels SCr and BUN of patients. According to the existing literature, older age and the presence of chronic kidney disease and diabetes are independent risk factors for AKI in patients after cerebrovascular interventional therapy [19]. In this study, none of the patients, including the elderly patients, had renal function damage after cerebrovascular interventional therapy with iodixanol as a contrast medium. The zero incidence of renal function damage in the elderly patients may be associated with the higher number of patients in the older adult group receiving hydration before and after the operation compared with the middle-aged and the young adult groups. It is commonly believed that hydration before and after surgery can effectively reduce the incidences of contrast-induced nephropathy and adverse reactions, and the results of this study align with this view [20, 21].

At present, there have been many reports about the adverse reactions of iodixanol in radiography, and the incidence rates of the adverse reactions differed between different studies. One study analyzed 20,418 cases of adverse reactions to nonionic iodinated contrast media and reported that the incidence rate of adverse reactions to iodixanol in CT imaging was 0.24%. Moreover, in that study, all adverse reactions to different nonionic iodinated contrast media were mainly acute, mild to moderate adverse reactions (mild to moderate adverse reactions accounted for 97.6%), and the incidence of mild to moderate adverse reactions to iodixanol was 100%; with no severe adverse reactions that occurred [22]. Another study analyzed 20,185 cases of adverse reactions to iodixanol in CT/coronary angiography and suggested that the

Table 4. Incidences of adverse reactions in the three groups after the operation (n, %)

	Yung adult group (n=44)	Middle-aged adult group (n=48)	Older adult group (n=40)	χ^2	P
Acute mild adverse reactions (n, %)	1 (2.27)	1 (2.08)	1 (2.50)	0.017	0.992
Acute moderate adverse reaction (n, %)	0 (0.00)	1 (2.08)	0 (0.00)	1.763	0.414
Delayed mild adverse reaction (n, %)	1 (2.27)	0 (0.00)	0 (0.00)	2.015	0.365
Incidence of adverse reactions (n, %)	2 (4.55)	2 (4.17)	1 (2.50)	0.270	0.874

total incidence of adverse reactions was 1.52%, of which the incidence of acute adverse reactions accounted for 0.58% [23]. Meanwhile, there have also been some case reports about adverse reactions from iodixanol [24].

In this study, there were five cases (3.79%) of adverse reactions after intravascular interventional therapy with iodixanol as a contrast agent. The three cases of acute adverse reactions were mild adverse reactions manifested as transient nausea and feeling hot and dry, and the symptoms were relieved spontaneously. One case of acute adverse reaction was a moderate adverse reaction that manifested as chest tightness and shortness of breath after the use of iodixanol. However, the patient who had the moderate adverse reaction had a history of coronary heart disease, and the symptom was relieved in the patient after we stopped the injection of iodixanol and placed a nitroglycerin sublingual tablet (0.6 mg) under the patient's tongue for 10 min. Afterward, the patient showed no more adverse reactions when we continued the injection of iodixanol. One case of a delayed adverse reaction was a mild reaction that presented with a red skin rash and pruritus on the face on the second day after the operation. After intravenous injection of dexamethasone (5 mg), the pruritus was relieved immediately, and the rash subsided spontaneously after one day. Our study results of the incidence of adverse reactions differed from those of previous studies, which may be due to the smaller sample size in our study. Moreover, since the patient with the moderate adverse reactions also had cardiovascular disease, it cannot be determined whether the patient's symptoms were caused by the onset of the cardiovascular disease or by iodixanol. Also, compared with coronary angiography and enhanced CT imaging, the number of blood vessels to be examined and the dose of contrast medium used in the cerebrovascular interventional procedure are higher, which may also be a major reason for the higher incidence of adverse reactions in our study compared with those of other studies.

However, there were still some limitations in our study. The sample size was relatively small, and the renal function of the patients was not observed at 72 h after operation. Therefore, more studies with a larger sample size need to be carried out in the future for verification.

In conclusion, iodixanol as a contrast medium shows good safety in interventional therapy for patients of different ages with cerebrovascular diseases, as it has no marked impact on the renal function of the patients and leads to a low incidence of adverse reactions.

Disclosure of conflict of interest

None.

Address correspondence to: Wanjie Geng, Department of Neurology, Taihe County People's Hospital, No. 21 Jiankang Road, Taihe County, Fuyang 236600, Anhui Province, China. Tel: +86-0558-8696501; E-mail: wanjiegeng@163.com

References

[1] Davis PH and Hachinski V. Epidemiology of cerebrovascular disease. neuroepidemiology. In: Davis PH and Hachinski V, editors. Florida: CRC Press; 1991. pp. 27-54.

[2] Caprio FZ and Sorond FA. Cerebrovascular disease. Med Clin North Am 2019; 103: 295-308.

[3] Xiao K. The application value of magnetic resonance angiography and ct angiography in the diagnosis of cerebrovascular diseases. Nuclear Industry 416 Hospi 2019.

[4] Okawa M, Higashi T, Fukuda K, Ogata T, Yoshioka T and Inoue T. Safety and feasibility of carotid artery stenting with dual-echo technique to minimize iodinated contrast dose. J Stroke Cerebrovasc Dis 2018; 27: 825-830.

[5] Tanaka H, Urushima M, Hirano S and Takenaga M. An acute adverse reaction with st eleva-

tion induced by magnetic resonance contrast media: kounis syndrome. Intern Med 2019; 58: 243-245.
[6] Olson MC, Atwell TD and Knudsen JM. Anaphylactic reaction to an ultrasound contrast agent (lumason) in a patient with systemic mastocytosis. J Clin Ultrasound 2018; 46: 533-535.
[7] Chalmers N and Jackson RW. Comparison of iodixanol and iohexol in renal impairment. Br J Radiol 1999; 72: 701-703.
[8] Zhang J, Jiang Y, Rui Q, Chen M, Zhang N, Yang H and Zhou Y. Iodixanol versus iopromide in patients with renal insufficiency undergoing coronary angiography with or without PCI. Medicine (Baltimore) 2018; 97: e0617.
[9] Ogura T, Imoto A, Okuda A, Fukunishi S and Higuchi K. Can iodixanol prevent post-endoscopic retrograde cholangiopancreatography pancreatitis? A prospective, randomized, controlled trial. Dig Dis 2019; 37: 255-261.
[10] McDonald JS, McDonald RJ, Williamson EE and Kallmes DF. Is intravenous administration of iodixanol associated with increased risk of acute kidney injury, dialysis, or mortality? A propensity score-adjusted study. Radiology 2017; 285: 414-424.
[11] Xu XJ, Zhang Q, Liu HL, Zhang XW and Chen GY. Effect of different atorvastatin doses on contrast-induced nephropathy after PCI. Chin J Geriatr. Heart Brain Vessel Dis 2018; 20: 32-36.
[12] Alcoceba E and Gaig P. Anaphylaxis reaction to iodixanol during coronary angiography. Allergy 2009; 64: 1103-1104.
[13] Xu ZX. Comparative analysis of adverse drug reactions caused by iodixanol and iohexol. Chin J Pharmacovigilance 2018; 15: 125-128.
[14] Muto NS, Kamishima T, Harris AA, Kato F, Onodera Y, Terae S and Shirato H. Renal cortical volume measured using automatic contouring software for computed tomography and its relationship with BMI, age and renal function. Eur J Radiol 2011; 78: 151-156.
[15] Divya M, Nivetha SR, Mohan L, Arul B And Kothai R. Drug-induced renal disorder-a mini review. Int J Res Pharm Sci 2020; 11: 166-172.
[16] Moniruzzaman. Contrast induced nephropathy - CIN. Kyamc J 2017; 4: 315.
[17] Gong R, Sun L, Wang XZ, Jing QM, Zhao X, Ma YY, Wang G and Han YL. A multicenter prospective registration study of iodixanol in the treatment of major adverse cardiovascular and cerebrovascular events and contrast-induced acute kidney injury, in Chinese patients with chronic kidrey disease undergoing percutaneous coronary intervention. Chin J Interv Cardiol 2018; 26: 191-197.
[18] Jiang MX, Ji Z, Zhou LY and Chen XG. Iodixanol used for cerebral angiography and stent implantation: observation of its safety. J Interv Radiol 2015; 24: 720-722.
[19] Cui D, Zhang XL and Sun Y. Clinical analysis of renal impairment caused by isotonic contrast agent in different people. J Liaoning Med Univ 2019; 40: 77-80.
[20] Dussol B, Morange S, Loundoun A, Auquier P and Berland Y. A randomized trial of saline hydration to prevent contrast nephropathy in chronic renal failure patients. Nephrol Dial Transplant 2006; 21: 2120-2126.
[21] Kotlyar E, Keogh AM, Thavapalachandran S, Allada CS, Sharp J, Dias L and Muller D. Prehydration alone is sufficient to prevent contrast-induced nephropathy after day-only angiography procedures--a randomised controlled trial. Heart Lung Circ 2005; 14: 245-251.
[22] Cao JX, Yao GL, Zhang KY, Wang R and Huang G. Adverse reactions induced by non-ionic iodinated contrast agent in 20,418 patients receiving CT examination. Chin J Med Imag 2017; 25: 876-880.
[23] Zhang BC, Hou L, Lv B and Xu YW. Post-marketing surveillance study with iodixanol in 20 185 Chinese patients from routine clinical practices. Br J Radiol 2014; 87: 20130325.
[24] Park JC, Ahn JH, Chang IB, Oh JK, Kim JH and Song JH. A case of unusual presentation of contrast-induced encephalopathy after cerebral angiography using iodixanol. J Cerebrovasc Endovasc Neurosurg 2017; 19: 184-188.