

Original Article

Effect of a modern stroke unit combined with recombinant human tissue-type plasminogen activator intravenous thrombolysis on ischemic cerebral infarction and its influence on limb motor function and activity of daily living

Qiulian Wang, Mingchao Hu, Pengfei Ye

Department of Neurology, Daye People's Hospital, Daye 435100, Hubei Province, China

Received January 20, 2021; Accepted February 21, 2021; Epub August 15, 2021; Published August 30, 2021

Abstract: Objective: To observe the effect of a modern stroke unit combined with recombinant human tissue-type plasminogen activator (rt-PA) intravenous thrombolysis on ischemic cerebral infarction and its impact on limb motor function and activity of daily living. Methods: In this prospective study, 82 patients with ischemic cerebral infarction who received treatment in our hospital were divided into two groups (41 cases in each group) according to the principle of randomized control. In the control group, patients received rt-PA intravenous thrombolysis. In the study group, patients received the modern stroke unit care combined with rt-PA intravenous thrombolysis. Before and after treatment, the clinical treatment efficacy, changes of serum inflammatory cytokines (hypersensitive C-reactive protein (hs-CRP), interleukin-6 (IL-6)), nerve factors (NSE, S100 β), nerve function (neurologic impairment score (NIHSS)), limb motor function (Fugl-Meyer scale score (FMA)) and activity of daily living (Barthel Index score) and adverse reactions were compared between the two groups. Results: The total effective rate in the study group (92.68%) was higher than that in the control group (73.17%, $P < 0.01$). Compared with those before treatment, the scores of NIHSS, FMA and Barthel indexes, and the levels of serum hs-CRP, IL-6, NSE and S100 β were improved in both groups after treatment, and the improvement in the study group was better than that in the control group (all $P < 0.001$). There was no statistically significant difference in the incidence of adverse reactions between the two groups (9.76% vs. 12.20%, $P > 0.05$). Conclusion: A modern stroke unit combined with rt-PA intravenous thrombolysis can effectively improve the clinical treatment efficacy, ameliorate the neurological function and limb motor function, reduce inflammatory reactions, promote the recovery of neurological function, and enhance the activity of daily living in the treatment of patients with ischemic cerebral infarction. Therefore, it is safe and worthy of further promotion.

Keywords: rt-PA intravenous thrombolysis, modern stroke unit, ischemic cerebral infarction, limb motor function, activity of daily living, inflammatory reaction

Introduction

Ischemic cerebral infarction is a common cerebrovascular disease seen in the clinic, which accounts for 60%-80% of the issues seen in stroke patients. Ischemic cerebral infarction has the characteristics of having an acute onset and being a severe illness. The clinical manifestations of patients are mainly language and limb dysfunction, which seriously threatens their life and health [1]. Ischemic cerebral infarction is mainly caused by insufficient blood supply to the brain, which damages the brain tissue. Patients are accompanied by neurologi-

cal impairment to varying degrees, which reduces limb motor function, and then leads to decreased or even complete loss of daily living ability, thus bringing a heavy burden to the family and society [2, 3]. Therefore, it is of great significance to treat ischemic cerebral infarction timely and effectively. At present, intravenous thrombolysis with recombinant human tissue-type plasminogen activator (rt-PA) is widely used for ischemic cerebral infarction in the clinic, aiming at re-canalizing the blood in the infarcted area and reducing the degree of nerve cell injury [4]. Although rt-PA intravenous thrombolysis is effective in treating ischemic

cerebral infarction, some patients have no obvious improvement in their clinical symptoms and still have a poor prognosis [5].

In recent years, the care of a modern stroke unit has been gradually applied to the clinical treatment of ischemic cerebral infarction, which can improve the clinical treatment efficacy through psychological intervention, rehabilitation training and other measures, and it has been well received by patients and clinicians [6]. Li et al. and other scholars have revealed that a modern stroke unit can effectively improve the neurological function and limb motor function in treating elderly patients with acute cerebral infarction, and the effect is obviously better than conventional medical treatment [7]. However, there are few clinical reports on the treatment of ischemic cerebral infarction with a modern stroke unit combined with rt-PA intravenous thrombolysis at home and abroad, and the curative effect needs to be further explored. Based on this, this study was designed to discuss the application effect of a modern stroke unit combined with rt-PA intravenous thrombolysis in ischemic cerebral infarction, aiming to provide reference for clinical treatment of this disease. The results are as follows.

Materials and methods

Baseline data

From May 2019 to April 2020, 82 patients with ischemic cerebral infarction who received treatment in our hospital were prospectively studied, including 48 males and 34 females, with an average age of (52.59 ± 3.92) years. They were divided into two groups (study group and control group) by a random number table method, with 41 cases in each group. In this study, all patients signed the informed consent, and this study was approved by the hospital ethics committee.

Selection criteria

Inclusion criteria: The patients met the diagnostic criteria for ischemic cerebral infarction [8]. The patient's infarct was confirmed by head MRI, CT and other imaging, and this was his/her first onset; the patient met the indications for thrombolysis; the patient was informed of and consented to the content of the study.

Exclusion criteria were as follows: allergy to the drugs used in the study; patients with poor compliance and those unable to cooperate with follow-up studies; lactating or pregnant women; those comorbid with cerebral hemorrhage, intracranial tumor and other diseases; patients with previous active bleeding or hemorrhagic diseases; those comorbid with severe abnormal liver and kidney function, and patients with cognitive dysfunction and infectious diseases.

Therapeutic methods

After admission, all patients were given routine treatment such as anti-platelet aggregation, improving microcirculation, nourishing brain nerves, controlling blood pressure, inhaling oxygen and scavenging of free radicals. In the control group, patients received intravenous thrombolysis with rt-PA (manufacturer: Boehringer Ingelheim Pharma GmbH & Co. KG, approval number: S20160054). The drug dose was 0.9 mg/kg. First of all, the patient was intravenously injected with 10% of the drug in the first minute, and the rest was added into 100 mL of normal saline for intravenous drip. The intravenous maximum dose was ≤ 90 mg. In the study group, patients were treated with modern stroke unit care combined with rt-PA intravenous drip, the delivery time was < 60 min, given once a day, and the intravenous thrombolysis, and rt-PA intravenous thrombolysis was consistent with that received in the control group.

Modern stroke unit treatment [9]. Patients were admitted to the stroke unit ward. A management team composed of attending physicians, rehabilitation therapists and nurses was set up to evaluate the specific condition of each patient in order to give targeted treatment and adjust the treatment plan according to their individual condition. The medical staff strengthened the health education of patients and their families, and gave targeted psychological intervention to relieve psychological pressure and improve treatment compliance. Patients were instructed to carry out rehabilitation training such as passive body training, posture transfer, and autonomous training depending on their conditions. An air pressure pump, neuromuscular electrical stimulation and other physical therapy were used to improve blood circulation. In both groups, patients were treated continuously for 4 weeks.

Outcome measures

Main outcome measures

Clinical efficacy: After treatment, the clinical efficacy was evaluated in both groups. Among them, if the clinical symptoms disappeared or improved significantly, and the NIHSS score decreased by more than 46% compared with that before treatment, this was regarded as “markedly effective” [10]. If the clinical symptoms improved, and the NIHSS score decreased by more than 18% but less than 46% compared with that before treatment, this was regarded as “effective”. If the clinical symptoms were not improved or aggravated, and the NIHSS score decreased by less than 18% or increased compared with that before treatment, this was regarded as “ineffective”. Total effective rate is the sum of effective rate and markedly effective rate.

Neurological function: After follow-up for 3 months, the neurological function of the patients was evaluated by NIHSS score before treatment and 3 months after treatment, including 11 items: visual field, facial paralysis, consciousness, etc. The total score was 0-42. The lower the score, the better the neurological function.

Limb motor function: Both before, and after treatment for 3 months, the limb motor function of patients was evaluated by Fugl-Meyer scale (FMA score), including upper limb motor function and lower limb motor function, with a total score of 0-100 [11]. The lower the score, the worse the motor function.

Activity of daily living: Before treatment and 3 months after treatment, the daily living ability of patients was evaluated by Barthel Index Scale, including 11 items: dressing, bathing, walking, etc., with a total score of 0-100 [12]. The lower the score, the worse the activity of daily living.

Secondary outcome measures

Inflammatory cytokine levels: In the morning, fasting venous blood was drawn from patients. After centrifugation, the serum levels of high sensitivity C-reactive protein (hs-CRP) and interleukin-6 (IL-6) were detected by immunoturbidimetry, both before, and after treatment for 3 months.

Nerve factor levels: The serum levels of neuron-specific enolase (NSE) and S100 β protein (S100 β) were detected by radioimmunoassay before and after treatment for 3 months. All the above kits were purchased from Guangzhou Chaobo Technology Co., Ltd., China.

Adverse reactions: The incidence of dizziness, fatigue, constipation and other adverse reactions were counted in the two groups.

Statistical processing

SPSS 23.0 was applied. The counting data (clinical efficacy, adverse reactions) were expressed as percentage, and tested by χ^2 test. The measurement data (the scores of NIHSS, FMA and Barthel indexes, the levels of serum hs-CRP, IL-6, NSE and S100 β) were expressed as ($\bar{x} \pm sd$). The independent sample t test and the paired sample t test were used for the comparison between the two groups and within the group before and after treatment. The difference was statistically significant with $P < 0.05$.

Results

Baseline data

The two groups had good comparability in age, gender, body mass index (BMI), time from onset to admission, and complications (all $P > 0.05$), indicating that the two groups were comparable (**Table 1**).

Clinical efficacy

The total effective rate in the study group (92.68%) was higher than that in the control group (73.17%, $P < 0.01$). It could be seen that the modern stroke unit combined with rt-PA intravenous thrombolysis could effectively improve the clinical treatment efficacy of patients with ischemic cerebral infarction (**Table 2**).

Nerve function, limb motor function and activity of daily living

Compared with those before treatment, the scores of NIHSS, FMA and Barthel indexes in the two groups were improved after treatment, and the improvement in the study group was better than that in the control group (all $P < 0.001$). It could be seen that the modern stroke unit combined with rt-PA intravenous thrombolysis could effectively improve the

Table 1. Comparison of baseline data between the two groups ($\bar{x} \pm sd$, n, %)

Group	Control group (n=41)	Study group (n=41)	χ^2/t	P
Gender (male/female)	23/18	25/16	0.201	0.654
Age (years)	52.4 \pm 3.8	52.7 \pm 3.8	0.357	0.722
BMI (kg/m ²)	25.12 \pm 2.36	24.89 \pm 2.29	0.448	0.656
Time from onset to visit (h)	4.21 \pm 1.39	4.09 \pm 1.42	0.387	0.700
Comorbidities (hypertension/diabetes/others)	14/10/8	15/11/8	0.001	0.976

Table 2. Comparison of clinical efficacy between the two groups (n, %)

Group	Remarkable effect	Effective	Invalid	Total effective
Control group (n=41)	14 (34.15)	16 (39.02)	11 (26.83)	30 (73.17)
Study group (n=41)	20 (48.78)	18 (43.90)	3 (7.32)	38 (92.68)
χ^2				7.256
P				0.007

Table 3. Comparison of nerve function, limb motor function and activity of daily living between the two groups ($\bar{x} \pm sd$, point)

Group	NIHSS score	FMA score	Barthel index score
Control group (n=41)			
Before treatment	28.63 \pm 4.25	46.85 \pm 3.74	58.25 \pm 5.52
After treatment	18.74 \pm 3.08***	65.91 \pm 6.06***	67.98 \pm 6.58***
Study group (n=41)			
Before treatment	28.78 \pm 4.19	46.97 \pm 3.58	58.74 \pm 5.61
After treatment	9.87 \pm 1.63***,###	74.98 \pm 6.32***,###	76.58 \pm 5.92***,###

Note: Compared with before treatment, ***P<0.001; Compared with the control group, ###P<0.001. NIHSS: neurologic impairment score.

neurological function and limb function, and enhance the daily living ability of patients with ischemic cerebral infarction (**Table 3** and **Figure 1**).

Serum inflammatory cytokines

Compared with those before treatment, the levels of serum hs-CRP and IL-6 in the two groups were decreased after treatment, and they were lower in the study group (all P<0.001). It could be seen that the modern stroke unit combined with rt-PA intravenous thrombolysis could effectively reduce the systemic inflammatory response of patients with ischemic cerebral infarction (**Table 4**).

Serum nerve factors

Compared with those before treatment, the levels of serum NSE and S100 β in the two groups

were decreased after treatment, and they were lower in the study group (all P<0.001). It could be seen that the modern stroke unit combined with rt-PA intravenous thrombolysis could effectively improve the neurological function of patients with ischemic cerebral infarction (**Table 5**).

Adverse reactions

There was no statistically significant difference in the incidence of adverse reactions between the two groups (9.76% vs. 12.20%, P>0.05). It could be seen that the modern stroke unit combined with rt-PA intravenous thrombolysis did not increase adverse reactions and had better safety in

patients with ischemic cerebral infarction (**Table 6**).

Discussion

The incidence of ischemic cerebral infarction is increasing annually, which is mainly related to cerebral artery occlusion or stenosis caused by atherosclerosis, cerebral thrombosis and other factors [13]. Clinically, it has been found that there is an ischemic penumbra around the lesion in patients with ischemic cerebral infarction, and the cells in this area are in a state of electric prostration. If blood perfusion is restored, the cells in this area will be reactivated, which can promote the recovery of nerve function [14]. Intravenous thrombolysis is a commonly used treatment for ischemic cerebral infarction, which can effectively remove arterial thrombosis and restore cerebral blood perfusion [15]. rt-PA is a new type of fibrin,

Effect of MSU + rt-PA intravenous thrombolysis on ICI and its influence

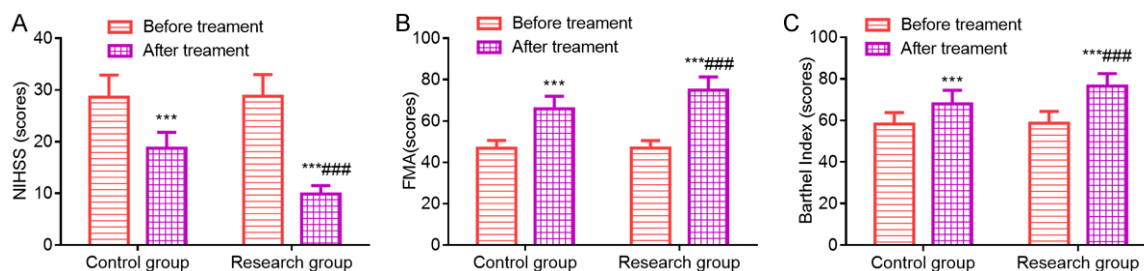


Figure 1. Comparison of nerve function, limb motor function and activity of daily living between the two groups. A: NIHSS; B: FMA score; C: Barthel index score. Compared with before treatment, *** $P < 0.001$; Compared with the control group after treatment, ### $P < 0.001$. NIHSS: neurologic impairment score; FMA: Fugl-Meyer scale.

Table 4. Comparison of serum inflammatory factors between the two groups ($\bar{x} \pm sd$)

Group	Control group (n=41)	Study group (n=41)	t	P
hs-CRP (mg/L)				
Before treatment	8.74±1.25	8.65±1.18	0.335	0.738
After treatment	5.36±1.08***	3.59±1.03***	7.594	<0.001
IL-6 (ng/L)				
Before treatment	18.25±2.14	18.39±1.98	0.308	0.759
After treatment	8.54±1.67***	5.47±1.59***	8.525	<0.001

Note: Compared with before treatment, *** $P < 0.001$. hs-CRP: hypersensitive C-reactive protein; IL-6: interleukin-6.

Table 5. Comparison of serum nerve factors between the two groups ($\bar{x} \pm sd$)

Group	Control group (n=41)	Study group (n=41)	T	P
NSE (mg/L)				
Before treatment	35.69±3.02	35.42±3.14	0.397	0.693
After treatment	25.36±3.15***	15.47±2.86***	14.884	<0.001
S100β (ng/L)				
Before treatment	2.78±0.85	2.83±0.87	0.263	0.793
After treatment	1.98±0.62***	1.45±0.57***	4.030	<0.001

Note: Compared with before treatment, *** $P < 0.001$.

Table 6. Comparison of adverse reactions between the two groups (n, %)

Group	Dizzy	Weakness	Constipation	Total effective
Control group (n=41)	2 (4.88)	1 (2.44)	1 (2.44)	4 (9.76)
Study group (n=41)	3 (7.32)	2 (4.88)	0 (0.00)	5 (12.20)
χ^2	0.000			
P	1.000			

which can combine with cellulose in arterial thrombosis, promote plasminogen to be converted into plasmin, and then dissolve the

thrombus, and it has less impact on the coagulation system and lower risk of bleeding [16]. In addition, rt-PA can inhibit platelet aggregation, reduce blood viscosity, improve blood circulation in brain tissue and repair ischemic penumbra cells [17].

The modern stroke unit is a new comprehensive treatment mode, aiming at improving the prognosis of patients. Through the administration of drugs, psychological intervention, rehabilitation training and other measures, the clinical treatment efficacy and the prognosis of patients can be improved [18]. This study was designed to apply modern stroke unit care combined with rt-PA intravenous thrombolysis in the clinical treatment of ischemic cerebral infarction. The results revealed that the total effective rate in the study group (92.68%) was higher than that in the control group (73.17%). Compared with those before treatment, the scores of NIHSS, FMA and Barthel indexes in the two groups were improved after treatment, and the improvement in the study group was better than that in the control group. There was no significant difference in adverse reactions

between the two groups. Studies by Han Xiao et al. have revealed that the effective rate of nerve stroke unit care combined with rt-PA intrave-

nous thrombolysis in the treatment of acute cerebral infarction is 97.14%, which is significantly higher than the conventional treatment (77.14%), and the scores of NIHSS and Barthel indexes are better than the conventional treatment, which is similar to the results of this study [19]. Therefore, modern stroke unit care combined with rt-PA intravenous thrombolysis can effectively improve the clinical efficacy, ameliorate the neurological function and limb function of patients with ischemic cerebral infarction, and enhance their ability of daily living, with better safety. The reasons are as follows: it is helpful to improve the clinical effect by setting up a modern stroke unit group and developing personalized treatment plans based on the patient's condition [20]. Strengthening health education and giving targeted psychological intervention can alleviate patients' negative emotions such as anxiety and fear, improve treatment compliance and ameliorate prognosis [21]. Emphasis on early rehabilitation training can promote patients to recover their limb motor function as soon as possible and improve their daily living ability. Physical therapy can promote muscle contraction, improve local blood circulation, and then promote physical recovery [22].

Clinical findings show that there is inflammatory reaction in patients with ischemic cerebral infarction, which leads to secondary injury of brain tissue, this aggravates the degree of hypoxia and ischemia in the brain tissue and increases the difficulty of treatment [23]. hs-CRP and IL-6 are typical inflammatory factors. When the body has an inflammatory reaction, hs-CRP and IL-6 levels rise, which can effectively reflect the degree of inflammatory reaction [24]. NSE is an isoenzyme of enolase, which exists in nerve tissue and neuroendocrine tissue, and it has the highest activity in brain tissue. When the body's nerves are injured, NSE is released into the blood in large quantities, which can effectively reflect the degree of nerve injury [25]. As an acidic calcium-binding protein, S100 β can nourish neurons, but its abnormal expression can cause neurotoxicity and damage nerves, and it can be used as an index to reflect the degree of nerve damage. The results of this study revealed that compared with those before treatment, the levels of serum hs-CRP, IL-6, NSE and S100 β in the two groups were decreased after treatment, especially in the

study group. It is suggested that modern stroke unit care combined with rt-PA intravenous thrombolysis can effectively reduce the degree of inflammatory reactions in the body and promote the recovery of neurological function in patients with ischemic cerebral infarction.

However, this research is from a single-center and is a small sample study, and the mechanisms of modern stroke unit care combined with rt-PA intravenous thrombolysis affecting inflammatory reactions in patients with ischemic cerebral infarction has not been explored. In the future, the scale of clinical research can be expanded for more in-depth study.

To sum up, modern stroke unit care combined with rt-PA intravenous thrombolysis can effectively improve the clinical treatment efficacy, ameliorate neurological function and limb motor function, reduce inflammatory reactions, promote the recovery of neurological function, and enhance the activity of daily living in the treatment of patients with ischemic cerebral infarction, all with better patient safety.

Disclosure of conflict of interest

None.

Address correspondence to: Pengfei Ye, Department of Neurology, Daye People's Hospital, No. 25 Dongfeng Road, Daye 435100, Hubei Province, China. Tel: +86-0714-8046038; E-mail: yepengfei25dy@163.com

References

- [1] Liu M, Pan Y, Zhou L and Wang Y. Low-dose rt-PA may not decrease the incidence of symptomatic intracranial haemorrhage in patients with high risk of symptomatic intracranial haemorrhage. *Neurol Res* 2019; 41: 473-479.
- [2] Meyer D, Chu F, Derry K and Hailey L. Acute reversal of dabigatran with idarucizumab for intravenous thrombolysis as acute stroke treatment. *J Clin Neurosci* 2019; 59: 355-357.
- [3] Yang Y, Sun W, Li D, Li XY, Wang XT, Li SC, Zhao HJ and Zhang JB. Multimode computed-tomography-guided thrombolysis under a prolonged time window in acute ischemic stroke patients with atrial fibrillation. *Int Heart J* 2019; 60: 822-829.
- [4] Ding JY, Bai ZX, Zhou D, Li XY, Rajah GB, Ding YC, Han J, Ji XM and Meng R. Circadian rhythms may not influence the outcomes of thrombolysis in patients with ischemic stroke: a study from China. *Chronobiol Int* 2018; 35: 1533-1542.

- [5] Yi K, Inoue M, Irie K, Mizoguchi T, Miwa K, Toyoda K and Koga M. Tissue plasminogen activator for cortical embolism stroke with magnetic resonance perfusion imaging: a report of two cases. *Case Rep Neurol* 2019; 11: 222-229.
- [6] Georgios T, Frederik G, Katsanos AH, Janika KR, Alexander K, Robert M, Michal R, Matthias W and Audebert HJ. Ultraearly intravenous thrombolysis for acute ischemic stroke in mobile stroke unit and hospital settings: a comparative analysis. *Stroke* 2018; 118: 21536.
- [7] Li YL, Sang C, Guo M and Yang Z. Effect of stroke unit on functional recovery of nerve defect in elderly patients with acute cerebral infarction. *Heilongjiang Med Pharm* 2020; 43: 30-32.
- [8] Guidelines for Diagnosis and Treatment of Acute Ischemic. Guidelines for diagnosis and treatment of acute ischemic stroke in China 2010. *Chin J Neurol* 2010; 43: 146-153.
- [9] Suissa L, Panicucci E, Perot C, Romero G, Gazzola S, Laksiri N, Rey C, Doche E, Mahagne MH, Pelletier J, Faivre A and Robinet-Borgomano E. Effect of hyperglycemia on stroke outcome is not homogeneous to all patients treated with mechanical thrombectomy. *Clin Neurol Neurosurg* 2020; 194: 105750.
- [10] Katsanos AH and Tsivgoulis G. Is intravenous thrombolysis still necessary in patients who undergo mechanical thrombectomy? *Curr Opin Neurol* 2019; 32: 3-12.
- [11] Qiu G, Yan YD, Zhang XF, Shen M, Qian J, Ma XD and Gu ZC. Successful thrombolytic therapy in acute ischemic stroke after reversal of warfarin: a case report. *Ann Palliat Med* 2020; 9: 2.
- [12] Wang Y, Zhang C, Sun W, Hu X, Lyu Z and Liu W. Effect of prehospital intervention based on emergency medical services on door-to-needle time of thrombolysis in acute ischemic stroke. *Zhonghua Wei Zhong Bing Ji Jiu Yi Xue* 2018; 30: 667-670.
- [13] Zhang Y, Yang YJ and Cheng JL. Pathophysiological basis of DWI and MRS in diagnosis of ischemic cerebral infarction. *J Pract Radiol* 2005; 21: 98-100.
- [14] Yang W, Zhang L, Yao Q, Chen W, Yang W, Zhang S, He L, Li H and Zhang Y. Endovascular treatment or general treatment: how should acute ischemic stroke patients choose to benefit from them the most? A systematic review and meta-analysis. *Medicine (Baltimore)* 2020; 99: 20187.
- [15] Al Khathaami AM, Al Bdah B, Tarawneh M, Alskaini M, Alotaibi F, Alshalan A, Almuhraj M, Aldaham D and Alotaibi N. Utilization of intravenous tissue plasminogen activator and reasons for nonuse in acute ischemic stroke in Saudi Arabia. *J Stroke Cerebrovasc Dis* 2020; 29: 104761.
- [16] Shen H, Yang P, Zhang L, Xing P and Liu J. Construction and application of information process management system in the treatment of acute ischemic stroke. *Chin J Cerebrovasc Dis* 2018; 15: 225-230.
- [17] Cashion, Catelyn, Gawarikar, Yash, Patel and Ronak. Description of a stroke unit mimic admissions. *J Neurol Neurosurg Psychiatry* 2018; 89: 31-33.
- [18] Steiner TJ and Rose FC. An emergency domiciliary stroke unit. *Practitioner* 1983; 227: 457-461.
- [19] Han X and Gao C. Study on the effect of RT PA intravenous thrombolysis in the treatment of acute cerebral infarction in stroke unit. *J Hubei Univ Sci Technol* 2018; 32: 119-121.
- [20] Reuter B, Stock C, Ungerer M, Hyrenbach S, Bruder I, Ringleb PA, Kern R and Gumbinger C. Only a minority of thrombectomy candidates are admitted during night shift: a rationale for diurnal stroke care planning. *Front Neurol* 2020; 11: 573381.
- [21] Tavares SF, Ferreira I, Chaves V, Flores L, Correia C, Almeida J, Fonseca L and Castro Chaves P. Acute ischemic stroke outcome and preceding anticoagulation: direct oral anticoagulants versus vitamin K antagonists. *J Stroke Cerebrovasc Dis* 2020; 29: 104691.
- [22] Eyding J, Bartig D, Weber R, Katsanos AH, Weimar C, Hacke W and Krogias C. Inpatient TIA and stroke care in adult patients in Germany - retrospective analysis of nationwide administrative data sets of 2011 to 2017. *Neurol Res Pract* 2019; 1: 39.
- [23] Huang XL. Association of serum levels of adipocyte fatty acid-binding protein and high-sensitivity C reactive protein with severity of acute ischemic stroke. *Cell Biochem Biophys* 2015; 72: 359-361.
- [24] Pawluk H, Grześk G, Kołodziejska R, Kozakiewicz M, Woźniak A, Grzechowiak E, Szumny M, Sobolewski P, Bieniaszewski L and Kozera G. Effect of IL-6 and hsCRP serum levels on functional prognosis in stroke patients undergoing IV-thrombolysis: retrospective analysis. *Clin Interv Aging* 2020; 15: 1295-1303.
- [25] Onatsu J, Vanninen R, Jääskelä P, Mustonen P, Pulkki K, Korhonen M, Hedman M, Höglund K, Blennow K, Zetterberg H, Herukka SK and Taina M. Tau, S100B and NSE as blood biomarkers in acute cerebrovascular events. *In Vivo* 2020; 34: 2577-2586.