

## Original Article

# Observation on the clinical effects of four kinds of root canal filling materials in the treatment of chronic periapical periodontitis

Ke Wang, Ying Chen, Hong Fu, Bo Zhong

Department of Stomatology, Shenzhen Second People's Hospital, Shenzhen 518000, Guangdong, China

Received September 29, 2025; Accepted December 11, 2025; Epub March 15, 2026; Published March 30, 2026

**Abstract:** Objective: To compare the clinical efficacy of four root canal filling materials for the treatment of chronic periapical periodontitis. Methods: The clinical data of 200 patients with chronic periapical periodontitis from January 2023 to October 2024 were retrospectively analyzed. Based on the different filling materials, the patients were divided into four groups: Group A (C-Root SP group), Group B (AH Plus group), Group C (Apexit Plus group), and Group D (iRoot SP group), with 50 patients in each group. The overall effective rate, pain status (Visual Analog Scale, VAS score), and Periapical Index (PAI) score were compared among the four groups. Results: There was no statistically significant difference in total effective rate among the four groups at 3 and 6 months after treatment ( $P > 0.05$ ). At 12 months after treatment, the total effective rate of groups A, B, and D was significantly higher than that of group C ( $P < 0.05$ ). There was no statistically significant difference in VAS scores among the four groups after treatment ( $P > 0.05$ ). At 12 months after treatment, the PAI scores of groups A, B, and D were significantly lower than those of group C ( $P < 0.05$ ). Conclusion: There is no significant difference in the short-term application effects of C-Root SP, AH Plus, Apexit Plus and iRoot SP in chronic periapical periodontitis, but the long-term effect and stability of Apexit Plus are relatively poor.

**Keywords:** C-Root SP, AH Plus, Apexit Plus, iRoot SP, root canal filling, chronic periapical periodontitis, short-term efficacy, long-term efficacy

## Introduction

Chronic periapical periodontitis refers to a persistent inflammatory disease of the tissues around the root apex. It is commonly seen in clinical practice and causes great harm to the oral health status of patients. This disease is characterized by easy recurrence and a relatively long course, with a high demand for treatment. Root canal treatment is one of the effective ways to treat this disease. Therefore, there are many related studies on various aspects of root canal treatment in clinical practice, and the related research on the selection of root canal filling materials is the main focus [1, 2]. C-Root SP, AH Plus, Apexit Plus and iRoot SP are root canal filling materials with a relatively high application rate in clinical practice, and each has its own advantages. iRoot SP has more advantages over AH Plus in terms of reducing the pain rate and saving the filling time, and

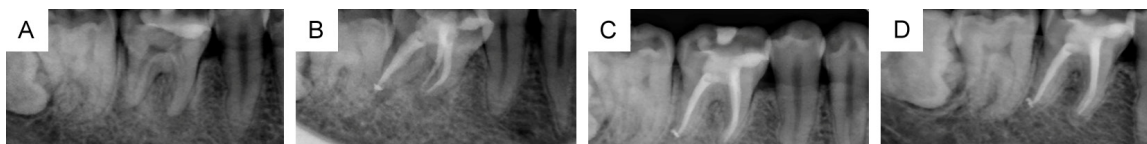the control of the degree of inflammatory reaction by the two is basically the same [6]. Apexit Plus has good tissue compatibility and is more helpful in controlling related adverse stimuli and reducing discomfort. However, the comprehensive and detailed research on the efficacy and stability of the four root canal filling materials is relatively insufficient [3-5]. In particular, as a new domestic material, C-Root SP is even more lacking in comparative studies with the classic materials previously used orally. Therefore, this study now explores the clinical effects and value of the four root canal filling materials including C-Root SP in those patients affected by chronic periapical periodontitis.

## Materials and methods

### Ethical statement

The study was reviewed and approved by the Clinical Research Ethics Committee of Shen-

## Four materials in the treatment of chronic periapical periodontitis



**Figure 1.** Cases treated with C-Root SP. A: Before surgery; B: 3 months after surgery; C: 6 months after surgery; D: 12 months after surgery.

zhen Second People's Hospital (2024-142-01PJ). Patient informed consent has been granted exemption.

### General data

The clinical data of 200 individuals with chronic periapical periodontitis from January 2023 to October 2024 were retrospectively analyzed. The preliminary experiment required 41 cases per group, but considering a 20% dropout rate, 50 cases were included in each group. The patients were allocated into four groups (A, B, C and D) based on different filling materials, with each group comprising 50 cases. In Group A, there were 30 males (35 teeth) and 20 females (23 teeth). The age range was 36 to 64 years and the average age was  $46.93 \pm 7.71$  years, including 26 premolars and 32 molars. In Group B, there were 29 males (34 teeth) and 21 females (23 teeth). The age range was 35 to 65 years and the average age was  $47.10 \pm 7.51$  years, including 25 premolars and 32 molars. In Group C, there were 28 males (33 teeth) and 22 females (24 teeth), with an age range of 37 to 65 years and an average age of  $47.21 \pm 7.69$  years, including 26 premolars and 31 molars. In Group D, there were 29 males (35 teeth) and 21 females (22 teeth), with an age range of 35 to 63 years and an average age of  $46.89 \pm 7.56$  years, including 25 premolars and 32 molars. No statistically significant difference was observed in the proportion of males and females, age and tooth position proportion among the four groups of patients with chronic periapical periodontitis ( $P > 0.05$ ).

**Inclusion criteria:** Those aged 20 to 65 years; Patients with chronic periapical periodontitis.

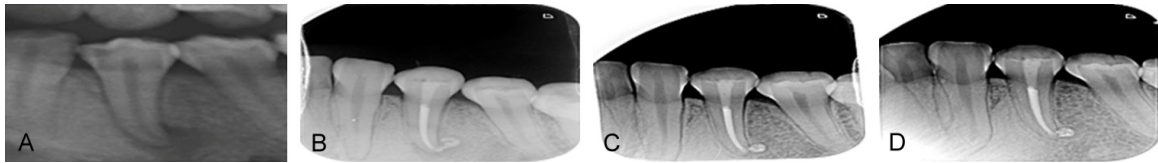
**Exclusion criteria:** Those who had used hormones or other drugs within one month; Those with low treatment compliance or unable to accept the whole process of follow-up visits; Those with dental fear; Those with normal mental status; Those with normal cardiopulmonary

function; Those with normal cognitive function; Those with periodontal pockets exceeding 5 mm and mobility exceeding degree I; Those with acute exacerbation of chronic periodontitis; Those with abnormal communication or cognition; Those with unstable vital signs; Those who did not sign up for the group.

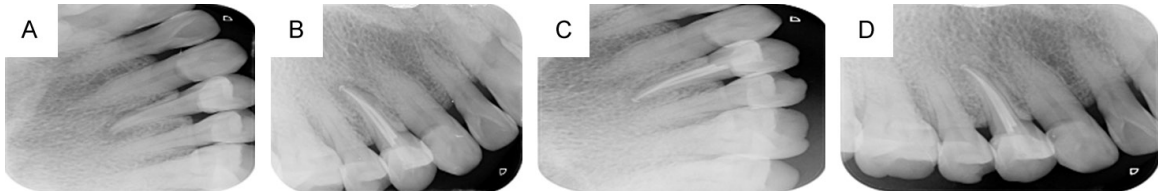
### Methods

All the patients in the four groups underwent root canal filling treatment. First, the patients' conditions were carefully evaluated, and the treatment plan was formulated according to the results of X-ray examination. The surrounding conditions were probed, and treatments such as pulp cavity opening and root canal dredging were carried out. After measuring the working length, root canal preparation was performed. During the whole process of preparing the root canal, the root canals were soaked with sodium hypochlorite. The WaveOne® Gold system (Densply) root canal files were used for root canal treatment, and then the ultrasonic root canal irrigator (Satelec) was used for root canal irrigation treatment. The drugs for root canal irrigation were 17% EDTA, 3% sodium hypochlorite and normal saline. Each root canal was irrigated with EDTA twice, 30 seconds each time, with a total duration of 1 minute. Each root canal was ultrasonically irrigated with sodium hypochlorite for 20 seconds, three times in total, with a total duration of 1 minute. Finally, it was rinsed with saline solution, and then a calcium hydroxide paste was used for temporary sealing treatment. One week later, those without symptoms and/or exudation underwent root canal treatment. First, effective cleaning was carried out. After ultrasonic irrigation and drying, C-Root SP (**Figure 1**) was applied in Group A, AH Plus (**Figure 2**) was applied in Group B, Apexit Plus (**Figure 3**) was applied in Group C, and iRoot SP (**Figure 4**) was applied in Group D. The above filling materials were slowly inserted with appropriate tapered gutta-percha points until reaching the working length, and

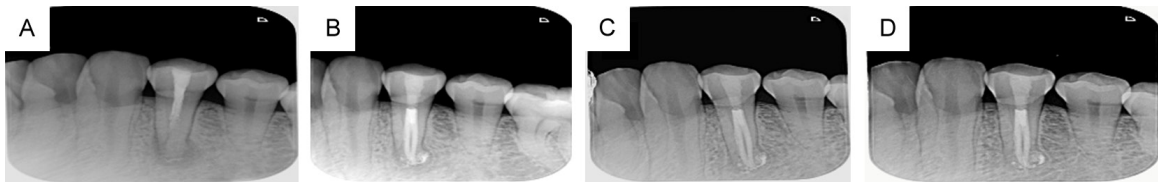
## Four materials in the treatment of chronic periapical periodontitis



**Figure 2.** Cases treated with AH Plus. A: Before surgery; B: 3 months after surgery; C: 6 months after surgery; D: 12 months after surgery.



**Figure 3.** Cases treated with Apexit Plus. A: Before surgery; B: 3 months after surgery; C: 6 months after surgery; D: 12 months after surgery.



**Figure 4.** Cases treated with iRoot SP. A: Before surgery; B: 3 months after surgery; C: 6 months after surgery; D: 12 months after surgery.

then the gutta-percha was cut off at the level of the root canal orifice, pressurized, and post-treated. Among them, the hydraulic single-point method was used for treatment in Group A and Group D. After selecting the main gutta-percha point and inserting it into the root canal, it was pulled back at a distance of 0.5 mm from the root apex. If there was resistance, it indicated that it was appropriate. Then, an appropriate needle was used to inject the sealer. The main point was dipped with a small amount of SP and inserted into the root canal, and it was cut off 1 mm below the root canal orifice and pressurized. In both Group B and Group C, the continuous wave of heated gutta-percha vertical pressurization method was used for treatment. First, appropriate working tips of the heat carrier and vertical pressurizers were selected, the points were tested, the main point and paste were placed, the gutta-percha points outside the root canal orifice were removed, rootward pressure was applied, and continuous wave vertical pressurization was carried out. After the working tip of the heat carrier was withdrawn, 3-4 mm of gutta-percha at the root apex

segment was retained, and the middle and upper segments were filled with heated gutta-percha in layers. Each time, a vertical pressurizer with an appropriate diameter was used for vertical pressurization. After root filling in the four groups, direct resin filling or indirect restoration was carried out according to the situation.

### *Observation indicators*

The therapeutic effective rate was assessed after treatment at 3 months, 6 months, and 12 months, by measuring the pain conditions, Visual Analog Scale (VAS) score and Periapical Index (PAI) score.

(1) Treatment efficacy: Complete recovery was required as disappearance of relevant symptoms and signs of the affected tooth after treatment, no percussion pain and loosening, normal masticatory function, and normal X-ray findings. Effectiveness was defined as the disappearance of relevant symptoms and signs of the affected tooth after treatment, no percussion pain and loosening, basically normal masticatory function, and a reduction in the periapi-

## Four materials in the treatment of chronic periapical periodontitis

**Table 1.** Comparison of the total effective rates of the four groups 3 months after treatment [n (%)]

Group	Cured	Effective	Ineffective	Total Effective Rate
A (n=58)	50 (86.21)	8 (13.79)	0 (0.00)	58 (100.00)
B (n=57)	49 (85.96)	7 (12.28)	1 (1.75)	56 (98.25)
C (n=57)	49 (85.96)	6 (10.53)	2 (3.51)	55 (96.49)
D (n=57)	52 (91.23)	5 (8.77)	0 (0.00)	57 (100.00)
$\chi^2$ value	---	---	---	3.745
P value	---	---	---	0.290

Note: A: C-Root SP; B: AH Plus; C: Apexit Plus; D: iRoot SP.

cal radiolucent area shown by X-ray. Ineffectiveness was defined as no significant improvement in relevant symptoms and signs of the affected tooth, masticatory function, etc. after treatment, and no obvious reduction, no change or further expansion of the periapical radiolucent area shown by X-ray [7]. The overall effective rate = (number of complete recovery cases + number of effective cases)/total number of cases  $\times$  100%. (2) Pain conditions: The VAS scores were used to assess the pain feelings of the four groups pre-treatment and at 1, 3 and 7 days following the treatment. The scoring range of this standard is 0-10 points. First, draw a 10-cm straight line and mark the numbers from 0 to 10. Guide the patients to select a number according to their pain feelings at a specific time point, where 0 means no pain and the higher the values, the more intense of discomfort such as pain [8]. (3) PAI scores: The PAI scores were used to assess the four groups of patients preoperatively and at 3, 6 and 12 months post-treatment. The results were judged by X-ray films and determined by two professionals using the double-blind method. The scoring range is 1-5 points, where 2 points and above indicate chronic periapical periodontitis, and the higher the score indicates the more severe periapical condition [8].

### Statistical methods

Statistical analysis was tested using SPSS 23.0. Categorical variables were expressed as [n (%)] and subjected to  $\chi^2$  test processing with the above software.

Measurement data following to a normal distribution were expressed as ( $\bar{x} \pm sd$ ). Bonferroni correction was performed using multiple comparisons. Repeated measurement of measurement data was analyzed by variance analysis, and the further pairwise comparisons were per-

formed using the SNK-qtest. P-value of less than 0.05 ( $P < 0.05$ ) was considered to indicate statistical significance.

### Results

#### *Comparative analysis of the total effective rates among the four groups at the 3 months post-treatment*

There was no statistically significant difference among the four groups regarding total effective rates at 3 months after treatment ( $P > 0.05$ ), as shown in **Table 1**.

#### *Comparative analysis of the total effective rates among the four groups at the 6 months post-treatment*

There was no statistically significant difference among the four groups regarding total effective rates at 6 months after treatment ( $P > 0.05$ ), as shown in **Table 2**.

#### *Comparative analysis of the total effective rates among the four groups at the 12 months post-treatment*

The total effective rates of Group A, B and D were notably higher than that of Group C 12 months after treatment, and the statistically significant disparity ( $P < 0.012$ ) was shown in **Table 3**.

#### *Comparison of VAS scores of the four groups before and after treatment*

There was no statistically significant difference in the VAS scores as well as PAI scores in the four groups before treatment ( $P > 0.05$ ). The VAS scores of the four groups at 1, 3 and 7 days after treatment were significantly reduced from those before treatment ( $P < 0.05$ ). While there was no statistically significant difference in the

## Four materials in the treatment of chronic periapical periodontitis

**Table 2.** Comparison of the total effective rates of the four groups 6 months after treatment [n (%)]

Group	Cured	Effective	Ineffective	Total Effective Rate
A (n=58)	45 (77.59)	12 (20.69)	1 (1.72)	57 (98.28)
B (n=57)	41 (71.93)	11 (19.30)	5 (8.77)	52 (91.23)
C (n=57)	40 (70.18)	11 (19.30)	6 (10.53)	51 (89.47)
D (n=57)	46 (80.70)	10 (17.54)	1 (1.75)	56 (98.25)
$\chi^2$ value	---	---	---	6.853
P value	---	---	---	0.076

Note: A: C-Root SP; B: AH Plus; C: Apexit Plus; D: iRoot SP.

**Table 3.** Comparison of the total effective rates of the four groups 12 months after treatment [n (%)]

Group	Cured	Effective	Ineffective	Total Effective Rate
A (n=58)	43 (74.14)	13 (22.41)	2 (3.45)	56 (96.55)*
B (n=57)	38 (66.67)	13 (22.81)	6 (10.53)	51 (89.47)*
C (n=57)	26 (45.61)	15 (26.32)	16 (28.07)	41 (71.93)
D (n=57)	41 (71.93)	10 (17.54)	6 (10.53)	51 (89.47)*
$\chi^2$ value	---	---	---	16.630
P value	---	---	---	< 0.012

Note: Compared with group C, \*P < 0.012. A: C-Root SP; B: AH Plus; C: Apexit Plus; D: iRoot SP.

**Table 4.** Comparison of VAS scores of the four groups before and after treatment [n (%)]

Group	Before treatment	1 d after treatment	3 d after treatment	7 d after treatment
A (n=58)	5.61±0.92	3.79±0.69*	2.35±0.59*	0.93±0.21*
B (n=57)	5.59±0.89	3.66±0.72*	2.33±0.61*	0.95±0.19*
C (n=57)	5.66±0.95	3.59±0.71*	2.29±0.56*	1.01±0.20*
D (n=57)	5.53±0.86	3.67±0.75*	2.27±0.62*	0.96±0.22*
F value	1.679	0.771	0.216	1.574
P value	0.172	0.511	0.885	0.196

Note: Compared with the group before treatment, \*P < 0.05. A: C-Root SP; B: AH Plus; C: Apexit Plus; D: iRoot SP.

VAS scores among the four groups after treatment (P > 0.5), as shown in **Table 4** and **Figure 5**.

### Comparison of PAI scores of the four groups before and after treatment

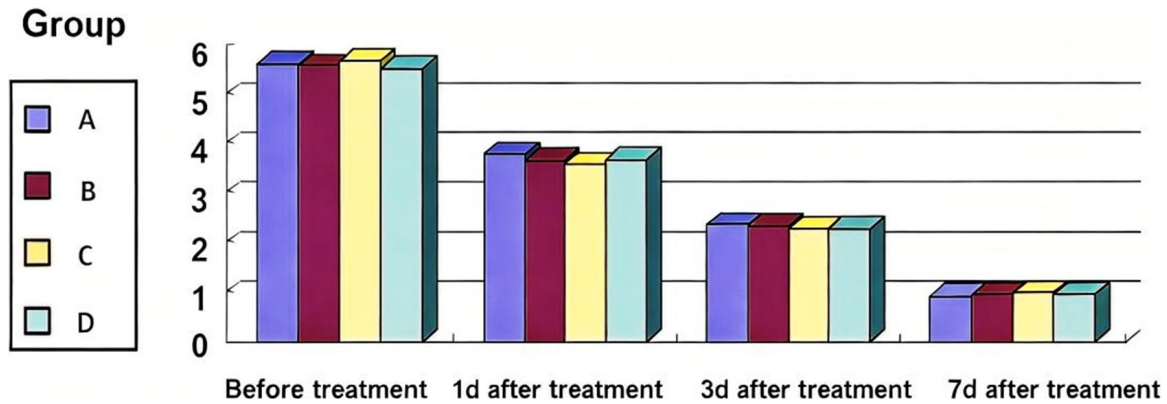
There was no statistically significant difference in PAI scores among the four groups before treatment, 3 months after treatment and 6 months post-treatment (P > 0.05). The PAI scores of Group A, Group B and Group D were significantly lower than that in Group C 12 months after treatment, and the difference was statistically significant (P < 0.05), as shown in **Table 5** and **Figure 6**.

### Discussion

Chronic periapical periodontitis can cause pain, limited masticatory function and other condi-

tions in patients, and may even develop into periapical cysts, causing great harm to the oral health status and related quality of life of patients [9, 10]. Therefore, the need and significance for the precise diagnosis and therapeutic strategies of chronic periapical periodontitis are both high. Among the treatment measures related to chronic periapical periodontitis, root canal treatment has obvious application advantages. It achieves the purpose of treating diseases by sealing the dead space and preventing bacterial infections [11-14], and its clinical application effect has been widely recognized. Meanwhile, there are many studies related to root canal filling treatment for such patients in clinical practice, covering a wide range of research aspects [15-17], among which the research on filling materials is the focus. In the past, AH Plus, Apexit Plus and iRoot SP were mostly used for treatment in clinical practice,

## Four materials in the treatment of chronic periapical periodontitis

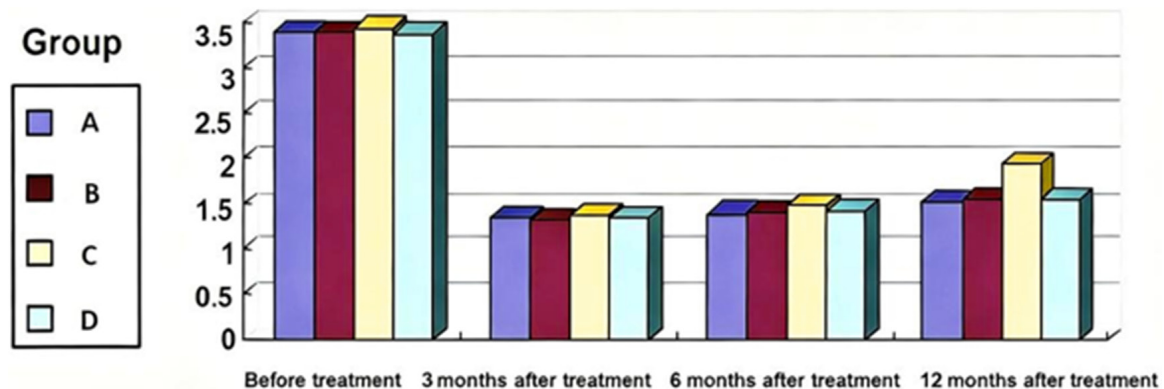


**Figure 5.** VAS scores of the four groups before and after treatment. VAS: Visual Analog Scale; A: C-Root SP; B: AH Plus; C: Apexit Plus; D: iRoot SP.

**Table 5.** Comparison of PAI scores of the four groups before and after treatment

Group	Before treatment	3 months after treatment	6 months after treatment	12 months after treatment
A (n=58)	3.39±0.79	1.35±0.35 <sup>#</sup>	1.40±0.36 <sup>#</sup>	1.52±0.38 <sup>*.#</sup>
B (n=57)	3.40±0.76	1.33±0.32 <sup>#</sup>	1.41±0.35 <sup>#</sup>	1.55±0.40 <sup>*.#</sup>
C (n=57)	3.43±0.77	1.39±0.29 <sup>#</sup>	1.49±0.40 <sup>#</sup>	1.95±0.43
D (n=57)	3.38±0.80	1.36±0.33 <sup>#</sup>	1.43±0.37 <sup>#</sup>	1.56±0.41 <sup>*.#</sup>
F value	0.043	0.341	0.678	14.479
P value	0.988	0.796	0.567	< 0.001

Note: Compared with group C, \*P < 0.05; compared with the group before treatment, <sup>#</sup>P < 0.05. A: C-Root SP; B: AH Plus; C: Apexit Plus; D: iRoot SP.



**Figure 6.** PAI scores of the four groups before and after treatment. PAI: Periapical Index; A: C-Root SP; B: AH Plus; C: Apexit Plus; D: iRoot SP.

achieving good results, but there were also certain differences in related comparative studies [18-22]. AH Plus, an epoxy resin-based root canal filling material, has the characteristics of good apical sealing performance, slow curing, good fluidity, low solubility, etc., and has strong adhesiveness. However, it cannot fully bond with gutta-percha, and its biocompatibility is

also poor. If it extends beyond the apical foramen, it can cause local inflammatory reactions [10], but it has the advantage of small volume shrinkage [23]. Apexit Plus has the advantages of broad-spectrum antibacterial and hard tissue induction. After curing, its volume can slightly expand, and the filling is more compact. However, it will be absorbed, so its long-term

## Four materials in the treatment of chronic periapical periodontitis

effect and stability are relatively poor. iRoot SP is a calcium silicate-based bioceramic material, with good fluidity, high biocompatibility, short curing time, and relatively simple clinical operation. It can absorb a certain amount of water during the solidification process, and may not be cured for a long time in a dry environment [11]. C-Root SP is a strontium silicate-based bioceramic material, which has many advantages, such as no toxic or side effects, good compatibility and corrosion resistance, etc., and also has the advantages of good fluidity, good sealing, filling more lateral root canals, good radiopacity, small postoperative reaction and fast periapical healing. The discomfort of patients is also greatly reduced. The strontium silicate in it is also relatively effective in inhibiting inflammatory factors and relieving pain. However, the research on its long-term effect and stability is extremely scarce. Moreover, iRoot SP cures faster and is more advantageous in emergency filling, but it is inferior to C-Root SP in terms of root apical bone tissue healing. C-Root SP can effectively improve the root filling efficiency by using the hydraulic single-point method, and it is more convenient to remove the excess paste. iRoot SP also uses the hydraulic single-point method. One reason is that its bonding strength decreases under high temperature [23].

Yu and Yi [6] believed that there is no significant difference in the short-term therapeutic outcomes of AH Plus and Apexit Plus in the therapeutic strategies of chronic periapical periodontitis after 3 months, and Apexit Plus had a more significant advantage in controlling pain and other discomforts, while the research on the long-term efficacy was not involved. The study by Jieqi et al. [3] showed that the treatment effect of iRoot SP single-point filling method in patients with chronic periapical periodontitis was significantly better than that of AH Plus at 3 months after treatment, while there was no significant difference in the effect at 1 year post-treatment, but the comparative study with Apexit Plus and others was not involved. As a relatively new domestic material, C-Root SP has a relatively short application time and relatively insufficient relevant research reports. However, the study by Liu [14] gave a certain affirmation to its clinical application effect. In view of the differences and deficiencies of the above studies, it is of great significance to further research the short-term and long-term effi-

cacy of the above four root canal filling materials in the treatment of patients with chronic periapical periodontitis.

The analysis revealed that there were no statistically significant differences in the total effective rates among the four groups at 3 and 6 months post-treatment. However, the total effective rate of patients treated with Apexit Plus was relatively lower than that of the other three groups at 12 months after treatment. Meanwhile, the VAS scores of the four groups at 1, 3 and 7 days post-treatment all showed a decreasing trend with no obvious difference. But the PAI score of patients treated with Apexit Plus was relatively worse at 12 months after treatment. This data indicates no statistically significant difference in short-term efficacy among the four root canal filling materials, and all of them can well control the discomfort. However, the long-term efficacy of Apexit Plus is relatively poor and there are certain deficiencies in its stability. At the same time, the results also suggest that the new material C-Root SP is worthy of affirmation in terms of application effect and stability compared with the previous classic materials, providing a certain reference for the selection of oral treatment materials by clinicians. Moreover, C-Root SP not only has the advantages of no need for mixing and no shrinkage after solidification, but also has better biocompatibility as a prominent advantage. It has fewer postoperative adverse reactions, better and faster healing effects, all of which lay an effective foundation for its clinical application. Meanwhile, its effect on apical sealing performance is similar to that of iRoot SP. Its strong antibacterial property helps to reduce adverse stress such as inflammatory reactions after treatment, which is also an important basis for controlling discomfort. Furthermore, its ultra-fine characteristics are more conducive to the filling of lateral branches, achieving seamless three-dimensional filling in one step with higher efficiency, all of which are the absolute advantages of it as a filling material. Therefore, its clinical application advantages are further affirmed.

### Conclusion

We believe that there is no statistically significant difference in short-term application effects of C-Root SP, AH Plus, Apexit Plus and iRoot SP in chronic periapical periodontitis, but

## Four materials in the treatment of chronic periapical periodontitis

the long-term effect and stability of Apexit Plus are relatively poor. However, due to the limited number of participants in this research, future study with larger sample sizes and more comprehensive and detailed investigations are still needed.

### Disclosure of conflict of interest

None.

**Address correspondence to:** Bo Zhong, Department of Stomatology, Shenzhen Second People's Hospital, No. 3002, Sungang West Road, Futian District, Shenzhen 518000, Guangdong, China. Tel: +86-0755-83366388-8628; E-mail: zhongbo1b@163.com

### References

- [1] Xiaolei F, Fang W and Mengjie L. Effects of three root canal filling methods in the treatment of chronic pulpitis and apical periodontitis and their effects on GI, SBI, PD and IL-1 $\beta$  levels. *J Clin Med Res Pract* 2024; 9: 69-72, 93.
- [2] Tingting Z, Guangchao Z and Cheng C. Quantitative evaluation of artifact expression in cone-beam computed tomography of mesoporous calcium silicate nanoparticles as a promising root canal sealer. *Oral Surg Oral Med Oral Pathol Oral Radiol* 2023; 136: 500-507.
- [3] Jieqi W, Yujia W and Jianglong Z. Efficacy of iRoot SP single-point filling method in treating chronic apical periodontitis in diabetic patients. *JPM* 2022; 38: 2676-2680.
- [4] Lin GSS, Luddin N and Ghani HA. Dislodgment resistance, adhesive pattern, and dentinal tubule penetration of a novel experimental algin biopolymer-incorporated bioceramic-based root canal sealer. *Polymers (Basel)* 2023; 15: 1317-1319.
- [5] Zhixiang L. Comparison of the effects of zinc oxide clove oil paste and Vitapex paste in root canal filling treatment of children with periapical periodontitis of deciduous teeth. *CJPM* 2024; 51: 47-50.
- [6] Yu X, Yi N. Comparison of the clinical application effects of iRoot SP and AH plus root canal sealers. *HH Med* 2023; 41: 379-382.
- [7] Xiaomin W, Fang G and Ying T. Effects of different root canal filling materials in root canal filling of patients with chronic apical periodontitis. *Int Med Health Herald* 2024; 30: 3910-3914.
- [8] Kapralos V, Böcker J and Vach K. On the biocompatibility of endodontic sealers. *Swiss Dent J* 2022; 132: 586-597.
- [9] Zhengzheng S, Xiangzhu W and Xiaoli X. Re-treatment of overfilled right mandibular molar with chronic periapical periodontitis: a case report. *Chinese J Contin Educ Stomatol* 2024; 27: 399-405.
- [10] Martins JFB, Scheeren B and Waal SV. The effect of unintentional AH-Plus sealer extrusion on resolution of apical periodontitis after root canal treatment and retreatment-a retrospective case-control study. *J Endod* 2023; 49: 1262-1268.
- [11] Di H, Yanping H and Sujuan W. A clinical study on the comparison between iRoot SP single-point filling technique and AH plus heated gutta-percha vertical compression filling technique. *JPCS* 2023; 39: 15-19.
- [12] Dong L, Shengnan Y and Juanjuan X. Effect of C-Root SP strontium silicate in root canal treatment of patients with chronic apical periodontitis and its role in repairing apical bone defects. *HLJ Med Sci* 2025; 48: 139-140, 143.
- [13] Ling L and Na J. Clinical effect analysis of different root canal filling methods in root canal treatment of chronic apical periodontitis. *G Z Med* 2024; 48: 1778-1780.
- [14] Li L. Effect analysis of vitapex paste root canal filling in the treatment of chronic periapical periodontitis of deciduous teeth in children. *Chin J Trauma Disabil Med* 2024; 32: 42-45.
- [15] Gang L, Minxia B and Na L. A comparative study on the overfilling rate and postoperative pain of C-Root SP and iRoot SP bioceramic sealers in root canal filling. *Oral Biomedicine* 2023; 14: 29-33.
- [16] Issa J, Jaber M and Rifai I. Mozdziakpdiagnostic test accuracy of artificial intelligence in detecting periapical periodontitis on two-dimensional radiographs: a retrospective study and literature review. *Medicina (Kaunas)* 2023; 59: 768-770.
- [17] Bakhsh A, Moyes D and Proctor G. The impact of apical periodontitis, non-surgical root canal retreatment and periapical surgery on serum inflammatory biomarkers. *Int Endod J* 2022; 55: 923-937.
- [18] Liang C, Zhenfang Z and Liangjing C. Observation on the clinical efficacy of iRoot SP combined with single-point filling technique in the treatment of chronic periapical periodontitis of molars. *BJOS* 2022; 30: 346-349.
- [19] Jiamin Y, Dongyu H and Huihua Q. Effect of iROOT SP single-pointed filling method in root canal treatment of pulpitis and apical periodontitis. *Jilin Medicine* 2025; 46: 107-109.
- [20] Peijuan Z, Nana W and Qing Z. Observation on the efficacy of two root canal dredging methods on sinus-type apical periodontitis in deciduous molars. *China Med Herald* 2024; 21: 85-87.

## Four materials in the treatment of chronic periapical periodontitis

- [21] Xiujian L, Xuesong H and Xing C. Analysis of overfilling in three root canal filling methods for the treatment of sinus-type periapical periodontitis. *CMD* 2023; 61: 39-42.
- [22] Kurup D, Nagpal AK and Shetty S. Data on the push-out bond strength of three different root canal treatment sealers. *Bioinformation* 2021; 17: 67-72.
- [23] Luchang L, Jianqiong L and Pan H. Clinical effect of iROOT SP single-apical filling method in root canal treatment of chronic apical periodontitis in adults and its influence on inflammatory response. *J Transl Med* 2025; 14: 7-10.