

Original Article

Transradial cerebral angiography with SM2 catheter: a safe and effective alternative to the transfemoral approach

Tao Qiu¹, Qiang Shi¹, Xiaoyong Deng¹, Ming Chen¹, Shengqi Fu¹, Xiaoyan Dai²

¹Department of Neurology, Zigong First People's Hospital, Zigong 643000, Sichuan, China; ²Department of Outpatient, Zigong First People's Hospital, Zigong 643000, Sichuan, China

Received December 6, 2025; Accepted March 18, 2026; Epub March 25, 2026; Published March 30, 2026

Abstract: Objective: To compare the efficacy and safety of cerebral angiography performed using an SM2 catheter combined with a long guidewire exchange technique via transradial approach (TRA) versus the conventional transfemoral approach (TFA). Methods: Data from 853 patients who underwent diagnostic cerebral angiography between October 2019 and September 2020 were retrospectively reviewed. Patients were divided into a TRA group (n=425) and a TFA group (n=428) according to the vascular access route used. All procedures were performed by experienced neurointerventionalists following a standardized protocol on a uniform imaging system. Primary outcomes were the procedural success rate and the incidence of major complications within 24 hours after the procedure. Secondary outcomes included angiographic completeness, procedure time, fluoroscopy time, radiation dose, and the incidence of all complications during hospitalization. Multivariate logistic regression analysis was performed to adjust for potential confounding factors. Results: The procedural success rate was high in both groups (TRA: 96.71% vs. TFA: 98.83%, $P=0.035$). Angiographic completeness was significantly higher in the TRA group than in the TFA group (99.27% vs. 87.00%, $P < 0.001$). Procedure time was shorter in the TRA group (32.4 ± 14.51 min vs. 42.54 ± 22.51 min, $P < 0.001$). There were no significant differences in fluoroscopy time or radiation dose. The overall complication rate was significantly lower in the TRA group (8.71% vs. 18.46%, $P < 0.001$), with no pseudoaneurysms observed in the TRA group versus 4.91% in the TFA group. Conclusions: The SM2 catheter with long guidewire exchange technique via the right radial artery is a safe and effective alternative to the conventional femoral approach for cerebral angiography. It offers shorter procedure times, higher angiographic completeness, and a significantly lower complication profile.

Keywords: Transradial approach, long wire exchange technique, SM2 catheter, whole brain angiography

Introduction

Cerebral angiography remains the gold standard for the diagnosis and evaluation of cerebrovascular diseases. For decades, the transfemoral approach (TFA) has been the conventional access route; however, it is associated with several well-documented drawbacks, including patient discomfort, prolonged immobilization, and access-site complications such as hematoma, pseudoaneurysm, and lower-limb deep vein thrombosis [1-3].

The transradial approach (TRA), renowned for its superior safety profile and improved patient comfort in cardiology [4], has garnered increasing interest in neurointervention. Pioneering

work by Campeau [5] and early neurosurgical applications, such as the study by Matsumoto et al. involving 166 cases [6], demonstrated the initial feasibility of this technique. Subsequent reports from other centers further support its potential advantages [7, 8]. However, its adoption in cerebral angiography has been limited. Existing studies are predominantly retrospective analyses or small case series [9, 10], reflecting a lack of large-scale prospective comparisons and, crucially, a standardized technical protocol. This variability in technique and equipment contributes to a steep learning curve and inconsistent outcomes, which may partly explain why TRA has not become a mainstream approach.

A central technical challenge of TRA is the retrograde catheter navigation from the radial artery into the cephalic vessels. The Simon2 (SM2) catheter has emerged as a promising tool due to its preformed configuration that is capable of forming a stable loop in the aortic arch for vessel selection [8]. However, a key technical obstacle remains - achieving safe and reliable formation of the SM2 catheter loop. While loop formation within the descending aorta is considered safest, directly advancing the SM2 catheter to this location can be technically challenging and potentially risky.

To address this issue, we developed a safety-enhanced and standardized sequence. First, aortic arch angiography is initially performed using a pigtail catheter. Then, the configuration of the pigtail catheter is utilized to facilitate safe advancement of a long 0.035-inch guidewire into the descending aorta. Subsequently, an exchange technique is employed to deliver the SM2 catheter loop over this wire to the descending aorta; and finally, the SM2 catheter loop is formed, followed with selective angiography. This method ensures reliable and safe loop formation in a stable vascular segment, potentially reducing the risk of aortic arch injury and improving procedural predictability.

Since 2019, our neurointerventional team has constantly refined this protocol. Preliminary experience suggested that the technique maintains high success rates while potentially reducing complications and procedure time. However, robust evidence from a controlled trial design remains limited.

Therefore, we conducted this retrospective cohort study. The primary aim was to compare the safety and efficacy of this standardized right TRA protocol versus conventional TFA. Furthermore, a key objective of this study is to validate and detail this specific technical protocol-utilizing a pigtail catheter and a long guidewire exchange technique to facilitate safe SM2 loop formation in the descending aorta as a potential standard operating procedure for TRA cerebral angiography. By providing high-level evidence and a reproducible technique framework, this study aims to reduce the technical barriers associated with TRA and promote its broader adoption as a mainstream, patient-centered alternative.

Methods

Study design and ethics

This retrospective, single-center cohort study was conducted at Zigong First People's Hospital. The study protocol was reviewed and approved by the Ethics Committee of Zigong First People's Hospital (Approval No.: Zigong First People's Hospital Ethics [Research] [2019]74). Due to the retrospective nature of the study and the use of anonymized data, the requirement for written informed consent was waived by the ethics committee.

Data sources and extraction

Clinical data were collected from the electronic medical record system, the radiology information system, and the catheterization laboratory database of Zigong First People's Hospital. Consecutive patients who underwent diagnostic cerebral angiography between October 2019 and September 2020 were identified and screened for eligibility.

Data extraction was independently performed by two investigators (T.Q. and Q.S.) using a standardized data collection form. The following variables were collected: demographic characteristics (age, sex), clinical history (including hypertension, diabetes, and prior stroke), procedural details (access route, catheter type, contrast volume, fluoroscopy time, radiation dose, and procedure duration), and outcomes (procedural success, angiographic completeness, and complications). Complications were further verified by reviewing postoperative clinical notes and, when necessary, ultrasound or imaging reports.

To ensure data accuracy, all extracted data were crosschecked by a third investigator (X.D.). Discrepancies were resolved through consensus discussion or by referring to the original records. The final anonymized dataset was then locked prior to statistical analysis.

Inclusion and exclusion criteria

Inclusion criteria: ① Age \geq 18 years old; ② Suspected cerebrovascular lesions or evaluation of the etiology of cerebrovascular diseases; ③ Etiological examination of intracerebral or subarachnoid hemorrhage; ④ Preoperative

Transradial cerebral angiography with SM2 catheter

assessment of highly vascularized tumors in the head and face; ⑤ Evaluation of the vascular supply and its relationship with adjacent blood vessels in intracranial space-occupying lesions, as well as characterization of some tumors; ⑥ Assessment of the anatomical relationship between vascular lesions and surrounding structures before vascular intervention or surgical treatment; ⑦ Acute cerebrovascular disease requiring arterial thrombolysis or other intravascular treatment; ⑧ Follow-up evaluation of cranial, facial, or intracranial vascular diseases after treatment.

Exclusion criteria: ① Known allergy or intolerance to iodine contrast agents; ② Known allergy to interventional equipment or associated materials; ③ Severe cardiac, hepatic, or renal insufficiency (e.g., inability to tolerate the supine position, alanine aminotransferase [ALT] or aspartate aminotransferase [AST] > 300 U/L, or creatinine > 250 $\mu\text{mol/L}$) ④ Local infection at the puncture site; ⑤ Complicated with cerebral herniation or other life-threatening conditions; ⑥ Severe bleeding tendency or hemorrhagic diseases, including platelets < $50 \times 10^9/\text{L}$; ⑦ Random blood glucose > 18 mmol/L or blood pressure > 180/110 mmHg; ⑧ Absence of palpable right femoral or radial artery pulse, suggesting possible arterial occlusion or other significant vascular lesions.

Operators and equipment

All procedures were performed by one of seven experienced neurointerventionalists. Each operator had previously performed at least 1,000 TFA and 100 TRA procedures prior to the study, ensuring proficiency in both approaches. All angiographic procedures were performed using a uniform imaging system (GE IGS 530, GE Healthcare, Milwaukee, WI, USA).

Procedural protocols

All patients received standardized perioperative care and post-procedure monitoring during hospitalization. Prior to the procedure, all patients underwent routine preoperative examinations, including routine blood, coagulation profile, serum electrolytes, liver and renal function tests, blood glucose, pretransfusion examination, electrocardiography, chest CT or chest X-ray, and brain CT/MRI to ensure the

absence of contraindications to angiography. Preoperative preparation included procedural explanation and acquisition of written informed consent, discontinuation of metformin 48 h before operation, establishment of venous access, and routine urinary catheterization for patients undergoing femoral artery puncture. In addition, vascular examinations of femoral artery and dorsalis pedis artery, and bilateral Allen test were performed to assess collateral circulation of the hand prior to radial artery cannulation.

Detailed operative protocols

Control group (TFA Group): Patients were placed in a supine position on the operating table. Following routine disinfection of the perineum and bilateral groin regions and sterile draping, local infiltration anesthesia was administered at the right groin using 3 ml of 2% lidocaine. The right common femoral artery was punctured using the Seldinger technique, and a 5F arterial sheath (Cordis Corporation, USA) was inserted. Under the guidance of a 0.035-inch guidewire, a 5F pigtail catheter was advanced into the aortic arch to perform aortic arch angiography. Subsequently, a 5F single-curve angiography catheter (Cordis) was selectively inserted into the left and right common carotid arteries, as well as the vertebral artery origins of the left and right subclavian arteries, under fluoroscopic guidance. Multi-angle digital subtraction angiography was performed for each vessel, with three-dimensional rotational angiography conducted when necessary. When complex vascular anatomy (e.g., a Type III aortic arch) was encountered, alternative catheters (e.g., a Hunter head catheter or an SM2 catheter) were used. Upon completion of the procedure, the puncture site was disinfected. Manual compression was applied for 10 minutes. Hemostasis was subsequently maintained using a femoral artery compression device (Anasca+e, Daxin Medical Technology, China), which was kept in place for 7 hours and released every 2 hours. Patients were instructed to remain in the supine position for 24 hours after the procedure, with close monitoring for bleeding at the puncture site and pulsation of the right dorsalis pedis artery. Color Doppler ultrasound of the femoral artery was performed on the following day to

Transradial cerebral angiography with SM2 catheter

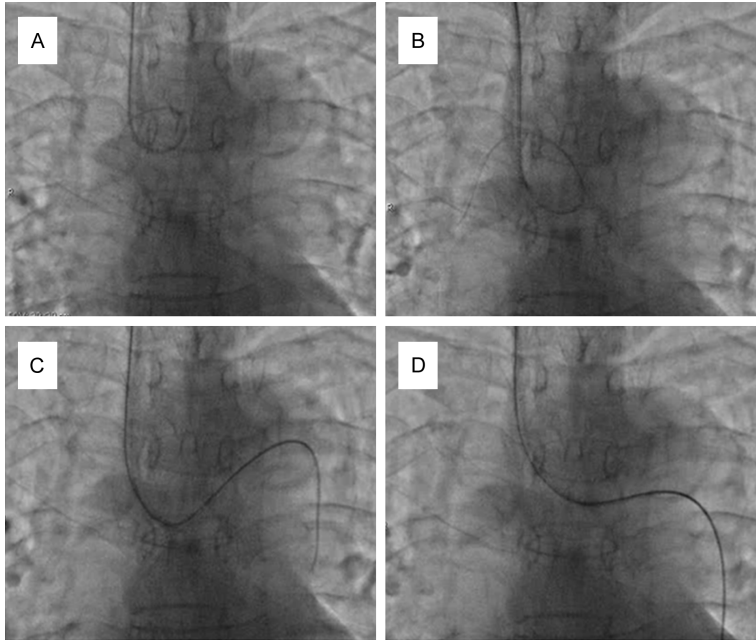


Figure 1. Technique for advancing a long guidewire (2.6 m, 0.035-inch) into the descending aorta using a pigtail catheter. A. The pigtail catheter tip is directed toward the right side of the ascending aorta. B. 2.6-m, 0.035-inch guidewire is advanced along the right wall of the ascending aorta. C. The guidewire deflects off the aortic wall and enters the descending aorta. D. The guidewire is further advanced into the abdominal aorta to establish a stable access route.

rule out pseudoaneurysm. All postoperative discomfort was documented by the physician.

Study group (TRA Group): Following placement in the supine position, the patient's right forearm and hand were routinely disinfected and draped. Local infiltration anesthesia was administered at the right radial artery puncture site using 0.5 ml of 2% lidocaine. The artery was punctured using the Seldinger technique, and a 5F radial artery sheath (Terumo Corporation, Japan) was inserted. Intravenous heparin (2000 U) was administered for anticoagulation, and nitroglycerin (200 µg) was injected intra-arterially to prevent vasospasm.

A 5F pigtail catheter paired with a 2.6-meter, 0.035-inch guidewire was advanced into the aortic arch for initial angiography. The guidewire was then advanced further into the descending aorta, with its tip positioned distal to the renal arteries (**Figure 1**). Over this wire, the pigtail catheter was exchanged for a 5F Simon2 (SM2) catheter (Yixinda, China), which was coaxially advanced to the level of the descending thoracic aorta. After partial with-

drawal of the guidewire, the SM2 catheter was rotated clockwise and gently pulled back simultaneously to form a stable loop within the aortic arch, with its tip oriented cephalad. This looped configuration was used to selectively catheterize, in sequence, the left subclavian artery (at the vertebral origin), left common carotid artery, right common carotid artery, and the right subclavian artery (at the vertebral origin), as illustrated in **Figure 2**. Multi-angle and three-dimensional angiography were performed as required. For right vertebral artery angiography, two alternative approaches were employed, shown in **Figure 3**.

Upon completion of the angiographic procedure, the loop configuration was carefully unraveled by re-advancing the guidewire before catheter withdrawal.

Hemostasis at the puncture site was achieved using a radial compression bandage and an elastic bandage for 6 hours, loosened every 1-2 hours to assess circulation. Patients were allowed to ambulate immediately after the procedure. The perfusion of the right hand and the puncture site were monitored for bleeding, and all postoperative discomfort was documented by the physician.

Outcome measures

Primary endpoints

Procedural safety: Composite incidence of access-site and procedure-related complications, including but not limited to hematoma, pseudoaneurysm, arterial dissection, distal embolism, symptomatic vasospasm, arterial hemorrhage, lower limb deep vein thrombosis, and contrast-related adverse events were evaluated.

Procedural success rate: Procedural success was defined as the successful completion of the intended diagnostic cerebral angiographic

Transradial cerebral angiography with SM2 catheter

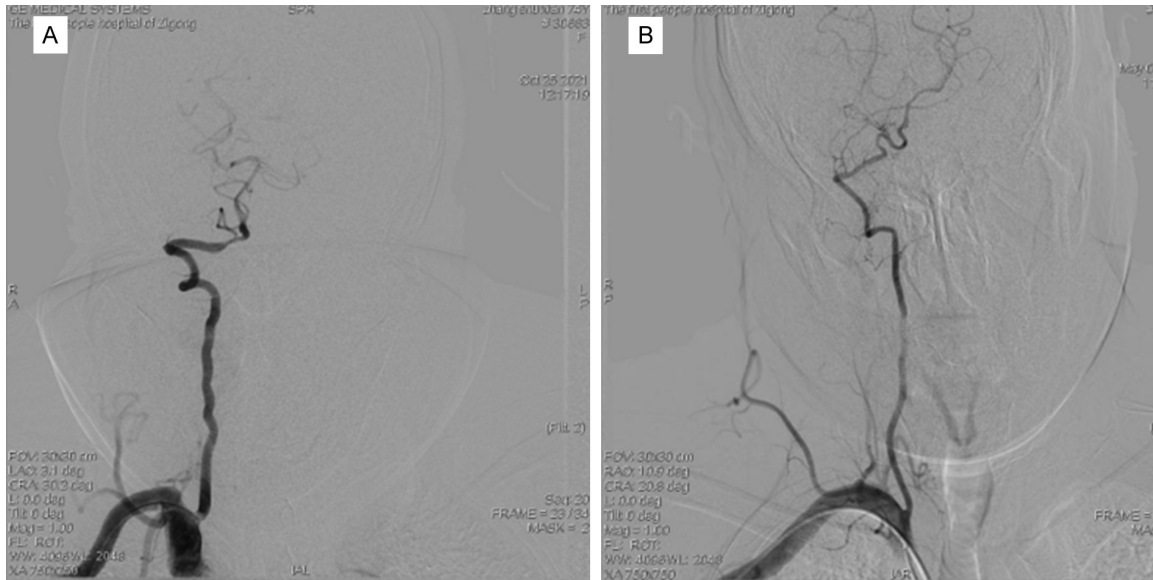


Figure 3. Two techniques for right vertebral artery angiography using the SM2 catheter. A. The SM2 catheter is opened and gently withdrawn so that the catheter tip engages the ostium of the right vertebral artery for angiography. B. While maintaining the loop configuration, the SM2 catheter is advanced into the right subclavian artery and then directed into the right vertebral artery for angiography.

examination using the initially assigned single vascular access site without the need for crossover to an alternative access route.

Angiographic completeness rate: Angiographic completeness was defined as successful, selective catheterization and angiographic visualization of all four target vessels: the bilateral common carotid arteries and the bilateral vertebral arteries (or the subclavian arteries proximal to the vertebral artery origins).

Secondary endpoints

Procedure time: Procedure time was defined as the interval from the patient's entry into the angiography suite (start time) to the achievement of successful hemostasis at the puncture site (end time).

Radiation exposure: Radiation exposure was assessed using fluoroscopy time (minutes) and cumulative radiation dose (mGy), as automatically recorded by the digital subtraction angiography (DSA) system.

Crossover rate: Crossover rate was defined as the proportion of cases requiring conversion from the assigned access approach (TRA or TFA) to the alternative approach to complete the procedure.

Aortic arch morphology: Aortic arch morphology was classified according to aortic arch type (I, II, III, bovine, etc.), and its correlation with procedural difficulty and procedural success was analyzed.

Statistical analysis

Statistical analyses were performed using SPSS software (version 25.0; IBM Corp., Armonk, NY, USA). Continuous variables were presented as mean \pm standard deviation and compared using the independent samples t-test or Mann-Whitney *U* test, as appropriate, after assessment of data normality. Categorical variables were expressed as frequencies and percentages and compared using the Chi-square test or Fisher's exact test, as appropriate.

Given the non-randomized and retrospective nature of the study, multivariate logistic regression analysis was performed to evaluate the independent association between the vascular access approach (TRA vs. TFA) and the primary safety outcome (occurrence of any complication). This adjustment was conducted to control for potential confounding factors that might have influenced the choice of access route and clinical outcomes. Variables

Transradial cerebral angiography with SM2 catheter

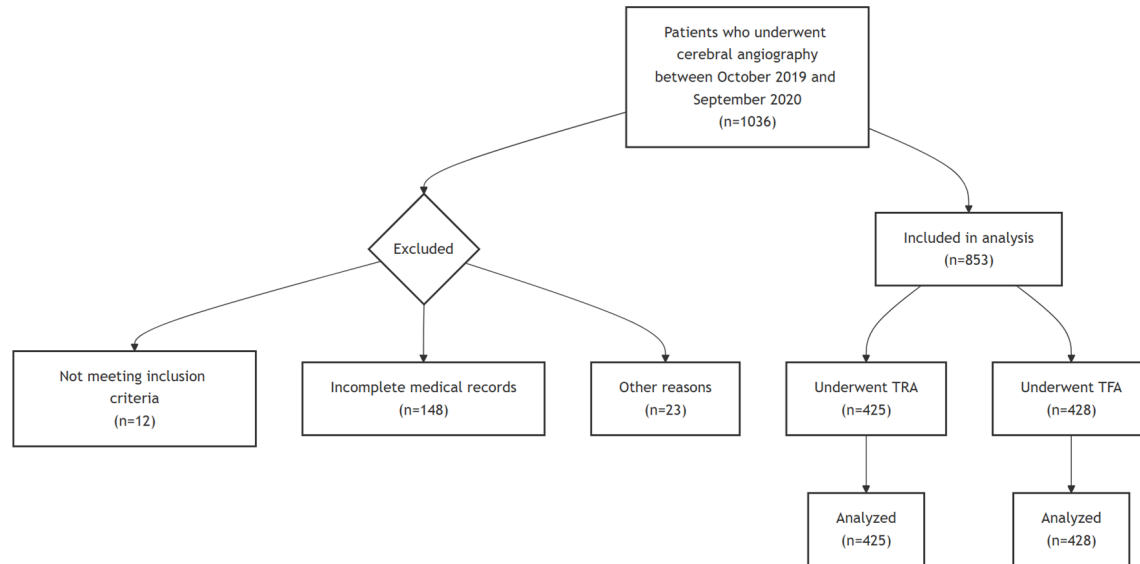


Figure 4. Flow diagram.

were selected for inclusion in the multivariate model based on clinical relevance and/or a significance level of $P < 0.10$ in univariable analyses. Adjusted odds ratios (ORs) with 95% confidence intervals (CIs) were calculated, and a two-sided P value < 0.05 was considered statistically significant. The Hosmer-Lemeshow goodness-of-fit test was used to assess the calibration of the logistic regression model.

All analyses were conducted on a complete-case basis, as the proportion of missing data for key variables was minimal ($< 2\%$).

Results

A total of 1,036 patients who underwent cerebral angiography between October 2019 and September 2020 were initially identified. After applying the inclusion and exclusion criteria, 183 patients were excluded, including 148 with incomplete medical records, 12 who did not meet the inclusion criteria, and 23 for other reasons. As shown in **Figure 4**, a total of 853 patients were included in the final analysis, comprising 425 who underwent TRA and 428 who underwent TFA. All patients successfully completed angiography procedures and were included in the final evaluation.

Baseline characteristics

The baseline characteristics of both groups are summarized in **Table 1**. There were no signifi-

cant differences between the groups in sex, hypertension, diabetes, history of myocardial infarction, smoking status, or prior cerebral infarction/transient ischemic attack (TIA) (all $P > 0.05$). However, patients in the TRA group were significantly older (62.09 ± 10.20 vs. 59.88 ± 10.19 years, $P = 0.002$) and had a higher prevalence of other cardiovascular diseases (18.8% vs. 12.4%, $P = 0.010$). A significant intergroup difference was also noted in the distribution of aortic arch types ($P < 0.001$), with a higher proportion of Type I aortic arches in the TRA group.

Procedural success and crossover

The procedural success rate from the initial access site was 98.83% (423/428) in the TFA group and 96.71% (411/425) in the TRA group ($P = 0.035$) (**Table 2**). In the TFA group, five patients required crossover to an alternative access route, with one case attributed to vasovagal reaction and four cases due to failure to advance the guidewire. In contrast, fourteen patients in the TRA group required crossover, primarily because of anatomical or technical challenges, including radial or brachial artery tortuosity ($n=4$), unsuccessful puncture ($n=3$), and small radial artery caliber ($n=2$). Specific situations encountered in our study that precluded the completion of angiography via TRA are illustrated in **Figure 5**, including small radial artery diameter, guidewire advance-

Transradial cerebral angiography with SM2 catheter

Table 1. Comparison of baseline data between the two groups

	TFA group	TRA group	χ^2	P value
Sex			0.624	0.430
Male	215	202		
Female	213	223		
Age	59.88 ± 10.19	62.09 ± 10.20	-3.183	0.002
Hypertension			0.093	0.761
Yes	203	206		
No	225	219		
Diabetes mellitus			0.674	0.412
Yes	81	90		
No	347	335		
Previous history of myocardial infarction			0.994	0.319
Yes	1	0		
No	427	425		
Other cardiovascular diseases (except atrial fibrillation and myocardial infarction)			6.721	0.010
Yes	53	80		
No	375	345		
Smoking			0.342	0.558
Yes	144	135		
No	284	290		
Previous cerebral infarction or TIA			0.181	0.670
Yes	44	40		
No	384	385		
Arch			27.588	0.000
I	59	105		
II	316	283		
III	51	31		
Horn bow	2	3		
Mirror arch	0	1		
Vagal arch	0	2		

TFA, transfemoral approach; TRA, transradial approach.

Table 2. Comparison of surgical success rate between the two groups

Group	Success	Failure	Total
TFA group	423	5	428
TRA group	411	14	425
χ^2	4.425		853
P value	0.035		

TFA, transfemoral approach; TRA, transradial approach.

ment limited to the accessory brachial artery, aberrant aortic arch anatomy, excessive tortuosity of the right subclavian artery, radial artery looping and tortuosity, and radial artery branch perforation with bleeding.

Angiographic completeness

The rate of complete selective angiography (successful catheterization and angiographic visualization of all four target vessels) was

99.27% (408/411) in the TRA group, significantly higher than the 87.00% (368/423) achieved in the TFA group ($P < 0.001$), as detailed in **Table 3**. In the TFA group, all 55 cases with incomplete selective angiography resulted from failure to selectively catheterize the right vertebral or subclavian artery, with 32 (58.2%) of these occurring in patients with a Type III aortic arch.

Procedure time and radiation exposure

The total procedure time was significantly shorter in the TRA group (32.4 ± 14.51 min) than in the TFA group (42.54 ± 22.51 min; $P < 0.001$). This advantage remained evident in the subgroup of patients with a Type III aortic arch (TRA: 36.1 ± 14.4 min vs. TFA: 46.45 ± 31.53 min; $P = 0.047$). In contrast, no significant intergroup differences were observed in fluoroscopy time or radiation dose, both in the

Transradial cerebral angiography with SM2 catheter

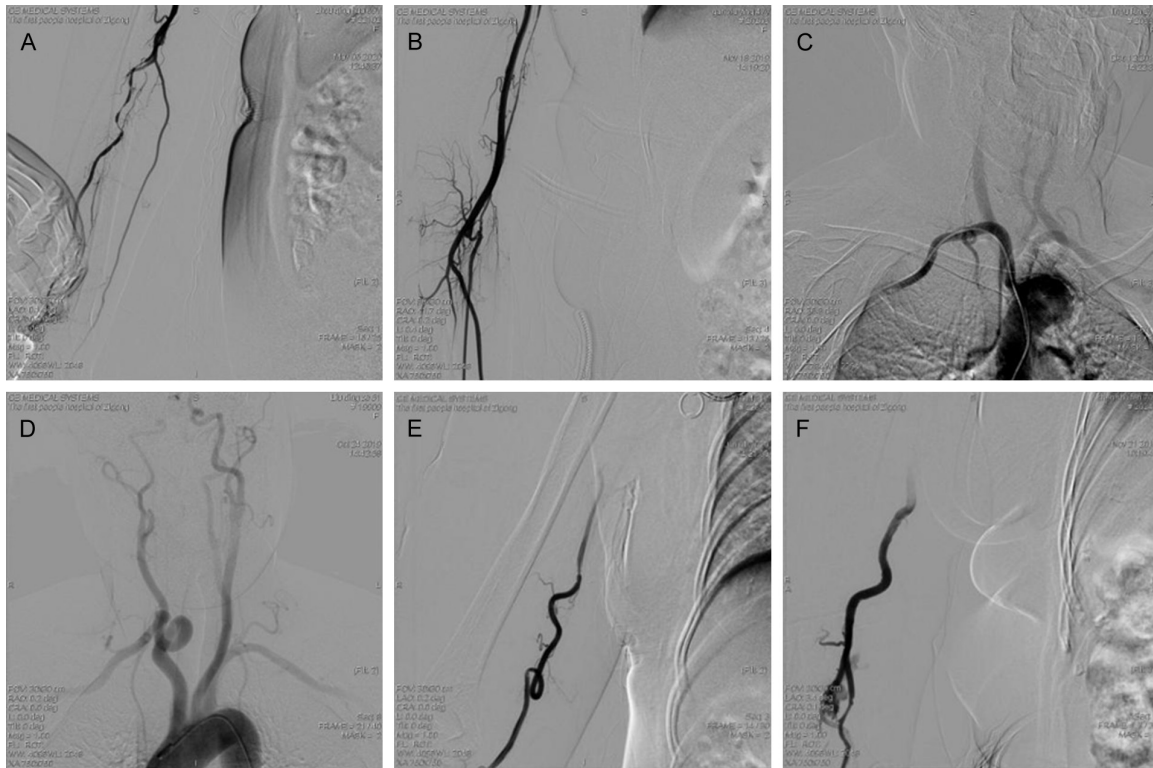


Figure 5. Representative causes of failure of cerebral angiography via TRA. A. Small radial artery diameter. B. Guidewire entering an accessory brachial artery. C. Aberrant aortic arch anatomy. D. Excessive tortuosity of the right subclavian artery. E. Looping and tortuosity of the radial artery. F. Radial artery branch perforation with bleeding.

Table 3. Comparison of angiographic completion rates between the two groups

Group	Complete selective angiography	Non-selective angiography	Total
TFA group	368	55	423
TRA group	408	3	411
χ^2	48.520		834
P value	0.000		

TFA, transfemoral approach; TRA, transradial approach.

overall cohort and within the Type III arch subgroup. Detailed procedural and radiation parameters are presented in **Table 4**.

Complications

The overall incidence of procedure-related complications was significantly lower in the TRA group (8.71%, 37/425) compared to the TFA group (18.46%, 79/428) ($P < 0.001$; **Table 5**). In the TFA group, the most notable complications were pseudoaneurysm (4.91%) and lower-limb venous thrombosis (0.70%). Complications in the TRA group were predomi-

nantly minor, consisting mainly of puncture-site pain or discomfort (7.76%) and vasospasm (1.88%). One case of arteriolar hemorrhage (0.24%) in the TRA group was successfully managed with manual compression. No serious adverse events occurred in either group.

Discussion

This retrospective cohort study demonstrates that cerebral angiography via the right TRA using an SM2 catheter combined with a long guidewire exchange technique is not only non-inferior to the conventional TFA in terms of procedural success but is associated with significantly higher angiographic completeness, shorter procedure times, and a markedly lower incidence of access-site complications.

Efficacy and safety in the context of existing literature

Our finding of a high procedural success rate (96.71%) with TRA exceeds the 92.8% success rate reported in the early neurosurgical series by Matsumoto et al. [6] and aligns closely with

Transradial cerebral angiography with SM2 catheter

Table 4. Procedural and radiation exposure parameters in the overall cohort and the type III aortic arch subgroup

Parameter	Group	Overall Cohort	Type III Aortic Arch Subgroup
Operation Time (min)	TFA group	42.54 ± 22.51	46.45 ± 31.53
	TRA group	32.4 ± 14.51	36.1 ± 14.4
	P value	< 0.001	0.047
Fluoroscopy Time(min)	TFA group	18.46 ± 10.39	21.47 ± 15.46
	TRA group	18.12 ± 8.77	21.03 ± 12.07
	P value	0.607	0.893
Radiation Dose (mGy)	TFA group	422.08 ± 316.88	454.04 ± 398.52
	TRA group	419.27 ± 173.78	392.9 ± 135.74
	P value	0.873	0.319

TFA, transfemoral approach; TRA, transradial approach.

Table 5. Comparison of incidence of complications between the two groups

	TFA group	TRA group	χ^2	P value
Complication			17.260	0.000
Yes	79	37		
No	349	388		

TFA, transfemoral approach; TRA, transradial approach.

the more recent study by Mirbolouk et al. [11], which reported a 97.2% success rate in 289 patients. This demonstrates that the outcomes observed in our cohort are comparable to contemporary evidence and further supports the feasibility and reliability of the TRA technique in cerebral angiography. A systematic review [12] encompassing 12,693 patients from 24 studies likewise substantiates that transradial cerebral angiography achieves procedural success rates comparable to those of the transfemoral approach. Notably, the angiographic completeness rate (99.27%) in our study surpasses that reported in previous reports [13]. We attribute this improvement to our standardized technical protocol, which directly addresses a key limitation noted in earlier literature: the absence of a uniform and reliable method for catheter navigation and vessel selection [14].

The key innovation of our protocol involves the use of a pigtail catheter to safely position a long guidewire in the descending aorta, followed by catheter exchange to an SM2 catheter, which ensures reliable loop formation. This approach effectively addresses the primary technical hurdle highlighted in prior studies: the

unpredictable or potentially unsafe shaping of catheters within the aortic arch, which can lead to failed selective cannulation [17]. Our data provides strong support for this approach, showing that TRA maintained a high angiographic completeness rate even in patients with Type III aortic arches, a subgroup historically associated with technical difficulty for TFA. In our study, the incomplete rate in the TFA group was 64% among patients with Type III arches, consistent with the recognized challenge of arch anatomy [18].

Regarding safety, in our study, the significantly lower complication rate in the TRA group (8.71% vs. 18.46% for TFA) further reinforces the well-documented safety advantage of radial access established in the cardiology literature [19] and supported by earlier neurointerventional case series [6]. The near elimination of pseudoaneurysm in our TRA cohort (0% vs. 4.91% in TFA) is particularly significant. This safety advantage is consistent with contemporary evidence, as demonstrated in a recent comparative study by Xi et al. [20], which reported a significantly higher incidence of both hematoma and pseudoaneurysm in the TFA group compared to the TRA group. The mechanism is primarily anatomical: the superficial, easily compressible radial artery minimizes the risk of concealed hematoma, a known drawback of femoral access. Furthermore, most TRA-related complications observed in our study were transient and minor (e.g., vasospasm), consistent with prior reports [21], and the complications were manageable, as noted by Evan Luther et al. [22].

Transradial cerebral angiography with SM2 catheter

Procedural efficiency, learning curve, and standardization

The significantly shorter procedure time for TRA (approximately 10 minutes less than TFA) represents an important advantage for procedural workflow optimization. This efficiency gain, also noted by Wilkinson et al. [17], may stem from rapid hemostasis compared with prolonged compression typically required following femoral artery puncture. Our findings demonstrate that TRA does not increase fluoroscopy time or radiation exposure, supports the notion that radiation exposure should no longer be considered a major barrier to TRA adoption [18].

The successful implementation of our approach underscores the importance of overcoming the procedural learning curve, a challenge discussed in prior studies [23, 24]. In this context, the standardized protocol - detailing the exchange technique for safe SM2 loop formation - provides a solution to the variability in technical routes and device selection that has hindered widespread adoption of TRA. Notably, this lack of procedural standardization was explicitly noted in the 2018 Chinese expert consensus and is reflected in the literature dominated by personal experience reports.

Study limitations and future directions

Several limitations of this study should be considered when interpreting the findings. First, this was a single-center retrospective study conducted in a high-volume neurointerventional center. While this ensures procedural consistency, it may limit the generalizability of our results to institutions with different patient populations, or operator experience levels.

Second, due to the non-randomized retrospective design, selection bias is unavoidable. The choice of TRA or TFA was made by operators based on clinical judgment and anatomical considerations, not by randomization. Although we employed multivariate logistic regression to adjust for measured confounders such as age, sex, aortic arch type, and comorbidities, residual confounding from unmeasured variables (e.g., vessel tortuosity, frailty, or operator preference) cannot be excluded and may have influenced the observed associations.

Third, data were retrospectively extracted from medical records and electronic databases, which may have introduced information bias and potential inaccuracies. Although we used standardized data extraction forms and independent verification by two investigators to minimize errors, the possibility of incomplete or misclassified documentation remains. Importantly, the objective nature of the primary endpoints (e.g., procedure time, complication rates) partly mitigates this concern.

Fourth, the follow-up period was limited to peri-procedural phase. Long-term data on radial artery patency, patient-reported quality of life, or late complications were not available. Although cardiology studies suggest that radial artery occlusion is a minor concern [26], dedicated neurointerventional follow-up data are warranted.

Finally, although a standardized technical protocol is described in this study, its successful implementation in other centers will require a dedicated learning phase, estimated in the literature to be around 25-50 cases [17]. Future prospective multicenter studies with standardized protocols and longer follow-up are needed to validate our findings and to further establish the role of TRA in neuroangiography.

Conclusion and implications

TRA using an SM2 catheter combined with a safety-enhanced long guidewire exchange protocol represents a favorable alternative to the TFA for diagnostic cerebral angiography. It offers enhanced efficacy, greater patient comfort, and improved safety. The detailed description of our technique, centered on safe loop formation in the descending aorta, addresses a key technical variability highlighted in prior literature and provides a reproducible model for broader clinical implementation. Future multicenter studies, preferably with prospective designs, are warranted to validate these findings across different practice settings and to explore the application of this optimized TRA protocol in therapeutic neurointerventional procedures.

Acknowledgements

This work was supported by the Zigong Science and Technology Bureau (Grant No.: 2020YLSF03).

Disclosure of conflict of interest

None.

Address correspondence to: Xiaoyan Dai, Department of Outpatient, Zigong First People's Hospital, Zigong 643000, Sichuan, China. Tel: +86-13990024811; E-mail: dxy_zgyyy@163.com

References

- [1] Schartz D, Akkipeddi SMK, Ellens N, Rahmani R, Kohli GS, Bruckel J, Caplan JM, Mattingly TK, Bhalla T and Bender MT. Complications of transradial versus transfemoral access for neuroendovascular procedures: a meta-analysis. *J Neurointerv Surg* 2022; 14: 820-825.
- [2] Zhang Y, Lan W, Liu H, Yuan K and Ye R. Transradial approach in vertebral artery stenting. *Front Neurol* 2025; 16: 1643105.
- [3] Elfil M, Ghaith HS, Jain A, Spirollari E, Sacknovitz A, Elmashad A, Aladawi M, Salem MM, Najdawi Z, El-Ghanem M, Khandelwal P, Jabbour P, Aljehani H, Santarelli J, Gandhi CD and Al-Mufti F. Transradial access as an innovative approach for endovascular thrombectomy: a living systematic review and meta-analysis. *Cardiol Rev* 2025; 33: 382-393.
- [4] Basile M, Salzillo C, Bianchini E, Bianchini F, Jurado-Roman A, Gaspardone A, Burzotta F and Sgueglia GA. Dedicated sheathless system versus sheath-based approach for transradial percutaneous coronary intervention: systematic review and meta-analysis. *Catheter Cardiovasc Interv* 2025; 105: 1668-1676.
- [5] Campeau L. Percutaneous radial artery approach for coronary angiography. *Cathet Cardiovasc Diagn* 1989; 16: 3-7.
- [6] Matsumoto Y, Hongo K, Toriyama T, Nagashima H and Kobayashi S. Transradial approach for diagnostic selective cerebral angiography: results of a consecutive series of 166 cases. *AJNR Am J Neuroradiol* 2001; 22: 704-708.
- [7] Xia J, Xiao S, Xv G, Li T and Wang Z. Effects and safety of the transradial artery approach for cerebral angiography: a comparative observational study. *Eur J Radiol* 2025; 188: 112165.
- [8] Rentiya ZS, Kuhn AL, Hutnik R, Shazeeb MS, De Leacy RA, Goldman D, Singh J and Puri AS. Transradial access for cerebral angiography and neurointerventional procedures: a meta-analysis and systematic review. *Interv Neuroradiol* 2024; 30: 404-411.
- [9] Shi M and He S. Transradial and transfemoral accesses for cerebral angiography: a retrospective comparative study. *Neurol Res* 2023; 45: 1063-1068.
- [10] Gao Y, Liu B, Yang H, Wang G, Huang J, Li C, Zhao P, Yang L and Yang Z. Comparison of transradial access and transfemoral access for diagnostic cerebral angiography in the elderly population. *World Neurosurg* 2024; 181: e411-e421.
- [11] Mirbolouk MH, Ebrahimnia F, Gorji R, Sasannejad P, Zabihyan S, Hoveizavi MA, Garivani Y, Mirzaasgari Z, Abdollahifard S, Mowla A and Baharvahdat H. Transradial access for neurointerventional procedures: a practical approach. *Brain Circ* 2023; 9: 88-93.
- [12] Mortezaei A, Hajikarimloo B, Eraghi MM, Sheikholeslami S, Sameer O, Shahidi R, Seraj FQM, Dmytriw AA, Rahmani R and Kasab SA. Trans-radial vs. trans-femoral approaches in diagnostic cerebral angiography: a comprehensive systematic review and meta-analysis of practicality and cost-effectiveness. *Clin Neurol Neurosurg* 2024; 247: 108637.
- [13] Shi M and He S. Transradial and transfemoral accesses for cerebral angiography: a retrospective comparative study. *Neurol Res* 2023; 45: 1063-1068.
- [14] Wu C, Qi DY, Zhu DY, Du M, He JL, Ye SF, Zheng TH and Fang YB. Pigtail catheter exchange technique for the Simmons catheter formation in transradial cerebral angiography. *Clin Neurol Neurosurg* 2023; 230: 107791.
- [15] Satti SR, Vance AZ and Sivapatham T. Radial access for cerebrovascular procedures: case report and technical note. *Interv Neuroradiol* 2016; 22: 227-235.
- [16] Snelling BM, Sur S, Shah SS, Khandelwal P, Caplan J, Haniff R, Starke RM, Yavagal DR and Peterson EC. Transradial cerebral angiography: techniques and outcomes. *J Neurointerv Surg* 2018; 10: 874-881.
- [17] Wilkinson DA, Majmundar N, Catapano JS, Fredrickson VL, Cavalcanti DD, Baranoski JF, Rutledge C, Ducruet AF and Albuquerque FC. Transradial cerebral angiography becomes more efficient than transfemoral angiography: lessons from 500 consecutive angiograms. *J Neurointerv Surg* 2022; 14: 397-402.
- [18] Sioutas GS, Salem MM, Muhammad N, Romeo D, Corral Tarbay A, Kim Y, Sussman J, Ng JJ, Rhodes IJ, Gajjar A, Zager EL, Srinivasan VM, Burkhardt JK, Jankowitz BT and Choudhri OA. Feasibility and safety of transradial intraoperative angiography for neurosurgery: an institutional experience. *Interv Neuroradiol* 2023; [Epub ahead of print].
- [19] Damluji AA, Nanna MG, Mason P, Lowenstern A, Orkaby AR, Washam JB, Kolkailah AA, Beckie TM, Dangas G and Lawton JS; American Heart Association Interventional Cardiovascular Care Committee of the Council on Clinical Cardiology; Council on Arteriosclerosis, Thrombosis and Vascular Biology; Council on Cardiovascular and Stroke Nursing; Council on Car-

Transradial cerebral angiography with SM2 catheter

- diovascular Surgery and Anesthesia; Council on Quality of Care and Outcomes Research. Coronary artery revascularization in the older adult population: a scientific statement from the American heart association. *Circulation* 2025; 152: e494-e525.
- [20] Xi H, Lu CY, Wang N, Zhao Y, Zhao YL, Hong T and Zhang WC. Effects of different puncture approaches on the curative effect and safety of patients with combined cardiovascular and cerebrovascular angiography. *Wideochir Inne Tech Maloinwazyjne* 2024; 19: 107-112.
- [21] Ramzan A, Kobeissi H, Ghozy S, Kadirvel R and Kallmes DF. Transradial balloon guide catheter placement for acute ischemic stroke thrombectomy: a systematic review and meta-analysis. *Interv Neuroradiol* 2023; [Epub ahead of print].
- [22] Luther E, Burks J, McCarthy DJ, Govindarajan V, Nada A, Saini V, Jamshidi A, King H, Heath R, Silva M, Abecassis IJ and Starke RM. Radial access techniques. *Neurosurg Clin N Am* 2022; 33: 149-159.
- [23] Hendrix P, Melamed I, Weiner GM, Goren O, Griessenauer CJ and Schirmer CM. Transradial versus transfemoral intraoperative cerebral angiography for open cerebrovascular surgery: effectiveness, safety, and learning curve. *Oper Neurosurg* 2023; 24: 476-482.
- [24] Tso MK, Rajah GB, Dossani RH, Meyer MJ, McPheeters MJ, Vakharia K, Waqas M, Snyder KV, Levy EI, Siddiqui AH and Davies JM. Learning curves for transradial access versus transfemoral access in diagnostic cerebral angiography: a case series. *J Neurointerv Surg* 2022; 14: 174-178.
- [25] Ahmad F, Ullah I and Khan SW. Radial artery occlusion after transradial access for coronary interventions. *Cureus* 2024; 16: e58036.
- [26] Zussman BM, Tonetti DA, Stone J, Brown M, Desai SM, Gross BA, Jadhav A, Jovin TG and Jankowitz BT. Maturing institutional experience with the transradial approach for diagnostic cerebral arteriography: overcoming the learning curve. *J Neurointerv Surg* 2019; 11: 1235-1238.