

## Original Article

# Traumatic elbow stiffness: pathogenic spectrum and comparative outcomes of minimally invasive versus open release surgery

Ye Tian<sup>1\*</sup>, Zhuangdai Zhang<sup>1\*</sup>, Pengfei Liu<sup>1</sup>, Yue Geng<sup>1</sup>, Yadong Yu<sup>2</sup>

<sup>1</sup>Department of Joint Surgery IV, The Third Hospital of Hebei Medical University, Shijiazhuang 050041, Hebei, China; <sup>2</sup>Department of Hand Surgery, The Third Hospital of Hebei Medical University, Shijiazhuang 050041, Hebei, China. \*Equal contributors and co-first authors.

Received March 7, 2026; Accepted April 22, 2026; Epub May 15, 2026; Published May 30, 2026

**Abstract:** Objective: To identify the predominant pathogenic factors in traumatic elbow stiffness (TES) and to compare functional outcomes between minimally invasive and open release surgery. Methods: We retrospectively analyzed 120 patients with TES who were admitted to the HEBEI MEDICAL UNIVERSITY THIRD HOSPITAL between June 2023 and December 2025. Of these, 60 underwent minimally invasive release surgery and 60 underwent open release surgery. Pathogenic causes were determined via preoperative imaging and intraoperative findings. Range of motion (ROM), Mayo Elbow Performance Score (MEPS), and SF-36 were assessed preoperatively and at 6 months. Results: Ligamentous contracture (91.7%) and heterotopic ossification (80.0%) were the two most common pathologies. The minimally invasive group achieved significantly higher total effectiveness rate (95.0% vs. 83.3%,  $\chi^2 = 12.818$ ,  $P = 0.002$ ), greater gains in extension ( $\Delta 34.93^\circ$  vs.  $\Delta 25.41^\circ$ ) and flexion ( $\Delta 42.23^\circ$  vs.  $\Delta 22.13^\circ$ ) (both  $P < 0.001$ ), and superior MEPS and SF-36 scores (all  $P < 0.001$ ). Multivariable regression analysis confirmed that surgical approach was an independent predictor of both MEPS total score ( $\beta = -9.17$ ,  $P < 0.001$ ) and good clinical outcome (OR = 0.18,  $P = 0.031$ ). Conclusion: Ligamentous contracture and heterotopic ossification constitute the main treatable targets in TES. Compared with open release surgery, minimally invasive surgery yields better early functional recovery, likely due to reduced iatrogenic trauma and faster rehabilitation. These findings support minimally invasive release surgery as a preferred option for appropriate TES candidates.

**Keywords:** Traumatic elbow stiffness, pathogenic causes, minimally invasive release surgery, range of motion, functional score

## Introduction

Traumatic elbow stiffness (TES) is a common and complex complication following elbow trauma [1-3]. It is defined as a persistent limitation of the normal range of motion of the elbow joint caused by pathological changes [4]. This functional impairment not only severely affects patients' activities of daily living (ADLs) - such as dressing, washing, and eating - but also poses significant challenges to their occupational function and mental health. Elbow stiffness affects an estimated 20-30% of patients following elbow trauma, representing a major clinical challenge in both orthopedics and rehabilitation [5-7].

As the core hub in the functional chain of the upper limb, the elbow's unique anatomy dictates that it must possess both stability to bear loads and flexibility to achieve multi-directional movement [8, 9]. This delicate balance depends on the interplay among osseous geometry, ligamentous tension, capsular compliance, and muscular control [10]. When the elbow sustains direct violence, fractures, dislocations, or surgical interventions, the balance of this sophisticated system is easily disrupted, triggering a series of complex pathophysiological changes [11, 12].

The disruption of this homeostatic balance initiates a self-perpetuating cycle of inflammation, fibrosis, and mechanical restriction. Acute trau-

ma triggers intra-articular hemarthrosis and the release of pro-inflammatory cytokines (e.g., TGF- $\beta$ , IL-6), leading to synovial hyperplasia and capsular edema. Prolonged immobilization, often required for fracture healing, exacerbates this process by promoting the differentiation of fibroblasts into myofibroblasts, which deposit excessive disorganized collagen and result in capsular fibrosis and ligamentous contracture - particularly affecting the posterior bundle of the medial collateral ligament. Concurrently, in a subset of patients with severe injury or genetic predisposition, local mesenchymal stem cells undergo aberrant differentiation along an osteoblastic lineage under the influence of bone morphogenetic proteins (BMPs), culminating in heterotopic ossification (HO). These pathological entities are not isolated; rather, capsular fibrosis increases joint volume pressure, which amplifies the functional 'bowstring' effect of a contracted ligament. Meanwhile, space-occupying osteophytes and HO act as rigid mechanical blocks, further limiting excursion and perpetuating disuse atrophy of the periarticular musculature. Understanding this interconnected pathogenic network is essential for tailoring surgical interventions that address the specific combination of soft-tissue and osseous restraints.

These changes do not exist in isolation; rather, they are intertwined and mutually causal, forming a network of etiological factors leading to joint stiffness [13]. For a long time, the academic community has held diverse views regarding the pathogenesis of post-traumatic elbow stiffness [14, 15]. Traditional perspectives emphasize intra-articular adhesions caused by hematoma organization and fibrin deposition, as well as contractures of the joint capsule and ligaments resulting from long-term immobilization [16]. In recent years, with advancements in imaging technology and pathological research, heterotopic ossification (HO) has received widespread attention as an independent pathogenic factor with poor predictability [17]. Heterotopic ossification refers to the abnormal formation of mature lamellar bone in non-skeletal tissues [18]. It frequently occurs after severe trauma, central nervous system injuries, or surgical procedures. The growth of HO around the elbow can directly create mechanical blocks, severely restricting joint movement. Furthermore, osteophytes resulting from malunited or non-united fractures, as well as extensive soft tissue fibrosis

mediated by post-traumatic inflammatory responses, are increasingly recognized as important causes of refractory stiffness [19].

When conservative measures fail, surgical release remains the cornerstone for restoring elbow motion. Traditional open approaches (e.g., Kocher, Bryan-Morrey) afford excellent visualization and allow thorough resection of osteophytes, heterotopic bone, and contracted capsule. Yet this comes at the expense of substantial soft tissue dissection, increased blood loss, postoperative pain, and a potential for recurrent adhesions. In contrast, minimally invasive techniques - arthroscopic or mini-open - have gained traction by enabling targeted release through small portals while preserving uninvolved structures. This technology utilizes a high-definition imaging system to magnify and view the intra-articular structures directly through several small channels, enabling precise resection and release of diseased tissues. Simultaneously, it protects normal nerves, blood vessels, and soft tissues to the greatest extent. Theoretically, it possesses the potential advantages of reducing iatrogenic injury, alleviating postoperative pain, and accelerating the rehabilitation process. However, whether there are limitations to minimally invasive surgery when dealing with complex situations such as extensive heterotopic ossification and severe joint capsule contracture, and whether its long-term efficacy is superior to or equivalent to open surgery, still require more high-quality clinical studies to provide evidence.

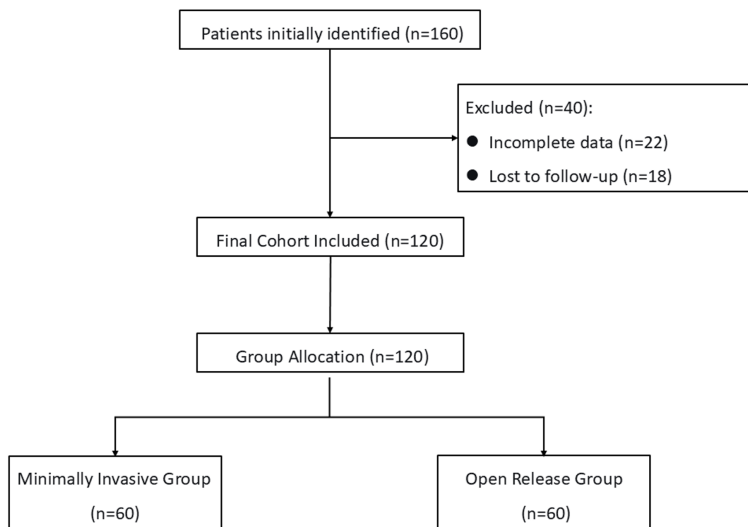
To address these knowledge gaps, we conducted a retrospective cohort study with three aims: (1) To delineate the prevalence and patterns of various pathogenic factors in TES; (2) To compare the efficacy of minimally invasive versus open release surgery in terms of ROM, functional scores, and quality of life; and (3) To assess whether surgical approach influences postoperative pain and joint stability. We hypothesized that minimally invasive release surgery would result in superior functional recovery without compromising stability. The findings are intended to inform evidence-based surgical decision-making for TES.

### Materials and methods

#### *Study design*

This study is a retrospective cohort study designed to analyze the pathogenic causes of

## Traumatic elbow stiffness & release surgery



**Figure 1.** Flowchart of patient selection.

traumatic elbow stiffness (TES) and to compare the clinical efficacy of minimally invasive release surgery and open release surgery. The research data were sourced from the electronic medical record system of the HEBEI MEDICAL UNIVERSITY THIRD HOSPITAL, and all diagnostic and therapeutic processes followed the routine clinical pathways. This study was approved by the Institutional Review Board of HEBEI MEDICAL UNIVERSITY THIRD HOSPITAL. All procedures adhered to the tenets of the Declaration of Helsinki (2013).

### Study subjects

Patients diagnosed with traumatic elbow stiffness and treated with surgical release in the Department of Orthopedics of our hospital between June 2023 and December 2025 were retrospectively included. According to the surgical method received, patients were divided into two groups: those who underwent minimally invasive release surgery were assigned to the minimally invasive group (observation group,  $n = 60$ ), and those who underwent traditional open release surgery were assigned to the open group (control group,  $n = 60$ , **Figure 1**).

### Inclusion and exclusion criteria

Inclusion criteria were as follows: (1) established diagnosis of post-traumatic elbow stiffness, defined by the following criteria: (I) a documented history of elbow trauma or prior elbow surgery; (II) loss of elbow range of motion with a

flexion-extension arc of  $<100^\circ$  or a flexion contracture exceeding  $30^\circ$ ; (III) persistence of symptoms for  $>6$  months after the initial injury or  $>3$  months after the conclusion of formal conservative therapy; and (IV) preoperative imaging confirming structural abnormalities consistent with stiffness; (2) age between 18 and 70 years; (3) confirmation of organic lesions on preoperative imaging; and (4) availability of complete clinical and follow-up data.

Exclusion criteria comprised: (1) malignant tumor of the elbow joint or pathological fracture; (2) severe systemic diseases contraindicating surgery; (3) congenital deformity or developmental abnormalities of the elbow; (4) history of inflammatory arthropathy, including infectious or rheumatoid arthritis; (5) cognitive impairment, mental illness, or peripheral nerve injury that could interfere with assessment; and (6) loss to follow-up during the study period.

### Surgical methods

All surgeries were performed by the same team of senior orthopedic surgeons.

Open release group (Open release surgery): Performed under general anesthesia with the patient in a supine position. A standard Kocher lateral approach combined with a Bryan-Morrey medial approach was utilized. Through the lateral approach, the joint capsule was incised to remove anterior heterotopic ossification, osteophytes, and scar tissue, while protecting the radial nerve. Through the medial approach, posterior adhesions were released, and posterior heterotopic ossification and osteophytes were removed. Intraoperatively, care was taken to protect the ulnar nerve and the anterior bundle of the medial collateral ligament. Postoperatively, the affected elbow was immobilized in extension with a plaster cast.

Minimally invasive group (Minimally invasive release surgery): Performed under general anesthesia as well. Anterolateral, anteromedial, posterolateral, and posteromedial arthroscopic or mini-open operative portals were estab-

## Traumatic elbow stiffness & release surgery

lished. Under direct arthroscopic vision or mini-open assistance, heterotopic ossification, hyperplastic osteophytes, and fibrous scar tissue were precisely removed. Targeted limited release of the contracted posterior bundle of the ulnar collateral ligament and the joint capsule was performed. Throughout the procedure, neurovascular structures were protected. Postoperatively, the affected elbow was immobilized in extension for only a short period (4-24 hours).

Both groups received the same postoperative rehabilitation protocol and were prescribed oral indomethacin (25 mg, three times daily for 6 weeks) to prevent recurrence of heterotopic ossification.

### *Observation indicators*

The following data were collected by reviewing medical records, imaging data, and postoperative follow-up records.

Analysis of pathogenic causes: Combining preoperative imaging (X-ray, CT) and surgical records, the existing pathogenic factors in each patient were identified and recorded, including ligamentous contracture (focusing on the posterior bundle of the ulnar collateral ligament), heterotopic ossification, capsular fibrosis, osteophyte formation, and soft tissue adhesions.

Clinical efficacy evaluation: Efficacy was assessed at 6 months postoperatively. *Excellent*: Symptoms basically disappeared, joint stable, range of motion  $\geq 110^\circ$ ; *Good*: Symptoms relieved, joint stability acceptable, range of motion between  $60^\circ$ - $110^\circ$ ; *Poor*: Did not meet the above standards. Total effective rate = (Number of excellent + good cases)/Total number of cases  $\times 100\%$ .

Range of motion measurement: By a rehabilitation therapist blinded to the grouping, a universal goniometer was used to measure the range of motion of extension, flexion, internal rotation, and external rotation of the affected elbow preoperatively and at 6 months postoperatively.

Functional and quality of life assessment: The Mayo Elbow Performance Score (MEPS) was used to evaluate elbow-specific function. The MEPS is a 100-point scale comprising four subscales: pain (45 points), range of motion (20

points), stability (10 points), and daily function (25 points). Scores were categorized as excellent ( $>90$ ), good (75-89), fair (60-74), or poor ( $<60$ ). To ensure consistency, all assessments were performed by a single senior rehabilitation therapist who was blinded to the surgical assignment.

The Short Form-36 (SF-36) Health Survey (Chinese standardized version) was administered to evaluate generic health-related quality of life. Raw scores were transformed and normalized to calculate the Physical Component Summary (PCS) and the Mental Component Summary (MCS), which represent physical health and psychological well-being, respectively. Higher scores indicate better health status.

Measurement protocol for range of motion: A standardized universal goniometer was used with the patient in a supine position and the arm placed in a neutral rotation. Bony landmarks (lateral epicondyle, radial styloid, and acromion) were marked preoperatively to ensure consistent placement. Three consecutive measurements were taken for each motion plane (extension-flexion, pronation-supination), and the mean value was recorded for analysis.

### *Statistical analysis*

Statistical analysis was performed using Python (version 3.13) with the following libraries: pandas, numpy, scipy.stats, statsmodels, and matplotlib/seaborn for visualization. Continuous variables were tested for normality using the Shapiro-Wilk test. Normally distributed data were presented as mean  $\pm$  standard deviation and were compared using independent-samples t-test (between groups) or paired-samples t-test (within group). Non-normally distributed data were presented as median (interquartile range) and were analyzed using the Mann-Whitney U test (between groups) or Wilcoxon signed-rank test (within group). Categorical variables were compared using the chi-square test or Fisher's exact test, as appropriate.

To assess the magnitude of differences, effect sizes were calculated. Cohen's d with 95% confidence interval (CI) was computed for continuous variables, where values of 0.2, 0.5, and 0.8 were considered small, medium, and large effects, respectively. For categorical variables, Cramer's V was reported.

## Traumatic elbow stiffness & release surgery

**Table 1.** Baseline characteristics and etiological distribution of patients with traumatic elbow stiffness

Variable/Etiology	Observation group (n = 60)	Control group (n = 60)	$\chi^2/t$	P-value
Baseline characteristics				
Age (years), mean $\pm$ SD	46.4 $\pm$ 3.6	46.9 $\pm$ 3.7	-0.750	0.455
Disease duration (months), mean $\pm$ SD	8.41 $\pm$ 1.64	8.57 $\pm$ 2.50	-0.414	0.680
Male sex, n (%)	24 (40.0)	31 (51.7)	1.645	0.199
Affected side, n (%)			0.033	0.855
Left	30 (50.0)	29 (48.3)		
Right	30 (50.0)	31 (51.7)		
Concurrent heterotopic ossification, n (%)	11 (18.3)	10 (16.7)	0.058	0.810
Etiological factors				
Ligamentous contracture	56 (93.3)	54 (90.0)	0.109	0.741
Heterotopic ossification	49 (81.7)	47 (78.3)	0.052	0.819
Capsular fibrosis	43 (71.7)	33 (55.0)	2.907	0.088
Osteophyte formation	32 (53.3)	28 (46.7)	0.300	0.584
Soft tissue adhesion	31 (51.7)	36 (60.0)	0.541	0.462

Note: Data for etiological factors are presented as n (%). All P-values were calculated using  $\chi^2$  test or independent-samples t-test as appropriate. Abbreviation: SD, Standard Deviation; HO, Heterotopic Ossification.

Correlations between variables were examined using Pearson's  $r$  for parametric data and Spearman's  $\rho$  for non-parametric data. Correlation strengths were interpreted as weak ( $|r| < 0.3$ ), moderate ( $0.3 \leq |r| < 0.7$ ), or strong ( $|r| \geq 0.7$ ).

Multivariable linear regression analysis was performed to identify independent predictors of postoperative MEPS total score. The model included surgical approach (Minimally invasive vs. Open release), age, sex, disease duration, affected side, concurrent HO, and all five etiological factors (ligamentous contracture, heterotopic ossification, capsular fibrosis, osteophyte formation, soft tissue adhesion). Results are reported as unstandardized coefficients ( $\beta$ ) with 95% CI and P-values.

Multivariable logistic regression analysis was conducted to identify independent predictors of good clinical outcome (excellent or effective). The same set of covariates was entered into the model. Results are presented as odds ratios (OR) with 95% CI and P-values. The variable ligamentous contracture was excluded from the final logistic model due to near-perfect separation, which caused unstable estimates; its exclusion did not affect the significance of the remaining covariates.

Subgroup analyses were performed to assess the consistency of treatment effect across cli-

nically relevant subgroups: gender (male vs. female), age ( $\leq$  median vs.  $>$  median), presence of concurrent HO (yes vs. no), ligamentous contracture (yes vs. no), and heterotopic ossification (yes vs. no). For each subgroup, the mean difference in MEPS total score between the two surgical groups was calculated with 95% CI and displayed using a forest plot.

All tests were two-tailed, and a P-value  $< 0.05$  was considered statistically significant.

### Results

#### Baseline characteristics and etiological profile

The two groups were well balanced with respect to baseline demographic and clinical characteristics. No significant differences were observed in age (46.4  $\pm$  3.6 vs. 46.9  $\pm$  3.7 years,  $P = 0.455$ ), disease duration (8.41  $\pm$  1.64 vs. 8.57  $\pm$  2.50 months,  $P = 0.680$ ), sex distribution (40.0% vs. 51.7% male,  $P = 0.199$ ), affected side ( $P = 0.855$ ), or the presence of concurrent heterotopic ossification (18.3% vs. 16.7%,  $P = 0.810$ ). The effect sizes for these variables were negligible (Cohen's  $d$  for age: -0.16, 95% CI -0.51 to 0.20; Cramer's  $V$  for categorical variables  $\leq 0.10$ ) (Table 1).

Analysis of preoperative imaging and intraoperative findings revealed that traumatic elbow

## Traumatic elbow stiffness & release surgery

**Table 2.** Comparison of clinical efficacy between the two groups

Outcome category	Observation group (n = 60)	Control group (n = 60)	$\chi^2$	P-value
Excellent	40 (66.7%)	21 (35.0%)		
Effective	17 (28.3%)	29 (48.3%)		
Ineffective	3 (5.0%)	10 (16.7%)		
Total effective rate	95.0%	83.3%	12.818	0.002

**Table 3.** Comparison of range of motion (ROM) between the two groups

Metric	Parameter	Observation group (n = 60)	Control group (n = 60)	t	P-value
Extension	Pre-op (°)	46.77 ± 3.85	45.49 ± 4.61		
	Post-op (°)	11.84 ± 5.25	20.08 ± 5.63		
	Improvement (°)	-34.93 ± 3.21*	-25.41 ± 3.62*	-15.236	<0.001
Flexion	Pre-op (°)	92.94 ± 4.81	93.10 ± 4.22		
	Post-op (°)	135.17 ± 7.12	115.23 ± 6.43		
	Improvement (°)	42.23 ± 5.27*	22.13 ± 4.54*	22.370	<0.001
Internal Rotation	Pre-op (°)	58.49 ± 5.54	60.03 ± 5.07		
	Post-op (°)	58.98 ± 5.65	60.52 ± 5.11		
	Improvement (°)	0.49 ± 0.45*	0.49 ± 0.48*	-0.041	0.967
External Rotation	Pre-op (°)	43.84 ± 4.43	42.76 ± 4.58		
	Post-op (°)	45.39 ± 4.48	44.23 ± 4.65		
	Improvement (°)	1.55 ± 0.54*	1.47 ± 0.51*	0.820	0.414

Note: Data are presented as mean ± standard deviation. Asterisks (\*) indicate statistically significant within-group improvement from preoperative to postoperative values ( $P < 0.001$  for all comparisons). Between-group differences in improvement scores were assessed using independent-samples *t*-tests; exact *t* and *p* values are reported. Abbreviation: ROM, Range of Motion.

stiffness stemmed from multiple coexisting pathologies. Ligamentous contracture was the most prevalent (91.7%), followed by heterotopic ossification (80.0%), capsular fibrosis (63.3%), soft tissue adhesions (55.8%), and osteophyte formation (50.0%). The distribution of these etiological factors did not differ significantly between the two groups (all  $P > 0.05$ ), confirming a comparable pathological basis (**Table 1**).

### Clinical efficacy

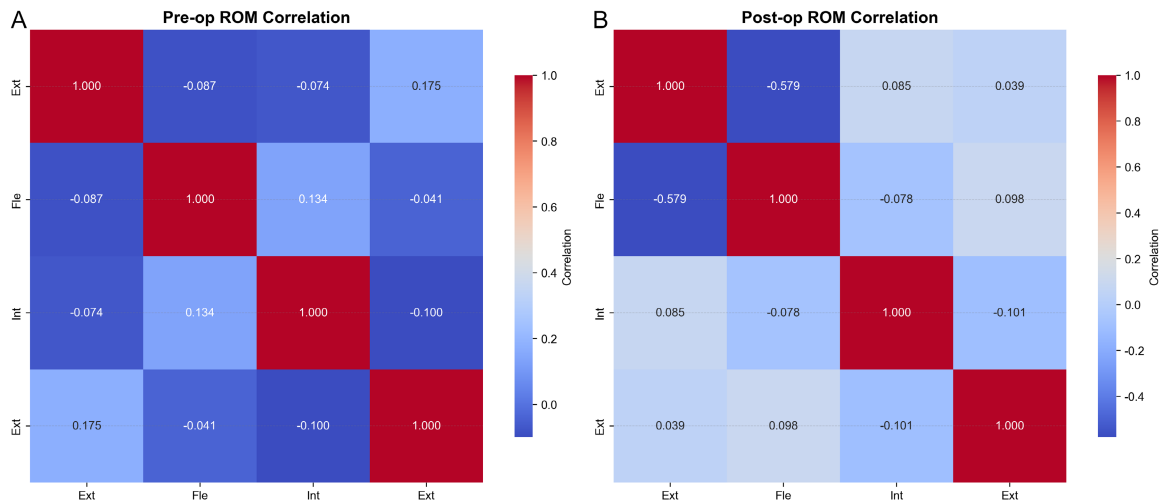
The minimally invasive group achieved significantly better clinical outcomes than the open release group. The total effective rate was 95.0% in the minimally invasive group versus 83.3% in the open group ( $P = 0.002$ ,  $\chi^2 = 12.818$ ). The distribution of efficacy grades also favored the minimally invasive group, with 66.7% of patients rated as “excellent” compared to 35.0% in the open group (**Table 2**). The risk difference for achieving a good or excellent outcome was 11.7% (95% CI 2.3% to 21.1%), corresponding to a number needed to treat (NNT) of 9.

### Range of motion (ROM) changes

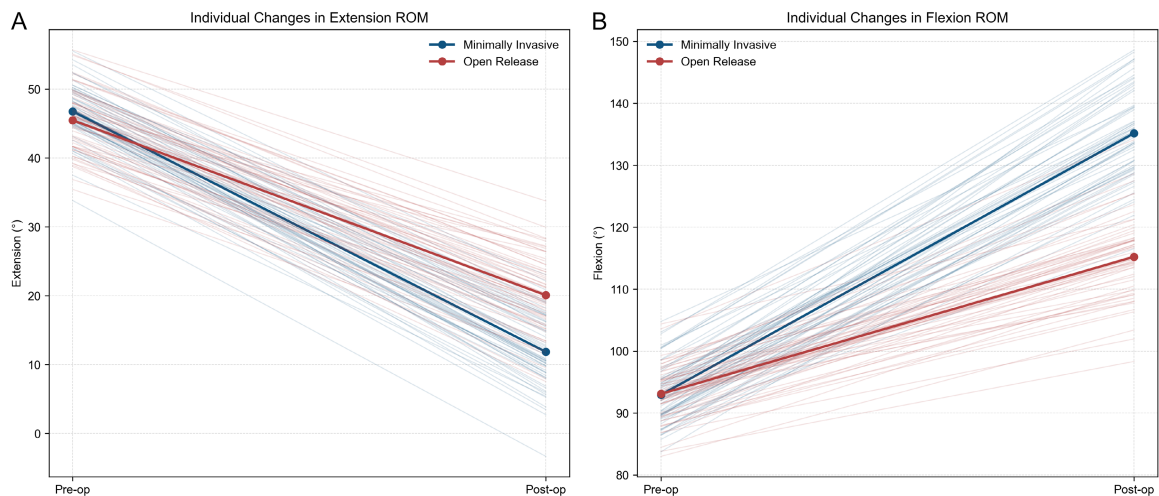
Both groups showed significant within-group improvements in all ROM parameters postoperatively (all  $P < 0.001$ ), but the magnitude of improvement was markedly greater in the minimally invasive group for extension and flexion. The minimally invasive group gained  $34.93^\circ \pm 3.21^\circ$  in extension (i.e., reduction of extension deficit) compared to  $25.41^\circ \pm 3.62^\circ$  in the open group (mean difference  $9.52^\circ$ , 95% CI  $8.24^\circ$  to  $10.80^\circ$ ;  $P < 0.001$ ; Cohen’s *d* = 2.78, 95% CI 2.28 to 3.29). Flexion improvement was  $42.23^\circ \pm 5.27^\circ$  vs.  $22.13^\circ \pm 4.54^\circ$  (mean difference  $20.10^\circ$ , 95% CI  $18.33^\circ$  to  $21.87^\circ$ ;  $P < 0.001$ ; Cohen’s *d* = 4.08, 95% CI 3.45 to 4.72). No significant between-group differences were observed for internal or external rotation (both  $P > 0.05$ ) (**Table 3**).

Preoperative ROM correlations were weak (**Figure 2A**), with extension and flexion showing a negligible negative correlation ( $r = -0.087$ ). Postoperatively, the negative correlation between extension and flexion strengthened con-

## Traumatic elbow stiffness & release surgery



**Figure 2.** ROM correlation heatmaps. A. Heatmap showing Pearson correlation coefficients among preoperative range of motion (ROM) parameters (extension, flexion, internal rotation, external rotation). Warmer colors indicate positive correlations, cooler colors indicate negative correlations. B. Heatmap showing postoperative ROM correlations. The strengthening of the negative correlation between extension and flexion postoperatively ( $r = -0.579$ ) indicates that patients with greater extension gains also achieved greater flexion gains. Abbreviation: ROM, Range of Motion.



**Figure 3.** Individual trajectories for extension and flexion. Individual patient changes in extension (A) and flexion (B) from pre-operative to 6 months post-operative. Light blue lines represent patients in the minimally invasive group, light red lines represent patients in the open release group. Thick solid lines with markers indicate group means. The plots visually confirm the superior improvements in both extension and flexion in the minimally invasive group.

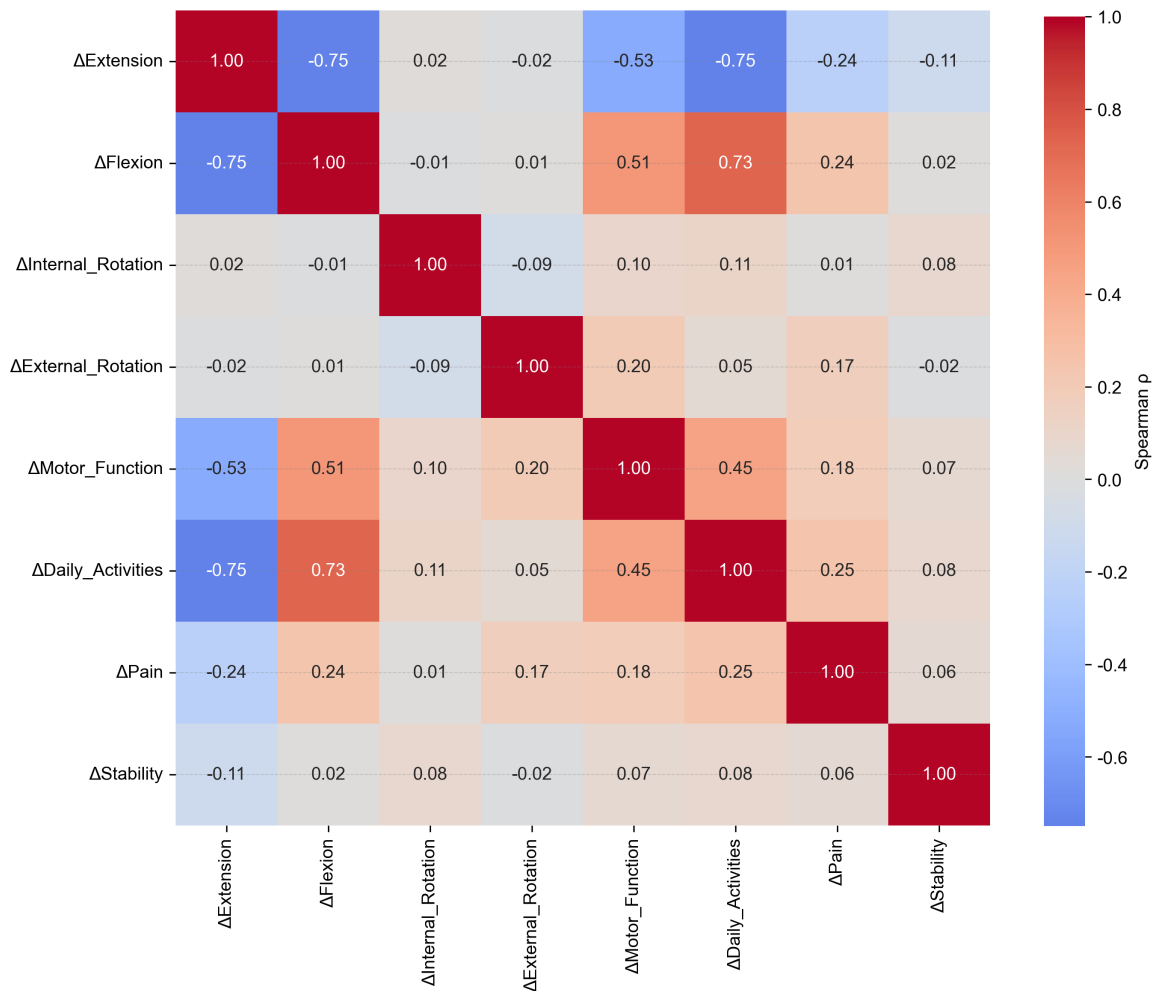
siderably ( $r = -0.579$ , **Figure 2B**), indicating that patients with greater extension gains also achieved greater flexion gains. Individual patient trajectories for extension and flexion are depicted in **Figure 3**, visually confirming the superior improvements in the minimally invasive group.

### *Correlation between ROM improvements and functional improvements*

Spearman correlation analysis (**Figure 4**) revealed strong associations between ROM im-

provements and functional gains. Improvement in extension was strongly negatively correlated with improvement in daily activities ( $\rho = -0.75$ ) and moderately with motor function ( $\rho = -0.53$ ), meaning that greater reduction in extension deficit was associated with better functional recovery. Improvement in flexion showed strong positive correlations with daily activities ( $\rho = 0.73$ ) and motor function ( $\rho = 0.51$ ). Pain improvement was moderately correlated with both extension ( $\rho = -0.24$ ) and flexion ( $\rho = 0.24$ )

## Traumatic elbow stiffness & release surgery



**Figure 4.** Correlation between ROM and MEPS improvements. Abbreviation: ROM, Range of Motion; MEPS, Mayo Elbow Performance Score.

gains. These findings confirm that restoration of elbow motion directly translates into better functional outcomes.

### Functional outcomes and subgroup analysis

All MEPS subscale scores improved significantly within each group postoperatively ( $P < 0.001$ ), except stability which remained unchanged (**Table 4**). The minimally invasive group exhibited significantly greater improvements in motor function ( $7.18 \pm 1.63$  vs.  $5.18 \pm 1.45$ ,  $P < 0.001$ ; Cohen's  $d = 1.29$ , 95% CI 0.90 to 1.69), daily activities ( $14.33 \pm 1.11$  vs.  $10.09 \pm 1.31$ ,  $P < 0.001$ ; Cohen's  $d = 3.49$ , 95% CI 2.92 to 4.06), and pain ( $10.40 \pm 2.76$  vs.  $9.07 \pm 2.80$ ,  $P = 0.010$ ; Cohen's  $d = 0.48$ , 95% CI 0.11 to 0.84). Total MEPS score was also significantly higher in the minimally invasive group ( $93.74 \pm 5.09$  vs.  $84.80 \pm 5.30$ ,  $P < 0.001$ ; Cohen's  $d =$

$1.72$ , 95% CI 1.30 to 2.14) (**Table 5**). SF-36 physical and mental health scores were both superior in the minimally invasive group (physical:  $77.55 \pm 7.58$  vs.  $68.83 \pm 9.46$ ,  $P < 0.001$ ; mental:  $81.64 \pm 8.81$  vs.  $72.78 \pm 8.59$ ,  $P < 0.001$ ), with large effect sizes (Cohen's  $d = 1.02$  for both) (**Table 5**).

The radar chart (**Figure 5**) visually summarizes the comprehensive functional advantage of minimally invasive surgery, showing larger improvements in all domains except stability. Correlation analysis of the final scores (**Figure 6**) revealed a moderate positive correlation between total MEPS and SF-36 physical health ( $r = 0.336$ ), while the correlation with mental health was weaker ( $r = 0.263$ ), suggesting partial independence of these dimensions.

Subgroup analysis (**Figure 7**) demonstrated that the superiority of minimally invasive sur-

## Traumatic elbow stiffness & release surgery

**Table 4.** Comparison of MEPS subscale scores between the two groups

Item	Parameter	Observation group (n = 60)	Control group (n = 60)	t/U	P-value
Motor Function	Pre-op	11.04 ± 2.33	11.17 ± 2.42		
	Post-op	18.22 ± 2.97	16.35 ± 2.59		
	Improvement	7.18 ± 1.63*	5.18 ± 1.45*	7.081	<0.001
Daily Activities	Pre-op	10.24 ± 1.38	10.03 ± 1.44		
	Post-op	24.57 ± 1.72	20.12 ± 1.89		
	Improvement	14.33 ± 1.11*	10.09 ± 1.31*	3578.000	<0.001
Pain	Pre-op	31.05 ± 2.62	29.76 ± 2.61		
	Post-op	41.44 ± 3.30	38.84 ± 4.02		
	Improvement	10.40 ± 2.76*	9.07 ± 2.80*	2.610	0.010
Stability	Pre-op	9.70 ± 0.34	9.71 ± 0.43		
	Post-op	9.50 ± 0.00	9.50 ± 0.00		
	Improvement	-0.20 ± 0.34*	-0.21 ± 0.43*	0.250	0.803

Note: Data are presented as mean ± standard deviation. Asterisks (\*) indicate statistically significant within-group improvement from preoperative to postoperative values ( $P < 0.001$  for all comparisons). Between-group comparisons for motor function, pain, and stability were performed using independent-samples t-tests; Daily activities were analyzed using the Mann-Whitney U test due to non-normal distribution or ordinal nature. Exact test statistics and  $p$  values are reported. Abbreviation: MEPS, Mayo Elbow Performance Score.

**Table 5.** Summary of functional scores and between-group comparisons

Outcome measure	Observation group (n = 60)	Control group (n = 60)	t	P-value
MEPS Total	93.74 ± 5.09	84.80 ± 5.30	9.416	<0.001
SF-36 Physical	77.55 ± 7.58	68.83 ± 9.46	5.571	<0.001
SF-36 Mental	81.64 ± 8.81	72.78 ± 8.59	5.577	<0.001

Note: Abbreviation: MEPS, Mayo Elbow Performance Score; SF-36, Short Form-36 Health Survey.

gery in terms of MEPS total score was consistent across all predefined subgroups (gender, age, presence of HO, ligament contracture, and heterotopic ossification). All mean differences favored the minimally invasive group, and none of the 95% confidence intervals crossed zero, indicating robust findings. The cumulative distribution of MEPS total scores (**Figure 8**) further confirmed the overall shift toward higher scores in the minimally invasive group.

### Multivariable regression analysis

Multivariable linear regression analysis (**Table 6**) confirmed that surgical approach was an independent predictor of postoperative MEPS total score. After adjusting for age, sex, disease duration, affected side, concurrent HO, and all five etiological factors, the open release group had a significantly lower MEPS total score compared to the minimally invasive group ( $\beta = -9.169$ , 95% CI: -11.153 to -7.185,  $P < 0.001$ ). None of the other covariates, including demographic characteristics or etiological factors, showed statistically significant associations with MEPS total score (all  $P > 0.05$ ), with capsu-

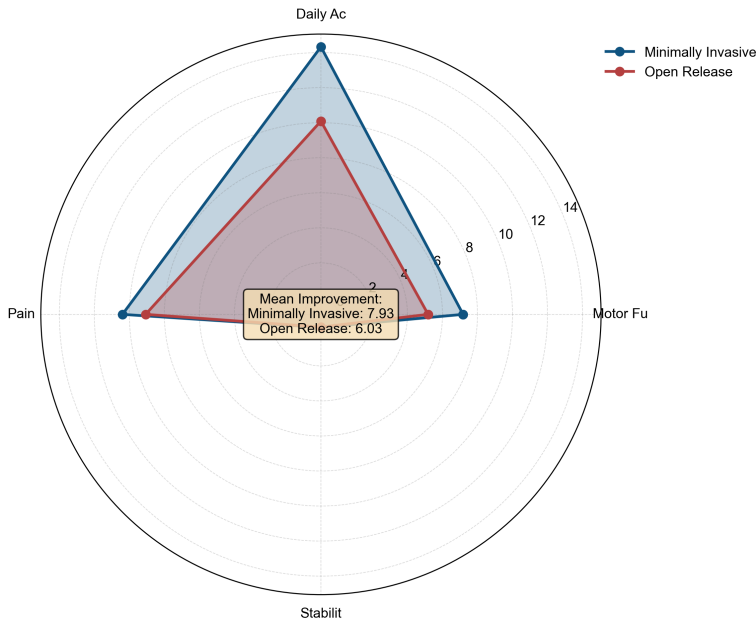
lar fibrosis approaching but not reaching significance ( $P = 0.053$ ).

Multivariable logistic regression analysis (**Table 7**) further demonstrated that surgical approach independently predicted good clinical outcome. Patients undergoing open release had significantly lower odds of achieving a good outcome (excellent or effective) compared to those receiving minimally invasive surgery (OR = 0.176, 95% CI: 0.037-0.850,  $P = 0.031$ ). Again, none of the other variables were significantly associated with the outcome (all  $P > 0.05$ ). The variable ligamentous contracture was excluded from the final model due to near-perfect separation, but its inclusion did not alter the significance of the remaining covariates. These regression results corroborate that the observed advantages of minimally invasive surgery are independent of baseline patient characteristics and etiological heterogeneity.

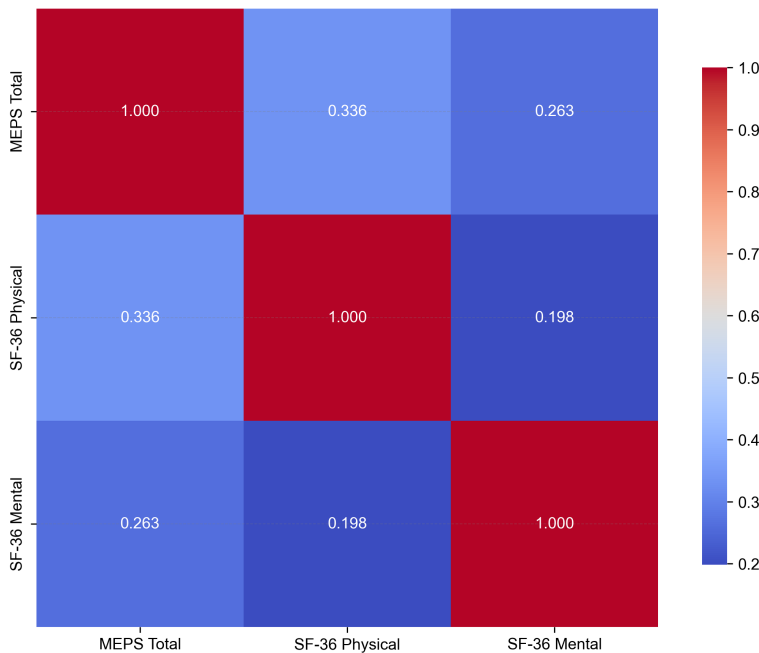
### Discussion

This study, through a retrospective analysis of 120 patients with traumatic elbow stiffness,

## Traumatic elbow stiffness & release surgery



**Figure 5.** Radar chart of functional improvements.



**Figure 6.** Functional score correlation heatmap.

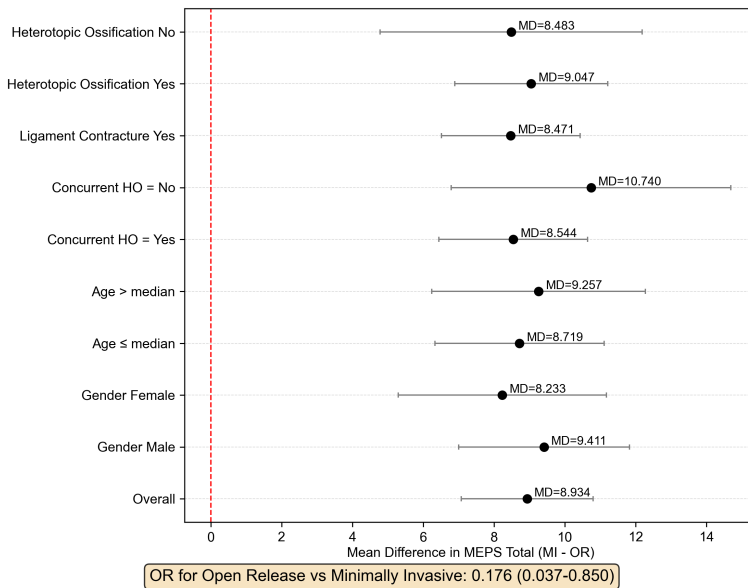
systematically elaborated on the multi-etiological composition of this disease and compared the clinical efficacy of minimally invasive versus open release surgery. The results confirm that ligamentous contracture and heterotopic ossification are the core pathological factors leading to elbow stiffness, and minimally invasive release surgery demonstrates significant advan-

tages in functional recovery, improvement of range of motion, and enhancement of patient quality of life.

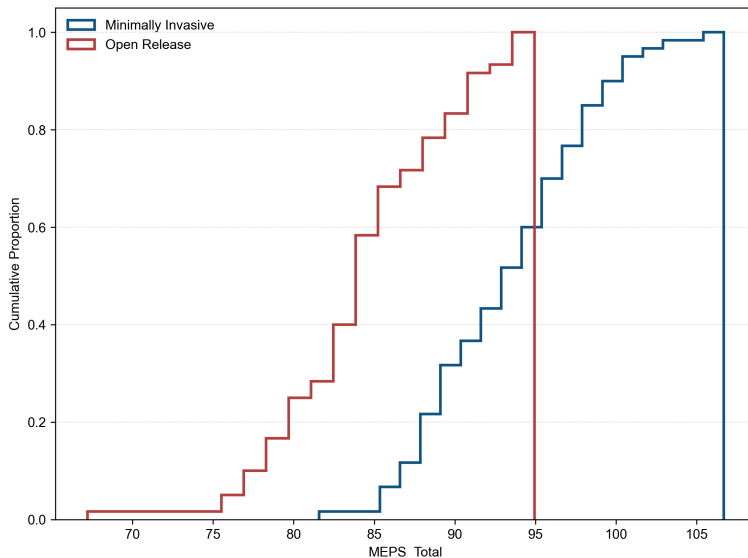
Our findings indicate that ligamentous contracture (particularly the posterior bundle of the ulnar collateral ligament) and heterotopic ossification are the primary pathogenic factors in post-traumatic elbow stiffness, with incidence rates of 91.7% and 80.0%, respectively. This result is consistent with several recent studies [20-22]. As the key stabilizing structure during elbow flexion, the posterior bundle of the ulnar collateral ligament is prone to fibrosis and contracture after trauma, creating a “bowstring” effect during flexion that becomes a critical mechanism restricting joint movement [10, 23, 24]. Heterotopic ossification refers to abnormal bone formation within soft tissues. Its occurrence is related to the severity of trauma, surgical intervention, and individual susceptibility [25, 26]. The resulting mechanical block has a particularly significant impact on joint function. Furthermore, capsular fibrosis (63.3%), soft tissue adhesions (55.8%), and osteophyte formation (50.0%) are also non-negligible synergistic factors. These pathological changes are intertwined, collectively forming a complex network of joint stiffness. This highlights the need for comprehensive clinical assessment and targeted intervention.

The results of this study show that the minimally invasive group was significantly superior to the open group in terms of total effective rate (95.0% vs. 83.3%), improvement in postoperative flexion-extension range of motion (improvement in extension: 34.93° vs. 25.41°; improvement in flexion: 42.23° vs. 22.13°), as well as MEPS and SF-36 scores. These advantages

## Traumatic elbow stiffness & release surgery



**Figure 7.** Subgroup analysis (MEPS Total Difference). Abbreviation: MEPS, Mayo Elbow Performance Score.



**Figure 8.** Cumulative distribution of MEPS total. Abbreviation: MEPS, Mayo Elbow Performance Score.

may stem from the following mechanisms: First, minimally invasive surgery, utilizing arthroscopic or mini-open portals, enables precise identification and limited release of pathological tissues. While effectively removing mechanical blocks, it maximizes the preservation of normal soft tissues and joint stabilizing structures [27]. In contrast, although open surgery provides adequate exposure, extensive soft tissue dissection may disrupt local blood supply

and increase the risk of post-operative adhesions and inflammatory reactions. Secondly, the smaller trauma and milder postoperative pain associated with minimally invasive surgery allow patients to initiate systematic rehabilitation training earlier. Early active movement helps maintain the range of motion, promotes synovial fluid circulation, and delays muscle atrophy, thereby accelerating functional remodeling [28, 29]. In this study, the more significant improvement in scores for motor function and activities of daily living in the minimally invasive group corroborates the importance of early rehabilitation. Notably, both groups showed comparable outcomes regarding joint stability and pain relief. This indicates that as long as key stabilizing structures (such as the anterior bundle of the medial collateral ligament and the ulnar nerve) are carefully preserved during surgery, both approaches can achieve good static stability and symptom resolution. The advantages of minimally invasive surgery are particularly evident in the recovery of flexion-extension function. This may be related to its more refined management of capsular and ligamentous contractures, resulting in reduced iatrogenic injury. Multivariable regression analysis further confirmed the independent role of surgical approach. After adjusting for age, sex, disease duration, and all etiological factors, minimally invasive surgery remained a significant predictor of higher MEPS total score ( $\beta = -9.17, P < 0.001$ ) and good clinical outcome (OR = 0.18,  $P = 0.031$ ). These findings underscore that the observed benefits are not confounded by baseline imbalances or etiological heterogeneity, thereby reinforcing the robustness of our conclusions.

## Traumatic elbow stiffness & release surgery

**Table 6.** Multivariable linear regression analysis for MEPS total score

Variable	Coefficient	Std. Error	t	P-value	95% CI
Intercept	97.405	7.096	13.726	<0.001	83.339, 111.471
Group (Open Release)	-9.169	1.001	-9.159	<0.001	-11.153, -7.185
Age (years)	-0.012	0.139	-0.090	0.929	-0.288, 0.263
Disease duration (months)	-0.239	0.237	-1.006	0.316	-0.709, 0.232
Gender (Male)	0.670	1.027	0.652	0.516	-1.366, 2.706
Affected side (Right)	0.096	0.995	0.097	0.923	-1.876, 2.069
Concurrent HO (Yes)	-0.295	1.310	-0.225	0.822	-2.891, 2.301
Ligamentous contracture	0.515	1.778	0.290	0.772	-3.008, 4.039
Heterotopic ossification	-0.346	1.237	-0.279	0.780	-2.797, 2.106
Capsular fibrosis	-2.055	1.050	-1.956	0.053	-4.137, 0.027
Osteophyte formation	-0.177	0.986	-0.179	0.858	-2.131, 1.777
Soft tissue adhesion	0.149	0.996	0.150	0.881	-1.825, 2.124

Note: Reference categories: Group (Minimally invasive), Gender (Female), Affected side (Left), Concurrent HO (No). All etiological factors are dichotomous (presence vs. absence). CI = confidence interval. Abbreviation: MEPS, Mayo Elbow Performance Score; CI, Confidence Interval; HO, Heterotopic Ossification.

**Table 7.** Multivariable logistic regression analysis for good clinical outcome

Variable	Coefficient	OR (95% CI)	P-value
Group_Open	-1.735	0.176 (0.037-0.850)	0.031
Age	0.112	1.119 (0.932-1.343)	0.227
Disease_Duration_Months	0.022	1.022 (0.776-1.346)	0.878
Gender_Male	0.983	2.673 (0.650-10.988)	0.173
Side_Right	0.214	1.238 (0.324-4.725)	0.755
Concurrent_HO	-1.424	0.241 (0.022-2.594)	0.240
Heterotopic_Ossification	-0.791	0.453 (0.079-2.587)	0.373
Capsular_Fibrosis	-0.481	0.618 (0.157-2.441)	0.492
Osteophyte_Formation	-0.140	0.870 (0.231-3.277)	0.837
Soft_Tissue_Adhesion	0.810	2.249 (0.593-8.534)	0.234

Note: The intercept term is omitted as it has no clinical interpretation. The variable Ligament\_Contracture was excluded due to model convergence issues (near-perfect separation); its inclusion did not alter the significance of other covariates and was not associated with the outcome ( $P > 0.05$ ). All other variables were entered simultaneously. Abbreviation: OR, Odds Ratio; CI, Confidence Interval; HO, Heterotopic Ossification.

The magnitude of functional gain observed in our minimally invasive cohort aligns favorably with contemporary series employing arthroscopic or mini-open techniques. Specifically, our reported mean flexion improvement of 42.2° is consistent with the systematic review by Kodde et al. [30], which reported an average arc improvement of approximately 40° following arthroscopic release for post-traumatic stiffness. In contrast, the 22.1° flexion gain in our open release group, while clinically significant, falls slightly below the 25-30° improvements reported in historical open arthrolysis

cohorts [31]. We attribute this discrepancy not to technical failure of the open approach but rather to the more extensive soft-tissue dissection and subsequent reactive fibrosis that can delay early mobilization. This hypothesis is further substantiated by our SF-36 data, where the minimally invasive group demonstrated superior physical component scores, mirroring findings by Khorram et al. [32], who noted that earlier functional independence is a hallmark of less invasive procedures.

Regarding heterotopic ossification, the high prevalence (80.0%) in our series under-

scores the severe nature of the underlying trauma. Nevertheless, our results support the notion that the surgical approach - rather than the mere presence of HO - is the critical determinant of early outcome, provided that meticulous resection of the offending mechanical block is achieved. This is in line with the work of Sun et al. [33], who demonstrated that arthroscopic HO resection, when combined with prophylactic NSAID therapy, yields recurrence rates and functional outcomes equivalent to or better than open excision in selected cases.

Our findings carry several practical implications. First, preoperative assessment should comprehensively evaluate the composition of etiological factors through detailed physical examination and imaging modalities such as CT, with particular attention paid to ligaments and heterotopic ossification. Second, for cases primarily involving ligamentous contracture and localized heterotopic ossification, minimally invasive release surgery can be considered the preferred option due to its distinct advantages in functional recovery and early rehabilitation. Third, regardless of the surgical approach, postoperative systematic and standardized rehabilitation therapy is essential to consolidate the surgical outcomes.

This study also has several limitations. First, as a single-center retrospective study, the sample size is relatively limited which may limit generalizability, although the cohort size is comparable to recent studies in this field. Second, the follow-up period was 6 months postoperatively. For long-term outcomes such as recurrence of heterotopic ossification or joint degeneration, extended follow-up is required for further observation. Additionally, this study did not perform typing analysis on the volume or anatomical location of heterotopic ossification. Future research could further investigate the impact of different categories of heterotopic ossification on surgical selection and prognosis.

### Conclusion

In conclusion, traumatic elbow stiffness is the result of the combined action of multiple pathological factors, among which ligamentous contracture and heterotopic ossification are the core causes. Compared with traditional open surgery, minimally invasive release surgery demonstrates significant advantages in improving clinical efficacy, restoring joint mobility, and enhancing patient quality of life, embodying the integrated application of precise surgery and enhanced recovery concepts. This study supports the use of minimally invasive release surgery as a key surgical option for traumatic elbow stiffness. Future research should focus on establishing a more refined preoperative assessment system, conducting multicenter prospective controlled studies, and exploring the optimization of perioperative comprehensive management models to further

improve the overall diagnostic and therapeutic standards for this condition.

### Disclosure of conflict of interest

None.

**Address correspondence to:** Yadong Yu, Department of Hand Surgery, The Third Hospital of Hebei Medical University, No. 139 Ziqiang Road, Qiaoxi District, Shijiazhuang 050041, Hebei, China. Tel: +86-0311-88602008; E-mail: hbsy\_yuyadong@163.com

### References

- [1] Del Core MA and Koehler D. Elbow arthritis. *J Hand Surg Am* 2023; 48: 603-611.
- [2] Marinelli A, Graves BR, Bain GI and Pederzini L. Treatment of elbow instability: state of the art. *J ISAKOS* 2021; 6: 102-115.
- [3] Lee DR, Therrien E, Song BM, Camp CL, Krych AJ, Stuart MJ, Abdel MP and Levy BA. Arthrofibrosis nightmares: prevention and management strategies. *Sports Med Arthrosc Rev* 2022; 30: 29-41.
- [4] Siemensma MF, van der Windt AE, van Es EM, Colaris JW and Eygendaal D. Management of the stiff elbow: a literature review. *EFORT Open Rev* 2023; 8: 351-360.
- [5] Ohl X and Siboni R. Surgical treatment of terrible triad of the elbow. *Orthop Traumatol Surg Res* 2021; 107: 102784.
- [6] Fahs A, Waldron J, Afsari A and Best B. Management of elbow terrible triad injuries: a comprehensive review and update. *J Am Acad Orthop Surg* 2024; 32: e982-e995.
- [7] Yao L, Pang L, Zhang C, Yang S, Wang J, Li Y, Li T, Xiong Y, Li J and Tang X. Platelet-rich plasma for arthroscopic rotator cuff repair: a 3-arm randomized controlled trial. *Am J Sports Med* 2024; 52: 3495-3504.
- [8] Sajan A, Epelboym Y, Martínez AF, Little M, Taliaie R and Isaacson A. Transarterial embolization for musculoskeletal pain management: AJR expert panel narrative review. *AJR Am J Roentgenol* 2025; 224: e2431626.
- [9] Kim HM, Morrey ME, Steinmann S and Barco R. Open and arthroscopic elbow contracture release: tips and pearls. *Instr Course Lect* 2024; 73: 625-637.
- [10] Sos C, Petit A, Brunet J, Rabarin F, Saint Cast Y, Raimbeau G and Bigorre N. Comparison of results of arthroscopic arthrolysis between traumatic and degenerative elbow stiffness. *Orthop Traumatol Surg Res* 2023; 109: 103436.
- [11] Raux S and Madelaine A. Sequelae of childhood elbow fracture. *Orthop Traumatol Surg Res* 2023; 109: 103454.

## Traumatic elbow stiffness & release surgery

- [12] Beck CM, Gluck MJ, Zhang Y, McGough JD, Reizner W, Rubin TA and Hausman MR. Outcomes of arthroscopic elbow contracture release: improvement for severe prosupination and flexion contracture. *Arthroscopy* 2022; 38: 315-322.
- [13] Dott C, Chin K and Compson J. Inflammatory arthritis and the elbow surgeon. *J Clin Orthop Trauma* 2021; 20: 101492.
- [14] Giddins G. Discussions about obstetric brachial plexus injuries. *Hand Clin* 2022; 38: 329-335.
- [15] Pucher CJ, Leschinger T, Ott N, Müller LP and Hackl M. Technical modifications to elbow interposition arthroplasty. *Oper Orthop Traumatol* 2024; 36: 167-179.
- [16] Wang X, Liu Q, Tan J, Wu J, Yang H, Xiong F, Ying Q and Mi J. Optimizing continuous passive motion duration following arthroscopic release of elbow contracture: a retrospective study. *BMC Musculoskelet Disord* 2024; 25: 965.
- [17] Ben H, Kholinne E, Zeng CH, Alsaqri H, Lee JB, So SP, Koh KH and Jeon IH. Prevalence, timing, locational distribution, and risk factors for heterotopic ossification after elbow arthroscopy. *Am J Sports Med* 2023; 51: 3401-3408.
- [18] Scholp AJ, Jensen JA, Fowler TP, Petersen E, Fredericks D, Salem AK, Seol D, Coleman M, Lake SP, Martin JA and Sander EA. Capsule release surgery temporarily reduces contracture in a rat elbow model of arthrofibrosis. *J Orthop Res* 2025; 43: 23-36.
- [19] Qi Wang, Jiang Peng, Aiyuan Wang, Wenjing Xu, Jinshu Tang and Jinshu Tang. Treatment and rehabilitation of post-traumatic elbow stiffness with heterotopic ossification. *J Plast Surg Hand Surg* 2024; 59: 18-23.
- [20] Romero B, Smith W, Lopez RD, Stavrakis A, Photopoulos C and Horneff JG 3rd. Comparison of total elbow arthroplasty complications between various surgical indications at 90-day and 1-year follow-up in 1600 elbows. *J Shoulder Elbow Surg* 2023; 32: S112-S117.
- [21] Sanchez-Sotelo J. Arthroscopic management of elbow stiffness. *J Exp Orthop* 2021; 8: 97.
- [22] Cai G, Song L, Chen G, Yuan S, Cai L, Ning X, Wang J and Jiang W. Short-term effectiveness of a modified osteotomy for total elbow joint replacement in patients of hemophilic elbow arthritis with severe flexion contracture deformity: a three-cases series report. *Orthop Surg* 2022; 14: 2741-2749.
- [23] Hockmann JP, Rausch V, Leschinger T and Müller LP. Radial head arthroplasty: pearls and pitfalls. *Z Orthop Unfall* 2025; 163: 94-107.
- [24] Ahmed AF, Alzobi OZ, Hantouly AT, Toubasi A, Farsakoury R, Alkhelaifi K and Zikria B. Complications of elbow arthroscopic surgery: a systematic review and meta-analysis. *Orthop J Sports Med* 2022; 10: 23259671221137863.
- [25] Xue Z, Guo W, Xu B, Ashaljiang M and Cao L. Effectiveness of total elbow arthroplasty via olecranon osteotomy approach. *Zhongguo Xiu Fu Chong Jian Wai Ke Za Zhi* 2022; 36: 1363-1368.
- [26] Dang Y, Du X, Ou X, Zheng Q and Xie F. Advances in diagnosis and treatment of Madelung's deformity. *Am J Transl Res* 2023; 15: 4416-4424.
- [27] Ma H, Xuan L, Zhong Z, Zhang Z, Zhu Z, Qiu Y and Li F. Dual mediolateral mini-open technique for the release of elbow contracture. *J Orthop Surg Res* 2025; 20: 905.
- [28] Goyal N, Luchetti TJ, Blank AT and Cohen MS. Atraumatic, progressive, and painful elbow contracture from a ganglion cyst. *J Hand Surg Am* 2021; 46: 345.e341-345.e343.
- [29] Pal CP, Mittal V, Dinkar KS, Kapoor R and Gupta M. Neglected posterior dislocation of elbow: a review. *J Clin Orthop Trauma* 2021; 18: 100-104.
- [30] Kodde IF, van Rijn J, van den Bekerom MP and Eygendaal D. Surgical treatment of post-traumatic elbow stiffness: a systematic review. *J Shoulder Elbow Surg* 2013; 22: 574-580.
- [31] Mansat P and Morrey BF. The column procedure: a limited lateral approach for extrinsic contracture of the elbow. *J Bone Joint Surg Am* 1998; 80: 1603-1615.
- [32] Khorram R, Ghayyad K, Vafadar R, Borazjani R, Nezameslami A, Huffman GR and Kachooei AR. Surgical treatments of post-traumatic elbow stiffness: a systematic review and meta-analysis. *J Shoulder Elbow Surg* 2026; 35: 387-407.
- [33] Sun Z, Li J, Luo G, Wang F, Hu Y and Fan C. What constitutes a clinically important change in Mayo Elbow Performance Index and range of movement after open elbow arthrolysis? *Bone Joint J* 2021; 103-B: 366-372.