

## Original Article

# Comparative study on rotational stability of toric intraocular lenses in cataract patients with low astigmatism: vertical versus horizontal implantation

Hairong Che<sup>1</sup>, Xinbo Jiao<sup>2</sup>, Yun Wang<sup>3</sup>, Xiaohui Qi<sup>4</sup>

<sup>1</sup>Department of Ophthalmology, Zhangye Second People's Hospital, Linsong West Street, Ganzhou District, Zhangye 734000, Gansu, China; <sup>2</sup>Department of Ophthalmology, Gansu Provincial Second People's Hospital, No. 1 Hezheng West Street, Chengguan District, Lanzhou 730030, Gansu, China; <sup>3</sup>Department of Pharmacy and Medical Devices, Zhangye Second People's Hospital, Linsong West Street, Ganzhou District, Zhangye 734000, Gansu, China; <sup>4</sup>Department of Ophthalmology, Dingxi People's Hospital, No. 22, Anding Road, Anding District, Dingxi 743000, Gansu, China

Received March 3, 2026; Accepted May 12, 2026; Epub June 15, 2026; Published June 30, 2026

**Abstract:** Objective: To compare the effects of horizontal versus vertical in-the-bag implantation of toric intraocular lenses (IOLs) on postoperative rotational stability, refractive outcome, and vision-related quality of life in cataract patients with low regular astigmatism, and to identify risk factors for postoperative rotational instability. Methods: This retrospective study included 370 eyes of 370 patients with low regular astigmatism who underwent phacoemulsification with toric IOL implantation. Patients were divided into horizontal implantation (n = 189) and vertical implantation (n = 181) groups according to intraoperative IOL orientation. Follow-up assessments were conducted at 1 week, 1 month, and 3 months postoperatively. The primary outcome was rotational instability at 3 months, defined as a rotation angle  $\geq 5^\circ$ . Secondary outcomes included rotation angle over time, uncorrected visual acuity (UCVA), best-corrected visual acuity (BCVA), spherical equivalent (SE), residual astigmatism, and National Eye Institute Visual Function Questionnaire-25 (NEI VFQ-25) scores. Longitudinal changes were analyzed using a linear mixed-effects model (LMM), and logistic regression was used to identify risk factors. Results: Baseline and intraoperative data were comparable between groups. The LMM revealed significant effects of time, group, and their interaction on rotation angle (all  $P < 0.001$ ). Rotation angles were significantly lower in the vertical implantation group than in the horizontal implantation group at all follow-up time points (all  $P < 0.001$ ). At 3 months, rotational instability was lower in the vertical group than in the horizontal group (5.5% vs. 16.9%,  $P < 0.001$ ). The vertical group demonstrated better UCVA, BCVA, SE, and lower residual astigmatism (all  $P \leq 0.001$ ), along with higher NEI VFQ-25 scores across multiple domains. Vertical implantation was independently protective (OR = 0.194, 95% CI: 0.077-0.444,  $P < 0.001$ ), whereas longer axial length, shallower anterior chamber depth, and larger capsular bag diameter were identified as risk factors. Complication rates were similar between groups. Conclusion: Vertical in-the-bag implantation of toric IOLs provided superior rotational stability, refractive outcomes, visual recovery, and vision-related quality of life compared to horizontal implantation in cataract patients with low regular astigmatism.

**Keywords:** Toric intraocular lens, implantation orientation, rotational stability, linear mixed-effects model

## Introduction

Due to the growing popularity of refractive cataract surgery, the goal is now not only the removal of cataracts but also the correction of vision. A significant number of patients expect improved visual acuity and comfort. Corneal astigmatism is very common in cataract patients. Residual astigmatism can affect both distance and near vision and cause dissatisfac-

tion if left uncorrected at the time of surgery. As a result, managing astigmatism during cataract surgery has become the norm [1, 2]. Surgeons currently have the option of corneal relaxing incisions, such as limbal relaxing incisions (LRI), astigmatic keratotomy (AK), or femtosecond laser-assisted arcuate keratotomy. Another option is toric intraocular lens (IOL) implantation. Compared to corneal incision-based options, toric IOLs offer more predict-

able correction and better control of residual astigmatism. In patients with low to moderate regular astigmatism, toric IOLs result in residual astigmatism of 0.50D or less in a greater proportion of cases [2]. Therefore, personalizing surgical planning is recommended to achieve the best outcome. European guidelines [3] state that corneal astigmatism should be actively managed during cataract surgery, supported by accurate measurements to enhance quality of life (QOL).

The surgical benefit of toric IOLs depends heavily on postoperative axis stability. Previous studies have shown that the efficacy of astigmatic correction decreases by approximately 3.3% for every 1° of deviation from the intended axis [4]. At a 10° rotation, approximately one-third of the correcting effect is lost. Larger rotations can almost completely nullify the correction [5]. Consequently, postoperative rotation and rotational instability remain crucial limitations of toric IOLs. Real-world data indicate that the overall rate of surgical repositioning is low, but clinically significant rotation and misalignment still occur, leading to fluctuating vision, higher residual astigmatism, the need for secondary surgical procedures, and increased healthcare costs and patient distress [6, 7]. The rotational stability of toric IOLs varies by brand and design, and these differences are magnified in certain populations, such as those with long axial lengths [8, 9].

Recent evidence suggests that rotational instability is not attributable to a single cause. It is not only due to changes in corneal curvature but also relates to ocular biometrics, capsular bag-lens interface biomechanics, and surgical factors. Increased axial length, a larger capsular bag, variations in anterior chamber indices, changes in lens and capsular bag morphology, and the postoperative course of capsular contraction and fibrosis may all affect the contact area and frictional forces between the IOL and the capsular bag, thereby influencing early positioning and long-term stability [5, 10]. Some investigators have proposed that delayed formation of the capsular bend may explain the higher early rotation rates observed in highly myopic or long-axial-length eyes. Other studies have discussed rotational resistance in relation to capsular bag diameter and IOL structure (including haptic configuration, material, and the degree of match with the capsular bag)

[10]. Finite element and *in vitro* biomechanical simulation studies have further shown that toric IOLs with different haptic designs exhibit markedly different ranges of rotation depending on capsular bag diameter, underscoring the importance of structural matching for rotational stability [11].

In clinical practice, implantation orientation (axis direction), in addition to IOL model selection and the better-known risk factors, may represent an undervalued and modifiable factor. In this study, we investigated early postoperative IOL rotation in a retrospective cohort comparing horizontal versus vertical placement of a toric IOL under a similar surgical protocol. Unlike previous studies, we focused on a commonly used IOL model. Our primary aims were: (1) to compare the effects of vertical versus horizontal toric IOL implantation on early postoperative rotational stability; (2) to determine whether implantation orientation affects the proportion of eyes exceeding a clinically relevant rotation threshold (5°); and (3) to evaluate refractive outcomes and vision-related quality of life. Additionally, we sought to identify ocular biometric risk factors for rotational instability. Given the lack of high-quality evidence and inconsistent findings in existing studies [5, 8, 11], this study was designed to systematically compare the postoperative rotational dynamics of vertical versus horizontal toric IOL implantation in a real-world cohort and to identify factors associated with rotational instability using ocular biometric data. The aim is to provide actionable evidence to assist intraoperative decision-making and personalized risk assessment prior to toric IOL implantation in patients with low astigmatism.

### Materials and methods

#### *Study design and participants*

Patients who underwent phacoemulsification combined with in-the-bag toric IOL implantation at Zhangye Second People's Hospital and Gansu Provincial Second People's Hospital between January 2021 and June 2024 were identified from medical records. This retrospective study was approved by the Ethics Committee of Zhangye Second People's Hospital and adhered to the tenets of the Declaration of Helsinki. The requirement for informed consent was waived due to the retrospective nature of

## Effect of implantation orientation on toric IOL rotational stability

the study and the use of anonymized patient data.

The study included patients aged > 50 years with a clinical diagnosis of age-related cataract and preoperative regular corneal astigmatism between 0.75 D and 2.50 D. All eyes received the same model of toric IOL, namely the AcrySof® IQ Toric IOL (Alcon Laboratories, Inc., Fort Worth, TX, USA), a single-piece hydrophobic acrylic lens with an open-loop haptic design. All patients completed follow-up assessments at 1 week, 1 month, and 3 months postoperatively.

Patients were excluded if they met any of the following criteria: (1) Irregular corneal astigmatism or keratoconus; (2) A history of any corneal or intraocular surgery; (3) Zonular weakness, lens subluxation, or pseudoexfoliation syndrome; (4) Intraoperative posterior capsular rupture, zonular dialysis, or vitreous loss; (5) Ocular comorbidities that could affect visual outcomes, including glaucoma with visual field loss, diabetic retinopathy, macular degeneration, or uveitis; (6) A postoperative incident requiring further surgical or medical intervention unrelated to IOL rotation.

After applying all inclusion and exclusion criteria, 370 eyes from 370 patients were included in the final analysis. Based on intraoperative IOL orientation, patients were allocated to two groups. In the horizontal implantation group (n = 189), the toric IOL was initially placed with its cylinder axis oriented horizontally before being rotated to the target meridian. In the vertical implantation group (n = 181), the IOL was initially placed with its axis oriented vertically before being aligned to the intended meridian.

### *Preoperative assessment*

All patients underwent a standardized preoperative assessment. Demographic and systemic information collected included age, sex, body mass index (BMI), place of residence (urban or rural), educational level, and Charlson Comorbidity Index (CCI). Optical biometry using the IOLMaster 700 (Carl Zeiss Meditec, Jena, Germany) was performed to measure ocular biometric indices, including axial length (AL), anterior chamber depth (ACD), lens thickness (LT), white-to-white distance (WTW), and the magnitude of corneal astigmatism. As part of

the preoperative workup, capsular bag diameter was measured using ultrasound biomicroscopy (UBM) or anterior segment optical coherence tomography (AS-OCT). The manufacturer's online planning platform was used to calculate toric IOL power and target axis, with the Barrett toric calculator used for cross-checking.

### *Surgical technique*

All surgeries were performed by two experienced surgeons following a standard protocol. Prior to surgery, corneal marking of the intended IOL axis was performed with the patient in an upright position using a slit lamp to minimize the cyclorotation effect. A 2.2 mm clear corneal incision was made either at the steep meridian or at the surgeon's preferred site. After administering topical and intracameral anesthetics, a continuous curvilinear capsulorhexis (CCC) of 5.0-5.5 mm was performed. Standard phacoemulsification involved hydrodissection, followed by phacoemulsification and irrigation/aspiration of cortical material. Intraoperative indices recorded included incision location, CCC diameter, cumulative dissipated energy (CDE), phacoemulsification time, total surgical duration, and whether a capsular tension ring (CTR) was placed.

The toric IOL was then implanted into the capsular bag. In the horizontal group, the IOL was loaded and delivered with its axis oriented horizontally and subsequently rotated to the desired meridian. In the vertical group, the IOL was delivered with its axis oriented vertically before being rotated to the target meridian. After careful removal of the ophthalmic viscosurgical device (OVD), the IOL axis was verified against the corneal reference marks and, when available, using intraoperative aberrometry or a digital overlay guidance system. At the end of the procedure, wound integrity was confirmed.

### *Postoperative follow-up and outcome measures*

Patients were assessed at 1 week, 1 month, and 3 months postoperatively. At each visit, toric IOL axis orientation was assessed using slit-lamp retroillumination photography. The rotation angle was independently measured by two experienced ophthalmologists who were masked to the implantation orientation. The average of the two measurements was used for

analysis, and discrepancies were resolved by consensus. The rotation angle was defined as the absolute angular difference between the observed and intended IOL axis positions.

Postoperative complications were systematically recorded at each follow-up visit. These included elevated intraocular pressure ( $\geq 25$  mmHg), transient corneal edema, anterior chamber inflammation ( $\geq$  grade 2 cells), posterior capsular opacification, IOL decentration ( $\geq 0.5$  mm), clinically significant cystoid macular edema, and the need for secondary intervention.

The primary outcome measure was the incidence of rotational instability at 3 months, defined as a rotation angle of  $\geq 5^\circ$ . Secondary outcome measures included: the rotation angle at each follow-up time point and its longitudinal change over time; the distribution of rotation grades at 3 months (grade 0:  $< 5^\circ$ ; grade 1:  $5^\circ$ - $9^\circ$ ; grade 2:  $\geq 10^\circ$ ); preoperative and 3-month postoperative uncorrected visual acuity (UCVA), best-corrected visual acuity (BCVA), spherical equivalent (SE), and residual astigmatism; and subscale scores of the National Eye Institute Visual Function Questionnaire-25 (NEI VFQ-25). The NEI VFQ-25 was administered preoperatively and at 3 months postoperatively to evaluate multi-domain vision-related quality of life.

### *Statistical analysis*

Continuous variables were expressed as mean  $\pm$  standard deviation (SD) or median (interquartile range [IQR]), as appropriate. Comparisons between the two groups were performed using the independent-samples t-test or Mann-Whitney U test, depending on data distribution. Categorical variables were presented as frequencies and percentages and were compared using the chi-square test or Fisher's exact test.

Longitudinal changes in rotation angle across the three follow-up visits were analyzed using a linear mixed-effects model (LMM) with time, group, and their interaction as fixed effects and a random intercept for each subject to account for within-subject correlation. Model assumptions were evaluated by inspecting residual diagnostics, including Q-Q plots for normality and residual-versus-fitted plots for homosce-

lasticity. The LMM included pairwise contrasts at each time point with estimated marginal means; Bonferroni correction was applied for multiple comparisons.

Univariate logistic regression was first used to test risk factors for rotational instability (rotation  $\geq 5^\circ$  at 3 months). Variables with a *P* value  $< 0.10$  in univariate analysis, together with clinically relevant variables, were entered into the multivariate logistic regression model. A stepwise selection procedure was applied to identify independent predictors. Multicollinearity was assessed using variance inflation factors (VIF). Receiver operating characteristic (ROC) curve analysis was used to determine the optimal cut-off values for continuous predictors. The cut-offs were then used to dichotomize the variables for inclusion in the model. Model discrimination was assessed using the area under the ROC curve (AUC), and calibration was evaluated using the Hosmer-Lemeshow goodness-of-fit test.

Subgroup analyses were performed by stratifying patients according to predefined cutoff values of axial length, anterior chamber depth, and capsular bag diameter. Interaction terms between implantation orientation and each variable were included in the multivariable logistic regression model to assess potential effect modification.

All statistical analyses were performed using R software (version 4.3.1) and SPSS (version 26.0). A two-sided *P* value  $< 0.05$  was considered significant.

## **Results**

### *Baseline characteristics*

A total of 370 eyes of 370 patients were analyzed, including 189 in the horizontal implantation group and 181 in the vertical implantation group. The mean age was  $67.8 \pm 7.4$  years in the horizontal group and  $66.9 \pm 7.1$  years in the vertical group (*P* = 0.243). The two groups did not differ significantly in sex distribution, body mass index (BMI), residential area, education level, or CCI (all *P*  $> 0.05$ ). No significant differences were found in preoperative ocular biometric indices between the two groups (AL, ACD, LT, WTW, capsular bag diameter and corneal astigmatism) (all *P*  $> 0.05$ , **Table 1**).

## Effect of implantation orientation on toric IOL rotational stability

**Table 1.** Comparison of baseline characteristics between the horizontal and vertical implantation groups

Variable	Total	Horizontal group (n = 189)	Vertical group (n = 181)	Statistic	P value
Age (years)				0.074	0.785
< 70	203 (54.86%)	105 (55.56%)	98 (54.14%)		
≥ 70	167 (45.14%)	84 (44.44%)	83 (45.86%)		
Sex				0.039	0.844
Male	190 (51.35%)	98 (51.85%)	92 (50.83%)		
Female	180 (48.65%)	91 (48.15%)	89 (49.17%)		
BMI				0.046	0.830
< 24 kg/m <sup>2</sup>	231 (62.43%)	119 (62.96%)	112 (61.88%)		
≥ 24 kg/m <sup>2</sup>	139 (37.57%)	70 (37.04%)	69 (38.12%)		
Residential area				0.151	0.697
Urban	257 (69.46%)	133 (70.37%)	124 (68.51%)		
Rural	113 (30.54%)	56 (29.63%)	57 (31.49%)		
Education level				0.210	0.647
≥ High school	215 (58.11%)	112 (59.26%)	103 (56.91%)		
< High school	155 (41.89%)	77 (40.74%)	78 (43.09%)		
CCI score				0.098	0.754
< 1	228 (61.62%)	115 (60.85%)	113 (62.43%)		
≥ 1	142 (38.38%)	74 (39.15%)	68 (37.57%)		
AL (mm)	23.84±1.24	23.85±1.31	23.82±1.17	0.301	0.763
ACD (mm)	3.11±0.33	3.11±0.34	3.10±0.31	0.200	0.842
LT (mm)	4.56±0.40	4.57±0.41	4.55±0.38	0.522	0.602
WTW (mm)	11.71±0.41	11.74±0.40	11.67±0.41	1.542	0.124
Capsular bag diameter (mm)	10.44±0.38	10.45±0.41	10.43±0.35	0.318	0.750
Corneal astigmatism (D)	0.97±0.28	0.96±0.30	0.98±0.26	-0.800	0.424

Note: AL, axial length; ACD, anterior chamber depth; LT, lens thickness; WTW, white-to-white distance; CCI, Charlson Comorbidity Index; BMI, body mass index.

### *Intraoperative variables*

Intraoperative variables were similar between the two groups. The distribution of incision sites did not differ significantly ( $P > 0.05$ ). No significant differences were observed in CCC diameter, CDE, phacoemulsification time, or the proportion of eyes receiving a CTR (all  $P > 0.05$ ). The operating time was longer in the vertical group, but the difference did not reach statistical significance ( $P = 0.059$ , **Table 2**).

### *Longitudinal changes in rotation angle*

The LMM revealed significant effects of time, group, and the time-by-group interaction on rotation angle (all  $P < 0.001$ ), indicating that the rotational trajectories over time differed between the two groups.

At 1 week postoperatively, the estimated marginal means of the rotation angle were  $2.906^\circ$

in the horizontal group and  $2.042^\circ$  in the vertical group, with a between-group difference of  $0.863^\circ$  ( $P < 0.001$ ). At 1 month, the difference widened, with the horizontal group showing an estimated marginal mean of  $3.940^\circ$  compared to  $2.355^\circ$  in the vertical group (difference:  $1.585^\circ$ ,  $P < 0.001$ ). At 3 months, the rotation angle was  $3.234^\circ$  in the horizontal group and  $2.654^\circ$  in the vertical group (difference:  $0.580^\circ$ ,  $P < 0.001$ ). The vertical implantation group exhibited less rotation at all time points. The between-group difference was largest at 1 month and partially converged by 3 months. Model diagnostics confirmed that the residuals were approximately normally distributed, and no significant heteroscedasticity was observed, supporting the validity of the model (**Table 3**).

### *Rotation grade distribution at 3 months*

There was a significant difference in the distribution of rotation grades between groups at

## Effect of implantation orientation on toric IOL rotational stability

**Table 2.** Comparison of intraoperative variables between the horizontal and vertical implantation groups

Variable	Total	Horizontal group (n = 189)	Vertical group (n = 181)	Statistic	P value
Incision location				0.124	0.940
Temporal	329 (88.92%)	167 (88.36%)	162 (89.50%)		
Superior	26 (7.03%)	14 (7.41%)	12 (6.63%)		
Other	15 (4.05%)	8 (4.23%)	7 (3.87%)		
CCC diameter (mm)	5.21±0.28	5.20±0.29	5.22±0.27	-0.458	0.648
CDE	8.09±3.49	7.97±3.81	8.22±3.13	-0.684	0.495
Phacoemulsification time (s)	55.75±20.18	55.65±20.28	55.86±20.12	-0.097	0.923
Surgical duration (min)	13.07±3.83	12.71±3.98	13.46±3.64	-1.894	0.059
CTR use				0.041	0.839
Yes	13 (3.51%)	7 (3.70%)	6 (3.31%)		
No	357 (96.49%)	182 (96.30%)	175 (96.69%)		

Note: CCC, continuous curvilinear capsulorhexis; CDE, cumulative dissipated energy; CTR, capsular tension ring.

**Table 3.** Longitudinal analysis of IOL rotation using a linear mixed-effects model (LMM)

Effect	F value	P value		
Time	25.908	< 0.001		
Group	161.32	< 0.001		
Time × Group	14.563	< 0.001		
Group	Week 1	Month 1	Month 3	
Horizontal	2.906±0.095 (2.718-3.093)	3.940±0.095 (3.753-4.128)	3.234±0.095 (3.047-3.421)	
Vertical	2.042±0.098 (1.851-2.234)	2.355±0.098 (2.164-2.547)	2.654±0.098 (2.463-2.845)	
Time point	Difference ± SE	t value	P value	
Week 1	0.863±0.136	6.327	< 0.001	
Month 1	1.585±0.136	11.62	< 0.001	
Month 3	0.580±0.136	4.254	< 0.001	

the 3-month follow-up visit ( $P < 0.001$ ). In the horizontal group, 142 eyes (75.1%) were classified as grade 0 (rotation  $< 5^\circ$ ), 32 eyes (16.9%) as grade 1 (rotation  $5^\circ$ - $9^\circ$ ), and 15 eyes (7.9%) as grade 2 (rotation  $\geq 10^\circ$ ). In the vertical group, 163 eyes (90.1%) were classified as grade 0, 14 eyes (7.7%) as grade 1, and 4 eyes (2.2%) as grade 2. The overall rate of clinically significant rotation (rotation  $\geq 5^\circ$ ) was 16.9% (32/189) in the horizontal group and 5.5% (10/181) in the vertical group ( $P < 0.001$ , **Figure 1**).

### Refractive outcomes

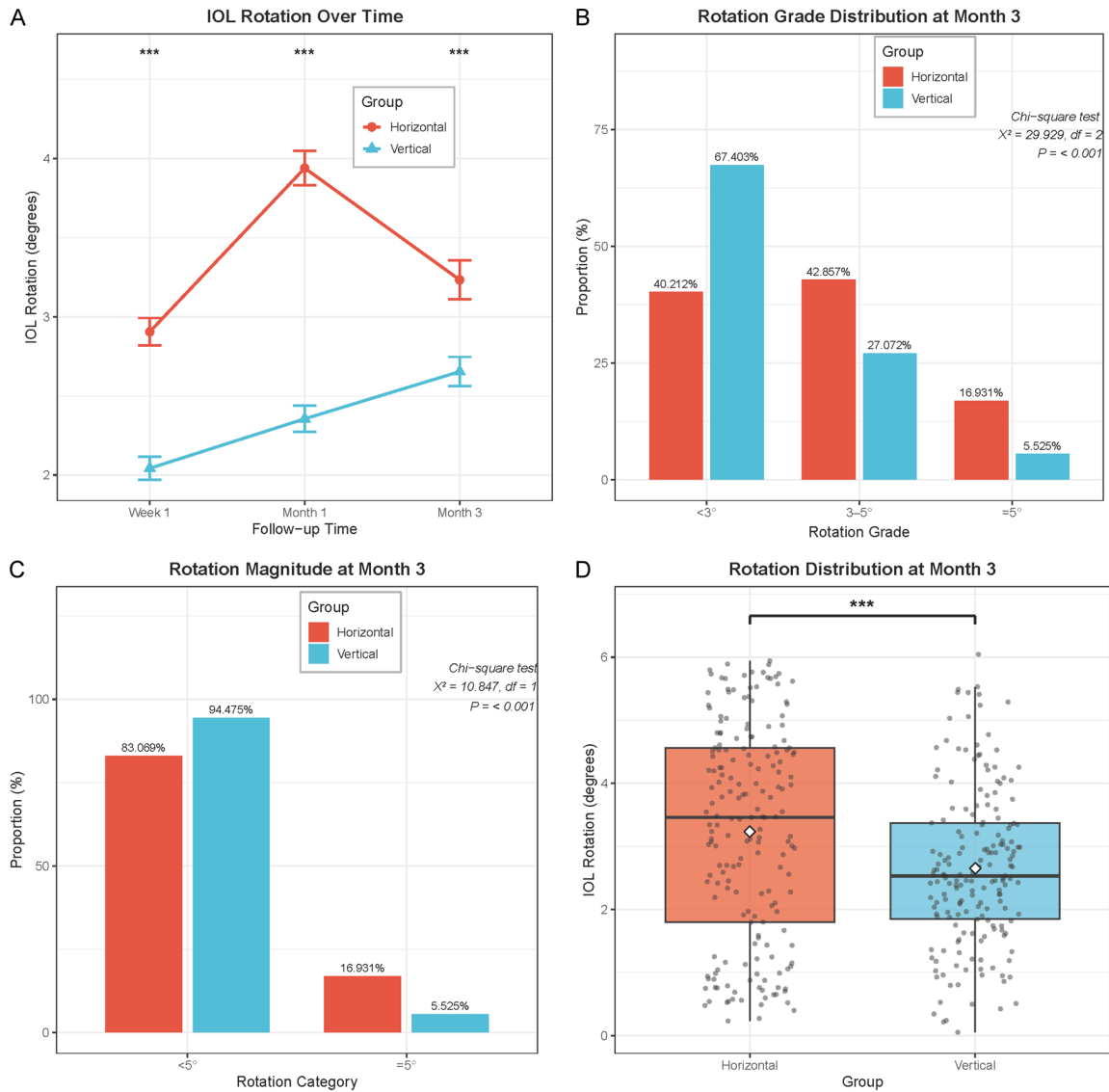
Preoperative UCVA, BCVA, SE, and residual astigmatism were similar between the two groups (all  $P > 0.05$ ). Three months postoperatively, the vertical implantation group showed significantly better UCVA and BCVA than the

horizontal group (both  $P < 0.001$ ). The SE in the vertical group was closer to the target refraction than that in the horizontal group ( $P = 0.001$ ), and residual astigmatism was significantly lower in the vertical group than in the horizontal group ( $P < 0.001$ ). These findings indicate that the enhanced rotational stability in the vertical group translated into improved refractive outcomes (**Figure 2**).

### Vision-related quality of life

The preoperative NEI VFQ-25 subscale scores were similar between the two groups across all domains (all  $P > 0.05$ ). At 3 months postoperatively, the vertical implantation group reported significantly higher scores for distance activities, near activities, light sensitivity and glare-related visual function, and social functioning (all  $P < 0.001$ ). The remaining subscale scores

## Effect of implantation orientation on toric IOL rotational stability



**Figure 1.** Longitudinal changes in intraocular lens rotation and rotation distribution at 3 months postoperatively between the two groups. A: Trends in IOL rotation angle over time at 1 week, 1 month, and 3 months postoperatively in the horizontal and vertical implantation groups. B: Distribution of IOL rotation grades (< 3°, 3°-5°, ≥ 5°) at 3 months postoperatively. C: Stratified distribution of IOL rotation magnitude (< 5° vs. ≥ 5°) at 3 months postoperatively. D: Distribution of IOL rotation angle as a continuous variable at 3 months postoperatively (box plot with overlaid scatter points). Note: IOL, intraocular lens; LMM, linear mixed-effects model; \*\*\*P < 0.001.

for general vision, ocular pain, and mental health also showed trends in favor of the vertical group, although none reached significance. These results suggest that the improved rotational stability associated with vertical implantation had a significant positive effect on daily visual function and quality of life. **Figure 3** present the detailed NEI VFQ-25 outcomes.

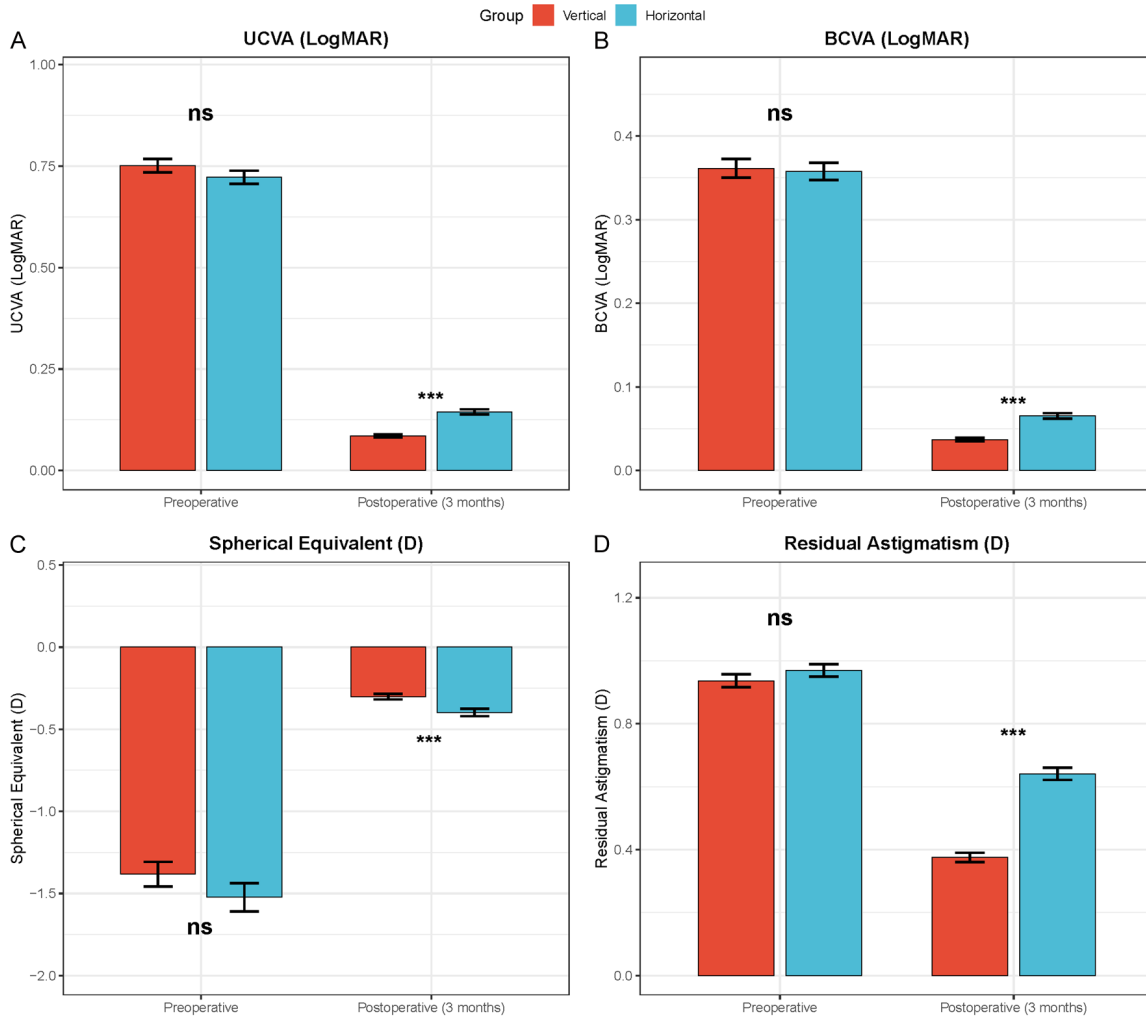
### Risk factors for rotational instability

Univariate logistic regression identified the following candidate predictors of rotational instability

at 3 months (rotation ≥ 5°): implantation orientation, AL, ACD, capsular bag diameter, LT, and CCC diameter (all P < 0.10). After multivariate logistic regression with stepwise selection, four independent predictors remained (**Table 4**).

Vertical implantation provided a substantial protective effect, with a significantly reduced risk of rotational instability compared with horizontal implantation (OR = 0.194, 95% CI: 0.077-0.444, P < 0.001). Three ocular biometric vari-

## Effect of implantation orientation on toric IOL rotational stability



**Figure 2.** Comparison of visual acuity and refractive indices between the two groups at baseline and 3 months postoperatively. A: UCVA (LogMAR) at baseline and 3 months. B: BCVA (LogMAR) at baseline and 3 months. C: SE at baseline and 3 months. D: Residual astigmatism at baseline and 3 months. Note: UCVA, uncorrected visual acuity; BCVA, best-corrected visual acuity; SE, spherical equivalent; LogMAR, logarithm of the minimum angle of resolution; D, diopters; ns  $P > 0.05$ ; \*\*\* $P < 0.001$ .

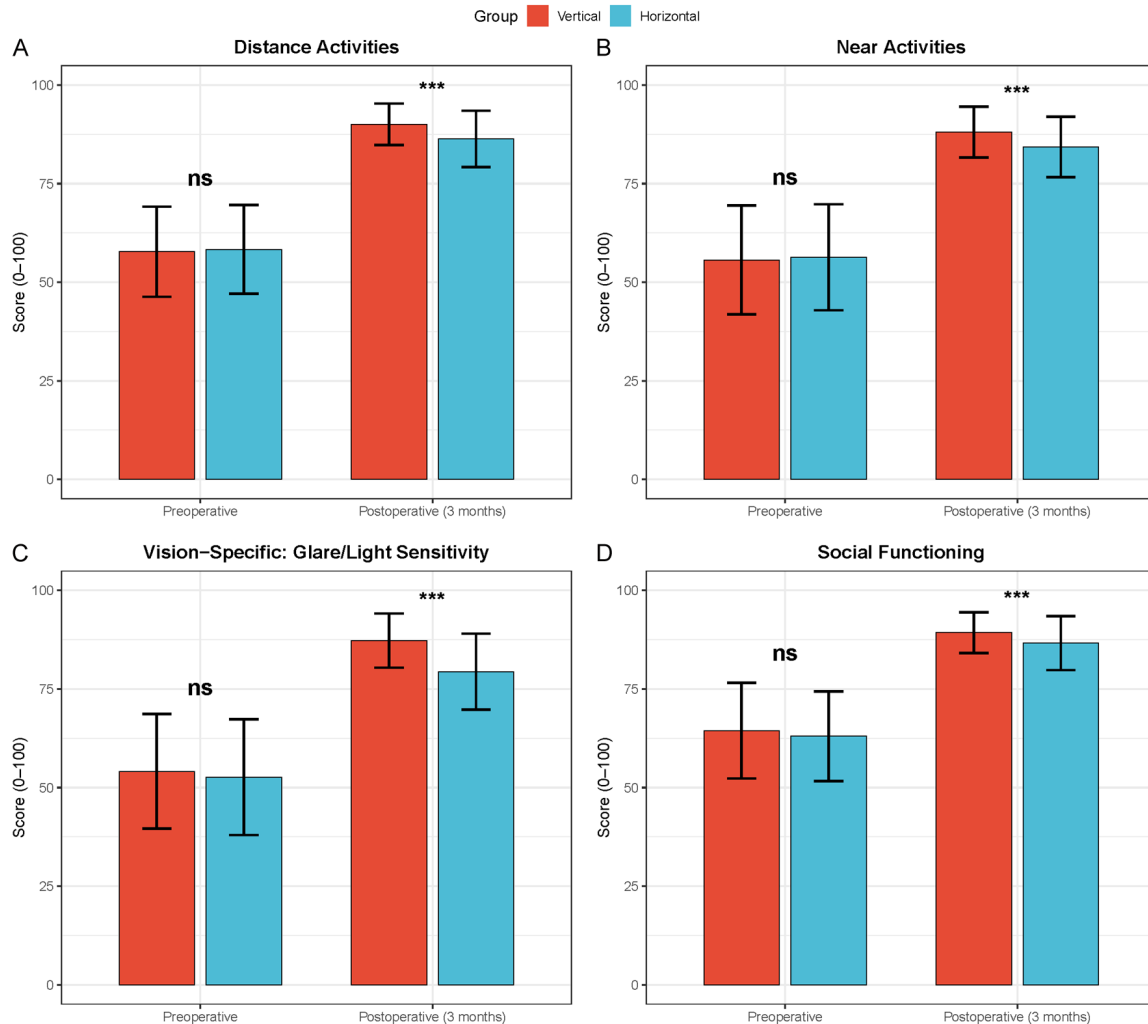
ables were identified as independent risk factors. An AL of  $\geq 23.925$  mm was associated with a more than sixfold increase in risk (OR = 6.296, 95% CI: 2.676-16.664,  $P < 0.001$ ). An ACD of  $\leq 2.835$  mm was associated with a significantly higher risk (OR = 6.823, 95% CI: 3.148-15.270,  $P < 0.001$ ). A capsular bag diameter of  $\geq 10.565$  mm (the optimal cutoff identified by receiver operating characteristic curve analysis) was associated with a 3.5-fold increase in risk (OR = 3.481, 95% CI: 1.618-7.789,  $P = 0.002$ ). Collinearity diagnostics are presented in **Figure 4**. The results of univariate and multivariate logistic regression are summarized in **Figure 5**.

### Subgroup and interaction analyses

Subgroup analyses were conducted to explore whether the association between implantation method and rotational instability varied across different risk strata. Stratified analyses based on AL, ACD, and capsular bag diameter consistently demonstrated protective effects of vertical implantation across different risk strata. Longer AL, shallower ACD, and larger capsular bag diameter were significantly associated with increased risk of rotational instability in both groups.

Interaction analyses were further performed to assess effect modification. No significant inter-

## Effect of implantation orientation on toric IOL rotational stability



**Figure 3.** Comparison of NEI VFQ-25 subscale scores between the two groups at baseline and 3 months postoperatively. A: Distance activities scores at baseline and 3 months. B: Near activities scores at baseline and 3 months. C: Light sensitivity and glare-related visual function scores at baseline and 3 months. D: Social functioning scores at baseline and 3 months. Note: NEI VFQ-25, National Eye Institute Visual Function Questionnaire-25; ns  $P > 0.05$ ; \*\*\* $P < 0.001$ .

actions were observed between implantation method and AL ( $P = 0.200$ ), ACD ( $P = 0.122$ ), or capsular bag diameter ( $P = 0.761$ ), indicating that the beneficial effect of vertical implantation was consistent across different anatomic subgroups. Subgroup analysis results are presented in **Figures 6** and **7**.

### Postoperative complications

The incidence of postoperative complications was low in both groups. As shown in **Table 5**, no significant differences were observed between the two groups for any postoperative complication (all  $P > 0.05$ ), indicating comparable safety profiles for horizontal and vertical implantation.

Specifically, elevated intraocular pressure ( $\geq 25$  mmHg) occurred in 8 eyes (4.23%) in the horizontal group and 6 eyes (3.31%) in the vertical group ( $P = 0.644$ ). Transient corneal edema was observed in 12 eyes (6.35%) and 10 eyes (5.52%), respectively ( $P = 0.737$ ). Anterior chamber inflammation ( $\geq 2+$  cells) occurred in 10 eyes (5.29%) in the horizontal group and 8 eyes (4.42%) in the vertical group ( $P = 0.697$ ). Posterior capsular opacification within 3 months was noted in 5 eyes (2.65%) and 4 eyes (2.21%), respectively ( $P = 1.000$ ). IOL decentration ( $\geq 0.5$  mm) occurred in 4 eyes (2.12%) in the horizontal group and 2 eyes (1.10%) in the vertical group ( $P = 0.720$ ). Clinically significant cystoid macular edema was observed in 3 eyes

## Effect of implantation orientation on toric IOL rotational stability

**Table 4.** Comparison of baseline and intraoperative factors between the rotational instability and stability groups at 3 months postoperatively

Variable	Total	Instability group (n = 42)	Stability group (n = 328)	Statistic	P value
Implantation orientation				11.954	< 0.001
Horizontal	189 (51.08%)	32 (76.19%)	157 (47.87%)		
Vertical	181 (48.92%)	10 (23.81%)	171 (52.13%)		
Age (years)				0.000	0.989
< 70	203 (54.86%)	23 (54.76%)	180 (54.88%)		
≥ 70	167 (45.14%)	19 (45.24%)	148 (45.12%)		
Sex				0.035	0.852
Male	190 (51.35%)	21 (50.00%)	169 (51.52%)		
Female	180 (48.65%)	21 (50.00%)	159 (48.48%)		
BMI				0.171	0.679
< 24 kg/m <sup>2</sup>	231 (62.43%)	25 (59.52%)	206 (62.80%)		
≥ 24 kg/m <sup>2</sup>	139 (37.57%)	17 (40.48%)	122 (37.20%)		
Residential area				4.299	0.038
Urban	257 (69.46%)	35 (83.33%)	222 (67.68%)		
Rural	113 (30.54%)	7 (16.67%)	106 (32.32%)		
Education level				2.141	0.143
≥ High school	215 (58.11%)	20 (47.62%)	195 (59.45%)		
< High school	155 (41.89%)	22 (52.38%)	133 (40.55%)		
CCI score				0.088	0.767
< 1	228 (61.62%)	25 (59.52%)	203 (61.89%)		
≥ 1	142 (38.38%)	17 (40.48%)	125 (38.11%)		
Incision location				0.341	0.843
Temporal	329 (88.92%)	38 (90.48%)	291 (88.72%)		
Superior	26 (7.03%)	3 (7.14%)	23 (7.01%)		
Other	15 (4.05%)	1 (2.38%)	14 (4.27%)		
CTR use				0.000	1.000
Yes	13 (3.51%)	1 (2.38%)	12 (3.66%)		
No	357 (96.49%)	41 (97.62%)	316 (96.34%)		
AL (mm)	23.88 (1.60)	24.80 (1.90)	23.78 (1.62)	5.655	< 0.001
ACD (mm)	3.11±0.33	2.83±0.36	3.14±0.31	5.981	< 0.001
LT (mm)	4.56±0.40	4.69±0.41	4.54±0.39	-2.226	0.027
WTW (mm)	11.71±0.41	11.81±0.44	11.69±0.40	-1.758	0.080
Capsular bag diameter (mm)	10.45 (0.55)	10.82 (0.46)	10.41 (0.54)	5.566	< 0.001
Corneal astigmatism (D)	0.97±0.28	1.00±0.24	0.96±0.29	-0.729	0.466
CCC diameter (mm)	5.21±0.28	5.23±0.30	5.21±0.28	-0.552	0.581
CDE	8.09±3.49	8.31±3.66	8.06±3.47	-0.436	0.663
Phacoemulsification time (s)	55.75±20.18	54.67±15.58	55.89±20.71	0.371	0.711
Surgical duration (min)	13.07±3.83	12.61±3.68	13.13±3.85	0.834	0.405

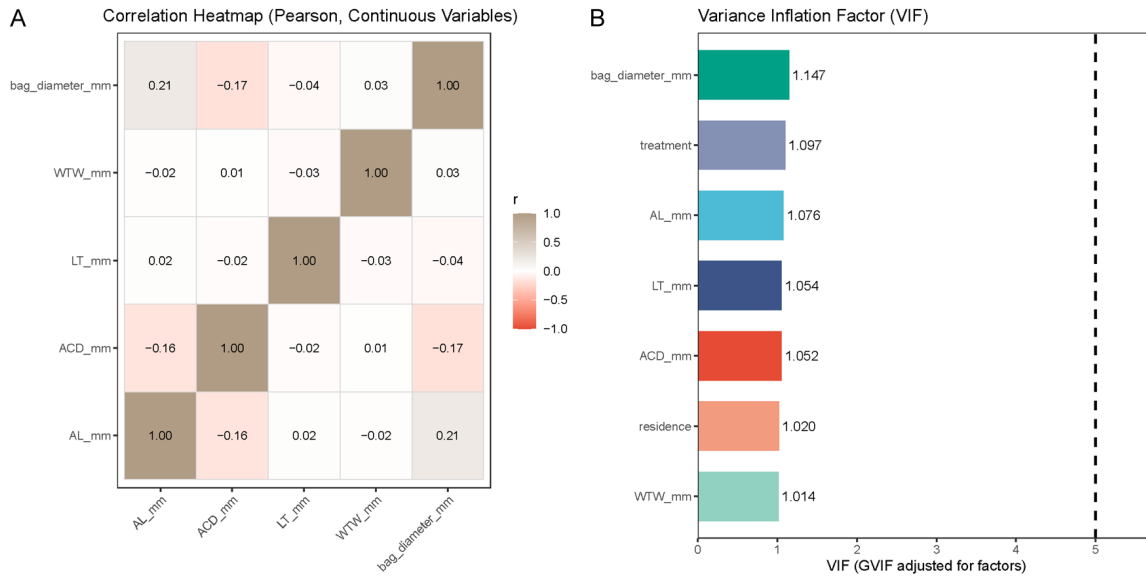
Note: AL, axial length; ACD, anterior chamber depth; LT, lens thickness; WTW, white-to-white; CCC, continuous curvilinear capsulorhexis; CDE, cumulative dissipated energy; CTR, capsular tension ring; CCI, Charlson comorbidity index. Data for AL and capsular bag diameter are presented as median (IQR); otherwise mean ± SD.

(1.59%) and 2 eyes (1.10%), respectively (P = 1.000). Secondary intervention was required in 2 eyes (1.06%) in the horizontal group and 1 eye (0.55%) in the vertical group (P = 1.000).

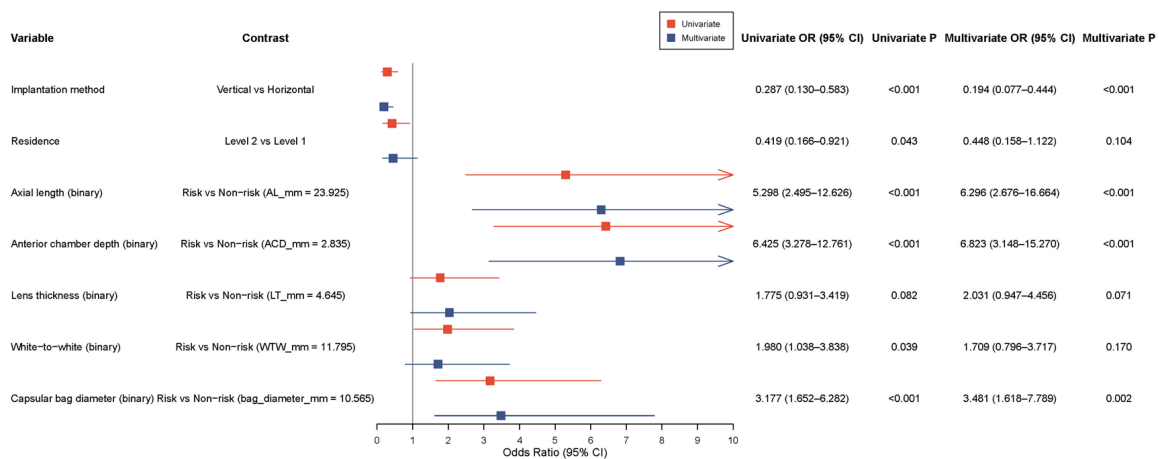
### Discussion

The present study compared vertical versus horizontal in-the-bag implantation of toric IOLs

## Effect of implantation orientation on toric IOL rotational stability



**Figure 4.** Collinearity diagnostics for candidate variables in the logistic regression model. A: Pearson correlation heatmap of continuous variables. B: Bar chart of variance inflation factors for candidate variables. Note: VIF, variance inflation factor; GVIF, generalized variance inflation factor.

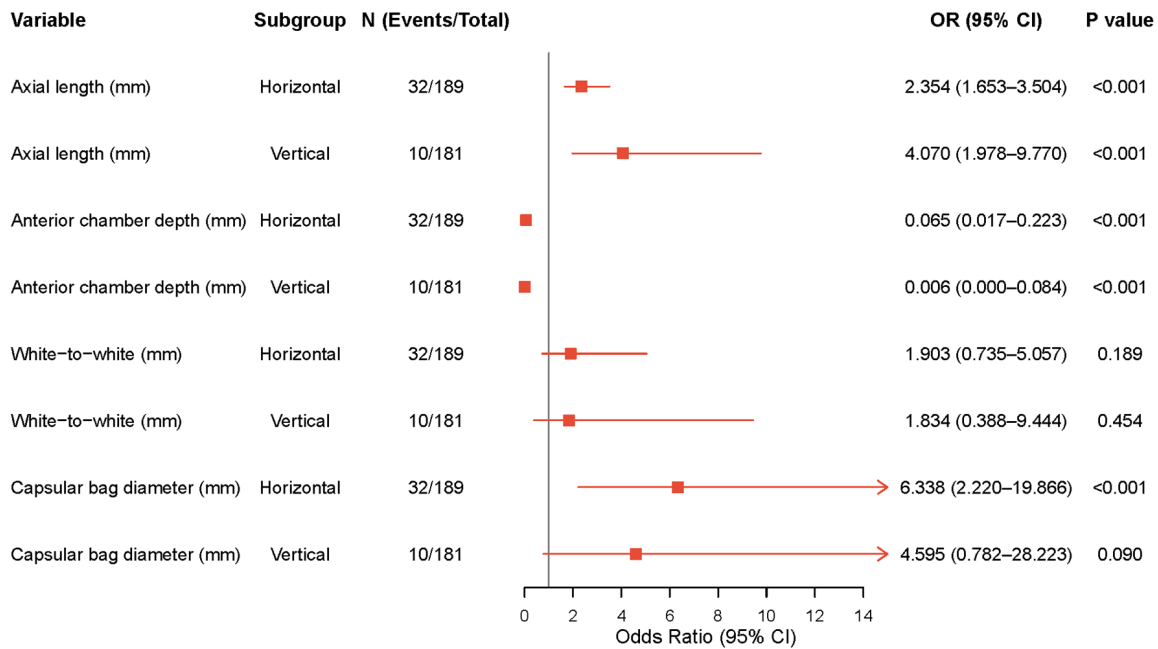


**Figure 5.** Forest plot of univariate and multivariate logistic regression for rotational instability at 3 months postoperatively. Note: OR, odds ratio; CI, confidence interval.

in cataract patients with low regular astigmatism, focusing on postoperative rotational stability, refractive outcomes, and vision-related quality of life. Our analysis showed that rotation angles were lower in the vertical implantation group at all follow-up assessments. Furthermore, this group exhibited a lower rate of clinically significant rotation ( $\geq 5^\circ$ ) at 3 months, along with better visual and refractive outcomes. These findings suggest that modifying intraoperative IOL orientation can improve clinical outcome.

According to the LMM analysis, rotation angles in the vertical implantation group were significantly smaller than those in the horizontal group at 1 week, 1 month, and 3 months postoperatively. The between-group difference was largest at 1 month and partially converged by 3 months, which likely reflects the process of capsular bag contraction and fibrosis that stabilizes the IOL over time [5, 10]. This pattern is consistent with previous clinical observations [12, 15], further confirming the time-dependent nature of rotational stability.

## Effect of implantation orientation on toric IOL rotational stability



**Figure 6.** Subgroup analysis of continuous variables according to implantation method. Note: AL, axial length; ACD, anterior chamber depth; WTW, white-to-white; CBD, capsular bag diameter; OR, odds ratio; CI, confidence interval.

The reduced rotation observed with vertical implantation was clinically significant, but the underlying biomechanical mechanisms remain unclear. Previous experimental and computational studies have suggested that contact area, frictional forces, and capsular bend formation between the IOL haptics and the capsular bag play important roles in rotational stability [11, 17, 18]. However, the present study did not directly measure these variables. Therefore, we could not determine whether the improved stability with vertical implantation was due to altered haptic-capsular bag interactions or other factors. Future studies incorporating intraoperative imaging or *in vitro* capsular bag models are needed to clarify the biomechanical basis of this clinical observation [19, 20].

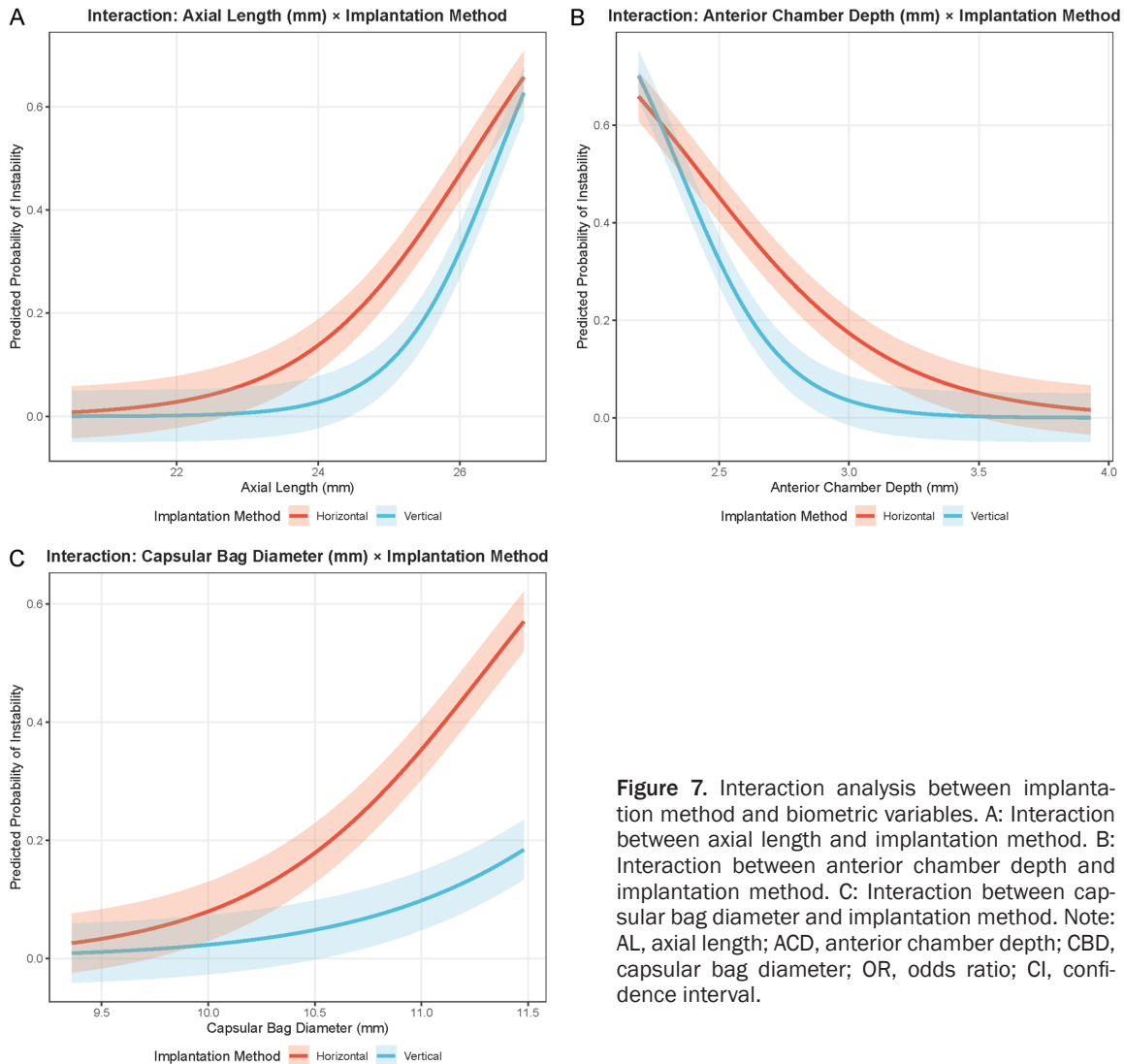
A rotation of 5° decreases the effective astigmatic correction by approximately 16.5%, and larger rotations can lead to substantial deterioration of visual outcomes [4, 5]. This is consistent with the findings of Chang et al. [4] and Gargallo et al. [14], who demonstrated that even small degrees of toric IOL rotation can significantly increase residual astigmatism and reduce visual quality. Our results further support these observations by showing that reduced rotation in the vertical implantation

group was associated with improved refractive outcomes. Although a rotation of  $\geq 5^\circ$  is commonly considered clinically meaningful, the decision for surgical repositioning is typically individualized and depends on residual refractive error and patient symptoms. The reduced rotational instability in the vertical group was associated with improved refractive outcomes and visual function scores, demonstrating additional clinical significance.

At 3 months postoperatively, the vertical implantation group achieved significantly better UCVA and BCVA, as well as SE values closer to the target refraction and lower residual astigmatism. The above-mentioned improvements were likely attributable to the improved rotational stability in this group. A toric IOL that more accurately maintains its intended axis delivers the planned cylindrical correction with minimal residual astigmatism, thereby optimizing the overall refractive outcome [2, 4].

The results from the NEI VFQ-25 further validate the functional effect of these findings. At 3 months, patients in the vertical group reported higher scores for distance activities, near activities, light sensitivity and glare, and social functioning. Residual astigmatism and optical aber-

## Effect of implantation orientation on toric IOL rotational stability



**Figure 7.** Interaction analysis between implantation method and biometric variables. A: Interaction between axial length and implantation method. B: Interaction between anterior chamber depth and implantation method. C: Interaction between capsular bag diameter and implantation method. Note: AL, axial length; ACD, anterior chamber depth; CBD, capsular bag diameter; OR, odds ratio; CI, confidence interval.

**Table 5.** Comparison of postoperative complications between the horizontal and vertical implantation groups

Complication	Total (n = 370)	Horizontal group (n = 189)	Vertical group (n = 181)	Statistic	P value
Elevated intraocular pressure ( $\geq 25$ mmHg)	14 (3.78%)	8 (4.23%)	6 (3.31%)	0.214	0.644
Transient corneal edema	22 (5.95%)	12 (6.35%)	10 (5.52%)	0.112	0.737
Anterior chamber inflammation ( $\geq$ grade 2 cells)	18 (4.86%)	10 (5.29%)	8 (4.42%)	0.152	0.697
Posterior capsular opacification (within 3 months)	9 (2.43%)	5 (2.65%)	4 (2.21%)	0.000	1.000
IOL decentration ( $\geq 0.5$ mm)	6 (1.62%)	4 (2.12%)	2 (1.10%)	0.128	0.720
Clinically significant cystoid macular edema	5 (1.35%)	3 (1.59%)	2 (1.10%)	0.000	1.000
Need for secondary intervention	3 (0.81%)	2 (1.06%)	1 (0.55%)	0.000	1.000

Note: IOP, intraocular pressure; mmHg, millimeters of mercury; IOL, intraocular lens.

rations predominantly affect these domains. Even a small amount of uncorrected astigmatism can moderately degrade retinal image quality, increase glare sensitivity, and reduce

contrast [14, 15]. The observation that vertical implantation improved patient-reported outcomes highlights the real-world relevance of optimizing rotational stability.

## Effect of implantation orientation on toric IOL rotational stability

In addition to efficacy outcomes, the safety profiles of the two implantation groups were comparable. In our study, the overall incidence of postoperative complications was low, and no significant differences were observed between the horizontal and vertical implantation groups across all evaluated events, including intraocular pressure elevation, corneal edema, anterior chamber inflammation, cystoid macular edema, IOL decentration, and the need for secondary intervention. Although the surgical duration tended to be slightly longer in the vertical implantation group, the difference was not significant and did not translate into increased postoperative inflammation, complications, or rotational instability, suggesting that minor variations in surgical time are unlikely to have clinically meaningful effects on postoperative outcomes. These findings suggest that the improved rotational stability and refractive outcomes associated with vertical implantation do not come at the expense of increased surgical risk. The absence of safety differences supports the clinical feasibility of adopting vertical implantation as a routine intraoperative strategy, directly addressing concerns regarding the safety of different implantation orientations.

Multivariate logistic regression identified four independent predictors of rotational instability at 3 months. After controlling for ocular biometric variables, the strong protective effect of vertical implantation (OR = 0.194) confirmed that implantation orientation independently influenced rotational outcomes.

A longer AL ( $\geq 23.925$  mm) increased the odds of instability by more than sixfold compared to a shorter AL. This finding is consistent with previous clinical studies showing greater toric IOL rotation or higher repositioning risk in eyes with longer axial lengths [8, 9, 22]. Although earlier reports have suggested that eyes with longer axial length may be associated with larger capsular bag dimensions and altered capsular dynamics, these relationships were not directly assessed in our dataset [10, 16]. Therefore, the proposed explanation of biomechanical mismatch between the IOL haptics and the capsular bag should be considered speculative.

A shallower ACD ( $\leq 2.835$  mm) was also associated with an increased risk of rotational insta-

bility. Previous studies have suggested that anterior segment measurements may be related to toric IOL rotational behavior, although the reported associations have not been entirely consistent across different IOL platforms and follow-up periods [23-25]. In the present study, the specific relationship between ACD and capsular bag morphology was not directly evaluated; therefore, this interpretation remains hypothetical.

A larger capsular bag diameter ( $\geq 10.565$  mm) was identified as an independent risk factor for rotational instability, increasing the risk by approximately 3.5-fold. Previous biomechanical studies have suggested that a mismatch between capsular bag size and IOL haptic design may reduce contact pressure and rotational resistance [21]. However, these mechanisms were not directly evaluated in the present study. Therefore, the proposed biomechanical explanation should be considered speculative and interpreted with caution. Our findings demonstrate a significant association between larger capsular bag diameter and increased rotational instability but do not provide direct evidence of the underlying mechanical pathways. Future studies incorporating detailed anatomical assessment or biomechanical modeling are needed to clarify these mechanisms.

Although subgroup analyses identified AL, ACD, and capsular bag diameter as significant risk factors for rotational instability, no significant interaction effects were observed. This suggests that the advantage of vertical implantation is not confined to specific high-risk populations but is broadly applicable across different anatomic conditions. From a clinical perspective, this finding supports the generalizability of vertical implantation as a strategy to enhance rotational stability. Although subgroup analyses were based on clinically meaningful cutoff values, further analyses using finer stratification (e.g., multiple interval categories) may provide additional insight into gradient effects across different risk levels.

### Limitations

This study had several limitations. First, its retrospective design introduced potential selection bias and unmeasured confounding, although baseline characteristics were well balanced between groups. Second, the follow-up

period was limited to 3 months, which may not have fully captured long-term rotational stability as capsular fibrosis continues to evolve. Third, all surgeries were performed at a single center by two surgeons using a single IOL model, which may limit the generalizability of the findings. Fourth, key biomechanical indices, such as the contact area between the IOL haptics and the capsular bag and the dynamics of capsular contraction, were not directly assessed using intraoperative imaging or experimental models. Fifth, although the NEI VFQ-25 is a validated instrument, it may not fully capture all aspects of visual satisfaction [13]. Moreover, refractive prediction error was not analyzed, and future studies should incorporate metrics such as mean absolute error to better evaluate refractive accuracy. Furthermore, subgroup analyses based on different degrees of corneal astigmatism were not performed, and future studies are needed to determine whether the effect of implantation orientation varies across astigmatism severity. Additionally, although the predictive model showed good performance, it has not yet been translated into a practical clinical tool, which may limit its immediate applicability in real-world settings.

### Conclusion

In cataract patients with low astigmatism, vertical toric IOL positioning resulted in lower rotation angles and less rotational instability at 3 months compared to horizontal positioning. These advantages were accompanied by better refractive outcomes, visual acuity, and vision-related quality of life scores. Longer axial length, shallower anterior chamber depth, and larger capsular bag diameter were identified as independent risk factors for rotational instability, whereas vertical implantation was a protective factor. Vertical implantation, an uncomplicated intraoperative modification that can be readily adopted, is a practical and suitable means of improving postoperative rotational stability and visual outcomes in these patients. To validate these results and further elucidate the differences from a biomechanical perspective, prospective, multicenter, randomized controlled trials with longer follow-up are warranted.

### Disclosure of conflict of interest

None.

**Address correspondence to:** Xiaohui Qi, Department of Ophthalmology, Dingxi People's Hospital, No. 22, Anding Road, Anding District, Dingxi 743000, Gansu, China. E-mail: qixiaohui743000@163.com

### References

- [1] Keshav V and Henderson BA. Astigmatism management with intraocular lens surgery. *Ophthalmology* 2021; 128: e153-e163.
- [2] Al-Mohtaseb Z, Steigleman WA, Pantanelli SM, Lin CC, Hatch KM, Rose-Nussbaumer JR, Santiago MR, Olsen TW, Kim SJ and Schallhorn JM. Toric monofocal intraocular lenses for the correction of astigmatism during cataract surgery: a report by the american academy of ophthalmology. *Ophthalmology* 2024; 131: 383-392.
- [3] Grosso A, Pertile G, Marchini G, Scarpa G, Ceruti P, Prigione G, Romano MR, Bert F, Gili R, Panico C, Siliquini R and Engelbert M. Adherence to european society for cataract and refractive surgery recommendations among Italian cataract surgeons: a survey. *Eur J Ophthalmol* 2016; 26: 398-404.
- [4] Chang P, Chen D, Hu B, Wang Y, Qian S, Ding X and Zhao Y. Effect of capsular bend on the rotational stability of toric intraocular lens. *Eye (Lond)* 2023; 37: 480-485.
- [5] Lin X, Ma D and Yang J. Insights into the rotational stability of toric intraocular lens implantation: diagnostic approaches, influencing factors and intervention strategies. *Front Med (Lausanne)* 2024; 11: 1349496.
- [6] Kramer BA, Berdahl J, Gu X and Merchea M. Real-world incidence of monofocal toric intraocular lens repositioning: analysis of the American academy of ophthalmology IRIS registry. *J Cataract Refract Surg* 2022; 48: 298-303.
- [7] Hu EH. Repositioning rates of toric IOLs implanted in cataract surgery patients: a retrospective chart review. *Clin Ophthalmol* 2023; 17: 4001-4007.
- [8] Li H, Sun J, Bai H, Leng L, Dai Y and Wu X. Incidence and risk factors of repositioning surgery to correct misalignment of toric intraocular lenses after cataract surgery: a single-center retrospective observational study. *Ophthalmic Res* 2023; 66: 259-264.
- [9] Tang Q, Yang W, Zhong Y, Song X, Hu J, Qin Z, Yu Y and Yu Y. Comparative analysis of three toric intraocular lenses: clinical outcomes and rotational stability in patients with corneal astigmatism. *Adv Ophthalmol Pract Res* 2026; 6: 42-49.
- [10] Oshika T, Nakano S, Fujita Y, Nomura Y, Inoue Y, Takehara H, Miyata K, Honbou M, Sugita T and Kaneko T. Long-term outcomes of cataract surgery with toric intraocular lens implantation

## Effect of implantation orientation on toric IOL rotational stability

- by the type of preoperative astigmatism. *Sci Rep* 2022; 12: 8457.
- [11] Zheng Y, Chen Y, Gu X, Wang M, Zhang C, Xu H, Zhou Y and Fang L. Evaluating the rotational stability of toric intraocular lenses with different haptic designs using finite element analysis. *Exp Eye Res* 2026; 264: 110854.
- [12] Hoffmann P, Potvin R, Anello RD, Hengerer F, Auffarth G, Guldenfels Y, Bertelmann E, Ruiz Mesa R, Fischinger I, Krawczyk S, Seitz B, Antolin-Garcia D, Schmickler S, Hoffart L, Kohnen T and Relucio AS. Comparing rotational stability over time between four monofocal toric intraocular lenses. *Clin Ophthalmol* 2025; 19: 1345-1355.
- [13] McAlinden C, Pesudovs K and Moore JE. The development of an instrument to measure quality of vision: the quality of vision (QoV) questionnaire. *Invest Ophthalmol Vis Sci* 2010; 51: 5537-5545.
- [14] Gargallo D, Remón L, Ares J and Castro-Alonso FJ. The influence of rotational error and axial shift of toric intraocular lenses on residual astigmatism. *PLoS One* 2024; 19: e0311566.
- [15] Ma D, Shen J, Qiu T, Zhang L, Hua Z, Cai L and Yang J. Rotational stability of plate-haptic toric intraocular lenses in Asian eyes: risk period for intraocular lens rotation and its influencing factors. *J Cataract Refract Surg* 2023; 49: 253-258.
- [16] Shi R, Ma D, Zeng Q, Hua Z, Shen W, Cai L and Yang J. Rotational stability of monofocal and diffractive multifocal toric intraocular lens with identical design and material: a propensity score based prospective comparative study. *BMC Ophthalmol* 2024; 24: 72.
- [17] Wang Y, Lou X, Qian S, Li Y, Wu X, Li S, Wang Y, Zhao Y and Chang P. Comparison of the effect of capsular bend on the rotational stability between 2 toric intraocular lenses. *J Cataract Refract Surg* 2024; 50: 283-288.
- [18] Sasaki K, Eguchi S, Miyata A, Nishimura T, Miyata K, Hasegawa Y and Oshika T. Anterior capsule coverage and rotational stability of an acrylic toric intraocular lens. *J Cataract Refract Surg* 2021; 47: 618-621.
- [19] Ichikawa K, Tokiwa S, Tanaka Y, Toda H, Kato Y, Sakai Y, Ichikawa K and Yamamoto N. Study on factors affecting toric intraocular lens rotation using intraoperative OCT-factors influencing IOL deployment and proximity to posterior capsule after insertion. *J Clin Med* 2025; 14: 6599.
- [20] Osawa R, Sano M, Yuguchi T, Kaiya T and Oshika T. Effects of modified haptics on surgical outcomes and rotational stability of toric intraocular lens implantation. *J Refract Surg* 2022; 38: 648-653.
- [21] Liu S, Chen C, Zhou J, Cheng K, Du Y, Meng J, Lu Y, He W and Zhu X. The influence of a modified haptic on preventing toric IOL rotation in high rotation risk eyes. *Adv Ophthalmol Pract Res* 2026; 6: 50-55.
- [22] Patnaik JL, Kahook MY, Berdahl JP, Hardten DR, Wagner BD, Seibold LK and Kramer BA. Association between axial length and toric intraocular lens rotation according to an online toric back-calculator. *Int J Ophthalmol* 2022; 15: 420-425.
- [23] Yao Y, Meng J, He W, Zhang K, Wei L, Cheng K, Lu Y and Zhu X. Associations between anterior segment parameters and rotational stability of a plate-haptic toric intraocular lens. *J Cataract Refract Surg* 2021; 47: 1436-1440.
- [24] Del Castillo C, Zatarain-Barrón NC, López Martínez M, Jiménez-Collado D, Navarrete-Azuara M, Pulido London D and Graue-Hernández EO. Impact of preoperative ocular biometry and capsulorhexis morphology on the rotational stability of a toric intraocular lens. *Arch Soc Esp Oftalmol (Engl Ed)* 2026; 101: 502455.
- [25] Na KS, An D, Kim HS and Kim EC. Relation between change of effective lens position and toric IOL rotation after toric IOL implantation. *Can J Ophthalmol* 2025; 60: 8-14.