

Original Article

Paclitaxel suppresses collagen-induced arthritis: a reevaluation

Yi Zhao¹, Zhi-Fang Chang², Ru Li², Zhan-Guo Li², Xiao-Xia Li¹, Lin Li³

¹Department of Rheumatology and Allergy, Xuanwu Hospital, Capital Medical University, Beijing 100053, China;

²Department of Rheumatology & Immunology, Peking University People's Hospital, Beijing 100044, China; ³Department of Pharmacology, Xuanwu Hospital, Capital Medical University, Beijing 100053, China

Received January 29, 2016; Accepted February 29, 2016; Epub November 15, 2016; Published November 30, 2016

Abstract: Objective: To reevaluate the suppressive effect of paclitaxel (PTX) liposome on collagen-induced arthritis (CIA) in rats and explore its mechanisms. Methods: Female Lewis rats were immunized with bovine type II collagen (CII) to induce arthritis. The rats with CIA were randomly divided into three groups: 5% GS control group, 2.5 mg/kg PTX treatment group and 1 mg/kg methotrexate (MTX) positive control group. The drugs were administered by intraperitoneal injection on the second day after arthritis onset. The body weights, arthritis scores and paw volumes were observed consecutively. The ankle joints of rats were collected for X-ray examination and histological evaluation. Serum samples were collected to test the levels of anti-CII antibodies and cytokines. Results: Body weights were not significantly affected after PTX or MTX treatments ($p > 0.05$). Compared with 5% GS control or MTX treatment groups, PTX group showed significant decrease of arthritis scores and paw volumes ($p < 0.05$). Radiographic and histologic evaluation provided evidence that rats with PTX treatment had less synovial proliferation and bone erosion. In addition, the levels of anti-CII antibodies as well as serum tumor necrosis factor (TNF)- α and vascular endothelial growth factor (VEGF) levels were remarkably lower in PTX group than those in 5% GS controls ($p < 0.05$). Conclusions: PTX inhibits the progression of CIA in rats and prevents the destruction of joints. The mechanism might be related to its inhibition on the levels of serum anti-CII antibodies, TNF- α and VEGF.

Keywords: Paclitaxel, therapy, collagen-induced arthritis, rheumatoid arthritis

Introduction

Rheumatoid arthritis (RA) is a common autoimmune disease characterized by chronic, aggressive erosion of articular bones. To date, the cause of RA has not been disclosed, and drugs or methods for RA therapy are still lack. Although immunosuppressants or immunomodifiers are potential disease modified anti-rheumatic drugs (DMARDs), the treatments were still not satisfactory [1]. Recently, a few bioagents, such as tumor necrosis factor (TNF)- α antagonists [2], interleukin-1 (IL-1) inhibitors [3], and IL-6 monoclonal antibodies [4] were effective in controlling the disease progression and improving the prognosis in RA. However, high cost and adverse effects including tuberculosis and malignancy risks restrict their wide applications [5]. Moreover, certain cases, such as refractory RA, show resistance to DMARDs and bioagents [6-8]. Thus, it is still necessary

to develop new effective and economical drugs for RA treatment.

Paclitaxel (PTX) is initially extracted from the bark of the Pacific yew *taxus brevifolia* and belongs to diterpenoid [9]. It is one of the most commonly used anticancer agents with broad antitumor activities in lung, stomach, breast, ovary and nasopharynx cancers [10]. As a microtubule-stabilizing agent, PTX has the capacity to disrupt the normal dynamic reorganization of the microtubule network, which is required for mitosis and cell proliferation [11]. As reported, PTX could arrest the cell cycle at G2/M phase [12], and inhibit tumor-related angiogenesis and tumor cell proliferation [13]. Considering the aggressive proliferation of synovial cells and pannus formation in RA, it is unsurprised to introduce PTX for RA treatment. Brahn E. firstly reported that PTX (Taxol) could completely prohibit the induction of collagen-

Paclitaxel suppresses collagen-induced arthritis

induced arthritis (CIA) in rats, and cause significant regression of existing arthritis [14]. Moreover, Brahn and his colleagues observed the inhibition of PTX on the synovitis and neovascularization in CIA [15]. Two phases of clinical trials were carried out afterwards. Although phase I clinical trial showed a very good result, the outcome of Phase II is still elusive. In this study, we aimed to reevaluate the effect of PTX on CIA, by assessing the severity of arthritis with more general methods (radiography, pathology and serology), and to explore the mechanism underlying the effect of PTX on CIA.

Materials and methods

Animals

Thirty-five female Lewis rats (weighing 110-120 g) were purchased from Beijing Vital River Experimental Animal Technique Co. Ltd (Beijing, China). The animals were housed under specific pathogen-free condition and fed a standard rodent chow and water ad libitum. All the experimental procedures were approved by the Animal Care and Use Committee of People's Hospital, Peking University and the Animal Research Ethics Committee of Xuanwu Hospital, Capital Medical University.

Induction of collagen-induced arthritis and treatments

CIA model was established as previously described [16]. Bovine type II Collagen (CII) (Sigma, Shanghai, China) was dissolved in 0.1 M acetic acid at a concentration of 4 mg/ml by stirring overnight at 4°C and emulsified in an equal volume of incomplete Freund's adjuvant (Sigma-Aldrich, StLouis, MO, USA). Rats were immunized intradermally with 150 µl of the emulsion containing 2 mg/ml of CII. One week later, a second injection of CII emulsion was administered. Onset of arthritis in all 4 limbs could usually be observed visually between day 12 and day 14. The rats without onset of arthritis after day 14 were excluded from the study.

30 rats were successfully established as CIA model and randomly allocated into three groups (10 rats in each group): paclitaxel (PTX) treatment group, methotrexate (MTX) treatment group and 5% glucose solution (GS) control group. In the PTX treatment group, paclitaxel liposome (LIPUSU®, 30 mg/package, Nanjing

Luye Sike Pharm Co., Ltd., China) was dissolved in 5 ml 5% GS to achieve a final concentration of 6 mg/ml PTX solution. The PTX solution was administered on alternate days at 2.5 mg/kg body weight by intraperitoneal injection starting from the second day post the arthritis onset (Day 1). The dosage of PTX was selected based upon our preliminary experiment. In MTX group, the rats were injected intraperitoneally with MTX injection (5 mg, Ebewe Pharma Gesm.b. HNfg. KG) at 1 mg/kg body weight dose weekly starting from Day 1. Control rats received 200 µl 5% GS intraperitoneally on alternate days starting from Day 1. All the rats were treated for four weeks. MTX treatment was applied as positive control.

Clinical assessment

Body weights were recorded twice per week from Day 1 to Day 30 (the rats were killed). Arthritis symptoms were observed by two independent investigators blindly on Day 1, 4, 8, 12, 15, 20, 25 and 29, respectively. The characteristics of arthritis in each limb were scored from 0 to 4 according to the severity of periarticular erythema and swelling as described previously [17]. Briefly, arthritic lesion was graded on a scale of 0-4: 0 = no change, 1 = swelling and erythema of the digit, 2 = mild swelling and erythema of the limb, 3 = gross swelling and erythema of the limb, and 4 = gross deformity and inability to use the limb. The sum of the scores for all 4 limbs was calculated as the arthritis index for each rat. The maximum index score is 16. An instrument (YLS-7A paw volume meter, Gene & I Co., Beijing, China) was applied to measure the volume of rat paw on Day 1, 8, 15, 22, and 29, respectively to reflect the severity of swelling of hind paws [18].

Radiologic and histologic studies

The radiologic and histologic changes in rats were analyzed according to the methods reported previously [19]. On day 30, rats were anesthetized with 2% sodium pentobarbital (45 mg/kg) and placed on a radiographic box at a distance of 90 cm from the X-ray source. Radiographic analysis (Philips X12; Philips, Munich, Germany) of each rat hind paw was performed with a 40 kW X-ray exposure for 0.01 s. Radiographs were scored on a scale of 0-3, based on joint space between the tibia and calcaneus, the tibia and talus, and the talus and calca-

Paclitaxel suppresses collagen-induced arthritis

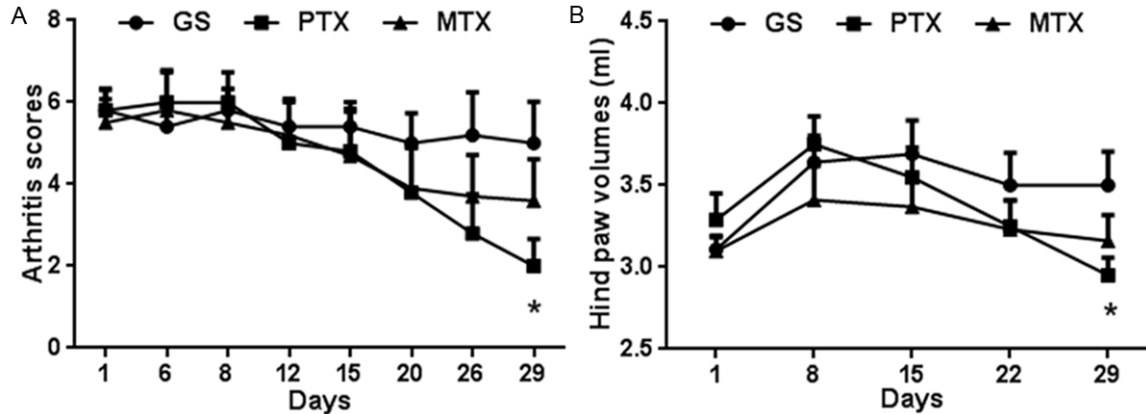


Figure 1. Paclitaxel liposome ameliorates the arthritis severity in collagen-induced arthritis rats. A. Changes of arthritis score in three groups. Both PTX group and MTX group reduced arthritis scores at 14 days after treatments. B. Changes of paw volume in three groups. * $p < 0.05$ compared with control group. GS: glucose solution; PTX, paclitaxel liposome; MTX, methotrexate.

neus (0 = no increase in space, 3 = maximally increased joint space). Radiographs were also scored for the extent of bony destruction/erosions (from 0-4), assigning one point for erosions in any one of the following bones: tibia, calcaneus, talus, and metatarsals (considered together). Soft tissue swelling was also scored on a scale of 0-3 (0 = no swelling, 3 = severe swelling). The sum of three scores was considered as the radiologic score for each ankle (Maximal score is 10), and the average of both ankle scores was used for the statistical analysis. The ankle joints were then fixed in 4% paraformaldehyde, decalcified with EDTA, and embedded in paraffin; 4 μ m sections were prepared. The extent of arthritis was assessed based on hematoxylin and eosin staining, using the following scale: 0 = normal synovium, 1 = synovial membrane hypertrophy and cell infiltrates, 2 = pannus and cartilage erosion, 3 = major erosion of cartilage and subchondral bone, and 4 = loss of joint integrity and ankylosis. The assessment was performed by investigators, who were blinded to the identity of the specimens, and the average of the 2 scores was used.

Detection of serum anti-CII antibodies

The peripheral blood of rats was collected by puncturing the posterior orbital venous before killing the rats (Day 30). Anti-CII antibodies were measured by enzyme-linked immunosorbent assay (ELISA) as described previously [15]. Briefly, 96-well microtiter plates (Costar,

Cambridge, MA) were coated with 5 μ g/ml bovine CII at 4°C overnight. After being washed with PBS containing 0.05% tween (PBS-T), the plates were blocked with 5% (wt/v) skimmed milk for 2 h at 37°C. Serum samples were diluted into 1:200 and 100 μ l were then added to each well. After incubation for 1 h at 25°C and washing, goat anti-rat IgG antibody conjugated to peroxidase was added to the wells at a 1:5000 dilution. After incubation for 1 h at 37°C and washing, the bound antibodies were detected with O-phenylenediamine dihydrochloride color-development reagent. Plates were read at absorbance of wavelength 490 nm (OD 490 nm).

Serum cytokine measurement

The serum samples were also applied for cytokine measurement. The levels of interleukin (IL)-1 β , tumor necrosis factor (TNF)- α and vascular endothelial growth factor (VEGF) were determined with commercially available ELISA kits (R&D, CA, Minneapolis, MN, USA) according to the manufacturer's instructions.

Statistical analysis

Data analyses were performed using SPSS 13.0 for Windows. For normally distributed data, the results were expressed as mean \pm SD; the differences between groups were analyzed with the *t* test. For abnormally distributed data, the differences were tested with the Mann-Whitney *U* test. *p* values less than 0.05 were considered statistically significant.

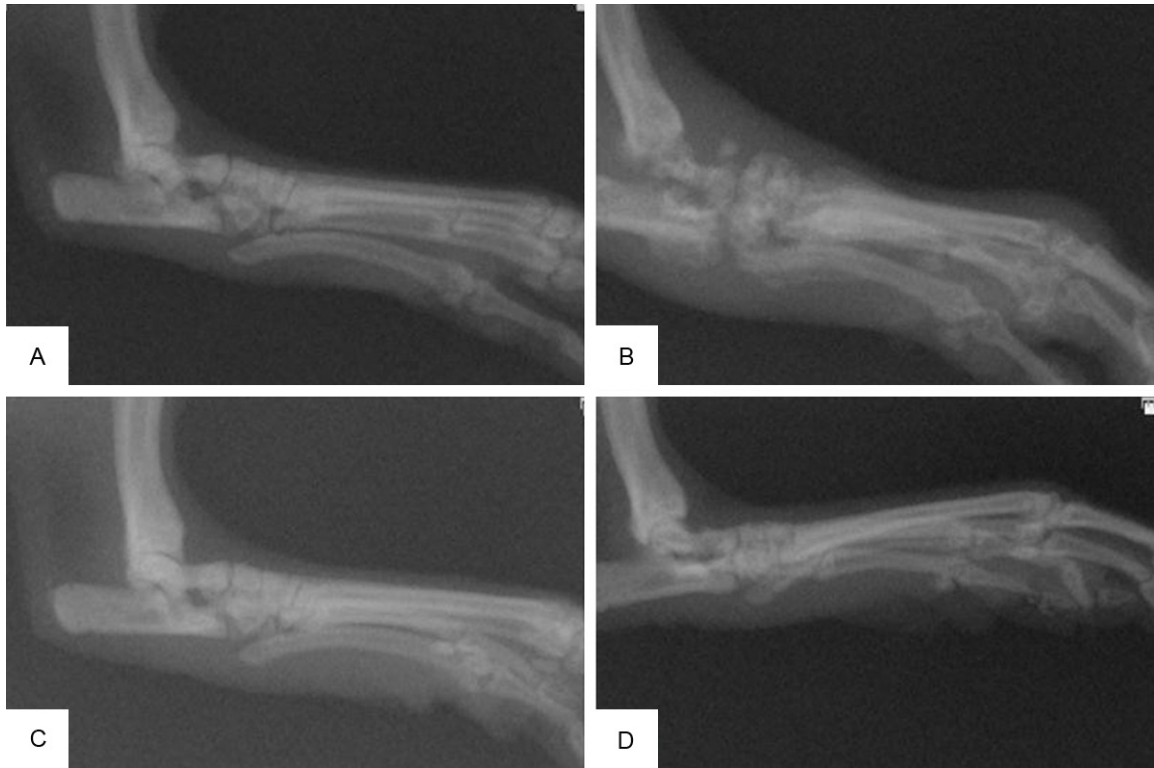


Figure 2. Radiographic changes of hind paws in three groups. (A) Normal rat hind paw. No paw swelling or joint damage. (B) Hind paw of rat treated with 5% GS. Obvious swelling of soft tissue, widened joint space and severe bone erosion. (C) Hind paw of rat treated with PTX. (D) Hind paw of rat treated with MTX. The scores for (A, B, C and D) were 0, 10, 4 and 6, respectively. GS: glucose solution; PTX: paclitaxel liposome; MTX: methotrexate.

Results

PTX inhibited the arthritis severity in CIA rats

The therapeutic effects of PTX on arthritis in CIA rats were based on the changes of body weight, arthritis scores and paw volumes. The results showed that body weight increased in the rats of all groups throughout the experiment. However, there were no significant differences in the change of body weight among the three groups ($p > 0.05$, data not shown). There was an obvious time-dependent reduction of arthritis scores in PTX group and MTX group from Day 15 compared with GS group. On Day 29 (i.e. the day before the experiment finished), the mean arthritis score in PTX group was significantly lower than that in GS control (2.0 ± 2.11 vs 5.0 ± 3.16 , $p < 0.05$). The mean arthritis score in MTX group was also lower than that in GS control, but without statistical significance ($p > 0.05$) (**Figure 1A**).

A similar trend of paw volume changes were observed in the three groups (**Figure 1B**). On Day 29, the mean paw volumes of PTX group,

MTX group and GS control group were 2.95 ± 0.34 ml, 3.16 ± 0.50 ml and 3.50 ± 0.65 ml, respectively. There was a significant difference between PTX group and GS group ($p < 0.05$). Together, the results suggested that PTX caused efficient inhibition on chronic inflamed arthritis in CIA.

PTX suppressed radiologic progression in CIA rats

Radiographic extent of joint destruction was analyzed on Day 30. The rats in PTX group had less soft swelling and bone erosion compared with rats in MTX group and GS group (**Figure 2**). Moreover, radiographic score in rats treated with PTX (3.95 ± 3.25) was remarkably reduced compared with that from GS controls (6.3 ± 3.51) ($p < 0.034$). By contrast, there was no significant difference between MTX and GS groups (5.0 ± 3.47 vs. 6.3 ± 3.51 , $p > 0.05$).

PTX prevented against the histologic changes in CIA rats

The therapeutic effect of PTX on CIA rats was further verified by histological examination. The

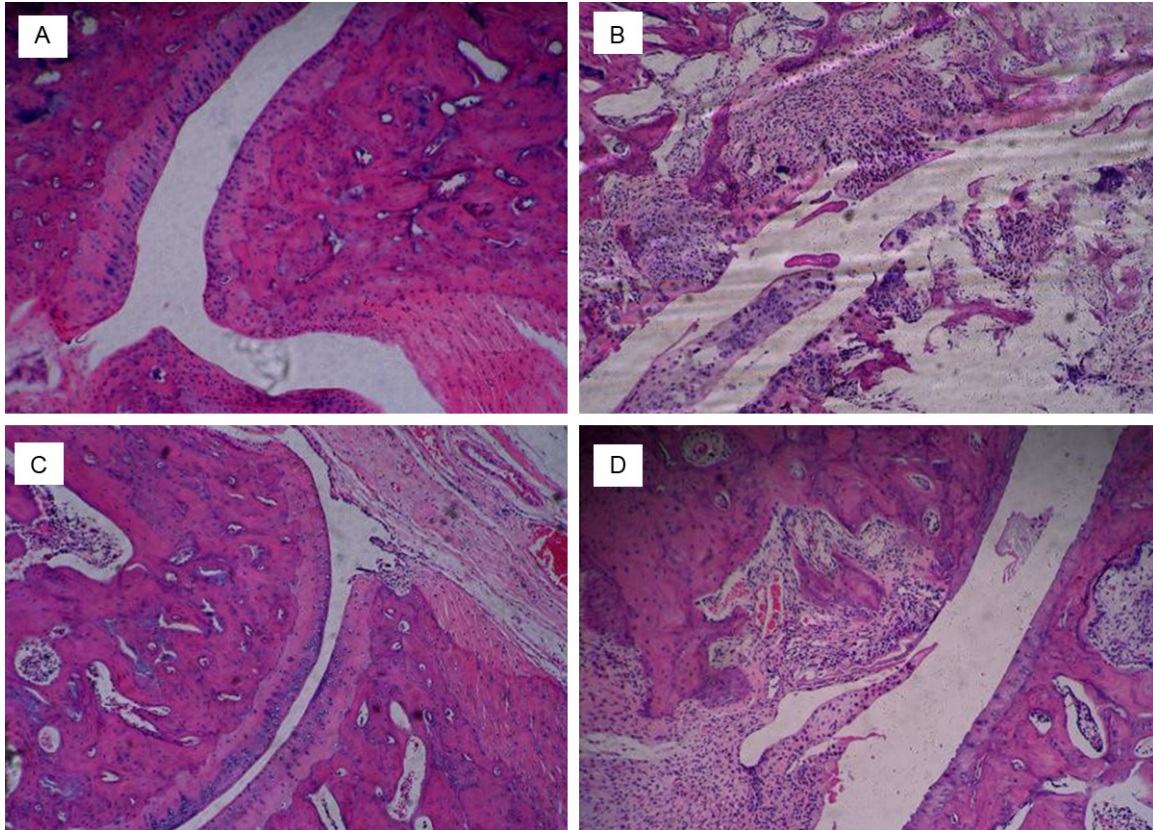


Figure 3. Histological analysis of ankle joints in three groups. (A) Normal ankle joint of rat, with intact articular cartilage and no infiltration of inflammatory cells in synovium. (B) Ankle joint of rat treated with 5% GS, with remarkable synovial proliferation, pannus formation, damage of articular cartilage and subchondral bone, and disruption of joint structure. (C) Ankle joint of rat treated with PTX, with mild synovial proliferation and cartilage damage. (D) Ankle joint of rat treated with MTX, with synovial proliferation, pannus formation and destruction of cartilage and subchondral bone. The scores for (A, B, C and D) were 0, 4, 2 and 3, respectively. GS: glucose solution; PTX: paclitaxel liposome; MTX: methotrexate.

CIA rats in GS group developed chronic inflammation of synovial tissue, pannus formation, cartilage destruction and bone erosion. In contrast, there were remarkable reduction in inflammatory infiltration, pannus formation and joint structure changes in PTX group and MTX group (**Figure 3**). The result of histologic scoring also showed that the mean score in PTX group (2.1 ± 0.2) was significantly lower than that in GS group (2.9 ± 0.3 , $p < 0.05$), and there was no significant difference between MTX group and GS group (2.3 ± 0.2 vs. 2.9 ± 0.3 , $p > 0.05$).

PTX suppressed humoral immunity in CIA rats

The level of anti-CII antibodies is closely related to the development and severity of CIA [20]. To verify the effect of PTX on humoral immunity in CIA rats, the serum levels of anti-CII antibodies

were detected by ELISA on Day 30. The median levels of anti-CII antibodies in PTX group, MTX group and GS group were 1.390 (1.282-1.460), 1.344 (1.170-1.554) and 1.446 (1.401-1.584), respectively. The level of anti-CII antibodies in either PTX group or MTX group was significantly lower than that in GS group ($p < 0.05$). However, there was no statistical difference in the levels of anti-CII antibodies between PTX group and MTX group ($p > 0.05$).

PTX inhibited the release of inflammatory cytokines in CIA rats

TNF- α and IL-1 β play important roles in the pathogenesis of collagen-induced arthritis in rats [21, 22]. VEGF is known as a potent inducer of synovial proliferation via its ability to induce angiogenesis [23]. The results of ELISA

Paclitaxel suppresses collagen-induced arthritis

Table 1. Levels of serum cytokines in three groups of rats with collagen-induced arthritis

Groups	TNF- α (pg/ml)	IL-1 β (pg/ml)	VEGF (pg/ml)
5% GS control	52.14 \pm 17.44	95.90 \pm 11.60	15.69 \pm 2.28
MTX-treated group	34.00 \pm 16.05*	76.99 \pm 11.56	11.57 \pm 1.87
PTX-treated group	29.23 \pm 16.21*	77.30 \pm 20.68	7.63 \pm 1.38*

* $p < 0.05$ compared with 5% GS group.

showed that the serum levels of TNF- α were significantly lower in both PTX group and MTX group than that in GS group ($p < 0.05$). Although the level of IL-1 β slightly decreased in both PTX group and MTX group when compared to GS group but without significant difference. PTX group had a significant lower level of VEGF than that in GS group ($p < 0.05$). In addition, there was no significant difference in the level of VEGF between MTX group and GS group (Table 1).

Discussion

Although the effects of PTX on the symptoms of CIA were reported before, the unclear mechanisms restrict its wide applications. In this study, we reevaluated the protective activity of PTX in CIA model. We confirm that PTX is useful in the treatment of CIA by using the methods of radiography, pathology and serology. Moreover, we disclosed that the potential mechanisms were related to humoral immunity, cytokines and VEGF.

PTX was administrated at the second day after successfully modeling of CIA. As evidenced by arthritis scoring and the volume of rat paw, PTX treatment exerted significant suppression of the arthritis in CIA rats. Importantly, the effects could be observed after two-week treatment, and the maximal changes were observed at the end of the experiment. In a previous study, Oliver et al applied a two-step PTX procedure to treat CIA rats (10 mg/kg per day for three days and 7.5 mg/kg on alternate days until the end of the experiment). They demonstrated that arthritis scores were reduced statistically at the time points of Day 9 and Day 11 after CIA onset [24]. The suppression of arthritis in CIA rats was much faster in Oliver's study than that in our study. That discrepancy might be caused by different animal strains used in the studies. In Oliver's study, Louvain rats were used, while in our study, Lewis rats were used. Although the

effects in that study were stronger, we reported that a low dose of PTX still had ideal activity.

CIA is often accompanied with change of body weight [25]. However, in our study, the body weight was not significantly affected after modeling. Moreover, treatment with PTX or MTX did not increase the body weight. This phenomenon might be explained by the negative effect on gastrointestinal function in PTX and MTX-treated rats, which nullified the therapeutic effect.

We further confirmed the effects of PTX in the CIA rats by the results of radiology and histopathology. PTX suppressed the proliferation of synovium and the formation of pannus in the inflammatory joints, and reduced the erosion of cartilages. Subsequently, radiologic progression in PTX group was weakened, in comparison to GS control or MTX group. Interestingly, the effect after engagement of MTX was weaker than that after PTX administration. That might be explained by a slower efficacy, the relatively low dosage used, and the short treatment duration in this study. Previously, Hui and Kurose investigated the mechanism underlying the effects of PTX on synovial proliferation in vitro [26, 27]. PTX induced cell arrest at G2/M phase and apoptosis in human cultured fibroblast-like synovial cells (FLS), which had high proliferative activity. Thus, the inhibition of PTX on the proliferative synovium might be beneficial for the treatment of RA.

Autoantibodies and inflammatory cytokines play important roles in the immunopathogenesis of RA, and the level of anti-CII antibodies is positively related to the development of CIA in rats [20]. As expected, we found that the levels of anti-CII antibodies in rats treated with PTX decreased significantly, following by alleviation of CIA. These data implicated that inhibition of PTX on the proliferation of B cells, or on the production and secretion of antibodies might be the mechanisms. However, whether PTX inhibits specific humoral immune responses has not been clarified. There are few studies on how PTX impacts the cytokines in CIA rats or RA patients. Previous studies showed that PTX up-regulated the expression of TNF- α but down-regulated the expression of TNF- α receptors in

Paclitaxel suppresses collagen-induced arthritis

murine macrophages [28, 29]. In our study, TNF- α level in CIA rats decreased significantly after PTX treatment, but IL-1 β level, another important cytokine in CIA, was unaltered. Since TNF- α plays a key role in the synovium proliferation and pannus formation of joints, the reduction of TNF- α after PTX treatment supported the weak histopathological changes in PTX group. Nevertheless, the effects of PTX on the expression of TNF- α or its receptors in CIA rats require future studies.

Pannus formation is an important pathological feature of RA. A lot of molecules are involved in synovial angiogenesis, especially VEGF [23]. As previously reported, RA patients had a high expression of VEGF in the synovial tissue and serum [30]. PTX inhibited angiogenesis by interfering with cell mitosis, migration and chemotaxis [31]. In our study, we found that VEGF level was significantly decreased after PTX treatment.

Presently, there are two commercially available forms of paclitaxel: Paclitaxel injection with Cremophor EL as medium and paclitaxel liposome. The former has poor water solubility with strong irritation. Latter is paclitaxel encapsulated in liposome. This innovation without changing the chemical structure and pharmacological action of paclitaxel, increases solubility and reduces adverse effects.

Conclusion

In conclusion, we reconfirmed the inhibitory effect of PTX on CIA rats, and found that PTX had a significant suppressive effect on serum antibody level and inflammation-related cytokines, thus demonstrating that PTX is a potential drug to treat RA.

Address correspondence to: Lin Li, Department of Pharmacology, Xuanwu Hospital, Capital Medical University, No. 45 Changchun Street, Beijing 100053, China. Tel: +8601083198886; Fax: +8601083198886; E-mail: lilin160128@163.com

References

[1] Bansard C, Lequerre T, Daveau M, Boyer O, Tron F, Salier JP, Vittecoq O and Le-Loet X. Can rheumatoid arthritis responsiveness to methotrexate and biologics be predicted? *Rheumatology (Oxford)* 2009; 48: 1021-1028.

- [2] Elliott MJ, Maini RN, Feldmann M, Kalden JR, Antoni C, Smolen JS, Leeb B, Breedveld FC, Macfarlane JD, Bijl H and et al. Randomised double-blind comparison of chimeric monoclonal antibody to tumour necrosis factor alpha (cA2) versus placebo in rheumatoid arthritis. *Lancet* 1994; 344: 1105-1110.
- [3] Fleischmann RM, Schechtman J, Bennett R, Handel ML, Burmester GR, Tesser J, Modafferi D, Poulakos J and Sun G. Anakinra, a recombinant human interleukin-1 receptor antagonist (r-metHuIL-1ra), in patients with rheumatoid arthritis: A large, international, multicenter, placebo-controlled trial. *Arthritis Rheum* 2003; 48: 927-934.
- [4] Genovese MC, McKay JD, Nasonov EL, Mysler EF, da Silva NA, Alecock E, Woodworth T and Gomez-Reino JJ. Interleukin-6 receptor inhibition with tocilizumab reduces disease activity in rheumatoid arthritis with inadequate response to disease-modifying antirheumatic drugs: the tocilizumab in combination with traditional disease-modifying antirheumatic drug therapy study. *Arthritis Rheum* 2008; 58: 2968-2980.
- [5] Nanau RM and Neuman MG. Safety of anti-tumor necrosis factor therapies in arthritis patients. *J Pharm Pharm Sci* 2014; 17: 324-361.
- [6] Gallego-Galisteo M, Villa-Rubio A, Alegre-del Rey E, Marquez-Fernandez E and Ramos-Baez JJ. Indirect comparison of biological treatments in refractory rheumatoid arthritis. *J Clin Pharm Ther* 2012; 37: 301-307.
- [7] Kawashiri SY, Kawakami A, Iwamoto N, Fujikawa K, Aramaki T, Tamai M, Arima K, Ichinose K, Kamachi M, Yamasaki S, Nakamura H, Origuchi T, Ida H and Eguchi K. Switching to the anti-interleukin-6 receptor antibody tocilizumab in rheumatoid arthritis patients refractory to anti-tumor necrosis factor biologics. *Mod Rheumatol* 2010; 20: 40-45.
- [8] Finckh A, Simard JF, Gabay C, Guerne PA and physicians S. Evidence for differential acquired drug resistance to anti-tumour necrosis factor agents in rheumatoid arthritis. *Ann Rheum Dis* 2006; 65: 746-752.
- [9] Wani MC, Taylor HL, Wall ME, Coggon P and McPhail AT. Plant antitumor agents. VI. The isolation and structure of taxol, a novel antileukemic and antitumor agent from *Taxus brevifolia*. *J Am Chem Soc* 1971; 93: 2325-2327.
- [10] Zhao Y, Mu X and Du G. Microtubule-stabilizing agents: New drug discovery and cancer therapy. *Pharmacol Ther* 2015; [Epub ahead of print].
- [11] Spencer CM and Faulds D. Paclitaxel. A review of its pharmacodynamic and pharmacokinetic properties and therapeutic potential in the

Paclitaxel suppresses collagen-induced arthritis

- treatment of cancer. *Drugs* 1994; 48: 794-847.
- [12] Long BH and Fairchild CR. Paclitaxel inhibits progression of mitotic cells to G1 phase by interference with spindle formation without affecting other microtubule functions during anaphase and telephase. *Cancer Res* 1994; 54: 4355-4361.
- [13] Gupta SC, Kim JH, Prasad S and Aggarwal BB. Regulation of survival, proliferation, invasion, angiogenesis, and metastasis of tumor cells through modulation of inflammatory pathways by nutraceuticals. *Cancer Metastasis Rev* 2010; 29: 405-434.
- [14] Brahn E, Tang C and Banquerigo ML. Regression of collagen-induced arthritis with taxol, a microtubule stabilizer. *Arthritis Rheum* 1994; 37: 839-845.
- [15] Arsenault AL, Lhotak S, Hunter WL, Banquerigo ML and Brahn E. Taxol involution of collagen-induced arthritis: ultrastructural correlation with the inhibition of synovitis and neovascularization. *Clin Immunol Immunopathol* 1998; 86: 280-289.
- [16] Li R, Li X and Li Z. Altered collagen II 263-272 peptide immunization induces inhibition of collagen-induced arthritis through a shift toward Th2-type response. *Tissue Antigens* 2009; 73: 341-347.
- [17] Schoen RT, Greene MI and Trentham DE. Antigen-specific suppression of type II collagen-induced arthritis by collagen-coupled spleen cells. *J Immunol* 1982; 128: 717-719.
- [18] Zhang L, Li J, Yu SC, Jin Y, Lv XW, Zou YH and Li Y. Therapeutic effects and mechanisms of total flavonoids of *Turpinia Arguta* Seen on adjuvant arthritis in rats. *J Ethnopharmacol* 2008; 116: 167-172.
- [19] Woods JM, Katschke KJ, Volin MV, Ruth JH, Woodruff DC, Amin MA, Connors MA, Kurata H, Arai K, Haines GK, Kumar P and Koch AE. IL-4 adenoviral gene therapy reduces inflammation, proinflammatory cytokines, vascularization, and bony destruction in rat adjuvant-induced arthritis. *J Immunol* 2001; 166: 1214-1222.
- [20] Cho YG, Cho ML, Min SY and Kim HY. Type II collagen autoimmunity in a mouse model of human rheumatoid arthritis. *Autoimmun Rev* 2007; 7: 65-70.
- [21] Williams RO. Collagen-induced arthritis in mice: a major role for tumor necrosis factor-alpha. *Methods Mol Biol* 2007; 361: 265-284.
- [22] Ferraccioli G, Bracci-Laudiero L, Alivernini S, Gremese E, Toluoso B and De Benedetti F. Interleukin-1beta and interleukin-6 in arthritis animal models: roles in the early phase of transition from acute to chronic inflammation and relevance for human rheumatoid arthritis. *Mol Med* 2010; 16: 552-557.
- [23] Szekanecz Z, Besenyei T, Paragh G and Koch AE. New insights in synovial angiogenesis. *Joint Bone Spine* 2010; 77: 13-19.
- [24] Oliver SJ, Banquerigo ML and Brahn E. Suppression of collagen-induced arthritis using an angiogenesis inhibitor, AGM-1470, and a microtubule stabilizer, taxol. *Cell Immunol* 1994; 157: 291-299.
- [25] Cremer MA, Townes AS and Kang AH. Collagen-induced arthritis in rodents. A review of clinical, histological and immunological features. *Ryumachi* 1984; 24: 45-56.
- [26] Kurose A, Yoshida W, Yoshida M and Sawai T. Effects of paclitaxel on cultured synovial cells from patients with rheumatoid arthritis. *Cytometry* 2001; 44: 349-354.
- [27] Hui A, Kulkarni GV, Hunter WL, McCulloch CA and Cruz TF. Paclitaxel selectively induces mitotic arrest and apoptosis in proliferating bovine synoviocytes. *Arthritis Rheum* 1997; 40: 1073-1084.
- [28] Bottex-Gauthier C, Condemine F, Picot F and Vidal D. Effects of taxol on the macrophage function. Interactions with some immunological parameters. *Immunopharmacol Immunotoxicol* 1992; 14: 39-61.
- [29] Manthey CL, Brandes ME, Perera PY and Vogel SN. Taxol increases steady-state levels of lipopolysaccharide-inducible genes and protein-tyrosine phosphorylation in murine macrophages. *J Immunol* 1992; 149: 2459-2465.
- [30] Nagashima M, Asano G and Yoshino S. Imbalance in production between vascular endothelial growth factor and endostatin in patients with rheumatoid arthritis. *J Rheumatol* 2000; 27: 2339-2342.
- [31] Lainer-Carr D and Brahn E. Angiogenesis inhibition as a therapeutic approach for inflammatory synovitis. *Nat Clin Pract Rheumatol* 2007; 3: 434-442.