

Original Article

Radiofrequency ablation for postsurgical thyroid removal of differentiated thyroid carcinoma

Dong Xu¹, Lipin Wang¹, Bin Long², Xuemei Ye², Minghua Ge³, Kejing Wang³, Liang Guo³, Linfa Li²

Departments of ¹Ultrasound, ²Nuclear Medicine, ³Head and Neck Surgery, Zhejiang Cancer Hospital, Hangzhou 310022, China

Received January 18, 2015; Accepted February 17, 2016; Epub April 15, 2016; Published April 30, 2016

Abstract: Differentiated thyroid carcinoma (DTC) is the most common endocrine malignancy. Surgical removal with radioactive iodine therapy is recommended for recurrent thyroid carcinoma, and the postsurgical thyroid removal is critical. This study evaluated the clinical values of radiofrequency ablation (RFA) in the postsurgical thyroid removal for DTC. 35 DTC patients who had been treated by subtotal thyroidectomy received RFA for postsurgical thyroid removal. Before and two weeks after RFA, the thyroid was examined by ultrasonography and ^{99m}TcO₄⁻ thyroid imaging, and the serum levels of free triiodothyronine (FT3), free thyroxin (FT4), thyroid stimulating hormone (TSH) and thyroglobulin (Tg) were detected. The efficacy and complications of RFA were evaluated. Results showed that, the postsurgical thyroid removal by RFA was successfully performed in 35 patients, with no significant complication. After RFA, the average largest diameter and volume were significantly decreased in 35 patients ($P > 0.05$), and no obvious contrast media was observed in ablation area in the majority of patients. After RFA, the serum FT3, FT4 and Tg levels were markedly decreased ($P < 0.05$), and TSH level was significantly increased ($P < 0.05$). After RFA, radioiodine concentration in the ablation area was significantly reduced in the majority of patients. The reduction rate of thyroid uptake was $0.69 \pm 0.20\%$. DTC staging and interval between surgery and RFA had negative correlation (Pearson coefficient = -0.543; $P = 0.001$), with no obvious correlation among others influential factors. RFA is an effective and safe method for postsurgical thyroid removal of DTC.

Keywords: Radiofrequency ablation, ultrasonography, differentiated thyroid carcinoma, removal

Introduction

Differentiated thyroid carcinoma (DTC) is the most common endocrine malignancy, and has good prognosis after surgery [1, 2]. However, the frequent metastasis in local cervical lymph nodes and remote organs are usually found. The follow-up period of 11.3 years shows that, the overall recurrence and mortality rates for DTC are 20.5% and 8.5% respectively [3]. It is necessary to find the effective way to treat recurrent thyroid carcinoma, for improving the survival rate and life quality of patients.

Surgical removal with radioactive iodine therapy is recommended for recurrent thyroid carcinoma [3]. Postsurgical thyroid removal is critical for the radioactive iodine therapy. For the repeated surgery, the neck dissection is difficult for surgeons due to distortion in the normal tissue plane, postsurgical fibrosis and severe adhesion, and is associated with the complica-

tions such as nerve injury, hypoparathyroidism and cosmetic concerns rated to re-incision [4]. For radioactive iodine therapy, the efficacy depends on many influential factors such as time of iodine ablation, surgical method, residual thyroid tissue, thyroid stimulating hormone (TSH) level, metastatic status, and so on. The remission rate of postsurgical thyroid removal by radioactive iodine therapy is not satisfactory, and there are many complications such as excessive iodine intake in thyroid tissue and high risk of radioiodine concentration in the local area [5]. As the first radioactive iodine therapy for patients with total thyroidectomy, the remission rate is just 64.5% [6]. For postsurgical DTC patients without far metastasis, the remission rate can reach 84.6%, but if the lymphatic metastasis and far metastasis occurs, the rate changes to 45.5% and 27.3%, respectively [7]. Radiofrequency ablation (RFA) is usually used in patients at high surgery risk and in those who refuse to undergo repeated

Radiofrequency ablation for postsurgical thyroid removal

surgery [8]. Recently, several studies report that ethanol injection with RFA can be the effective and valuable treatment option for original thyroid carcinoma and recurrent disease [9-11]. However, application of RFA to thyroid removal of after surgery in DTC patients has seldom been reported. In this study, the efficacy and safety of RFA in postsurgical thyroid removal of DTC was evaluated. The objective was to more formally define the role of RFA in treatment of DTC.

Patients and methods

Patient recruitment

Thirty-five DTC patients (15 males and 20 females; aged 27-78 years, with mean age of 43.49 ± 13.01 years) who received ultrasonography-guided RFA for postsurgical thyroid removal from January 2014 to May 2015 were enrolled in this study. All patients had been treated by subtotal thyroidectomy, and the interval between surgery and RFA was 1-3 months. The histologic type confirmed by postsurgical pathology was papillary thyroid carcinoma. The size of thyroid carcinomas was 7-46 mm (average 28.71 ± 10.32 mm).

According to the results from US and $^{99m}\text{TcO}_4^-$ thyroid nuclear medical imaging, there was no obvious nodule in thyroid after surgery. 25 patients needed unilateral removal of residual thyroid tissue (left, 11 cases; right, 14 cases), and 10 patients needed bilateral removal. In 35 patients, the maximum unilateral diameter and volume of residual thyroid tissue were 15-39 mm (average 25.14 ± 5.87 mm), and 0.9-4.4 mL (average 2.38 ± 0.86 mL), respectively. The TSH level of patients was < 30 mU/L. This study was approved by the Institutional Review Board in XXXXXX Hospital. Informed consent was obtained from each patient.

Radiofrequency ablation

Under guidance with Logiq E9 ultrasound machine with 6-16 MHz linear probe (GE Healthcare Inc., WS, USA), the RFA was performed in an outpatient operating room by 2 ultrasound intervention doctors with 5 years of RFA experience. Radiofrequency generator (VRS01, STARmed Inc., Gyeonggi-do, Korea) and thyroid-dedicated, internally cooled radiofrequency electrode (STARmed Inc., Gyeonggi-do, Ko-

rea) were used for ablation. A 7-cm long, 18-gauge electrode with a 0.5- or 1.0-cm active tip was chosen according to postsurgical thyroid size. The radiofrequency power was 20-45 w, and the radiofrequency work time was 1.0-4.5 min. The patient blood pressure, blood O_2 saturation, heart rate and electrocardiography were monitored during the RFA procedure.

The patient was in supine position, with pillow under shoulder and head back to expose the neck. After iodophor disinfection and sterile towel, lidocaine (2%, up to 10 mL; Hebei Tiancheng Pharmaceutical Co., Ltd., Shijiazhuang, China) we carefully injected to the skin, needle track and anterior thyroid capsule for local anesthesia. Several important methods were performed to prevent the unnecessary complications during RFA. Firstly, US-guidance was used to trace the electrode tip. Secondly, totally 20-30 mL of physiological saline (North China Pharmaceutical Co., Ltd., Shijiazhuang, China) was injected to front edge of residual thyroid tissue, inner carotid sheath and back of thyroid gland to create a protective barrier to radiofrequency energy (i.e., the hydrodissection technique) [10, 12].

The electrode tip was initially positioned in the deepest, most remote portion of the lesion, and then the thyroid tissue removal was executed gradually and anteriorly with the moving short technique [8]. Ablation was started with low power (5 w for 0.5-cm active tip or 20 w for 1.0-cm active tip, respectively), and the radiofrequency power was gradually and carefully increased (up to 10 w in 0.5-cm active tip and 45 w in 1.0-cm active tip, respectively) [3]. During the ablation, the patient voice and pain were checked frequently. If the patient could not tolerate pain, the radiofrequency power was reduced or turned off immediately. Ablation was terminated when the residual thyroid tissue changed to a transient hyperechoic zone or the hoarseness developed [8, 12]. Finally, following the electrode trace, the ablation was completed, and the pinprick on the skin was packed with woundplaster. After RFA, all patients were observed for 1-2 h in the resting room, and the discomfort or complications associated with RFA were observed. All patients stopped taking thyroid hormone tablets and continued to take low-iodine diet for two weeks before and after RFA.

Radiofrequency ablation for postsurgical thyroid removal

Table 1. Patients and thyroid carcinoma characteristics according to DTC stage

Stage	T2	T3	T4	M1	N1
n (%)	5 (14.3%)	7 (20.0%)	7 (20.0%)	8 (22.9%)	8 (22.9%)
Age, year	55.8±18.16	44.71±10.94	47.71±14.8	41.0±7.43	33.5±6.3
Male	3	1	4	6	1
DTC size, mm	32.6±3.51	43.4±2.3	27.1±7.76	24.1±5.57	19.4±8.35

DTC, differentiated thyroid carcinoma.

Ultrasonography

Logiq E9 ultrasound machine with 6-16 MHz linear probe was used for pre- and post-RFA routine ultrasound and contrast-enhanced ultrasound (CEUS) examination, and guidance during the ablation. The size of residual thyroid tissue, internal echo and color flow was observed and recorded by routine ultrasound. During CEUS, the contrast media SonoVue (Bracco Corp., Milan, Italy) was used, which consisted of inert gas (SF₆) with lecithin. The microbubble suspension of SonoVue with physiological saline was prepared. The contrast mode on the machine was activated, and the mechanical index was set as 0.06. After shaking for 20 s, 2.4 mL of SonoVue suspension was quickly injected through the elbow vein, followed by continued quick injection of 5 mL physiological saline. 3-min contrast dynamic pictures were observed and stored for analysis.

Follow-up and assessment of RFA efficacy

After RFA, any discomfort or complication associated with treatment was observed. Patients were followed up two weeks after RFA. The size, internal echo and color flow of residual thyroid tissue were observed by routine ultrasonography. The contrast media performance of residual thyroid tissue was examined by CEUS. No obvious contrast media in the area of postsurgical thyroid was regarded as the diagnosis standard of successful postsurgical thyroid removal by RFA [13]. If there was still residual thyroid tissue, the additional RFA was performed, until till no obvious contrast media was found. The ^{99m}TcO₄ thyroid imaging was performed, and radioiodine concentration in the residual thyroid tissue was significantly reduced that was regarded as the diagnosis standard of successful RFA removal. The reduction rate of thyroid uptake was assessed, and the final con-

clusion for further radioactive iodine treatment was determined by two radiologists with 5 years of diagnosis experience. In addition, the serum levels of free triiodothyronine (FT3), free thyroxine (FT4) and TSH were detected using radioimmunoassay, and thyroglobulin

(Tg) was detected using double-antibody radioimmunoassay. All procedures were performed according to the instructions of kit manufactures.

Statistical analysis

All statistical analysis was carried out using SPSS 17.0 software (SPSS Inc., Chicago, IL, USA). The measurement data were presented as mean ± SD. Wilcoxon signed-rank test was used for comparison of maximum diameter and volume of residual thyroid tissues, serum FT3, FT4, TSH and Tg level before RFA and two weeks after RFA. *P* < 0.05 was considered as statistically significant. According to previous study on iodine therapy [6], some significant influential factors such as DTC staging, pre-RFA thyroid volume, interval between surgery and RFA, post-RFA TSH level and post-RFA Tg level were selected for Pearson's correlation coefficient analysis. Scatter plots were obtained to indicate the correlations among these variables.

Results

General information of patients

Total 35 DTC patients received RFA for postsurgical thyroid removal. The patient and thyroid carcinoma characteristics were summarized in **Table 1**. The DTC staging included T2, T3 and T4 or M1 (distant metastasis) and N1 (lateral neck lymphatic metastasis, without central lymphatic metastasis).

Overall treatment outcome

All 35 patients successfully received the postsurgical thyroid removal by RFA, including 25 cases of unilateral postsurgical thyroid removal (left, 11 cases; right 14 cases) and 10 cases of bilateral postsurgical thyroid removal for in patients. The mean time of hospitalization for all patients was 1.2 days.

Radiofrequency ablation for postsurgical thyroid removal

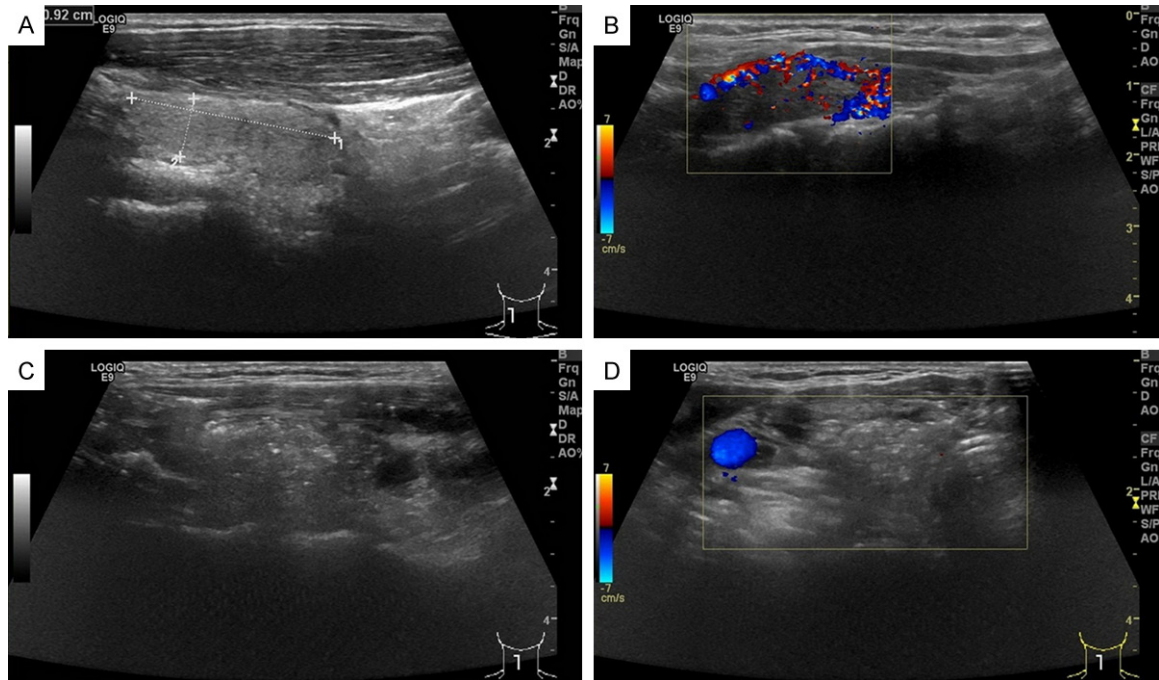


Figure 1. Routine ultrasonography on thyroid before and after RFA. Before RFA, the size of residual thyroid tissue was 32.2 mm*9.2 mm*10.7 mm (A), and rich blood flow was observed in thyroid tissue (B); After RFA, the size of residual thyroid tissue was 30.0 mm*10.0 mm*10.5 mm (C), and there was no obvious blood flow in thyroid tissue (D).

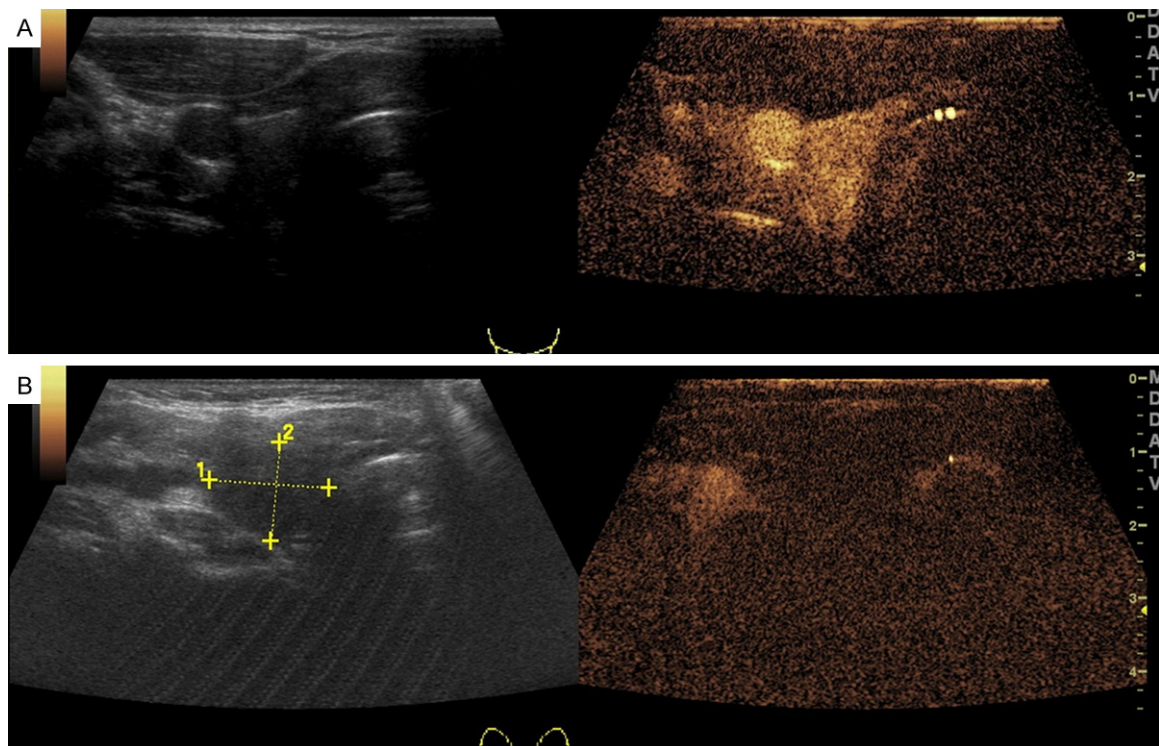


Figure 2. CEUS on thyroid before and after RFA. Before RFA, there was irregular enhancement in the residual thyroid tissue (A); After RFA, no obvious contrast media was observed in the ablation area (B).

Radiofrequency ablation for postsurgical thyroid removal

Table 2. Maximum thyroid diameter/volume and serum biochemical indexes before and after RFA

	Diameter mm	Volume ml	FT3 pg/mL	FT4 ng/dL	TSH U/L	Tg ng/mL
Before	25.14±5.87	2.38±0.86	3.19±0.32	1.03±0.20	18.78±6.28	44.45±14.30
After	24.73±5.61	2.33±0.71	2.82±0.63	0.93±0.26	33.37±14.66	27.79±23.65
P	0.064	0.080	0.003	0.011	0.000	0.001

RFA, radiofrequency ablation; FT3, free triiodothyronine; FT4, free thyroxine; TSH, thyroid stimulating hormone; Tg, thyroglobulin.

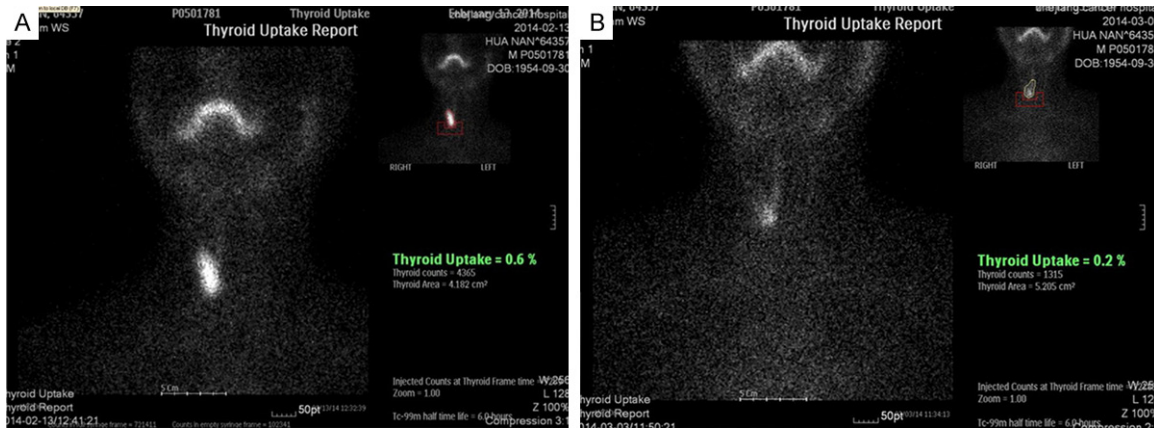


Figure 3. $^{99m}\text{TcO}_4$ -thyroid nuclear medical imaging on thyroid before and after RFA. Before RFA, there was obvious radioiodine concentration in thyroid (A); Two weeks after RFA, only a little radioiodine concentration was observed (B).

Complications

There was no significant complication for the RFA procedure. Two patients experienced voice change immediately after RFA and recovered soon. No any voice change and nerve complication was observed in other patients. A burning sensation, pain, or both came from 10 patients, but the symptoms were relieved by reducing RF power or stopping RFA procedure for several seconds.

Ultrasonography examination results

Routine ultrasonography showed that, before RFA, there were low-level echo and relatively rich blood flow signal in thyroid tissue (**Figure 1A, 1B**). After RFA, the high-level internal echo with light spots in the ablation area was observed, without obvious color flow inside (**Figure 1C, 1D**).

CEUS showed that, before RFA, there were irregular enhancement in the whole residual thyroid tissue (**Figure 2A**); After RFA, no obvious contrast media was observed in the ablation area in 34 patients (**Figure 2B**), with contrast media filling in 1 patient. The second RFA was executed for this patient, and the active ablation time was 45 s. The CEUS was performed

again, until no obvious contrast media was observed.

Changes of maximum diameter/volume of residual thyroid tissue and serum biochemical indexes

The unilateral maximum diameter and volume of residual thyroid tissue and FT3, FT4, TSH and Tg levels were detected before RFA and two weeks after RFA. Results were shown in **Table 2**. Compared with before RFA, the maximum diameter and volume of residual thyroid tissue after RFA decreased (from 25.14±5.87 mm to 24.73±5.61 mm and from 2.38±0.86 mm³ to 2.33±0.71 mm³, respectively), but the difference was not significant ($P > 0.05$). Compared with before RFA, the serum FT3, FT4 and Tg level after RFA significantly decreased (from 3.19±0.32 mm to 2.82±0.63, from 1.03±0.2 mm to 0.93±0.26 mm, from 44.45±14.30 mm to 27.79±23.65 mm, respectively) ($P < 0.05$), and the TSH level significantly increased (from 18.78±6.28 mm to 33.37±14.66 mm) ($P < 0.05$).

Changes of radioiodine concentration in thyroid

$^{99m}\text{TcO}_4$ -thyroid nuclear medical imaging showed that, before RFA, there was obvious radio-

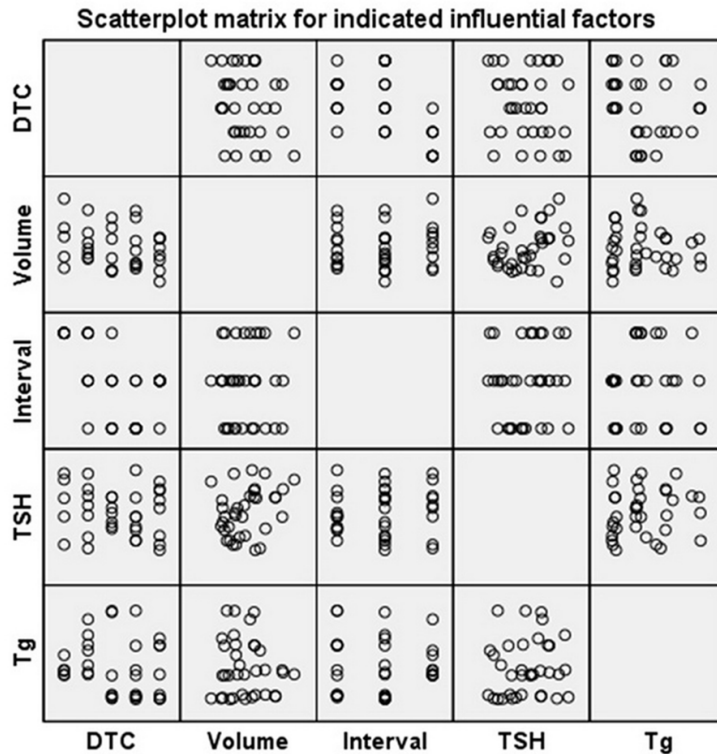


Figure 4. Scatter plots for DTC staging, thyroid volume, interval between surgery and RFA, post-RFA TSH and post-RFA Tg. RFA, radiofrequency ablation; Tg, thyroglobulin; TSH, thyroid stimulating hormone; DTC, differentiated thyroid carcinoma.

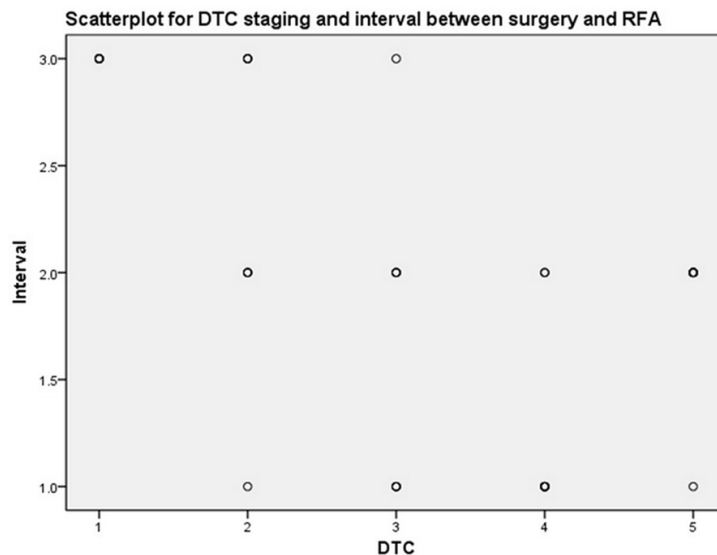


Figure 5. Scatter plots for DTC staging and interval between surgery and RFA. RFA, radiofrequency ablation; DTC, differentiated thyroid carcinoma.

update was $0.69 \pm 0.20\%$ (Figure 3). Only for 2 patients, the reduction rate of thyroid uptake was 0.4%, others were more than 0.5%. In addition, the Tg levels of these 2 patients were 2.31 and 1.76 ng/mL, respectively. Therefore, two radiologists gave the final conclusion that all 35 patients could receive the radioactive iodine treatment.

Correlations among DTC staging, pre-RFA thyroid volume, interval between surgery and serum biochemical indexes

Results of Pearson's correlation coefficient analysis showed that, among the influential factors including DTC staging, pre-RFA thyroid volume, interval between surgery and RFA, post-RFA TSH level and post-RFA Tg level, the DTC staging and interval between surgery and RFA had negative correlation (Pearson coefficient = -0.543 ; $P = 0.001$), and no obvious correlation among others factors. Scatter plots were used to indicate the correlations between these variables, and the results were shown in Figures 4, 5.

Discussion

Thyroid carcinoma is the most common endocrine malignant tumor. The prevalence of thyroid nodules is 18.6%, and 5-15% thyroid nodules are malignant, of which 90% is DTC. The incidence of DTC continues to increase in these 30 years [5, 14]. The surgical resection of tumor is often used for DTC, and there are two ways for removal of residual thyroid tissue after surgery. One is secondary surgical removal, and the other is radioactive iodine treatment [15, 16]. There are many significant complications for repeated surgical therapy, including nerve injury, hypoparathyroidism and cosmetic concerns rated to re-incision [4].

iodine concentration in thyroid, which indicated the residual thyroid tissue. After RFA, radioiodine concentration in the ablation area was significantly reduced, the reduction rate of thyroid

Radiofrequency ablation for postsurgical thyroid removal

Table 3. Clinical findings and outcomes of RFA for recurrent DTC (literatures)

Authors	Number of Tumor	Follow-up range/ month	VRR/%	CDR/%	Tg	
					Patient number	Reduction Rate/%
Dupuy et al. [19]	11 (8 patients)	6-26 (10.3)	NA	25	6	92.4
Monchik et al. [9]	24 (16 patients)	10-68 (40.7)	NA	50	11	95
Baek et al. [10]	12 (10 patients)	16-31 (23.6)	93	50	7	73
Park et al. [20]	16 (11 patients)	1-14 (6)	50.9	NA	9	58.4

RFA, radiofrequency ablation; DTC, differentiated thyroid carcinoma; VRR, volume reduction rate; CDR, complete disappearance rate; Tg, thyroglobulin.

Table 4. Meta analysis results of radioactive iodine thyroid removal

Authors	Time	Low-dose group		SR	High-dose group		SR	Weight factor %
		Successful cases	Patients number		Successful cases	Patients number		
Johansen et al. [21]	1991	21	36	58.3%	14	27	51.9%	4.7
Bal et al. [22]	1996	17	27	63.0%	28	38	73.7%	6.9
Maenpaa et al. [23]	2008	49	77	63.6%	55	72	76.4%	16.8
Mallick et al. [24]	2012	198	214	92.5%	197	207	95.2%	59.3
Caglar et al. [25]	2012	36	47	76.6%	42	48	87.5%	12.3

Low-dose group, 1110 MBq; High-dose group, 3700 MBq; SR, success rate.

Although the radioactive iodine thyroid removal is the most common treatment method in clinic, but the efficacy depends on many influential factors. This treatment is also associated with many complications [5]. Therefore, it is necessary to seek better methods for postsurgical thyroid removal of DTC. In this study, RFA is used for postsurgical thyroid removal of DTC. All 35 patients have successfully received RFA, and obtained satisfactory efficacy. After RFA, the maximum diameter and volume of residual thyroid tissue are decreased slightly. The serum FT3, FT4 and Tg level significantly drop down in the majority of patients, and the TSH level markedly increases. These are the intuitionistic results of the efficacy of RFA.

In this study, RFA was performed in the patients who require radioactive iodine treatment after thyroid surgery. The inclusion standard for radioactive iodine treatment is recommended as TSH \geq 30 mU/L, and the lower TSH level will decrease the treatment efficacy [17]. In this study the TSH level in all patients is under 30 mU/L, so these patients cannot acquire satisfied efficacy by directly radioactive iodine treatment. After RFA, the TSH level increases to above 30 mU/L, so the subsequent radioactive iodine treatment can be conducted. During all the procedures, one patient receives additional RFA, because of the border residual thyroid tis-

sue around the ablation area. The additional RFA depends on the size of residual thyroid tissue. For this patient, there is a spot of residual thyroid tissue, with maximum diameter of 39 mm, so second RFA is performed. According to our experience, RFA is just a treatment before radioactive iodine treatment. Some thyroid tissue adjacent to the trachea and laryngeal nerve should be retained, for ensuring the safety of RFA.

Results of Pearson's correlation coefficient analysis show that, DTC staging and interval between surgery and RFA have negative correlation. The reason may be that, for the patients with T4 staging or far lymph node metastasis, the interval time between surgery and RFA should be shortened, and the removal of residual thyroid should be executed as soon as possible, based on the condition of the patients. Just as we mention that the aim of RFA is to inactive the residual normal thyroid tissue, there is no obvious correlation among pre-RFA thyroid volume, post-RFA TSH level and post-RFA Tg level.

From previous report [18], except no obvious radioiodine concentration by nuclear medical imaging in the whole body, Tg < 2.0 ng/mL is another diagnosis standard of successful removal of thyroid tissue under radioactive iodine

Radiofrequency ablation for postsurgical thyroid removal

treatment. In this study, Tg < 2.0 ng/ml is not considered as the referred standard indicator. After RFA, the Tg level in 35 patients is 27.79 ± 23.65 ng/mL. There are two reasons. Firstly, the treatment is for inactivated normal residual thyroid tissue, but not the metastasis of DTC in the whole body, which has the function of Tg secretion. This is also the key point of subsequent radioactive iodine therapy. Secondly, some thyroid tissues adjacent to the trachea and laryngeal nerve are retained, which affects the Tg level. Also for the 2 patients that the reduction rate of thyroid uptake was 0.4%, two radiologists considered the Tg levels that were 2.31 and 1.76 ng/mL the final conclusion was determined that all patients could receive the radioactive iodine treatment. RFA is a new method for postsurgical thyroid removal, the diagnostic standard for Tg level and nuclear medicine imaging also need be explored in the further study in the future.

In this study, there are 2 patients (5.7%, 2/35) with voice change. The complication rate (5.7%, 2/35) is somewhat superior to the results reported in previous studies [8, 11], in which are RFA is applied to treating thyroid cancer or local recurrence of DTC. A multicenter study of Korean Society of Thyroid Radiology (KSThR) reports that the voice change occurs in 1% patients after RFA [15]. The relatively higher complication rate in this study is probably due to the superabundant thyroid tissue ablation. In addition, the maximum diameter and volume of residual thyroid tissue are related to voice change, and the conservation treatment or RF power may also be the reason of voice change. In this study, the two patients just have immediate voice change, and both of them recover soon. The physiological saline is used to create a protective barrier as prevention procedure, which may be the good way to avoid voice change and decrease complication.

Until now we have not inquired any related literature for RFA treated post-surgical thyroid removal. As Lee et al. [3] report that, RFA can be effective in treating loco-regional, recurrent, and DTC in patients with high surgical risk. After 30 months of follow-up, the maximum diameter and volume of recurrent DTC were decreased by 93.2% and 96.4%, respectively. According to more previous RFA studies (Table 3), after RFA the volume reduction rate of thyroid is from 50.9% to 93%, with complete disappearance rate from 25% to 50%. All of them are the evi-

dence to ensure that RFA is effective and safe for thyroid carcinoma. According to previous study [8] for RFA to treat local recurrence of DTC, a mean volume reduction is 96.4%, which is extremely higher than this study. The postsurgical thyroid removal is the treatment of normal thyroid tissue, and the residual thyroid tissue is just inactivated, which is different from RFA treatment for thyroid carcinoma or local tumor recurrence.

The literatures on the efficacy of radioactive iodine ablation are reviewed, and the detailed information is shown in Table 4. The low- and high-dose radioactive iodine groups are separated for meta analysis [26]. The success rates of treatment in low- and high-dose groups are 63%-93% and 74%-95%, respectively. RFA thyroid removal is a local ablation, and is based on the diagnosis criteria from the results of CEUS and $^{99m}\text{TcO}_4^-$ thyroid imaging. In this study, the removal efficacy was satisfied for all 35 patients and all of them could receive the further radioactive iodine treatment. However, for radioactive iodine thyroid removal, the success rate usually is based on the whole body scanning result and Tg level. Although RFA cannot be simply compared with radioactive iodine ablation, it can be concluded that RFA is effective for postsurgical thyroid removal.

This study also has some limitations. Although 35 patients are included in the study, the sample size is relatively small. In addition, it is the primary study for RFA to treat postsurgical thyroid removal, and the research methods are not very mature. There are some points which should be improved for the study. Firstly, a relatively large sample size is needed for patient selection, adaptation disease indication and complication. Secondly, considering the characteristics of thyroid nuclear medical imaging and Tg level, longer follow-up period is also needed. Thirdly, the efficacy of subsequent radioactive iodine treatment should be observed for comprehensive analysis. Finally, the standardized procedures for RFA thyroid removal should be established. Therefore, further large-size, long-term, prospective studies are required to provide advanced evidence for the efficacy of RFA for postsurgical thyroid removal.

In conclusion, RFA is the effective and safe method for postsurgical thyroid removal of DTC. This study has provided a basis for further

Radiofrequency ablation for postsurgical thyroid removal

application of RFA to treatment of thyroid carcinoma.

Acknowledgements

This study was supported by Zhejiang Provincial Natural Science Foundation of China (No. LY15H180001).

Disclosure of conflict of interest

None.

Address correspondence to: Dr. Dong Xu, Department of Ultrasound, Zhejiang Cancer Hospital, No. 38, Guangji Road, Gongshu, Hangzhou 310022, China. E-mail: xud_nj@163.com

References

- [1] Kumar V, Abbas AK, Aster JC. Robbins and cotran pathologic basis of disease. 9th edition. Philadelphia: Saunders; 2014. pp. 1073-1139.
- [2] Dupuy DE, Monchik JM. Radiofrequency ablation of recurrent thyroid cancer. In: Ellis LM, Curley SA, Tanabe KK, editors. Radiofrequency ablation for cancer: Current indications, techniques, and outcomes. New York: Springer-Verlag; 2003. pp. 213-223.
- [3] Lee SJ, Jung SL, Kim BS, Ahn KJ, Choi HS, Lim DJ, Kim MH, Bae JS, Kim MS, Jung CK, Chong SM. Radiofrequency ablation to treat loco-regional recurrence of well-differentiated thyroid carcinoma. *Korean J Radiol* 2014; 15: 817-826.
- [4] Esnaola NF, Cantor SB, Sherman SI, Lee JE, Evans DB. Optimal treatment strategy in patients with papillary thyroid cancer: a decision analysis. *Surgery* 2001; 130: 921-930.
- [5] Gharib H, Papini E, Paschke R, Duick DS, Valcavi R, Hegedüs L, Vitti P; AACE/AME/ETA Task Force on Thyroid Nodules. American Association of Clinical Endocrinologists, Associazione Medici Endocrinologi, and European Thyroid Association medical guidelines for clinical practice for the diagnosis and management of thyroid nodules. *J Endocrinol Invest* 2010; 33: 1-50.
- [6] Cury AN, Meira VT, Monte O, Marone M, Scalis NM, Kochi C, Calliari LE, Longui CA. Clinical experience with radioactive iodine in the treatment of childhood and adolescent Graves' disease. *Endocr Connect* 2012; 2: 32-37.
- [7] Zhang GZ, Tan J, Liu XH. Influential factors on the effectiveness of ¹³¹I treatment on postsurgical differentiated thyroid cancer patients. *Chin J Nucl Med* 2010; 30: 259-263. In Chinese.
- [8] Na DG, Lee JH, Jung SL, Kim JH, Sung JY, Shin JH, Kim EK, Lee JH, Kim DW, Park JS, Kim KS, Baek SM, Lee Y, Chong S, Sim JS, Huh JY, Bae JI, Kim KT, Han SY, Bae MY, Kim YS, Baek JH; Korean Society of Thyroid Radiology (KSThR); Korean Society of Radiology. Radiofrequency ablation of benign thyroid nodules and recurrent thyroid cancers: consensus statement and recommendations. *Korean J Radiol* 2012; 13: 117-125.
- [9] Monchik JM, Donatini G, Iannuccilli J, Dupuy DE. Radiofrequency ablation and percutaneous ethanol injection treatment for recurrent local and distant well-differentiated thyroid carcinoma. *Ann Surg* 2006; 244: 296-304.
- [10] Baek JH, Kim YS, Sung JY, Choi H, Lee JH. Locoregional control of metastatic well-differentiated thyroid cancer by ultrasound-guided radiofrequency ablation. *AJR AM J Roentgenol* 2011; 197: W331-W336.
- [11] Shin JE, Baek JH, Lee JH. Radiofrequency and ethanol ablation for the treatment of recurrent thyroid cancers: current status and challenges. *Curr Opin Oncol* 2013; 25: 14-19.
- [12] Baek JH, Lee JH, Sung JY, Bae JI, Kim KT, Sim J, Baek SM, Kim YS, Shin JH, Park JS, Kim DW, Kim JH, Kim EK, Jung SL, Na DG; Korean Society of Thyroid Radiology. Complications encountered in the treatment of benign thyroid nodules with US-guided radiofrequency ablation: a multicenter study. *Radiology* 2012; 262: 335-342.
- [13] Wiggermann P, Zuber-Jerger I, Zausig Y, Loss M, Scherer MN, Schreyer AG, Stroszczyński C, Jung EM. Contrast-enhanced ultrasound improves real-time imaging of ablation region during radiofrequency ablation: preliminary results. *Clin Hemorheol Microcirc* 2011; 49: 43-54.
- [14] Bauer AJ. Thyroid nodules and differentiated thyroid cancer. *Endocr Dev* 2014; 26: 183-201.
- [15] Woodrum DT, Gauger PG. Role of ¹³¹I in the treatment of well differentiated thyroid cancer. *J Surg Oncol* 2005; 89: 114-121.
- [16] American Thyroid Association (ATA) Guidelines Taskforce on Thyroid Nodules and Differentiated Thyroid Cancer¹, Cooper DS, Doherty GM, Haugen BR, Kloos RT, Lee SL, Mandel SJ, Mazzaferri EL, McIver B, Pacini F, Schlumberger M, Sherman SI, Steward DL, Tuttle RM. Revised American Thyroid Association management guidelines for patients with thyroid nodules and differentiated thyroid cancer. *Thyroid* 2009; 19: 1167-1214.
- [17] Edmonds CJ, Hayes S, Kermodé JC, Thompson BD. Measurement of serum TSH and thyroid hormones in the management of treatment of thyroid carcinoma with radioiodine. *Br J Radiol* 1977; 50: 799-807.
- [18] Cheng W, Ma C, Fu H, Li J, Chen S, Wu S, Wang H. Low- or high-dose radioiodine remnant abla-

Radiofrequency ablation for postsurgical thyroid removal

- tion for differentiated thyroid carcinoma: a meta-analysis. *J Clin Endocrinol Metab* 2013; 98: 1353-1360.
- [19] Dupuy DE, Monchik JM, Decrea C, Pisharodi L. Radiofrequency ablation of regional recurrence from well-differentiated thyroid malignancy. *Surgery* 2001; 130: 971-977.
- [20] Park KW, Shin JH, Han BK, Ko EY, Chung JH. Inoperable symptomatic recurrent thyroid cancers: preliminary result of radiofrequency ablation. *Ann Surg Oncol* 2011; 18: 2564-2568.
- [21] Johansen K, Woodhouse NJ, Odugbesan O. Comparison of 1073 MBq and 3700MBq iodine-131 in postoperative ablation of residual thyroid tissue in patients with differentiated thyroid cancer. *J Nucl Med* 1991; 32: 252-254.
- [22] Bal C, Padhy AK, Jana S, Pant GS, Basu AK. Prospective randomized clinical trial to evaluate the optimal dose of 131I for remnant ablation in patients with differentiated thyroid carcinoma. *Cancer* 1996; 77: 2574-2580.
- [23] Mäenpää HO, Heikkonen J, Vaalavirta L, Tenhunen M, Joensuu H. Low vs. high radioiodine activity to ablate the thyroid after thyroidectomy for cancer: a randomized study. *PLoS One* 2008; 3: e1885.
- [24] Mallick U, Harmer C, Yap B, Wadsley J, Clarke S, Moss L, Nicol A, Clark PM, Farnell K, McCready R, Smellie J, Franklyn JA, John R, Nutting CM, Newbold K, Lemon C, Gerrard G, Abdel-Hamid A, Hardman J, Macias E, Roques T, Whitaker S, Vijayan R, Alvarez P, Beare S, Forsyth S, Kadalayil L, Hackshaw A. Ablation with low-dose radioiodine and thyrotropin alfa in thyroid cancer. *N Engl J Med* 2012; 366: 1674-1685.
- [25] Caglar M, Bozkurt FM, Akca CK, Vargol SE, Bayraktar M, Ugur O, Karaağaoğlu E. Comparison of 800 and 3700MBq iodine-131 for the postoperative ablation of thyroid remnant in patients with low-risk differentiated thyroid cancer. *Nucl Med Commun* 2012; 33: 268-274.
- [26] Li Li, Jin Jianhua, Lu Keyi, Liu jianzhong, et al. A meta-analysis of efficacy of iodine-131 for post-thyroidectomy ablation of remnants in patients with differentiated thyroid carcinoma. *Int J Radiat Med Nucl Med* 2014; 38: 152-156; 170. In Chinese.