

Case Report

Peutz-Jeghers syndrome with early onset of pre-adolescent gynecomastia: a predigree case report and clinical and molecular genetic analysis

Long-Jiang Zhang, Zhe Su, Xia Liu, Li Wang, Qin Zhang

Department of Endocrine, Shenzhen Children's Hospital, No. 7019 Yitian Road, Futian District, Shenzhen 518000, Guangdong, China

Received December 29, 2016; Accepted April 12, 2017; Epub May 15, 2017; Published May 30, 2017

Abstract: This study reports a case of Peutz-Jeghers syndrome with early onset of gynecomastia, and discusses its clinical characteristics and genetic changes in a family. The clinical characteristics of a child diagnosed with Peutz-Jeghers syndrome in our hospital and his parents were summarized, and related genes were detected in the child and his parents. Furthermore, the therapeutic effect of letrozole was also observed. A five-year-and-three-month-old male patient visited a doctor due to "progressive painless enlargements at bilateral breast for more than two years". The mother of the patient had breast hyperplasia and ovarian cysts, had no hematemeses and hematochezia history, and had two 1-mm pigmented spots on the palm side of the left thumb. The father of the patient revealed no abnormalities. In the child, luteinizing hormone (LH) release peak induced by luteinizing hormone releasing hormone (LHRH) excitation testing was 0.29 U/l, and follicle stimulating hormone (FSH) peak was 0.41 U/l. Karyotype: 46, XY. Gene sequencing revealed a mutation c.658C>T in the serine threonine kinase 11 (STK11) gene in the child and this mother, while the child's father was normal. After one year of oral administration of letrozole, the boy's breasts reduced to stage B2, bone age was 10 years and eight months old, and $\Delta\text{BA}/\Delta\text{CA}$ ratio was <1. The patient had early onset of pre-adolescent gynecomastia, had no obvious gastrointestinal symptoms, presented with a few pigmented spots in the skin mucosa, and was diagnosed with Peutz-Jeghers syndrome by genetic testing. Letrozole treatment can effectively control the development of breast and progression of bone age.

Keywords: Molecular genetics, gynecomastia, estrogen

Introduction

The main cause of gynecomastia is abnormally elevated levels of mammary stroma and terminal ducts in men induced by the absolute or relative increase in estrogen levels. The manifestation is breast enlargement, and breast tissue under the mammary areola can be felt in clinical practice. Gynecomastia can occur in some physiological states, and can also be pathological. Physiological gynecomastia mainly occurs in the neonatal period, puberty and old age; while pathological gynecomastia has a complex etiology, can be induced by liver, thyroid, gonadal and adrenal diseases, and can also be a manifestation of other syndromes. Due to the complex etiology, it is difficult to determine the exact causes of some pathological gynecomastia. In this report, a patient with

pre-adolescent gynecomastia as the early manifestation was admitted to our department and diagnosed with genetic Peutz-Jeghers syndrome (PJS) by genetic testing. These are reported as follows.

Case report

The patient was a five-year-and-three-month-old boy, who was born at the first pregnancy and first labor of his mother. The patient went to see a doctor due to the discovery of bilateral breast development for more than two years, and a painless progressive enlargement for six months. The patient usually has no galactorrhea, melena and bloody stools, and has no obvious symptoms such as abdominal pain. At approximately three years old, the parents found bilateral mastaxue in the boy of the

Rare peutz-Jeghers syndrome

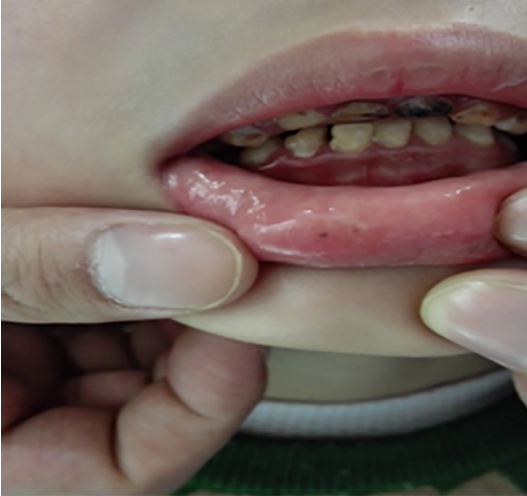

Figure 1. Pigmented spots under lip.




Figure 2. Pigmented spots at the lateral side of the right forefinger.

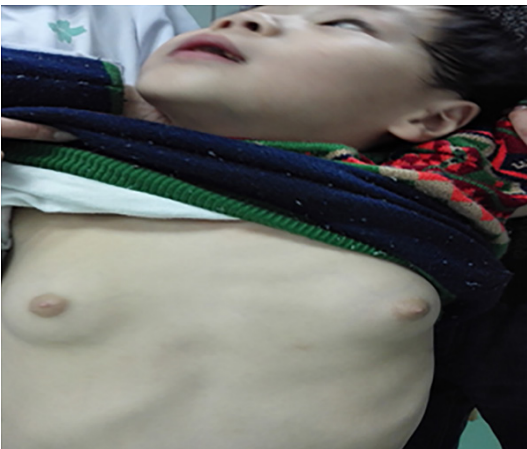

Figure 3. 3B stage of development of bilateral breasts in patients.

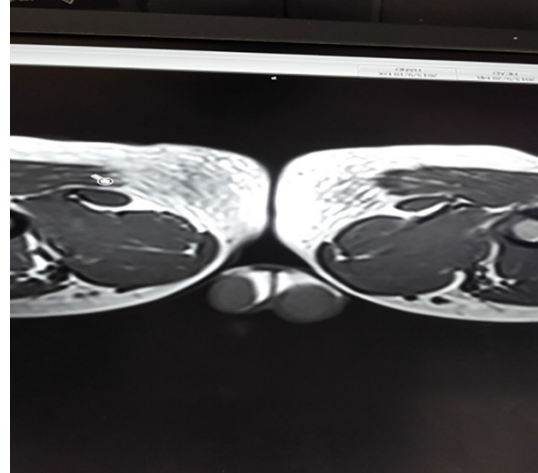


Figure 4. Magnetic resonance imaging (MRI) used to bilateral testes found nothing abnormal.

patient, but did not visit a doctor, since the boy had no discomfort. In the past six months, the breasts presented with progressive enlargement. Hence, the patient visited the Endocrinology Department of our hospital in August 2015. Since the onset the mental status of the patient was acceptable, and appetite and stool were not obviously abnormal, the patient did not take special drugs or eat tonic. Furthermore, the patient had no significant acceleration in height and weight gain. The patient had no family history of similar diseases.

Physical examinations: Height was 120.5 cm (+2 SD), weight was 21.8 kg, Body mass index (BMI) was 15 (fiftieth percentile), development was normal, nutritional status was medium, skin was white, two 1-mm pigmented spots were found at the lower lip mucosa and the lateral side of the right forefinger; no pigmented spots were found in other skin mucosa (**Figures 1 and 2**). The development of bilateral breasts was in stage B3, and the mammary areola was not colored (**Figure 3**). Heart, lung and abdomen examinations revealed no abnormalities. The patient had a male external genitalia, and bilateral testes were 3 ml in size, which had a relatively hard texture. The penis was 3.8 × 1.5 cm, and the development of pubic hair was in stage PH1. No pigmentation was found in the scrotum. The height of the patient's father was 175 cm, while the mother's height was 163 cm.

Adjuvant examinations: Bone age of the child was 10 years old. Karyotype: 46, XY. Breast

Rare peutz-Jeghers syndrome

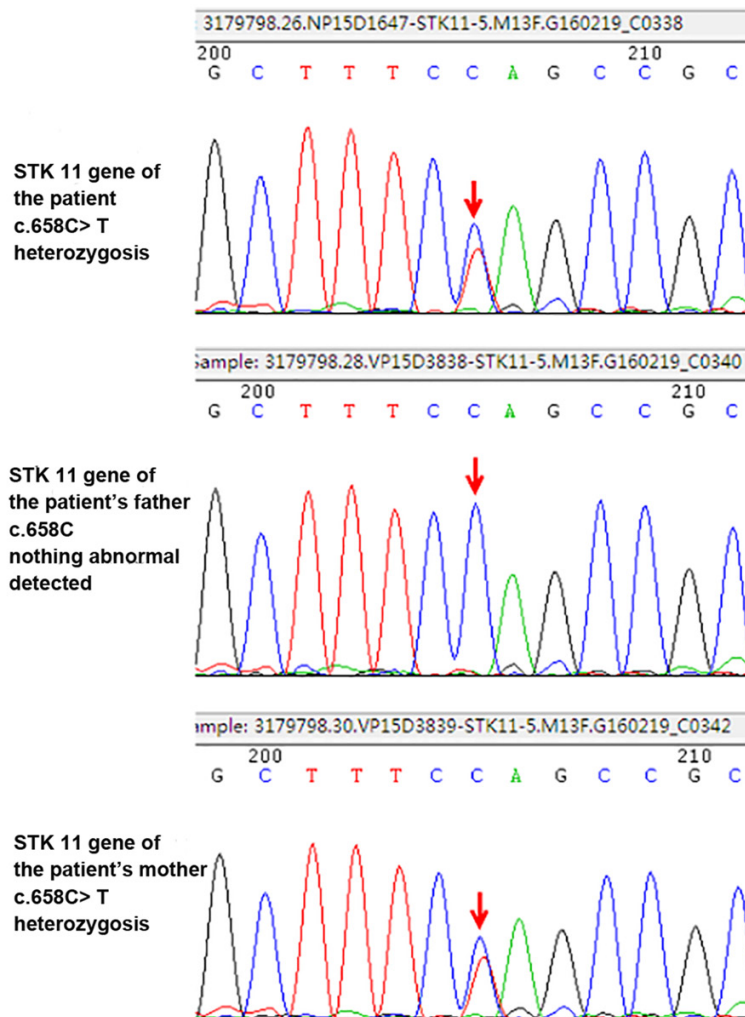


Figure 5. Gene sequencing of the patient and his parents by Sanger. The red arrow indicates the mutation site of the Exon-5 in STK11, c.658C>T p.(Gln220*), and the patient and his mother have the same mutation.

ultrasound revealed low echo masses in the bilateral breasts, and a small amount of breast duct and glandular tissue echoes were found in the surrounding area. Testicular B ultrasound revealed an increase in bilateral testicular volumes, with a size of 2.2 cm × 1.1 cm × 1.2 cm. Testicular parenchyma was uneven, exhibiting irregular flaky hypoechoic areas and patchy hyperechoic areas. Pelvic B ultrasound revealed no uterus and ovarian tissue. Enhanced and non-enhanced testicular magnetic resonance imaging (MRI) revealed no occupying lesions (**Figure 4**). Liver and kidney function, thyroid function, blood lipid, blood electrolytes were normal. Sex hormones: estradiol was 23 pg/ml, testosterone was 0 nmol/l, progesterone was 0.26 ng/ml, 8 AM cortisol was 8.73 ng/ml, 8 AM ACTH was 43.3 pg/ml, rostenedione was

<0.3 ng/ml, dehydroepian-drosterone sulfate was 1.1 ng/ml, and 17-hydroxyprogesterone was 0.23 ng/ml. LHRH excitation testing: LH release peak was 0.29 U/l, and FSH peak was 0.41 U/l. HCG excitation testing: Testosterone was 10.32 nmol/L after excitation. Non-enhanced and enhanced pituitary MRI revealed that pituitary height was approximately 5 mm, and no other abnormality was found at other parts.

The child's mother was 30 years old, had no history of obvious abdominal pains, bloody stools and melena; but had breast hyperplasia and ovarian cysts (from B ultrasound examination results, no surgery, no pathological results). Physical examination results: No pigmented spots were found on the oral mucosa, had two 1-mm pigmented spots on the palm side of the left thumb, and no pigmented spots on other skin mucosa. The father of the patient revealed no abnormalities.

After obtaining approval from the medical ethics committee of our hospital and a signed

agreement with the parents of the child, the peripheral blood of the child and his parents were drawn, and peripheral blood DNA was extracted through the column method (QIAamp Blood DNA Mini Kit, QiaGen, USA). Primers for all exon coding regions of the STK11 gene were designed using Premier 5.0 software, and 2 × PCR MasterMix polymerase (Tiangen Biotech, Beijing) was used for PCR amplification (ABI-9700 PCR system, Life Technology, USA). The direct sequencing of PCR products was performed (ABI3500 sequencing instrument, Life Technology, USA). The sequence was compared with the reference sequence recorded in GenBank, in order to detect possible gene mutations (DNA sequencing was performed by Guangzhou Jinyu Medical Examination Center Co. Ltd.).

Rare peutz-Jeghers syndrome

The PCR-DNA sequencing method was used to amplify all exons of the STK11 gene in the child and his parents. Then, these were directly sequenced. A heterozygous mutation c.6578C>T was detected in exon 5 (p.Gln 220*) of the STK11 gene (NM_000044.3) in the child. The mutation was a nonsense mutation, causing the 220th site that encodes amino acid (glutamine) of the gene to be replaced by a stop codon. This mutation was not recorded in the Thousands Human Genome Database, dbSNP database and ESP6500 database. A literature reported that this heterozygous mutation was detected in a PJS family [1]. Forecast software predicted that the mutation would lead to brachytmema of the protein encoded by the gene and loss of normal function. Sanger validation of the site was performed in the mother of the child, and the same mutation was detected; while no abnormality was detected in the father of the child. On the basis of clinical manifestations of the child, it was speculated that the mutation of the site is a pathogenic mutation (gene sequencing results are shown in **Figure 5**).

Discussion

PJS is a rare cancer-inducing autosomal dominant genetic disease characterized by skin mucosal melanoplakia and gastrointestinal multiple polyp, and is a ordinary incomplete dominant inheritance. No race and gender differences were found in this disease. The incidence was different in reports, ranging between 1/8,300-280,000 [2-4].

Mucosal pigmented spots occurred mainly in the lips, surrounding areas of the lips, buccal mucosa, nasolabial groove, finger and toe, palms and soles. It exhibits as black, brownish black or brown, with a size of approximately 1-5 mm. Furthermore, it is round or diamond, with clear boundaries, and is flat and non swelling. These spots may appear months after birth, but mostly appear before reaching 10 years old. The pigmented spots will change with age, and lighten or disappear in adolescence. Skin mucosal spots are found in 90% of patients, and no spots are found in very few patients [5, 6]. The skin pigmented spots were light in this child and his mother, which were only found in the lip mucosa and fingers, and were not found in other parts. In addition, gastrointestinal pol-

yps are found in more than 90% of patients. Polyps can occur in any part of the gastrointestinal tract, which are multiple; but are more common in the small intestine, colon, stomach and rectum, with various sizes. The median age of the first appearance of polyps is 11-13 years old, and symptoms appear before 20 years old in half of the patients. Polyps may be followed by intestinal obstruction, intussusception, rectal bleeding and canceration. The median age of the occurrence of intussusception is 15 years. Patients undergo surgical treatment due to intussusception or intestinal obstruction before 10 years old in 30% of children, and before 18 years old in 60% of patients [4, 7, 8].

Clinical manifestations of PJS vary greatly in children and adolescents. Some children present with abdominal pain, bloody stools, intussusception or prolapsed polyp in rectum, and anemia; while few children may present with gynecomastia [9, 10].

The risk of gastrointestinal and extra gastrointestinal (in the mammary gland, pancreas, testis, etc.) malignant tumors significantly increases in PJS patients. A report revealed that the age of occurrence of testicular cancer in PJS patients ranged between 3-20 years old, with an average age of nine years old; and all were Sertoli cell carcinoma [11, 12]. The testes of this child were over large, the texture was relatively hard, and B ultrasound revealed scattered irregular flaky hypoechoic areas and patchy hyperechoic areas. The possibility of a tumor (large-cell calcifying Sertoli cell tumors of the testes) was considered. Testicular MRI was conducted, and no abnormality was found. The doctor recommended a testicular biopsy, but the parents rejected.

Since the clinical manifestations of PJS patients vary significantly, some scholars suggest that pathological examination and STK11 gene detection should be the gold standard for the diagnosis of PJS [13]. Since the child and his mother had no intestinal bleeding, obvious abdominal pain and other manifestations of intestinal obstruction, the parents refused to let the child undergo colonoscopic and gastroscopic examinations.

The increase in activity of aromatizing enzyme in PJS patients induces increase in the transformation of 1, 4-androstendione derived from the

Rare peutz-Jeghers syndrome

suprarenal gland into theelin, and in the transformation of testosterone estradiol; leading to excess estrogen in the body, and subsequently gynecomastia and bone age progression [14, 15]. Some scholars believe that the increase in sensitivities of the growth plate and breast tissue to estrogen leads to accelerated growth, advance in bone age, and gynecomastia. The child exhibited breast development at approximately three years old, and visited a doctor in our hospital at five years and four months old. Bone age was 10 years old.

PJS is induced by mutations in the STK11 gene. The gene is located on 19P13.3, which mainly consists of three regions: N-terminal non-catalytic region (encoded by the 1th-49th amino acids), catalytic kinase region (encoded by the 49th-309th amino acids), and C-terminal non-catalytic regulatory region (encoded by the 309th-433th amino acids). The STK11 gene encodes the Liver Kinase B1 (LKB1) protein, while the inactivating mutation of STK11/LKB1 inhibits adenosine monophosphate-activated protein kinase (AMPK). The role of AMPK is to inhibit the mammalian target of rapamycin (mTOR). mTOR is a signal protein in the regular growth pathway of cells. STK11 directly inhibits the expression of mTOR by altering the TSC1-TSC2 complex in the the upstream of the mTOR signaling pathway. In PJS patients, the dysregulation of mTOR leads to tumor formation [16]. A study reported that the types and sites of mutations in the STK11 gene are related to the risk of complications. Saloch reported that truncate mutation and the number and size of polyps were related to the occurrence of cancers [17]. Wang *et al.* [18] reported that mutation in exon 7 was related to the abnormal increase in multiple gastrointestinal polyps. There is also a view that the sites and types of mutations in the STK11 gene do not increase cancer risk [19].

For PJS gastrointestinal polyps, there is a foreign consensus that regular reexamination, regular gastroscopy and colonoscopy should be performed. Polyps greater than 10 mm is recommended to be removed. Patients should understand the progression of polyps to prevent carcinogenesis, and that large polyps can be removed early to avoid intussusception or intestinal obstruction.

At present, there are no specific drugs for the treatment of PJS. For gynecomastia and the

advance of bone age, aromatizing enzyme inhibitors can be given. In this study, the child's bilateral breasts decreased three months after oral letrozole. At present, the child is orally taking letrozole for nearly a year, and the development of bilateral breasts is maintained in stage B2, which significantly decreased compared to that before treatment. At present, the height is 126.8 cm, and the bone age is 10 years and eight months old. The long-term efficacy of aromatizing enzyme inhibitors is unestablished. Graziella [10] reported that when PJS patients underwent anastrozole treatment, in the first year, the breasts significantly decreased, and in the second year the curative effect was not significant; and patients finally underwent surgical treatment. Crocker [20] reported that the use of aromatizing enzyme inhibitors could decrease or eliminate gynecomastia of PJS patients, reduce growth rate, and delay the progression of bone age. However, the long-term effects of aromatizing enzyme inhibitors need more accumulated data for verification.

Since mTOR plays a certain role in the tumorigenesis in PJS patients, some scholars believe that as a mTOR inhibitor, rapamycin may be applied in the treatment of PJS patients [16].

In summary, for children with preadolescent gynecomastia, doctors should conduct careful examination to achieve an etiological diagnosis as far as possible. Although the pigmented spots in specific sites of the skin, multiple gastrointestinal polyps and hereditary are the clinical characteristics of PJS patients, these vary greatly in children and adolescents. The patient in this report had early onset of gynecomastia, and light mucosal pigmented spots. For PJS children with gynecomastia, the application of aromatizing enzyme inhibitors has a certain effect in the improvement of breast enlargement and the acceleration of bone age in the short term.

Acknowledgements

Scientific and technological innovation committee of shenzhen (JCYJ20150403100317064).

Disclosure of conflict of interest

None.

Address correspondence to: Long-Jiang Zhang, Department of Endocrine, Shenzhen Children's Hospital, No. 7019 Yitian Road, Futian District, Shenzhen

Rare peutz-Jeghers syndrome

518000, Guangdong, China. Tel: +86 0755-8300-8331; E-mail: zhanglj2564@163.com

References

- [1] Gruber SB, Entius MM, Petersen GM, Laken SJ, Longo PA, Boyer R, Levin AM, Mujumdar UJ, Trent JM, Kinzler KW, Vogelstein B, Hamilton SR, Polymeropoulos MH, Offerhaus GJ and Giardiello FM. Pathogenesis of adenocarcinoma in Peutz-Jeghers syndrome. *Cancer Res* 1998; 58: 5267-5270.
- [2] Chen HM and Fang JY. Genetics of the hamartomatous polyposis syndrome: a molecular review. *Int J Colorectal Dis* 2009; 24: 865-874.
- [3] Gammon A, Jaspersen K, Kohlmann W and Burt RW. Hamartomatous polyposis syndromes. *Best Pract Res Clin Gastroenterol* 2009; 23: 219-231.
- [4] Giardiello FM and Trimbath JD. Peutz-Jeghers Syndrome and management recommendations. *Clin Gastroenterol Hepatol* 2006; 4: 408-415.
- [5] Mozaffar M, Sobhiyeh MR, Hasani M and Falah M. Peutz-Jeghers Syndrome without mucocutaneous pigmentation: a case report. *Gastroenterol Hepatol Bed Bench* 2012; 5: 169-173.
- [6] Tomas C, Soyer P, Dohan A, Dray X, Boudiaf M and Hoeffel C. Update on imaging of Peutz-Jeghers syndrome. *World J Gastroenterol* 2014; 20: 10864-10875.
- [7] Kopacova M, Tacheci I, Rejchrt S and Bures J. Peutz-Jeghers Syndrome: diagnostic and therapeutic approach. *World J Gastroenterol* 2009; 15: 5397-5408.
- [8] Hinds R, Philp C, Hyer W and Fell JM. Complications of childhood Peutz-Jeghers Syndrome: implications for Pediatric Screening. *J Pediatr Gastroenterol Nutr* 2004; 39: 219-220.
- [9] Huang ZH, Song Z, Zhang P, Wu J and Huang Y. Clinical feature, endoscopic polypectomy and STK11 gene mutation in a nine-month-old Peutz-Jeghers Syndrome Chinese infant. *World J Gastroenterol* 2016; 22: 3261-3267.
- [10] Di Grezia G, Romano T, De Francesco F, Somma F, Rea G, Grassi R and Gatta G. Breast ultrasound in the management of gynecomastia in Peutz-Jeghers syndrome in monozygotic twins: two case reports. *J Med Case Rep* 2014; 8: 440.
- [11] van Lier MG, Wagner A, Mathus-Vliegen EM, Kuipers EJ, Steyerberg EW and van Leerdam ME. High cancer risk in Peutz-Jeghers Syndrome: a systematic review and surveillance recommendation. *Am J Gastroenterol* 2010; 105: 1258-1264.
- [12] Giardiello FM, Brensinger JD, Tersmette AC, Goodman SN, Petersen GM, Booker SV, Cruz-Correa M and Offerhaus JA. Very high risk of cancer in familial Peutz-Jeghers Syndrome. *Gastroenterology* 2000; 119: 1447-1453.
- [13] Beggs AD, Latchford AR, Vasen HF, Moslein G, Alonso A, Aretz S, Bertario L, Blanco I, Bülow S, Burn J, Capella G, Colas C, Friedl W, Møller P, Hes FJ, Järvinen H, Mecklin JP, Nagengast FM, Parc Y, Phillips RK, Hyer W, Ponz de Leon M, Renkonen-Sinisalo L, Sampson JR, Stormorken A, Tejpar S, Thomas HJ, Wijnen JT, Clark SK and Hodgson SV. Peutz-Jeghers Syndrome: a systematic review and recommendations for management. *Gut* 2010; 59: 975-986.
- [14] Ham S, Meachem SJ, Choong CS, Charles AK, Baynam GS, Jones TW, Samarajeewa NU, Simpson ER and Brown KA. Overexpression of aromatase associated with loss of heterozygosity of the STK11 gene accounts for prepubertal gynecomastia in boys with Peutz-Jeghers Syndrome. *J Clin Endocrinol Metab* 2013; 98: E1979-1987.
- [15] Bulun SE, Noble LS, Takayama K, Michael MD, Agarwal V, Fisher C, Zhao Y, Hinshelwood MM, Ito Y and Simpson ER. Endocrine disorders associated with inappropriately high aromatase expression. *J Steroid Biochem Mol Biol* 1997; 61: 133-139.
- [16] Zbuk KM and Eeg C. Hamartomatous polyposis syndromes. *Nat Clin Pract Gastroenterol Hepatol* 2007; 4: 497-502.
- [17] Salloch H, Reinacher-Schick A, Schulmann K, Pox C, Willert J, Tannapfel A, Heringlake S, Goecke TO, Aretz S, Stemmler S and Schmiegel W. Truncating mutations in Peutz-Jeghers Syndrome are associated with more polyps, surgical interventions and cancers. *Int J Colorectal Dis* 2010; 25: 97-107.
- [18] Wang Z, Wu B, Mosig RA, Chen Y, Ye F, Zhang Y, Gong W, Gong L, Huang F, Wang X, Nie B, Zheng H, Cui M, Wang Y, Wang J, Chen C, Polydorides AD, Zhang DY, Martignetti JA and Jiang B. STK11 domain X1 mutations: candidate genetic drivers leading to the development of dysplastic polyps in Peutz-Jeghers Syndrome. *Hum Mutat* 2014; 35: 851-858.
- [19] Hearle N, Schumacher V, Menko FH, Olschwang S, Boardman LA, Gille JJ, Keller JJ, Westerman AM, Scott RJ, Lim W, Trimbath JD, Giardiello FM, Gruber SB, Offerhaus GJ, de Rooij FW, Wilson JH, Hansmann A, Möslein G, Royer-Pokora B, Vogel T, Phillips RK, Spigelman AD and Houlston RS. Frequency and spectrum of cancers in the Peutz-Jeghers Syndrome. *Clin Cancer Res* 2006; 12: 3209-3215.
- [20] Crocker MK, Gourgari E, Lodish M and Stratakis CA. Use of aromatase inhibitors in large cell calcifying sertoli cell tumors: effects on gynecomastia, growth velocity, and bone age. *J Clin Endocrinol Metab* 2014; 99: E2673-2680.