

## Original Article

# Effect of omiganan on colonic anastomosis healing in a rat model of peritonitis

Teresa Lorenzi<sup>1</sup>, Maria Michela Cappelletti Trombettoni<sup>2</sup>, Roberto Ghiselli<sup>2</sup>, Francesca Paolinelli<sup>1</sup>, Rosaria Gesuita<sup>3</sup>, Oscar Cirioni<sup>4</sup>, Mauro Provinciali<sup>5</sup>, Wojciech Kamysz<sup>6</sup>, Elzbieta Kamysz<sup>7</sup>, Cristiano Piangatelli<sup>8</sup>, Mario Castellucci MD<sup>1</sup>, Mario Guerrieri<sup>2</sup>, Manrico Morroni<sup>1,9</sup>

<sup>1</sup>Department of Experimental and Clinical Medicine, Section of Neuroscience and Cell Biology, School of Medicine, Università Politecnica delle Marche, Italy; <sup>2</sup>General Surgery and Surgery Methodology Clinic, Università Politecnica delle Marche, Ospedali Riuniti, Ancona, Italy; <sup>3</sup>Center of Epidemiology, Biostatistics and Medical Information Technology, Università Politecnica delle Marche, Italy; <sup>4</sup>Clinic of Infectious Diseases, Department of Biomedical Sciences and Public Health, Università Politecnica delle Marche, Ospedali Riuniti, Ancona, Italy; <sup>5</sup>Experimental Animal Models for Aging Units, Scientific Technological Area, I.N.R.C.A. I.R.R.C.S., Ancona, Italy; <sup>6</sup>Department of Inorganic Chemistry, Faculty of Pharmacy, Medical University of Gdansk, Gdansk, Poland; <sup>7</sup>Department of Organic Chemistry, Faculty of Chemistry, Medical University of Gdansk, Gdansk, Poland; <sup>8</sup>Division of Anesthesia and Resuscitation, Emergency Department, Ospedali Riuniti, Ancona, Italy; <sup>9</sup>Electron Microscopy Unit, Ospedali Riuniti, Ancona, Italy

Received January 23, 2017; Accepted May 21, 2017; Epub July 15, 2017; Published July 30, 2017

**Abstract:** Background: This study investigates the effects of the antimicrobial cationic peptide omiganan-alone and combined with the antibiotic imipenem-on colonic anastomosis healing in presence of intraperitoneal sepsis induced in a rodent model of cecal ligation and puncture (CLP). Methods: Forty male Wistar rats were divided into 5 groups of 8 animals. Group 1 (control group) underwent laparotomy and cecal mobilization and the next day received left colon anastomosis. In group 2 (CLP without treatment), group 3 (CLP + imipenem), group 4 (CLP + omiganan), and group 5 (CLP + omiganan + imipenem), the left colon anastomosis was performed the day after CLP. Imipenem and omiganan were administered by intraperitoneal injection immediately before anastomosis construction and subsequently at 24 h intervals until the 7th postoperative day, when rats were sacrificed. Anastomotic bursting pressure was measured in situ. Tissue samples were collected for determination of hydroxyproline content and histological characteristics. Results: Only rats receiving omiganan + imipenem displayed re-epithelialization, reduced neovascularization of granulation tissue, and a bursting pressure that was similar to that of controls. Omiganan-alone and combined with imipenem-was associated with a better control of inflammatory parameters than imipenem alone. In addition omiganan, like imipenem, counteracted the collagen depletion typical of sepsis. Conclusions: This experimental study demonstrates the efficacy of the new antimicrobial agent omiganan, alone and in combination with imipenem, in delaying the effects of intraperitoneal sepsis on colonic anastomosis healing and provides evidence of the value of omiganan as a therapeutic agent.

**Keywords:** Rat model of peritonitis, colonic anastomosis, omiganan, wound healing process, bursting pressure, hydroxyproline concentration

## Introduction

Gastrointestinal anastomoses are common surgical procedures where leakage constitutes a severe complication. Anastomosis healing is affected by several systemic and local factors; among them, peritoneal infection has a major impact in conditions such as colonic perforation caused by diverticular disease or colorectal cancer [1, 2]. Performance of a gastrointes-

tinal anastomosis in presence of peritonitis is a debated issue [3-5], as several surgeons consider a primary anastomosis performed in a patient with intra-abdominal infection as potentially hazardous [6, 7]. Healing of colonic anastomoses in presence of peritonitis is therefore an outstanding issue [8], and a variety of antimicrobial, anti-inflammatory, and antioxidant agents are being tested to prevent the systemic effects of infection-induced organ injury [9-13].

## Omiganan and colonic anastomosis healing in peritonitis

However, the efficacy of many of these agents on the failure rates of colonic anastomoses is still unclear.

Antimicrobial peptides have recently emerged as a class of antibiotics with therapeutic potential. These positively charged molecules, which act as natural defense mechanisms, have been isolated from a broad range of plants and animals. In addition to their constitutive expression, they are produced in response to molecules that are associated with pathogens, like lipopolysaccharides (LPSs) [14, 15]. Antimicrobial peptides have been demonstrated to have wide-spectrum activity against bacteria, fungi, and protozoa [16, 17]; for instance, several cationic peptides are able to inhibit macrophage-derived cytokine production in response to endotoxic LPSs and confer a degree of protection against lethal endotoxemia [18]. They act by binding to negatively charged LPS residues on the bacterial external membrane through electrostatic interactions with negatively charged phosphoryl groups and through hydrophobic interactions with lipid A acyl chains [19]. Moreover, they can induce transcription of several genes in eukaryotic cells, and appear to have multiple effects on the inflammatory response [14, 15, 18, 20, 21]. Recent investigations have documented that antimicrobial peptides, combined with traditional antibiotics, can accelerate the maturation of granulation to fibrous tissue through a strong biological action exerted on the epidermal and connective tissue components of the wound healing response [22, 23]. Among these molecules, omiganan (formerly MBI 226, an analog of indolicidin) is a topical cationic peptide that was originally purified from the cytoplasmic granules of bovine neutrophils [24]. Omiganan pentahydrochloride acts *in vitro* against a variety of microorganisms, including gram-positive and gram-negative bacteria and fungi [24]. It exerts a fast microbicidal effect by interacting with the cytoplasmic membrane of gram-positive and -negative bacteria [24]. The unique structure of omiganan (i.e. the presence of both positively charged and hydrophobic amino acids) represents the key prerequisite for its ability to interact with bacterial cytoplasmic membrane through a non-receptor-mediated mechanism [25], which is the same used by other cationic peptides to kill microorganisms [26]. Once bound, omiganan likely undergoes a conformational change, stabilizing its interaction with the

polar lipid heads and possibly initiating its insertion into the bilayer. This event results in membrane depolarization and cell death. In addition to membrane effects, omiganan exerts its antibacterial activity through inhibition of macromolecular synthesis of DNA, RNA and proteins [27]. A demonstration of the non enzymatic mechanism of action of omiganan comes from its exceptionally rapid bactericidal property [24] and the lack of resistance developed by the pathogens [25, 27].

Antimicrobial peptides exercise a synergistic action with antibiotics, suggesting that cationic peptides may have an adjuvant effect in patients receiving antimicrobial chemotherapy against antibiotic-resistant bacterial strains [14, 20].

The aim of this study was to assess the effects of the antimicrobial omiganan, alone and combined with the antibiotic imipenem, on the healing of colonic anastomoses in presence of peritonitis induced by cecal ligation and puncture (CLP) in a rat model.

The present findings document that omiganan exerts a beneficial effect on anastomosis healing in presence of sepsis.

### Materials and methods

#### *Drugs*

Imipenem (Merck, Sharp & Dohme, Milano, Italy) powder, dissolved in sterile distilled water according to the manufacturer's recommendations, was prepared fresh every day.

Omiganan was kindly provided by Prof. Wojciech Kamysz (Faculty of Pharmacy, Medical University of Gdansk, Gdansk, Poland). Its concentration was determined by measuring absorbance at 280 nm (extinction coefficient at 280 nm =  $1.72 \times 10^4 \text{ M}^{-1} \text{ cm}^{-1}$ ).

#### *Animals and surgical procedures*

Male Wistar rats (Harlan, Horst, The Netherlands) weighing 550-600 g were provided by I.N.R.C.A.-I.R.C.C.S., Ancona, Italy. They were housed in wire-bottom cages at room temperature with a 12 h light/dark cycle and free access to food and water. The surgical procedure, use of anesthesia, and animal care were in line with National Institutes of Health Guide for the Care

## Omiganan and colonic anastomosis healing in peritonitis

and Use of Laboratory Animals recommendations (publication no. 86-23, revised 1985, Bethesda, MD) and were approved by the Animal Research Ethics Committee of I.N.R.C.A.-I.R.C.C.S., Ancona. All efforts were made to minimize animal suffering.

Rats were placed in an anesthesia box that was filled with isoflurane (5%) mixed with 30% oxygen (O<sub>2</sub>) and 70% nitrous oxide (N<sub>2</sub>O). During the procedure, a similar mixture, where isoflurane was reduced to 2-3%, was inhaled through a mask. A heating pad with feedback control through a rectal probe was employed to keep body temperature at 37°C.

Surgery was performed under aseptic conditions. The abdomen was shaved and painted with iodine before performing a midline laparotomy incision. The feces were gently moved back by milking them up from the descending colon, the cecum was then ligated with 3-0 silk right below the ileocecal valve. The anterior mesenteric cecal portion was punctured twice below the ligature using a 22 gauge needle. Finally, the bowel was replaced into the abdominal cavity and the skin closed in two layers [28-30].

Rats were placed in individual cages within cabinets kept at constant temperature and ventilation, and maintained in standard laboratory conditions with free access to water and chow.

Animals were frequently checked by I.N.R.C.A.'s veterinarian for overall wellbeing, including apathetic behavior, anorexia, piloerection, and passage of stool; any suffering or symptoms of illness were recorded. Animals in excessive pain, indicating septic shock, were sacrificed in a CO<sub>2</sub> chamber as recommended by the Guide for the Care and Use of Laboratory Animals, and autopsy was performed to establish the cause of illness.

Then, 24 h from CLP, animals were anesthetized by an intra-muscular injection of ketamine/xylazine (40 mg/kg and 13 mg/kg, respectively), the abdomen was reopened, and intra-abdominal fluid samples were collected with swabs to check that peritonitis had developed. For quantitative bacterial evaluation in intra-abdominal fluid, each rat received an intraperitoneal injection of 10 ml sterile saline solution. Samples of peritoneal lavage fluid were serially diluted. For enumeration of devel-

oped colonies (CFU/ml), duplicate samples were plated and incubated in air and under anaerobic conditions at 35°C for 48 h. The limit of detection was < 1 log<sub>10</sub> CFU/ml. Peritoneal lavage was further continued with 40 ml of warm sterile saline solution. The left colon was then transected 3-4 cm above the peritoneal reflection, an end-to-end anastomosis was performed using one layer of interrupted 6-0 sutures, and the abdomen was closed [31]. Imipenem and omiganan were administered by intraperitoneal injection immediately before surgery and subsequently at 24 h intervals at the same dose. Buprenorphine 0.01 mg/kg was administered upon induction of anesthesia and then at 12 h intervals for 3 days. Animals were fed with standard rat chow and water. On the 7<sup>th</sup> postoperative day rats were killed in a CO<sub>2</sub> room. A 4 cm colon segment including the anastomosis and a proximal segment of normal adjacent colon was collected from each rat.

### *Study groups*

Animals were divided into 5 groups of 8 rats. Group 1 (control group) received laparotomy and cecal mobilization, and on the following day left colon anastomosis. In group 2 (CLP without treatment), group 3 (CLP + imipenem), group 4 (CLP + omiganan), and group 5 (CLP + omiganan + imipenem), the colon was anastomosed the day after CLP.

Rats in groups 3, 4, and 5 received respectively 20 mg/kg imipenem, 1 mg/kg omiganan, and 20 mg/kg imipenem + 1 mg/kg omiganan by intraperitoneal injection. The control group received tap water.

### *Tissue sample collection*

The colon segments including the anastomosis and proximal segments of normal adjacent colon were cut longitudinally and rinsed with saline solution to remove intestinal contents. One half of each sample was fixed for 24 h in 4% neutral buffered formalin at 4°C for histopathological analysis; the other half was immediately frozen in liquid nitrogen and stored at -80°C for hydroxyproline determination.

### *Histopathological analysis*

Fixed samples were dehydrated and embedded in paraffin; then, 3 µm serial sections were cut from each block. Sections were deparaffinized,

## Omiganan and colonic anastomosis healing in peritonitis

**Table 1.** Histological parameters of anastomotic wound healing, granulation tissue development, and local inflammatory response [32-34]

<i>1. Mucosal anastomotic re-epithelialization</i>				
Grade 0	Absence of epithelialization on the anastomotic line			
Grade 1	Incomplete coating of the anastomotic wound with a single layer of cells			
Grade 2	Complete coating of the anastomotic wound with a single layer of cells			
Grade 3	Complete re-epithelialization with granular epithelium			
<i>2. Inflammatory granuloma and granulation tissue formation</i>				
<i>Grade</i>	<i>Inflammatory cells</i>	<i>Neovascularization</i>	<i>Fibroblasts</i>	<i>Fibrosis formation</i>
Grade 1	Absence	Absence	Absence	Absence
Grade 2	Slight	Slight	Slight	Slight
Grade 3	Mild	Mild	Mild	Mild
Grade 4	Intense	Intense	Intense	Intense
<i>3. Muscle layer destruction</i>				
<i>Grade</i>	<i>Ischemic necrosis</i>	<i>Muscle layer continuity</i>	<i>Inflammatory infiltration</i>	
Grade 1	Absence	Complete interruption	Absence	
Grade 2	Slight	Muscle synechia	Slight	
Grade 3	Mild	Complete restitution	Mild	
Grade 4	—	—	Intense	
<i>4. Anastomotic wound inflammatory infiltration</i>				
<i>Grade</i>	<i>Neutrophils</i>	<i>Lymphocytes</i>	<i>Histiocytes</i>	<i>Giant cells</i>
Grade 1	Absence	Absence	Absence	Absence
Grade 2	Slight	Slight	Slight	Slight
Grade 3	Mild	Mild	Mild	Mild
Grade 4	Intense	Intense	Intense	Intense

rehydrated in xylene and a graded series of ethyl alcohols, and stained with hematoxylin-eosin for morphological examination. The fibrous tissue reaction was assessed with Heidenhain's AZAN trichrome.

Histological examination of the anastomoses was conducted by two investigators (M.M. and T.L.), who were blinded to group identity, using digitized micrographs generated by a video camera that was mounted on a light microscope and connected to a computer for image digitalization (Nikon, Firenze, Italy). Ten specimens per group were analyzed and 5 high-power fields per sample evaluated.

Anastomotic healing, granulation tissue formation, local inflammatory response, and neovascularity were assessed according to the histological parameters described by Houdart et al. [32] and Hutschenreiter et al. [33] as modified by García et al. [34] (**Table 1**).

### *Determination of hydroxyproline concentration*

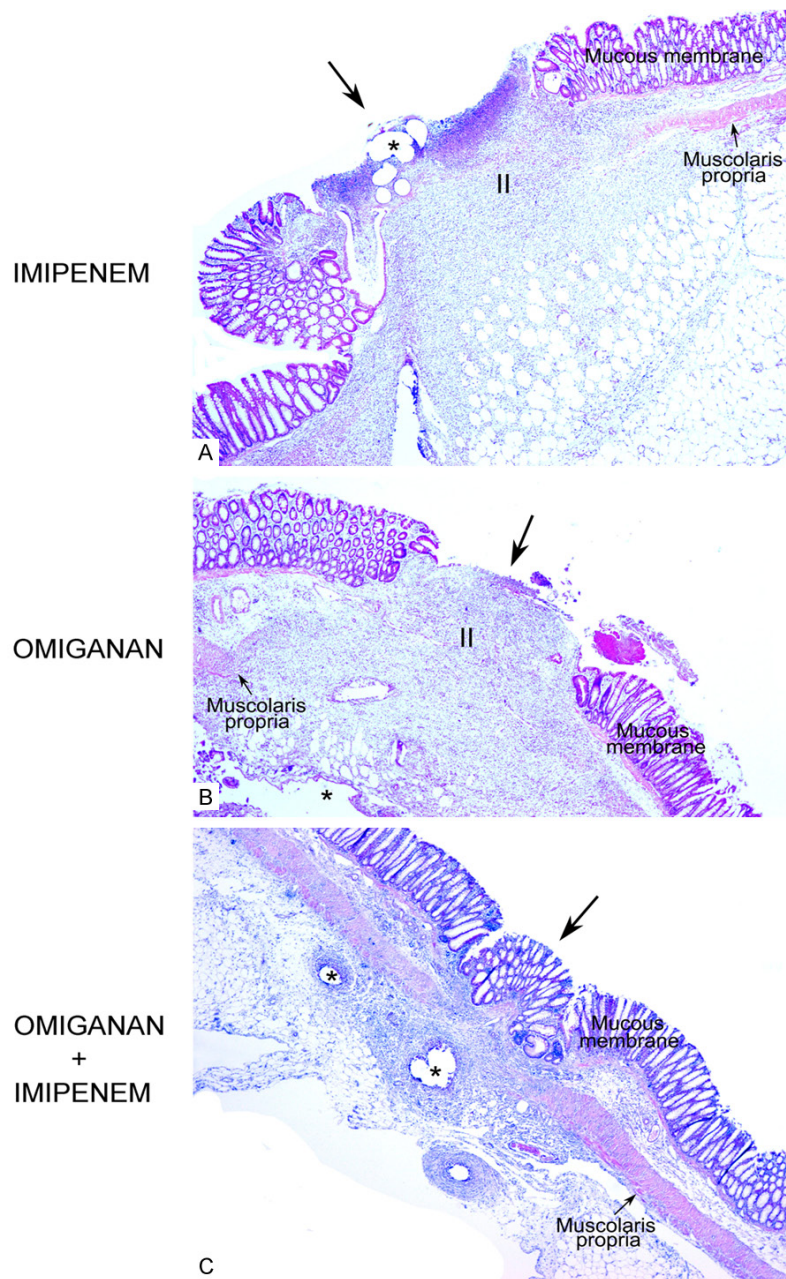
Total collagen was determined by measuring hydroxyproline concentration in each specimen

according to Reddy and Enwemeka [35], with some modifications.

Tissue samples were weighed and thoroughly homogenized in distilled water with a homogenizer (Ultra-Turrax T8, IKA®-WERKE, Lille, France). Extracts were cleared by centrifugation (20,000 x g). For alkaline hydrolysis, 40 µl was hydrolyzed in 4 M NaOH by autoclaving at 120°C for 90 min in thick-walled glass tubes. Samples were mixed gently with 450 µl of freshly prepared buffered chloramine-T reagent (0.056 M) (1.27 g chloramine T dissolved in 20 ml 50% n-propanol, brought to 100 ml with acetate citrate buffer, pH 6.0) and incubated for 1 h at room temperature. Subsequently, 500 µl of Ehrlich's reagent (1 M) (15 g of p-dimethylaminobenzaldehyde dissolved in n-propanol/perchloric acid 2:1 v/v, brought to 100 ml; made fresh daily) was added to each sample and mixed gently; the chromophore was developed by incubating the samples for 1 h at 65°C. The mixture was cooled and the color change evaluated by reading the absorbance at 550 nm with an Eppendorf BioSpectrometer UV/Vis spectrophotometer (Thermo Fisher Scientific, Milano, Italy).



## Omiganan and colonic anastomosis healing in peritonitis



**Figure 1.** Full thickness anastomotic tissue (hematoxylin-eosin). (A) group 3, imipenem; (B) group 4, omiganan; (C) group 5, omiganan + imipenem. Epithelialization at the anastomotic line is absent in (A) and (B); in (C) complete re-epithelialization with glandular epithelium is evident (long arrows). Asterisks indicate suture stitches. II: inflammatory infiltrate. Magnification: 20  $\times$ .

Hydroxyproline concentration in each tissue specimen was inferred from a standard calibration curve, obtained under the same conditions, using L-hydroxyproline. To normalize the data, protein concentration was assessed with the Bradford assay (Bio-Rad Laboratories, Milano, Italy) [36]. The relative hydroxyproline content was expressed as the ratio of hydroxy-

proline concentration ( $\mu\text{g}/\text{ml}$ ) to the protein concentration ( $\text{mg}/\text{ml}$ ) in each sample. Results were expressed as  $\mu\text{g}$  of hydroxyproline per  $\text{mg}$  of total protein.

Total collagen content was calculated based on the assumption that hydroxyproline accounts for 14% of the total amino acid content of collagen.

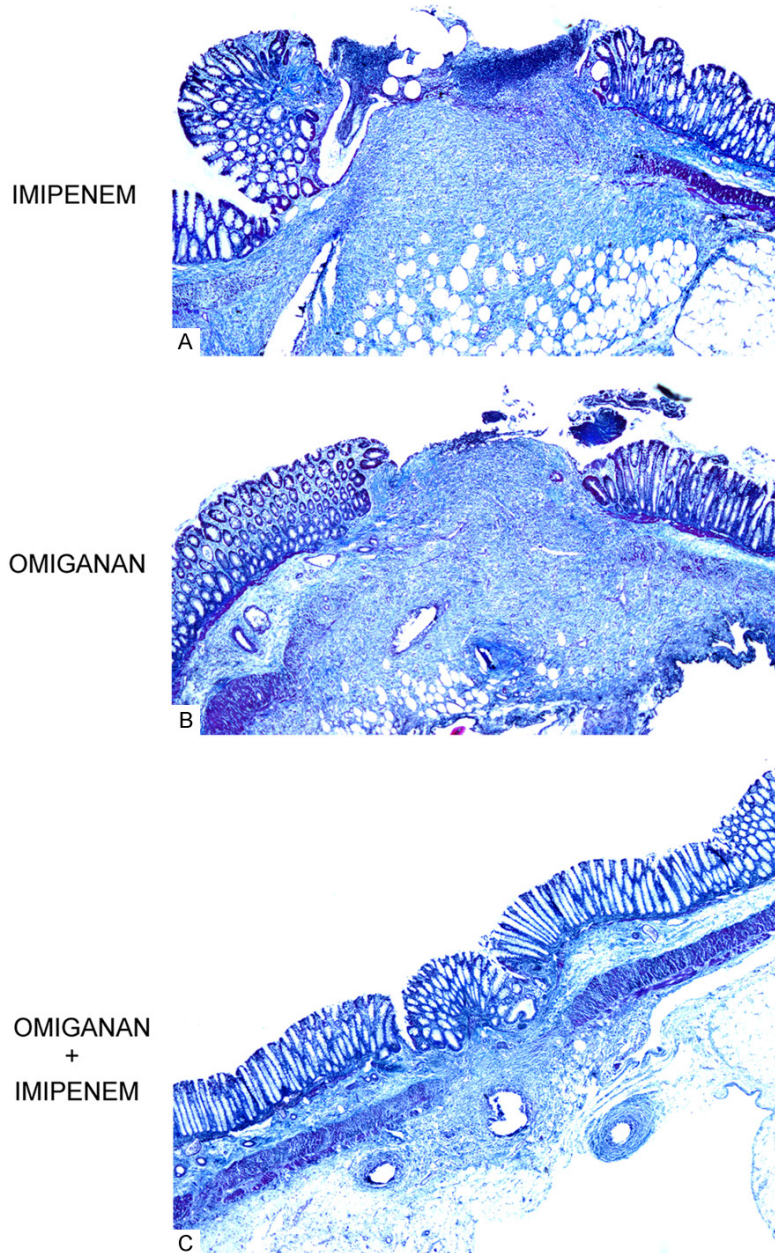
### *Anastomotic bursting pressure*

Anastomotic bursting pressure was measured in situ after sacrifice, carefully avoiding disturbing any adhesions formed around the anastomosis. The 4 cm colon segment straddling the anastomosis was flushed with saline to remove luminal contents. An 8 gauge silastic catheter was inserted through the proximal end of the segment and secured with 2/0 silk, taking care to not disturb the anastomosis [37], whereas the distal end was secured to a disposable pressure transducer (Edwards Lifesciences, Milano, Italy). Saline containing methyl blue was infused using a syringe pump Perfusor® Compact S (B-Braun, Milano, Italy) at a rate of 2 ml/min. Pressure was monitored with the pressure transducer and recorded with a Datex-Ohmeda S Multifunction apparatus (GE Healthcare, Milano, Italy).

The peak pressure documented before rupture was recorded as the anastomotic bursting pressure [38].

### *Statistical analysis*

A non-parametric approach was used to compare treatment groups, because variables were



**Figure 2.** Full-thickness anastomotic tissue (Heidenhain's AZAN trichrome). A: Group 3, imipenem; B: Group 4, omiganan; C: Group 5, omiganan + imipenem. Magnification: 20 ×.

not normally distributed (Shapiro test). Results were expressed as quartiles and graphically represented by box-plots. The Kruskal-Wallis test, a non-parametric analysis of variance, was performed to compare study groups. A level of probability of 0.05 was set for statistical significance. All the statistical analyses were performed using R statistical package (Foundation for Statistical Computing, Vienna, Austria).

## Results

### Macroscopic examination

The day after CLP, the bacterial cultures of peritoneal fluid demonstrated mixed aerobic and anaerobic bacteria, with *Escherichia coli* as the predominant organism.

All rats developed symptoms of sepsis such as lethargy, piloerection, exudation, and pus formation with filmy adhesions around the cecum. As regards post-operative mortality, all rats of group 2 (CLP without treatment) died of sepsis, as demonstrated by autopsy.

### Histopathological analysis


Mucosal re-epithelialization at the site of the anastomosis was detected only in group 5 rats (omiganan + imipenem), whereas it was not documented in the groups treated with either compound alone (Figures 1, 2). In group 5 re-epithelialization was similar to that seen in control animals (rats without peritonitis).

Inflammatory cells and neutrophils were significantly more abundant in group 3 (imipenem) than in the control group ( $P = 0.040$  and  $P = 0.043$ , respectively) (Figure 3).

In the rats treated with omiganan, alone or combined with imipenem, they were more numerous than in the control group but less numerous than in group 3, and the differences were not significant (Figure 3).

Lymphocytes and histiocytes were significantly less abundant in group 3 than in the control group ( $P = 0.019$  and  $P = 0.007$ , respectively)

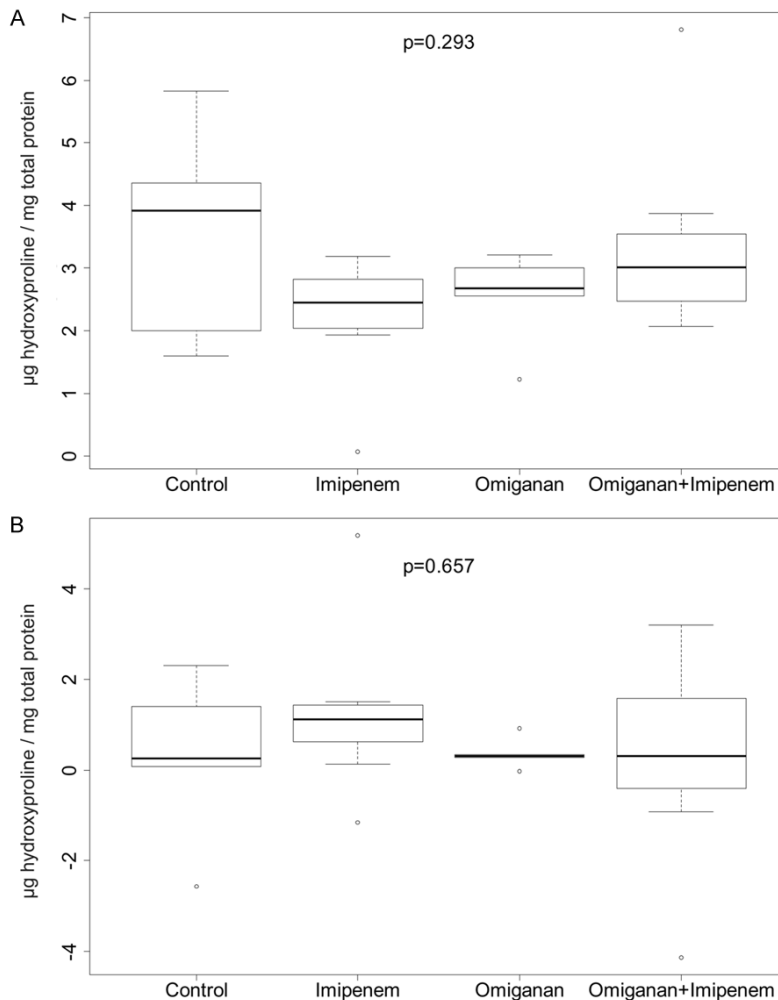
### Omiganan and colonic anastomosis healing in peritonitis



**Figure 3.** Histopathological analysis of the anastomosis according to the scores of Houdart et al [32] and Hutschenreiter et al [33] as modified by Garcia et al [34].



## Omiganan and colonic anastomosis healing in peritonitis



**Figure 4.** Hydroxyproline concentrations in anastomotic and perianastomotic tissue in rats treated with imipenem, omiganan, and omiganan + imipenem. A: Hydroxyproline concentration in anastomotic tissue. Comparison between the groups. B: Differences in hydroxyproline concentrations between anastomotic and perianastomotic tissue. Comparison between the groups. Neither comparison yielded significant differences.

(Figure 3), and roughly equal in the other groups (Figure 3).

Neovascularity at the site of the anastomosis was least evident in group 5 (omiganan + imipenem) (Figures 1-3) and was significantly different only between group 5 and group 4 (omiganan) ( $P = 0.017$ ) (Figure 3).

A similar number of giant cells were counted in rats treated with imipenem and omiganan, combined and alone, and in the control group (Figure 3).

Histopathological examination of the anastomosis disclosed no differences among groups

in terms of perianastomotic fibrosis, fibroblasts, or muscle layer destruction parameters (Figures 1, 2). Given the lack of intra- and intergroup variability, these data were not subjected to statistical analysis.

### *Hydroxyproline concentration*

The hydroxyproline concentrations measured in the tissue segments comprising the anastomosis were compared in the 5 groups of rats. To reduce the effect of interindividual variability, concentrations were first compared between anastomosis tissue and the adjacent tissue segment of each rat and subsequently between groups. Neither comparison yielded significant differences (Figure 4).

### *Anastomotic bursting pressure*

Breaks in the suture line were induced by saline infusion in all groups. Significantly different bursting pressures were measured between controls and rats treated with imipenem ( $P = 0.003$ ) or omiganan ( $P <$

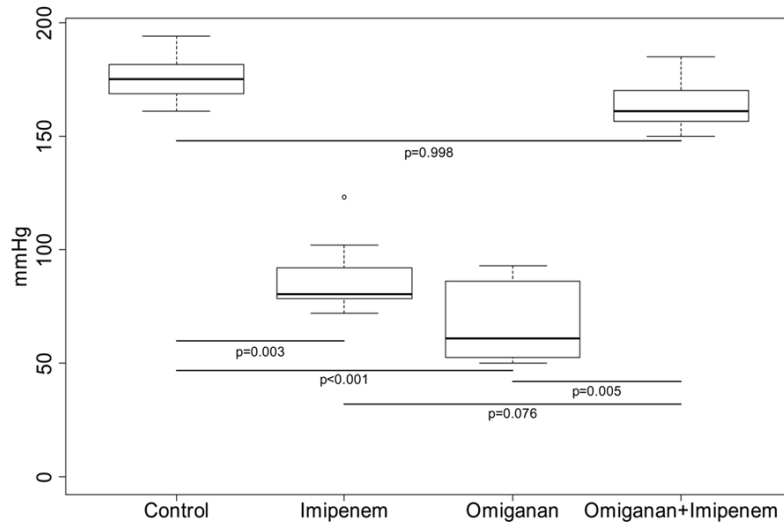
$0.001$ ), values being lower in the treated groups (Figure 5). Interestingly, in group 5 (omiganan + imipenem) bursting pressure was similar to that of controls and higher than the one measured in rats receiving a single drug (imipenem,  $P = 0.076$ ; omiganan,  $P = 0.005$ ) (Figure 5).

### **Discussion**

Intraperitoneal sepsis is a major surgical problem [39] that may be secondary to colon inflammation, as in diverticulitis and colitis [2]; less common causes include colon perforation due to cancer, trauma, incarcerated hernia, and intussusception [1, 8]. Such patients may require an intestinal anastomosis. However, con-



## Omiganan and colonic anastomosis healing in peritonitis



**Figure 5.** Anastomotic bursting pressure. The anastomotic bursting pressure in rats treated with omiganan + imipenem was similar to that of controls and higher than that measured in rats receiving a single drug.

structuring an intestinal anastomosis during an inflammatory process involves a high risk [3-7]. In the early healing phase of a colonic anastomosis, inflammation developing as a response to the injury and the foreign material (e.g. the suture) [40] induces production of cytokines (e.g. TNF- $\alpha$ , IL-1, IL-6) and reactive oxygen species [41, 42]. The inflammatory and chemo-attractant properties of the anastomosis result in accumulation, around the anastomosis, of sepsis-induced activated circulating and intra-peritoneal granulocytes, which compound the inflammatory reaction. Inflammation is a precondition for successful wound healing, because pathogen clearance without adverse consequences requires release of an appropriate amount of cytokines and inflammatory cells [43], whose imbalance may induce endothelial damage, hemodynamic and metabolic disruption, and death [39, 44]. In addition, granulocytes are a potential source of collagenase, a matrix metalloproteinase (MMP) responsible for the breakdown of collagen fibers [43]. Collagen is a protein with a key function throughout the healing process, due to its essential role in tissue integrity. Its turnover is integral to tissue repair [45, 46], which relies on formation of collagen fibrils to bridge the wound cleft. Even a modest disturbance in the balance of collagen synthesis, deposition, cross-linking, and MMP-mediated degradation may result in defective healing [39, 47-49]. An excessive inflammatory response increases collagenase

activity and impairs the synthesis of reparative collagen, resulting in a weaker anastomosis [42, 46]. The inflammation developing during peritonitis thus leads to defective wound healing and anastomotic dehiscence [39, 43, 50].

This study assesses the role of the peptide omiganan, alone or combined with the antibiotic imipenem, in delaying the effect of intra-peritoneal sepsis on colonic anastomosis healing using the CLP rat model. Omiganan shares the documented ability of anti-microbial peptides to acceler-

ate the healing process. Critically, such peptides induce a significant reduction in the fibrinous exudate and enhance epidermal reconstruction with thick granulation tissue and regular collagen deposition [14, 16, 21, 24]. Rat CLP is the most widely used animal model of intra-abdominal sepsis [51], because the rat cytokine profile is similar to the one described in human sepsis [52].

A limitation of the present study is that rats with peritonitis did not survive unless they were treated with omiganan and/or imipenem. For this reason, the control group was made up of rats without peritonitis, which showed a milder inflammatory condition; this is important when assessing the efficacy of omiganan, alone and combined with imipenem, in counteracting the effects of sepsis on anastomotic healing.

Over the first few days after its construction, the strength of the anastomosis depends on the hold of sutures on submucosal tissue; the risk of dehiscence is high even in procedures performed in optimal conditions [38, 40]. The design of this study involved sacrifice on the 7<sup>th</sup> postoperative day, because the 5<sup>th</sup> and 7<sup>th</sup> postoperative days are characterized by production of new matrix and peak collagen synthesis. In this proliferative phase, the strength of the anastomosis depends mainly on newly-formed organized collagen fibers [38, 40].

## Omiganan and colonic anastomosis healing in peritonitis

The present findings document that omiganan, both alone and combined with imipenem, counteracted peritoneal sepsis by inducing an inflammatory response whose cellular pattern was similar to the one seen in control rats without peritonitis. In particular the peptide, either alone and combined with imipenem, limited the recruitment of neutrophils, lymphocytes, and histiocytes, whose local levels were similar to those measured in the absence of peritonitis. Both acute and chronic inflammation thus appeared to be under control. The giant cell content in the area was also similar in rats treated with omiganan (with or without imipenem) and in the control group without peritonitis, highlighting its effectiveness in reducing granuloma formation. Notably, imipenem alone efficiently controlled only chronic inflammation and giant cell content.

There were no differences in fibroblast number or perianastomotic fibrosis among the groups, a finding that reflects the beneficial effect of treatment with omiganan and/or imipenem on anastomotic wound healing. However, only their combination induced re-epithelialization and reduced granulation tissue neovascularization, highlighting that only combined administration provides the stimulation required to restore tissue integrity in the wound area.

Since collagen content is considered the key element in tissue repair, hydroxyproline, an index of collagen deposition, was measured at the anastomosis site [38]. Its concentrations demonstrate that the two drugs, alone or combined, counteracted the collagen depletion typical of the inflammatory conditions induced by bacterial peritonitis. The restoration of bursting pressure, reflecting the healthy condition of the anastomotic wound, in rats receiving omiganan + imipenem showed that only combined administration was able to stop the harmful effects of sepsis-induced damage on collagen synthesis during wound healing.

Overall, the present findings indicate that imipenem alone is less effective in achieving colon anastomosis repair in presence of intraperitoneal sepsis than omiganan. The peptide, either alone and combined with imipenem, exerted a profound effect on the various components involved in the tissue healing process. Such strong impact on the histological parameters may be due to its ability to modulate the inflam-

matory response. Indeed, several recent studies have described the interaction of LPSs with different classes of cationic and amphipathic compounds such as omiganan [15, 18, 24]. These compounds can not only fight the infection, but also neutralize the biological effects of the inflammatory mediators by blocking LPSs. The reduced leukocyte activation and the improvement of all tissue healing parameters are secondary to the anti-inflammatory effects of omiganan.

### Conclusions

The present study demonstrates the value of omiganan in enhancing the safety of gastrointestinal anastomoses in rats with intraperitoneal sepsis. Further studies are needed to elucidate the actual mechanisms by which its protective effects are exerted.

Omiganan is the most advanced antimicrobial peptide tested to date [27]. Our findings highlight its clinical application potential, since successful healing of human colonic anastomoses would provide for safer gastrointestinal surgery.

### Acknowledgements

We are grateful to Word Designs ([www.silvi-amodena.com](http://www.silvi-amodena.com)) for the language revision. This study was supported by PRIN 2010 from Ministero dell'Istruzione, dell'Università e della Ricerca to MC and by grants from Università Politecnica delle Marche to RG (Ghiselli), RG (Gesuita), OC, MC, MG, MM.

### Disclosure of conflict of interest

None.

### Authors' contribution

TL: Histopathological analysis; data examination and interpretation; manuscript drafting. MMCT, CP: Surgical procedures; tissue sample collection; measurement of colonic anastomotic bursting pressure. RG (Ghiselli): Design and conceptualization of the study. FP: Determination of hydroxyproline. RG (Gesuita): Statistical analysis. OC, MP, MC, MG: Manuscript revision for intellectual content. WK, EK: Consultation on drug use. MM: Examination and interpretation of the data; manuscript revision for intellectual content.

## Abbreviations

CFU, colony forming unit; CLP, cecal ligation and puncture; I.N.R.C.A., Istituto Nazionale di Riposo e Cura per Anziani; I.R.C.C.S., Istituto di Ricovero e Cura a Carattere Scientifico; IL-1, interleukin-1; IL-6, interleukin-6; LPS, lipopolysaccharides; MMP, matrix metalloproteinase; TNF- $\alpha$ , tumor necrosis factor- $\alpha$ .

**Address correspondence to:** Drs. Teresa Lorenzi and Manrico Morroni, Department of Experimental and Clinical Medicine, Section of Neuroscience and Cell Biology, School of Medicine, Università Politecnica delle Marche, Via Tronto 10/a, 60020 Torrette, Ancona, Italy. Tel: +39 071 220 6085, +39 071 220 6270; Fax +39 071 220 6087; E-mail: teresalorenzi@yahoo.it; t.lorenzi@univpm.it (TL); m.morroni@univpm.it (MM)

## References

- [1] Zorcolo L, Covotta L, Carlomagno N, Bartolo DC. Safety of primary anastomosis in emergency colo-rectal surgery. *Colorectal Dis* 2003; 5: 262-269.
- [2] Wedell J, Banzhaf G, Chaoui R, Fischer R, Reichmann J. Surgical management of complicated colonic diverticulitis. *Br J Surg* 1997; 84: 380-383.
- [3] Salem L, Flum DR. Primary anastomosis or Hartmann's procedure for patients with diverticular peritonitis? A systematic review. *Dis Colon Rectum* 2004; 47: 1953-1964.
- [4] Biondo S, Jaurrieta E, Martí Ragué J, Ramos E, Deiros M, Moreno P, Farran L. Role of resection and primary anastomosis of the left colon in the presence of peritonitis. *Br J Surg* 2000; 87: 1580-1584.
- [5] Regenet N, Pessaux P, Hennekinne S, Lermite E, Tuech JJ, Brehant O, Arnaud JP. Primary anastomosis after intraoperative colonic lavage vs Hartmann's procedure in generalized peritonitis complicating diverticular disease of the colon. *Int J Colorectal Dis* 2003; 18: 503-507.
- [6] Wittmann DH, Schein M, Condon RE. Management of secondary peritonitis. *Ann Surg* 1996; 224: 10-18.
- [7] Koperna T. Surgical management of severe secondary peritonitis. *Br J Surg* 2000; 87: 378.
- [8] Runkel NS, Hinz U, Lehnert T, Buhr HJ, Herfarth Ch. Improved outcome after emergency surgery for cancer of the large intestine. *Br J Surg* 1998; 85: 1260-1265.
- [9] Sharma VK, Dellinger RP. Recent developments in the treatment of sepsis. *Expert Opin Investig Drugs* 2003; 12: 139-152.
- [10] Wang P, Gong G, Li Y, Li J. Hydroxyethyl starch 130/0.4 augments healing of colonic anastomosis in a rat model of peritonitis. *Am J Surg* 2010; 199: 232-239.
- [11] Bulbuloglu E, Ezberci F, Gul M, Kurutas EB, Bozkurt S, Kale IT, Ciragil P. Effects of the intraperitoneal lornoxicam on the formation of intraperitoneal adhesions in rat peritonitis model. *ANZ J Surg* 2005; 75: 1115-1119.
- [12] Pinsky MR. Antioxidant therapy for severe sepsis: promise and perspective. *Crit Care Med* 2003; 31: 2697-2698.
- [13] Thiernemann C. Membrane-permeable radical scavengers (tempol) for shock, ischemia-reperfusion injury, and inflammation. *Crit Care Med* 2003; 31 Suppl 1: S76-S84.
- [14] Cirioni O, Ghiselli R, Silvestri C, Kamysz W, Orlando F, Mocchegiani F, Di Matteo F, Riva A, Lukasiak J, Scalise G, Saba V, Giacometti A. Efficacy of tachyplesin III, colistin, and imipenem against a multiresistant *Pseudomonas aeruginosa* strain. *Antimicrob Agents Chemother* 2007; 51: 2005-2010.
- [15] Cirioni O, Silvestri C, Ghiselli R, Orlando F, Riva A, Mocchegiani F, Chiodi L, Castelletti S, Gabrielli E, Saba V, Scalise G, Giacometti A. Protective effects of the combination of alpha-helical antimicrobial peptides and rifampicin in three rat models of *Pseudomonas aeruginosa* infection. *J Antimicrob Chemother* 2008; 62: 1332-1338.
- [16] Hancock RE, Diamond G. The role of cationic antimicrobial peptides in innate host defenses. *Trends Microbiol* 2000; 8: 402-410.
- [17] Drabick JJ, Bhattacharjee AK, Hoover DL, Siber GE, Morales VE, Young LD, Brown SL, Cross AS. Covalent polymyxin B conjugate with human immunoglobulin G as an antiendotoxin reagent. *Antimicrob Agents Chemother* 1998; 42: 583-588.
- [18] Ghiselli R, Giacometti A, Cirioni O, Mocchegiani F, Viticchi C, Scalise G, Saba V. Cationic peptides combined with betalactams reduce mortality from peritonitis in experimental rat model. *J Surg Res* 2002; 108: 107-111.
- [19] Hancock RE. Cationic peptides: effectors in innate immunity and novel antimicrobials. *Lancet Infect Dis* 2001; 1: 156-164.
- [20] Cirioni O, Silvestri C, Ghiselli R, Orlando F, Riva A, Gabrielli E, Mocchegiani F, Cianforlini N, Trombettoni MM, Saba V, Scalise G, Giacometti A. Therapeutic efficacy of buforin II and rifampin in a rat model of *Acinetobacter baumannii* sepsis. *Crit Care Med* 2009; 37: 1403-1407.
- [21] Giacometti A, Cirioni O, Ghiselli R, Mocchegiani F, Viticchi C, Orlando F, D'Amato G, Del Prete MS, Kamysz W, Lukasiak J, Saba V, Scalise G. Antiendotoxin activity of protegrin analog IB-

## Omiganan and colonic anastomosis healing in peritonitis

- 367 alone or in combination with piperacillin in different animal models of septic shock. *Peptides* 2003; 24: 1747-1752.
- [22] Ghiselli R, Giacometti A, Cirioni O, Mocchegiani F, Orlando F, Silvestri C, Di Matteo F, Abbruzzetti A, Scalise G, Saba V. Efficacy of the bovine antimicrobial peptide indolicidin combined with piperacillin/tazobactam in experimental rat models of polymicrobial peritonitis. *Crit Care Med* 2008; 36: 240-245.
- [23] Giacometti A, Cirioni O, Ghiselli R, Orlando F, Kamysz W, Rocchi M, D'Amato G, Mocchegiani F, Silvestri C, Łukasiak J, Saba V, Scalise G. Effects of pexiganan alone and combined with betalactams in experimental endotoxic shock. *Peptides* 2005; 26: 207-216.
- [24] Sader HS, Fedler KA, Rennie RP, Stevens S, Jones RN. Omiganan pentahydrochloride (MBI 226), a topical 12-amino-acid cationic peptide: spectrum of antimicrobial activity and measurements of bactericidal activity. *Antimicrob Agents Chemother* 2004; 48: 3112-3118.
- [25] Melo MN, Castanho MA. Omiganan interaction with bacterial membranes and cell wall models. Assigning a biological role to saturation. *Biochim Biophys Acta* 2007; 1768: 1277-1290.
- [26] Hancock RE, Rozek A. Role of membranes in the activities of antimicrobial cationic peptides. *FEMS Microbiol Lett* 2002; 206: 143-149.
- [27] Melo MN, Dugourd D, Castanho MA. Omiganan pentahydrochloride in the front line of clinical applications of antimicrobial peptides. *Recent Pat Antiinfect Drug Discov* 2006; 1: 201-207. Review.
- [28] Wichterman KA, Baue AE, Chaudry IH. Sepsis and septic shock: a review of laboratory models and a proposal. *J Surg Res* 1980; 29: 189-201.
- [29] Rittirsch D, Huber-Lang MS, Flierl MA, Ward PA. Immunodesign of experimental sepsis by cecal ligation and puncture. *Nat Protoc* 2009; 4: 31-36.
- [30] Scheiermann P, Hoegl S, Revermann M, Ahluwalia D, Zander J, Boost KA, Nguyen T, Zwissler B, Muhl H, Hofstetter C. Cecal ligation and incision: an acute onset model of severe sepsis in rats. *J Surg Res* 2009; 151: 132-137.
- [31] Komen N, van der Wal HC, Ditzel M, Kleinrensink GJ, Jeekel H, Lange JF. Colorectal anastomotic leakage: a new experimental model. *J Surg Res* 2009; 155: 7-12.
- [32] Houdart R, Lavergne A, Galian A, Hautefeuille P. Anatomic-pathological evolution of single-layer end-to-end digestive anastomoses. A study of 210 colonic anastomoses in rats from the 2nd to the 180th day. *Gastroenterol Clin Biol* 1983; 7: 465-473.
- [33] Hutschenreiter G, Haina D, Paulini K, Schumacher G. Wound healing after laser and red light irradiation. *Z Exp Chir* 1980; 13: 75-85.
- [34] García JC, Arias J, García C, Vara E, Balibrea JL. Modification of inflammatory mediators in intestinal ischemia reperfusion in a model of type II diabetes. *Cir Esp* 2002; 71: 276-286.
- [35] Reddy GK, Enwemeka CS. A simplified method for the analysis of hydroxyproline in biological tissues. *Clin Biochem* 1996; 29: 225-229.
- [36] Bradford MM. A rapid and sensitive method for the quantitation of microgram quantities of protein utilizing the principle of protein-dye binding. *Anal Biochem* 1976; 72: 248-254.
- [37] Colak T, Dag A, Turkmenoglu O, Polat A, Comelekoglu U, Bagdatoglu O, Polat G, Akca T, Sucullu I, Aydin S. The effect of octreotide on healing of injured colonic anastomosis with immediate postoperative intraperitoneal administration of 5-Fluorouracil. *Dis Colon Rectum* 2007; 50: 660-669.
- [38] Hendriks T, Mastboom WJ. Healing of experimental intestinal anastomoses. Parameters for repair. *Dis Colon Rectum* 1990; 33: 891-901.
- [39] Angus DC, Linde-Zwirble WT, Lidicker J, Clermont G, Carcillo J, Pinsky MR. Epidemiology of severe sepsis in the United States: analysis of incidence, outcome, and associated costs of care. *Crit Care Med* 2001; 29: 1303-1310.
- [40] Thornton FJ, Barbul A. Healing in the gastrointestinal tract. *Surg Clin North Am* 1997; 77: 549-573.
- [41] Ordoñez CA, Puyana JC. Management of peritonitis in the critically ill patient. *Surg Clin North Am* 2006; 86: 1323-1349.
- [42] Essani NA, Fisher MA, Farhood A, Manning AM, Smith CW, Jaeschke H. Cytokine-induced up-regulation of hepatic intercellular adhesion molecule-1 messenger RNA expression and its role in the pathophysiology of murine endotoxin shock and acute liver failure. *Hepatology* 1995; 21: 1632-1639.
- [43] Ravanti L, Kähäri VM. Matrix metalloproteinases in wound repair (review). *Int J Mol Med* 2000; 6: 391-407.
- [44] Baue AE, Durham R, Faist E. Systemic inflammatory response syndrome (SIRS), multiple organ dysfunction syndrome (MODS), multiple organ failure (MOF): are we winning the battle? *Shock* 1998; 10: 79-89.
- [45] Ho YH, Ashour MA. Techniques for colorectal anastomosis. *World J Gastroenterol* 2010; 16: 1610-1621.
- [46] Thornton FJ, Barbul A. Healing in the gastrointestinal tract. *Surg Clin North Am* 1997; 77: 549-573.
- [47] de Hingh IH, de Man BM, Lomme RM, van Goor H, Hendriks T. Colonic anastomotic strength



## Omiganan and colonic anastomosis healing in peritonitis

- and matrix metalloproteinase activity in an experimental model of bacterial peritonitis. *Br J Surg* 2003; 90: 981-988.
- [48] Kuzu MA, Tanik A, Kale IT, Aşlar AK, Köksoy C, Terzi C. Effect of ischemia/reperfusion as a systemic phenomenon on anastomotic healing in the left colon. *World J Surg* 2000; 24: 990-994.
- [49] Christensen H, Chemnitz J, Christensen BC, Oxlund H. Collagen structural organization of healing colonic anastomoses and the effect of growth hormone treatment. *Dis Colon Rectum* 1995; 38: 1200-1205.
- [50] Benjamim CF, Hogaboam CM, Kunkel SL. The chronic consequences of severe sepsis. *J Leukoc Biol* 2004; 75: 408-412.
- [51] Buras JA, Holzmann B, Sitkovsky M. Animal models of sepsis: setting the stage. *Nat Rev Drug Discov* 2005; 4: 854-865.
- [52] Remick DG, Newcomb DE, Bolgos GL, Call DR. Comparison of the mortality and inflammatory response of two models of sepsis: lipopolysaccharide vs. cecal ligation and puncture. *Shock* 2000; 13: 110-116.