

Case Report

A protracted primary cutaneous nocardiosis due to *Nocardia otitidiscaviarum*

Bingyan Zhang, Yaojie Shen, Jingwen Ai, Lingyun Shao, Wenhong Zhang, Jialin Jin

Department of Infectious Diseases, Huashan Hospital, Fudan University, No 12 Wulumuqi Middle Road, Shanghai 200040, China

Received April 2, 2016; Accepted October 13, 2016; Epub January 15, 2017; Published January 30, 2017

Abstract: *Nocardia otitidiscaviarum* was seldom reported to cause primary cutaneous nocardiosis, which is difficult to diagnosis due to its nonspecific clinical features. Misdiagnosis of the disease could result in inappropriate treatment and chronic protracted lesions. In this report, we described a previously misdiagnosed case of primary cutaneous nocardiosis caused by *N. otitidiscaviarum* in a 30-year-old, immune-sufficient male patient. The culture of the lesion pus revealed gram-positive and partially acid-fast positive bacilli. The analysis of 16S ribosomal RNA gene of the isolates showed 100% similarity with the type strain of *N. otitidiscaviarum* ATCC 14629. The patient was cured after 3 months of treatment with doxycycline and trimethoprim-sulfamethoxazole. We also presented a brief review of the literatures on *N. otitidiscaviarum* and summarized the features of cutaneous infection of this bacteria.

Keywords: Primary cutaneous nocardiosis, *Nocardia otitidiscaviarum*, immunocompetent

Introduction

Chronic infections of the skin and soft tissue are not commonly observed in the clinical practice, and an early, accurate diagnosis of the causative pathogens is essential for an effective treatment strategy. Apart from some common bacteria and fungus, several microorganisms should also be considered in such situations, including tuberculosis, atypical mycobacterial infections, leprosy, syphilis, and actinomycosis. *Nocardia* species, a group of opportunistic pathogens, belongs to a suborder of actinomycetes that can cause lymphocutaneous infection, superficial cellulitis, and localized abscess [1]. The clinical features of the *Nocardia* infection are usually nonspecific and the identification of the bacteria can be difficult due to the low culture positive rate. Therefore, physicians face the challenge in both the diagnosis and the treatment of this pathogen. In this article, we reported a case of primary cutaneous nocardiosis with protracted ulceration and exudate for six years caused by *N. otitidiscaviarum* and summarized the features of cutaneous infection by this infrequent pathogen.

Case report

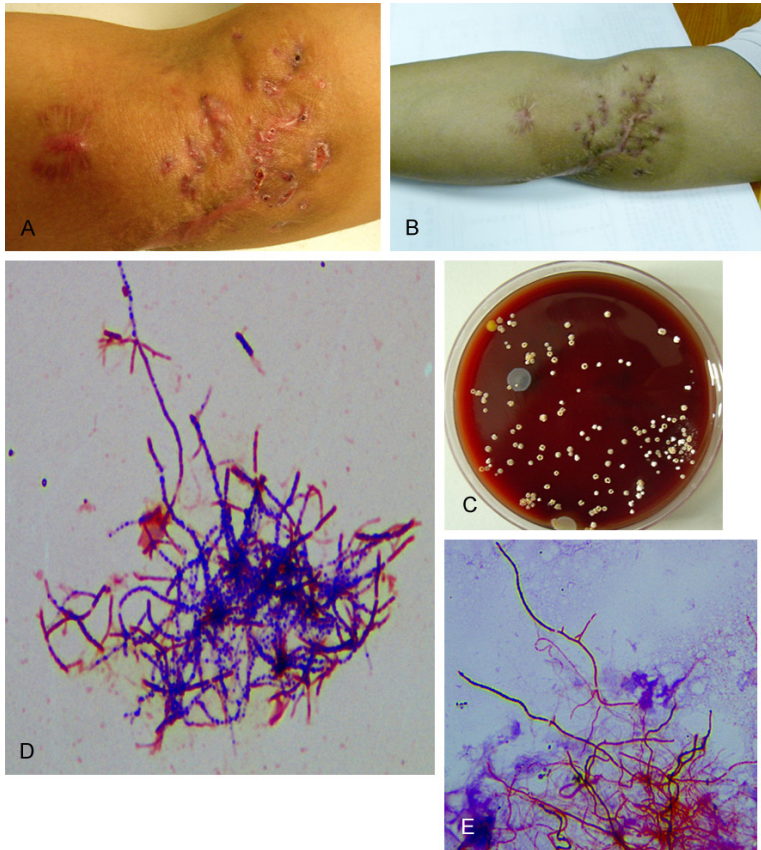
A 30-year-old man was presented to our hospital, and complained of repeated local suppurative exudates on his right elbow for the past six years. The patients reported having had right elbow laceration in a motorcycle accident and received surgical debridement at a local clinic 12 years ago. Six years later, he first found a nodule at the surgical site on his right elbow, with no tenderness and erythema observed. He went to the local clinic and received abscesses drainage in which yellow pus was drained out. The lesion was later resolved. However, the cutaneous abscess developed repeatedly and continued to expand in size. Multiple surgical debridement were performed in the following years. Four years later, the patient underwent skin biopsy, and the result revealed "purulent inflammation of soft tissue infiltrated with lymphocyte, plasma cells, neutrophils, and bacterial foci were seen as well". At the same time, the result of all the pus cultures came back negative.

One year before admission, because of his refractory condition and positive tuberculin skin

Primary cutaneous nocardiosis

Table 1. The management and therapeutic effect of the patient within 6 years before admission

Years before admission	Management	Therapeutic effect
6 years	Drainage of the abscess	Abscess resolved but recurred.
2 to 6 years	Multiple surgical debridement	Recurrent abscesses developed and expanded in size.
2 years	Skin biopsy and pus culture	Bacterial foci were seen. But all the pus cultures were negative.
1 years	Rifampicin, isoniazid, ethambutol and pyrazinamide for eight months	Nodules developed recurrently which drained later.



F
Nocardia otitidiscaviarum strain ATCC 14629 16S ribosomal RNA gene, partial sequence
 Sequence ID: [ref|NR_115836.1](#) Length: 1434 Number of Matches: 1

Range 1: 51 to 1393 [GenBank](#) [Graphics](#)

Score	Expect	Identities	Gaps	Strand
2481 bits(1343)	0.0	1343/1343(100%)	0/1343(0%)	Plus/Plus

Figure 1. Primary cutaneous nocardiosis due to *Nocardia otitidiscaviarum*. A. Multifocal ulcerations covered by bloody exudate on the right elbow upon arrival at the hospital. B. The healed lesion after 3-month treatment. C. 5% sheep blood agar showing dry, rough, raised, and yellowish *Nocardia* colonies. D. Gram stains showing gram-positive, thin, branching, filamentous bacilli. E. Modified acid-fast stain using weak acid for decoloration showing partially acid-fast bacilli. F. Analysis using BLAST program in the GenBank database showing 16S rRNA gene of the isolate and type strain *N. otitidiscaviarum* ATCC 14629 had 100% similarity

test result, the patient was diagnosed tuberculosis and prescribed with rifampicin, isoniazid, ethambutol and pyrazinamide. However, the

patient developed nodules recurrently on his elbow, which was drained later, and the treatment was discontinued after 8 months (Table 1). The patient was then transferred to our hospital.

Upon arrival, the patient's temperature was 37.9°C. On local cutaneous examination, multifocal ulcerations covered by bloody exudates on the right elbow were noted (Figure 1A), and the ulcerations were surrounded by pigmented and scarred periphery. Superficial lymph nodes were not palpable. The complete blood count tests were normal and the erythrocyte sedimentation rate was 2 mm/h. A comprehensive metabolic panel, including blood sugar, urea and creatinine, was all within normal limits. ELISA for HIV and T-SPOT. TB were negative. Skin biopsy yielded focal acanthosis with acanthosis and perivascular infiltration with lymphocytes and some plasma cells were found in both the superficial and deep layer of dermis.

Pus culture on the 5% sheep blood agar reported the growth of small, white or brown, irregular colonies at the eighth day of the inoculation (Figure 1C). Upon microscopic examination, the organisms were observed to be gram-positive, thin, branching, filamentous bacilli (Figure 1D) and partially acid-fast with modified acid-fast stain using weak acid for

Primary cutaneous nocardiosis

Table 2. Characteristics of reported cases of lymphocutaneous nocardiosis

Num	Age/sex	Underlying condition	Disease duration	Injury	Drug susceptibility	Drug resistance	Treatment regimen	Treatment duration	Outcome
1	65/F [5]	Breast cancer, IS	-	Yes	Gentamicin, tobramycin, amikacin, minocycline, doxycycline, TMP-SMX (50% strains), moxifloxacin, linezolid, tigecycline,	Ampicillin, amoxicillin clavulanate, imipenem, cephalosporins, clarithromycin, ciprofloxacin	Levofloxacin	-	Cure
2	47/M [5]	Renal transplant, IS	-	Yes			Linezolid	-	Cure
3	82/M [5]	None	-	Yes			Minocycline	-	Cure
4	77/M [5]	Lung cancer, IS	-	Yes			Ciprofloxacin, linezolid	-	Cure
5	31/M [6]	None	10 days	Yes	TMP-SMX, imipenem, amikacin, kanamycin	Penicillins, cephalosporins, quinolones, erythromycin, clindamycin, tetracycline, chloramphenicol, fosfomycin, vancomycin, tobramycin	TMP-SMX, imipenem	8 weeks	Cure
6	70/M [7]	Rheumatoid arthritis, IS	2 weeks	Yes	-	-	Ofloxacin, clindamycin	3 months	Cure
7	69/F [8]	None	12 days	Yes	-	-	TMP-SMX	6 months	Cure
8	60/M [9]	COPD	1 month	Yes	Amikacin, minocycline, linezolid	-	Amikacin, linezolid	3 months	Cure
9	86/M [10]	None	2 weeks	Yes	TMP-SMZ	-	TMP-SMZ	10 weeks	Cure
10	78/F [11]	Bronchial asthma, IS	3 days	None	Minocycline, ofloxacin, gentamicin (Farmer)	Penicillin, cephem	Doxycyclin, ofloxacin	3 months	Cure

M, male; F, female; IS, immunosuppressive therapy; COPD, chronic obstructive pulmonary disease; DM: diabetes mellitus; TMP-SMZ, trimethoprim-sulfamethoxazole.

decoloration (**Figure 1E**). The clinician suspected the microorganism to be *Nocardia* sp and performed 16S ribosomal RNA (rRNA) gene PCR and sequencing to make the definitive identification at the species level. The DNA sequence of the cultured strains reported 100% similarity with *N. otitidiscaviarum* ATCC 14629 and the partial gene sequence of 1343 bp was later submitted to GenBank, accession number NR117344.1 (**Figure 1F**).

The clinicians used broth microdilution method to test the drug susceptibility of the bacteria and found that the strain was sensitive to gentamicin, linezolid, levofloxacin, trimethoprim-sulfamethoxazole (TMP-SMX) and teicoplanin, but resistant to penicillin, cefazolin, erythromycin, clindamycin, fosfomycin and rifampicin. Upon patient's arrival, the clinicians had prescribed doxycycline (0.1 g twice daily) and TMP-SMX (two tablets every 8 hours) to treat atypical bacterial infection, which was suspected based on the patient's clinical features. After the diagnosis of *N. otitidiscaviarum* infection was reached and based on all the patient's laboratory tests, the patient adhered to the regimen for three months. After the treatment course was completed, the patient reported remarkable improvement with his lesions, which gradually crusted and healed (**Figure 1B**). During the one-year follow-up through telephone, the patient was in good condition and no recurrence of the cutaneous nodules or abscess was observed.

Discussion

Nocardia spp, which belong to a suborder of aerobic actinomycetes, are ubiquitous soil organisms which can be found in soil, decomposing vegetation, and fresh or salt water. Human infection can be acquired through traumatic inoculation, resulting in primary infections of the skin and subcutaneous tissues that often presents as a localized, nodular process. Compared with *N. brasiliensis*, *N. otitidiscaviarum* was less frequently reported [2] and we summarized and listed its features through reviewing all previously reported cases in the literature (**Table 2**). Majority of the reported patients were male who were over 60 years old, and most of them had immunocompromised condition. Even though primary cutaneous nocardiosis may develop in immunocompetent host, but as *N. otitidiscaviarum* is postulated to

be less pathogenic than other species [2], patients with cutaneous infection of *N. otitidiscaviarum* should be carefully evaluated for immune defects. Infection in immunocompetent host, as shown in our case, is typically a chronic process, during which infection tends to be localized to a single region. The leading risk factor for *Nocardia* infection was trauma, and in our case, the patient's accident 12 years ago might have led to the bacterial colonization.

The diagnosis of nocardiosis tends to be difficult, as clinical presentations are usually non-specific and serological tests are not yet available. Isolation of the *Nocardia* organisms by smear or by culture from pus or tissue biopsies are the key to diagnosis in the clinical practice. *Nocardia* colonies can take up 2 to 3 weeks to exhibit growth [2, 3] and it is imperative for physicians to stay alert to the possibility of nocardiosis and notify the laboratory once *Nocardia* is suspected, so that the diagnosis work-up can be expedited.

Because of the continuous revision of the taxonomy of *Nocardia* and nonreactive nature of some species in biochemical tests, species typification using biochemical methods does not provide reliable results. *Nocardia* taxonomy has been linked to specific patterns of antimicrobial susceptibility, which determines the optimal antimicrobial therapy. Our laboratory has successfully applied 16S rRNA gene sequencing, which is highly conserved and specific for species identification [2].

N. otitidiscaviarum isolates display a distinct drug susceptibility pattern (**Table 2**) [4]. Based on the literature reports, *N. otitidiscaviarum* are generally susceptible to amikacin, fluoroquinolones, and sulfonamides, but usually resistant to beta-lactams, including penicillin, cephalosporins, ampicillin, amoxicillin-clavulanic acid, and imipenem [2]. Drug susceptibility of the isolate in this case was a typical one, similar to the previous reports. However, it should be noted that *N. otitidiscaviarum* demonstrated inconsistent susceptibility to sulfonamides [4].

Insufficient treatment could lead to an extended and refractory disease progress. It is suggested that surgical drainage alone might be inadequate to cure the disease and that prima-

Primary cutaneous nocardiosis

ry cutaneous nocardiosis should be treated with appropriate antibiotics for 1 to 3 months to reduce the chance of recurrence [3]. In the previous case reports, all cases of primary cutaneous *N. otitidiscaviarum* infection treated with appropriate antibiotics had favorable prognosis (**Table 2**), indicating again the importance of appropriate antibiotics regimens.

In summary, we report a case of primary cutaneous infection caused by *N. otitidiscaviarum*. This case reminded us again that physicians should always stay alert of *Nocardia* infection, especially when the disease does not respond to empirical antibiotic treatment. The optimal therapy requires species strain identification because of its heterogeneous drug susceptibility. 16S rRNA gene sequencing is specific for the pathogen identification.

Disclosure of conflict of interest

None.

Address correspondence to: Jialin Jin, Department of Infectious Diseases, No 12 Wulumuqi Middle Road, Huashan Hospital, Shanghai 200040, China. Tel: +86-21-52888262; Fax: +86-21-62481258; E-mail: jinjialin@fudan.edu.cn

References

- [1] Wilson JW. Nocardiosis: updates and clinical overview. *Mayo Clin Proc* 2012; 87: 403-407.
- [2] Brown-Elliott BA, Brown JM, Conville PS and Wallace RJ Jr. Clinical and laboratory features of the *Nocardia* spp. based on current molecular taxonomy. *Clin Microbiol Rev* 2006; 19: 259-282.
- [3] Ambrosioni J, Lew D and Garbino J. Nocardiosis: updated clinical review and experience at a tertiary center. *Infection* 2010; 38: 89-97.
- [4] McTaggart LR, Doucet J, Witkowska M and Richardson SE. Antimicrobial susceptibility among clinical *Nocardia* species identified by multilocus sequence analysis. *Antimicrob Agents Chemother* 2015; 59: 269-75.
- [5] Maraki S, Scoulica E, Nioti E and Tselentis Y. Nocardial infection in Crete, Greece: review of fifteen cases from 2003 to 2007. *Scand J Infect Dis* 2009; 41: 122-127.
- [6] Mereghetti L, van der Mee-Marquet N, Dubost AF and Boiron P. *Nocardia otitidiscaviarum* infection of a traumatic skin wound. *Eur J Clin Microbiol Infect Dis* 1997; 16: 383-384.
- [7] Fabre S, Gibert C, Lechiche C, Jorgensen C and Sany J. Primary cutaneous *Nocardia otitidiscaviarum* infection in a patient with rheumatoid arthritis treated with infliximab. *J Rheumatol* 2005; 32: 2432-2433.
- [8] Wada A, Matsuda S, Kubota H, Miura H and Iwamoto Y. Primary lymphocutaneous nocardiosis caused by *Nocardia otitidiscaviarum*. *Hand Surg* 2002; 7: 285-287.
- [9] Shahapur PR, Peerapur BV, Shahapur RP, Honnutagi RM and Biradar MS. Lymphocutaneous nocardiosis caused by *Nocardia otitidiscaviarum*: a case report and review of literature. *J Nat Sci Biol Med* 2014; 5: 197-201.
- [10] Clark NM, Braun DK, Pasternak A and Chenoweth CE. Primary cutaneous *Nocardia otitidiscaviarum* infection: case report and review. *Clin Infect Dis* 1995; 20: 1266-1270.
- [11] Suzuki Y, Toyama K, Utsugi K, Yazawa K, Mikami Y, Fujita M and Shinkai H. Primary lymphocutaneous nocardiosis due to *Nocardia otitidiscaviarum*: the first case report from Japan. *J Dermatol* 1995; 22: 344-347.