

Case Report

Percutaneous kyphoplasty for vertebral fracture second to polyostotic fibrous dysplasia: a case report and review of the literature

Hao Shen^{1*}, Sudeep B Shrestha^{1*}, Xiang Fang², Hao Liu¹, Jun Lin¹, Huilin Yang¹

Departments of ¹Orthopedic Surgery, ²Radiology, The First Affiliated Hospital of Soochow University, Suzhou, Jiangsu, China. *Equal contributors.

Received September 17, 2016; Accepted November 7, 2016; Epub January 15, 2017; Published January 30, 2017

Abstract: A 26-year-old female patient suffered from intermittent back pain for 4 years and a fall from bicycle aggravated the symptom. Physical and imaging examinations revealed the diagnosis of polyostotic fibrous dysplasia in McCune-Albright syndrome. No neurological symptom was found. A vertebral fracture was seen at the eighth thoracic body. Percutaneous kyphoplasty was performed at the fractured level. The patient got a remarkable pain relief after surgery. As a suggestion, percutaneous kyphoplasty may be a usable choice to treat the patients with vertebral fracture second to polyostotic fibrous dysplasia.

Keywords: Percutaneous kyphoplasty, polyostotic fibrous dysplasia, vertebral fracture, McCune-Albright syndrome

Introduction

Fibrous dysplasia (FD) is an uncommon disorder of bone characterized by progressive replacement of normal bone with fibro-osseous tissue, which may result in pain, deformity and pathological fracture [1, 2]. The disease could affect single bone (monostotic) or several (polyostotic) bones. Polyostotic fibrous dysplasia (PFD) can occur combining with café-au-lait skin spots and precocious puberty, which is known as McCune-Albright syndrome (MAS) [3, 4]. In most cases, FD preferentially affects long bones and craniofacial bones are the most frequently affected [5]. As reported, FD rarely affects the spine in about 2.5% of cases [6]. Herein, we present an even rare case of PFD in MAS involving with thoracic spine, ribs and ilium.

Case report

The patient was a 26-year-old female patient with a history of intermittent back pain. She reported that the pain had lasted for 4 years until a tumble accidentally occurred on her two weeks ago, which aggravated the symptom. On

questioning, we learned the history of twice vaginal bleeding at the patient's age of 5. Two light brown-pigmented patches were observed on the back and medial side of her left thigh, which were snatchy and asymptomatic (**Figure 1A, 1B**). Physical examination revealed conspicuous tenderness and percussion pain in the thoracic region, within T8-9. Neurological examination demonstrated normal status. Visual analog scale (VAS) was 6 before treatment and painkiller had little help.

Computed tomography (CT) of thoracic spine revealed multiple lytic expansile lesions involving several ribs, T2, T3 and T8 (**Figure 2**). Sagittal and coronal CT showed obvious collapse in T8 (**Figure 2B, 2C**). Magnetic resonance imaging (MRI) of short tau inversion recovery (STIR) sequence showed abnormal hyperintense of the T8 vertebral body (**Figure 3**). Fresh vertebral fracture of T8 was confirmed, in line with the location of back pain. Positron emission tomography-computed tomography (PET-CT) suggested hypermetabolism in several ribs, T2, T3, T8 and left ilium. Additional MRI of sacrum demonstrated the lesions of left ilium (**Figure 4**). A needle biopsy of T8 showed

Percutaneous kyphoplasty for vertebral fracture

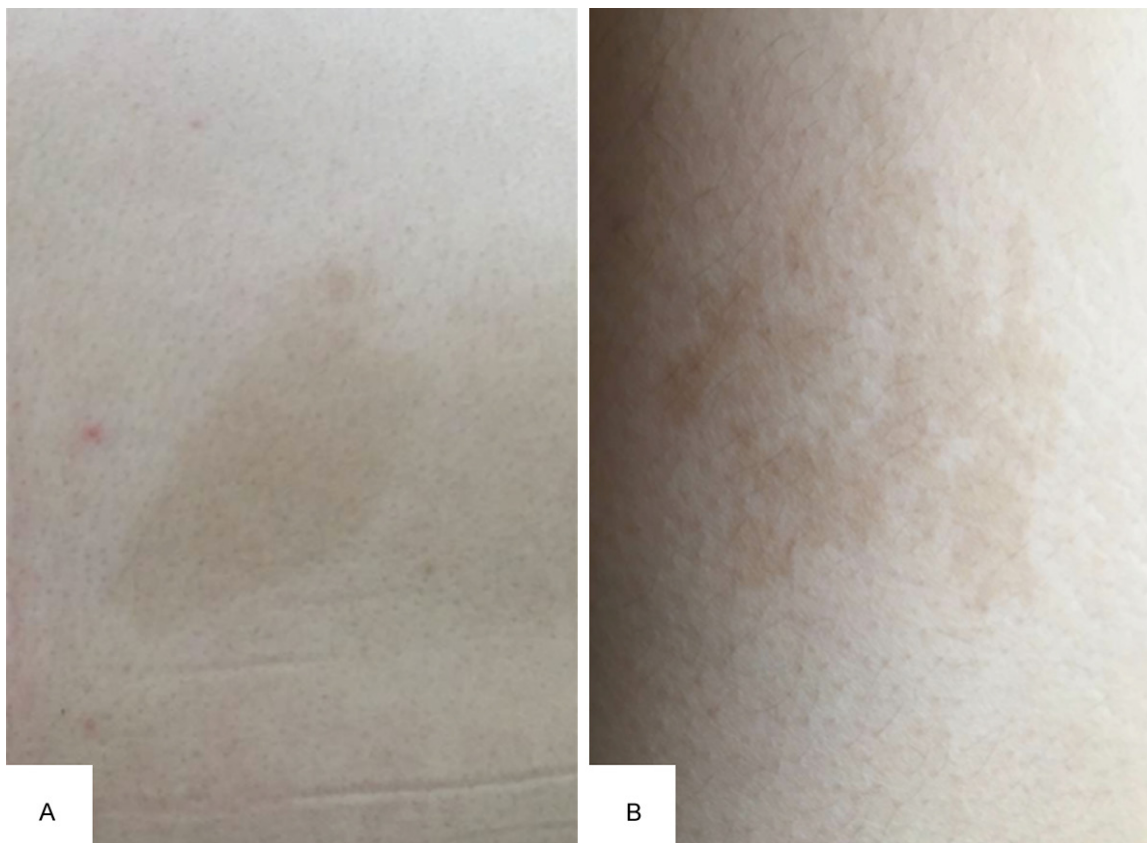

Figure 1. Light brown pigmented patches on the back of truncus (A) and inner of left thigh (B).

cellular fibrous matrix, which is consistent with fibrous dysplasia (**Figure 5**).

All the findings above appeared to fit the classical triad of symptoms of MAS. In case of endocrinopathies, the patient received an all-round endocrine evaluation, which revealed no abnormality.

With diagnosis established, the treatment was discussed. After explaining benefits and risks of different surgical methods, the patient and her family chose percutaneous kyphoplasty, consistent with our option. The bilateral PKP was performed under general anesthesia. After T8 was located with help of fluoroscopy, a trocar and cannula was inserted into vertebral body through each pedicle. Then the trocar was removed and a balloon was inserted and inflated through each cannula. After that, cement was introduced into the fractured vertebral body. No cement leaked duration the whole procedure.

After the surgery, VAS was reduced to 0. Patient got a complete pain relief. Radiography after 1

week showed the recovery of height of T8 (**Figure 6**). In 1 month, 3 months and 6 months, the patient's follow-up visits showed a good status of her.

Discussion

Fibrous dysplasia is a non-inheritable disorder due to the activating mutations of codon 201 in the GNAS1 gene that encodes for the alpha-subunit of protein Gs [7]. From the perspective of cytology, it is caused by abnormal proliferation and differentiation of bone marrow stromal cells, which leads to the replacement of normal bone with matrix, trabeculae and collagen [8, 9].

Biological variability results in the multiformity of clinical manifestation. In general, FD is asymptomatic, which may be a chance finding by radiography [10]. However, pain, deformity or even fracture could happen in many cases. The typical MAS is classically defined by the triad of PFD, precocious puberty and café-au-lait skin spots [11]. In patients with MAS, there is a high-

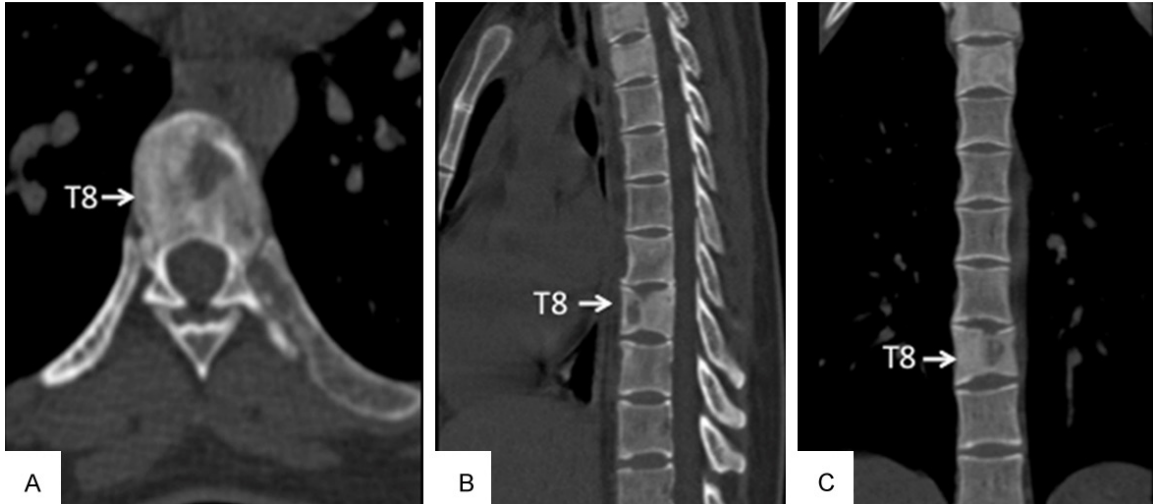


Figure 2. CT of thoracic spine revealed multiple lytic expansile lesions involving several ribs, T2, T3 and T8. (A) Cross section. Sagittal (B) and coronal (C) CT pictures showed obvious collapse in T8.

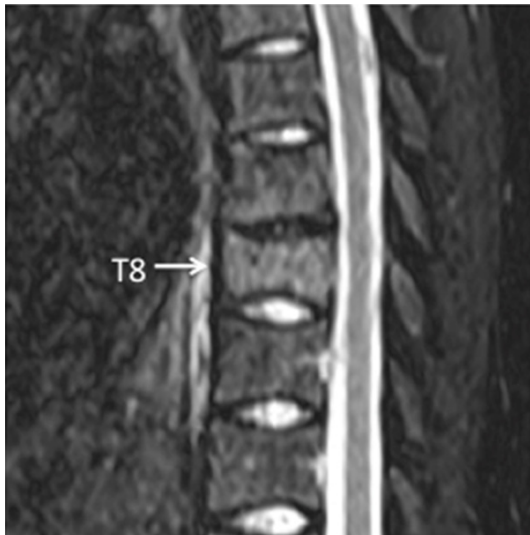

Figure 3. MRI of STIR sequence showed abnormal hyperintense of T8.

er rate of fractures, which is 0.29 versus 0.08 fractures per year, compared with patients with PFD alone [12].

FD has a typical matrix “ground glass” appearance in radiography [13]. Vertebral involvement often presents with lytic expansile lesions. With the help of needle biopsy, the diagnosis can be established. If a vertebral fracture is suspected in FD case, MRI is necessary to check the abnormal hyperintense in STIR sequence [14].

Conservative treatment for FD aims at optimizing function and minimizing morbidity. Con-

ventional medicines consist of calcitonin, etidronate, mithramycin, and bisphosphonates [15]. But all these options are palliative. Surgical treatment is challenging. Methods like curettage, grafting and screws are frequently ineffective [16, 17]. However, aggressive resection with rigid fixation and fusion for FD of spine are supported and proved to be effective by some scholars [18, 19]. Deen *et al* suggest that balloon kyphoplasty may be an option in patients with painful vertebral compression fracture caused by fibrous dysplasia [20]. Above all, the treatment for FD is complex and individualized.

In our case, the patient was diagnosed with MAS and PFD was involved with her thoracic spine, ribs and ilium. Her main symptom was back pain due to the fractured eighth thoracic body. Previous medications were ineffective. According to radiography, no other fracture was found except T8. Taking the principle of minimal invasion and rapid pain relief into consideration, we chose percutaneous kyphoplasty as a surgical method [21]. With bone cement injected into the vertebra, height of T8 got a remarkable recovery. After the surgery, the patient gained significant pain relief and the VAS score was improved to 0 from 6. No complication sets in during 6 months’ follow-up.

Conclusion

This report presents a rare case of polyostotic fibrous dysplasia in McCune-Albright syndrome involving with thoracic spine, ribs and ilium. The

Percutaneous kyphoplasty for vertebral fracture

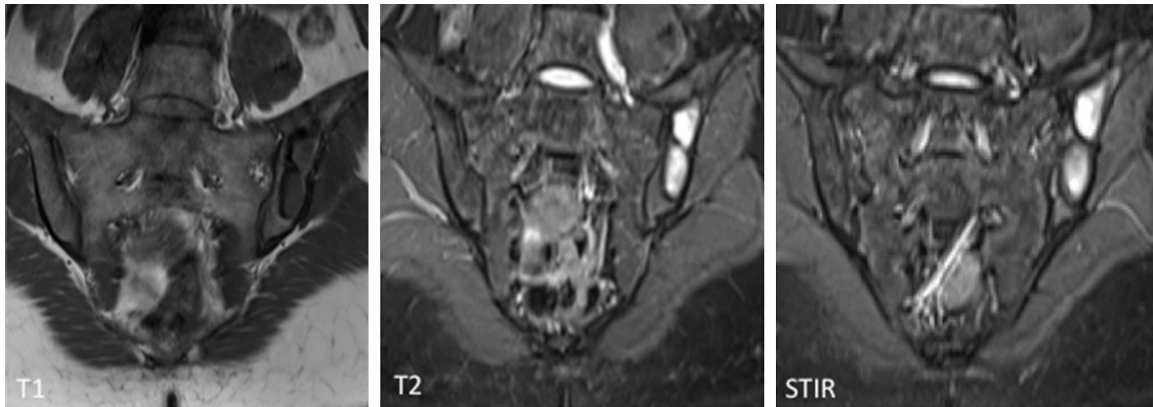


Figure 4. Sagittal MRI of the sacrum revealed the lesions located in left ilium, which were found to be low signal intensity on T1-weighted, high intensity on T2-weighted images and especially high intensity on STIR sequence.

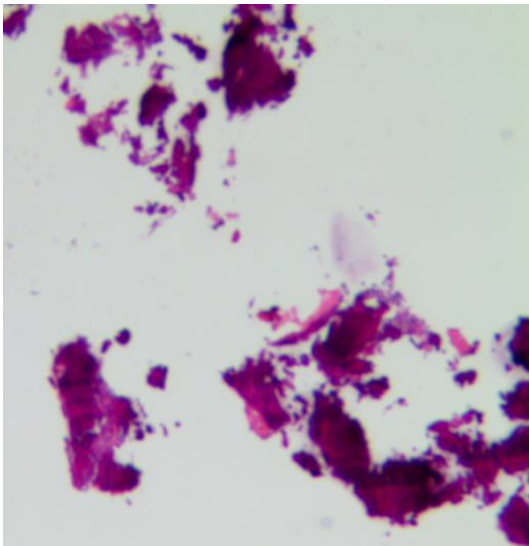


Figure 5. Image of the material from needle biopsy showed cellular fibrous matrix, consistent with fibrous dysplasia.

patient suffered from back pain and a vertebral fracture of T8 was found after examinations. By performing PKP to relieve the pain, we suggest it as a usable choice to treat this kind of patients.

Disclosure of conflict of interest

None.

Address correspondence to: Drs. Jun Lin and Huilin Yang, Department of Orthopedic Surgery, The First Affiliated Hospital of Soochow University, 188 Shizi Street, Suzhou 215006, Jiangsu, China. Tel: 0086-512-67780101; Fax: 0086-512-67780999; E-mail: jasonosfc@163.com (JL); yhlisdfyy@163.com (HLY)

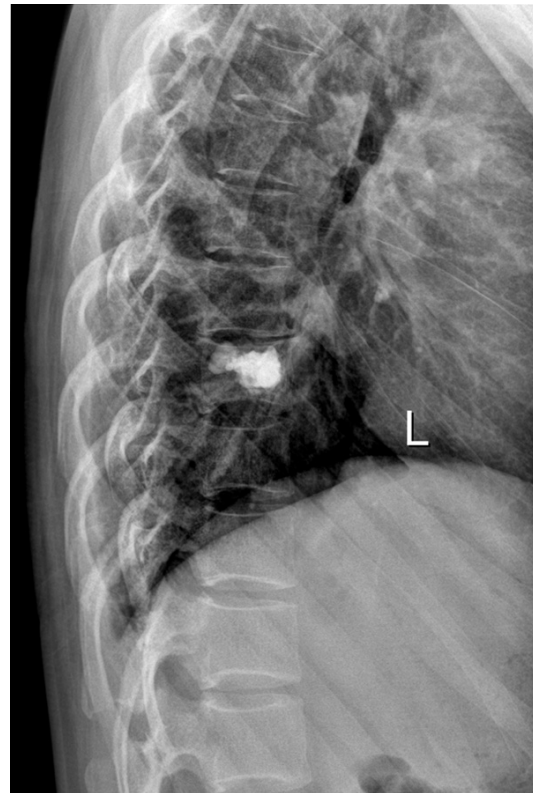


Figure 6. Radiography after 1 week of the surgery showed the recovery of height of T8.

References

- [1] Lichtenstein L. Polyostotic fibrous dysplasia. *Archives of Surgery* 1938; 36: 874-898.
- [2] Collins MT, Riminucci M and Bianco P. Fibrous dysplasia. *Primer on The Metabolic Bone Diseases And Disorders of Mineral Metabolism* 2009; 20081: 423-428.
- [3] Riminucci M, Fisher LW, Shenker A, Spiegel AM, Bianco P and Robey PG. Fibrous dysplasia

Percutaneous kyphoplasty for vertebral fracture

- of bone in the McCune-Albright syndrome: abnormalities in bone formation. *Am J Pathol* 1997; 151: 1587.
- [4] Weinstein LS, Shenker A, Gejman PV, Merino MJ, Friedman E and Spiegel AM. Activating mutations of the stimulatory G protein in the McCune-Albright syndrome. *N Engl J Med* 1991; 325: 1688-1695.
- [5] Collins MT, Kushner H, Reynolds JC, Chebli C, Kelly MH, Gupta A, Brillante B, Leet AI, Riminucci M, Robey PG, Bianco P, Wientroub S and Chen CC. An instrument to measure skeletal burden and predict functional outcome in fibrous dysplasia of bone. *J Bone Miner Res* 2005; 20: 219-226.
- [6] Harris WH, Dudley HR and Barry RJ. The natural history of fibrous dysplasia. *J Bone Joint Surg Am* 1962; 44: 207-233.
- [7] Shenker A, Weinstein LS, Sweet DE and Spiegel AM. An activating Gs alpha mutation is present in fibrous dysplasia of bone in the McCune-Albright syndrome. *J Clin Endocrinol Metab* 1994; 79: 750-755.
- [8] Chapurlat RD and Orcel P. Fibrous dysplasia of bone and McCune-Albright syndrome. *Best Pract Res Clin Rheumatol* 2008; 22: 55-69.
- [9] Robinson C, Collins MT and Boyce AM. Fibrous Dysplasia/McCune-Albright Syndrome: clinical and translational perspectives. *Curr Osteoporos Rep* 2016; 14: 178-86.
- [10] Rosenblum B, Overby C, Levine M, Handler M and Sprecher S. Monostotic fibrous dysplasia of the thoracic spine. *Spine (Phila Pa 1976)* 1987; 12: 939-942.
- [11] Feuillan PP. McCune-Albright syndrome. *Curr Ther Endocrinol Metab* 1997; 6: 235-239.
- [12] Leet AI, Chebli C, Kushner H, Chen CC, Kelly MH, Brillante BA, Robey PG, Bianco P, Wientroub S and Collins MT. Fracture incidence in polyostotic fibrous dysplasia and the McCune-Albright syndrome. *J Bone Miner Res* 2004; 19: 571-577.
- [13] Daffner RH, Kirks DR, Gehweiler JA Jr and Heaston DK. Computed tomography of fibrous dysplasia. *AJR Am J Roentgenol* 1982; 139: 943-948.
- [14] Yang HL, Wang GL, Niu GQ, Liu JY, Hiltner E, Meng B and Tang TS. Using MRI to determine painful vertebrae to be treated by kyphoplasty in multiple-level vertebral compression fractures: a prospective study. *J Int Med Res* 2008; 36: 1056-1063.
- [15] Stephenson RB, London MD, Hankin FM and Kaufer H. Fibrous dysplasia. An analysis of options for treatment. *J Bone Joint Surg Am* 1987; 69: 400-409.
- [16] Leet AI, Boyce AM, Ibrahim KA, Wientroub S, Kushner H and Collins MT. Bone-Grafting in Polyostotic Fibrous Dysplasia. *J Bone Joint Surg Am* 2016; 98: 211-219.
- [17] Stanton RP, Ippolito E, Springfield D, Lindaman L, Wientroub S and Leet A. The surgical management of fibrous dysplasia of bone. *Orphanet J Rare Dis* 2012; 7 Suppl 1: S1.
- [18] Przybylski GJ, Pollack IF and Ward WT. Monostotic fibrous dysplasia of the thoracic spine. A case report. *Spine (Phila Pa 1976)* 1996; 21: 860-865.
- [19] Mezzadri JJ, Acotto CG, Mautalen C and Basso A. Surgical treatment of cervical spine fibrous dysplasia: technical case report and review. *Neurosurgery* 1999; 44: 1342-1346; discussion 1346-1347.
- [20] Deen HG and Fox TP. Balloon kyphoplasty for vertebral compression fractures secondary to polyostotic fibrous dysplasia. Case report. *J Neurosurg Spine* 2005; 3: 234-237.
- [21] Kasperk C, Noldge G, Meeder P, Nawroth P and Huber FX. [Kyphoplasty: method for minimally invasive treatment of painful vertebral fractures]. *Chirurg* 2008; 79: 944-950, 952-945.