

Case Report

Recurrent pelvic stromal tumor with colon fistula of left leg: a case report

Jing Luo, Hongliang Yao, Sanlin Lei, Yong Xie

Department of Gastrointestinal Surgery, Second Xiangya Hospital, Central South University, Changsha 410011, Hunan, China

Received March 8, 2017; Accepted September 4, 2017; Epub October 15, 2017; Published October 30, 2017

Abstract: The oral tyrosine kinase inhibitor (TKI), sunitinib malate, has been widely used in patients with gastrointestinal stromal tumors (GISTs). The formation of colon fistula of left leg during treatment with sunitinib for recurrent pelvic stromal tumor has not been described before. We describe a 47 years old man who had received several surgical resections and taken imatinib mesylate due to recurrent gastrointestinal stromal tumors. Recently, in consideration of imatinib resistance, the patient changed the drug from imatinib to sunitinib. Unfortunately, a fistula developed between the sigmoid colon cavity and the left leg skin. Thus, the patient received surgery under general anesthesia after active nutrition support therapy and the vacuum assisted closure therapy was taken to promote wound healing and avoid skin grafting or reduce the grafting area. Finally, the patient was discharged with a better health condition without skin grafting. This is the first description of recurrent pelvic stromal tumor with colon fistula of left leg under sunitinib treatment. From this case, clinicians should raise awareness of the possibility of intestinal perforation and enterocutaneous fistula for patients with gastrointestinal stromal tumors, especially when the intestine is involved by tumor and under the treatment of molecular targeted drugs.

Keywords: Gastrointestinal stromal tumors, colon fistula of left leg, sunitinib, case report, vacuum-assisted closure

Background

GISTs remain the most common mesenchymal neoplasm of gastrointestinal tract, accounting for 0.1-3% of gastrointestinal tumors [1, 2]. GISTs are considered to be a tumor caused by c-Kit or PDGFR α mutations, and were solid tumors that need TKI therapy [3]. Imatinib mesylate, a small molecule TKI, has been proven to be beneficial to patients with Kit-positive GISTs that failed to resection or with metastatic lesions by prolonging PFS, RFS and OS. Present, imatinib has been regarded as the first-line drug for GISTs [4-7].

Sunitinib malate, another novel oral small-molecule TKI, has anti-tumor and anti-angiogenesis functions through interacting with angiogenesis receptors, including platelet-derived growth factor receptors and the VEGF receptors [8, 9]. For GISTs patients who are resistant or intolerant to imatinib, sunitinib can be deemed as the second-line drug. A randomized controlled trial reported that sunitinib could apparently

slow tumor progression and is generally well tolerated, with most side-effects being mild to moderate [10]. The most common side effects included fatigue (34%), diarrhea (24%), skin discoloration (25%), nausea (24%) and anorexia (19%). Previous studies confirmed fistula formation was rare in GISTs [8, 10, 11]. However, recently, some case reports demonstrated vesicocutaneous fistula, tumor fistula and enterocutaneous fistula formation in GISTs patients treated with sunitinib [12-14]. This study reported the clinical aspects of a rare enterocutaneous fistula between enteric cavity and the left leg skin in a GISTs patient with repeated recurrence and surgeries, since the case was easy to be misdiagnosed for atypical clinical manifestation.

Case presentation

A 47-year-old man, the Han nationality, was admitted to our hospital for the fourth time due to recurrent abdominal pain for 19 years, and accompanied by the left leg pain for 5 days on

Recurrent pelvic stromal tumor with colon fistula of left leg: a case report

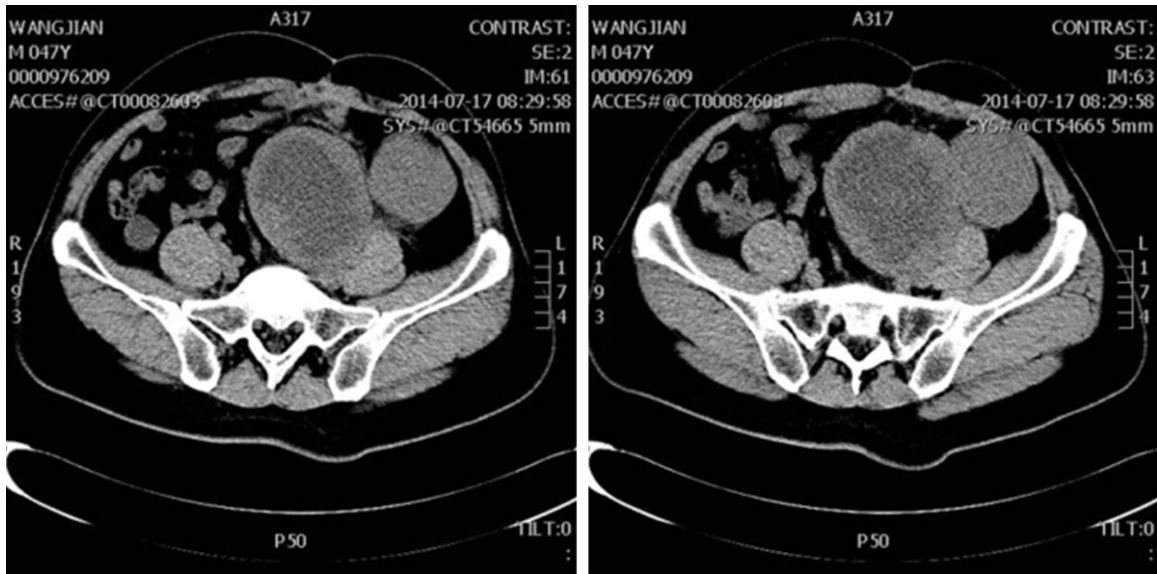


Figure 1. Abdominal CT showed GISTs recurrence on July 17th 2014.

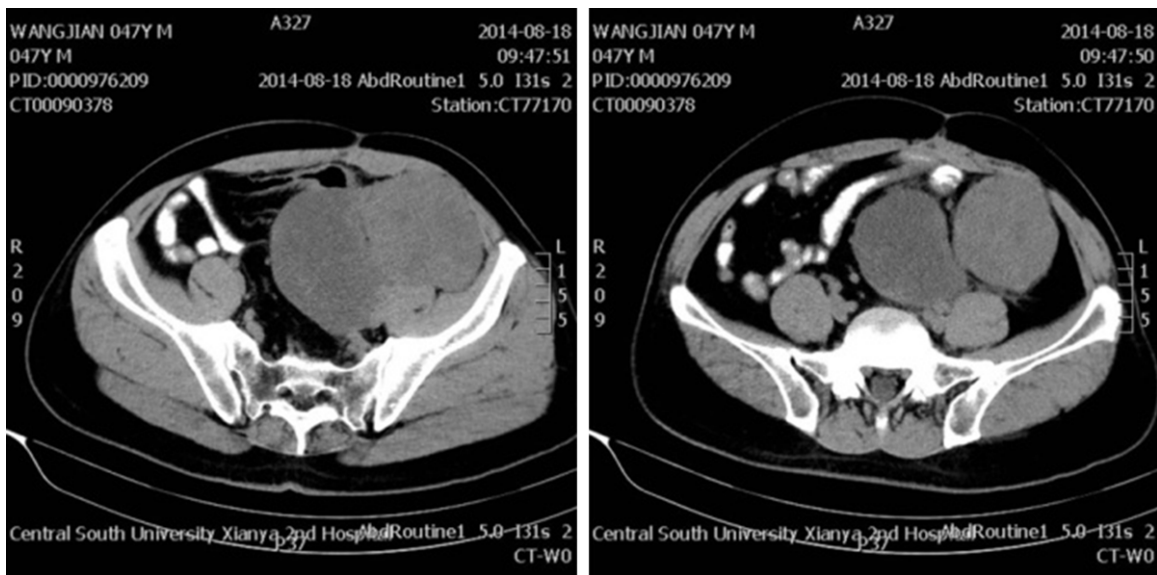


Figure 2. CT reexamination showed recurrent GISTs on August 18th 2014.

28th September, 2014. In 1995, the patient was firstly admitted to our hospital due to abdominal pain. The contrast-enhanced CT of pelvic cavity and the barium enema revealed a mass in the rectovesical pouch (7.5 cm×10 cm×13 cm). After huge mass resection in pelvic peritoneum and jejunum part resection and anastomosis, biopsy result revealed the existence of low-grade malignant leiomyosarcoma of small intestinal (Now it confirmed to be GISTs). The patient was discharged with a better health condition.

The patient had no special discomfort until June 2008, and was admitted to our hospital again for abdominal pain. Pelvic CT showed an occupied lesion (8.5 cm×7.5 cm) with hemorrhage and necrosis, the source and property were unknown. Finally, the pathological diagnosis confirmed GISTs with medium risk after the pelvic mass resection. The mitotic index was 2/50 HPF and the result of immunohistochemical examination was CD117(+), NSE(+), Vim(+), CD34(+), Actin(+), CD68(-) and S100(-). The patient received adjuvant therapy with imatinib

Recurrent pelvic stromal tumor with colon fistula of left leg: a case report

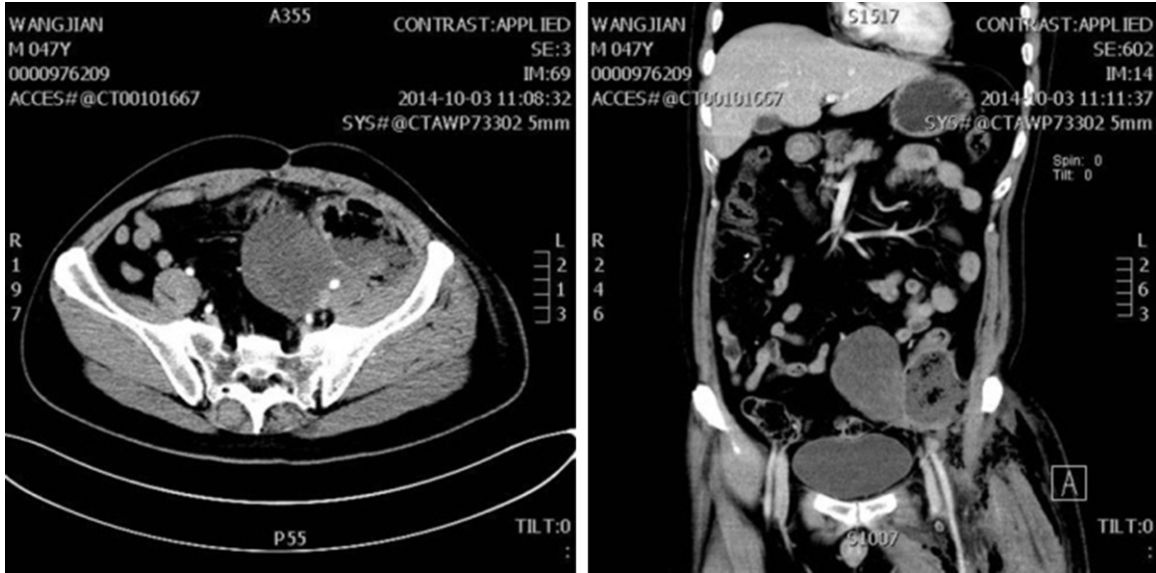


Figure 3. Abdominal CT showed that the mass in left lower abdomen was smaller with 77 mm×64 mm and density was lower.

Table 1. The list of treatment times, categories and dosages of molecular target drugs for the patient

Time	Type	Dosage
2008-2010	Imatinib mesylate	400 mg QD
2012-July 19, 2014	Imatinib mesylate	400 mg QD
July 20, 2014-Sep 23, 2014	Sunitinib malate	37.5 mg QD
Sep 24, 2014-Sep 25, 2014	Imatinib mesylate	400 mg QD
Sep 26, 2014-Sep 27, 2014	Imatinib mesylate	600 mg QD
Sep, 28, 2014-Oct 5, 2014	Imatinib mesylate	800 mg QD
Oct 6, 2014	Withdraw	

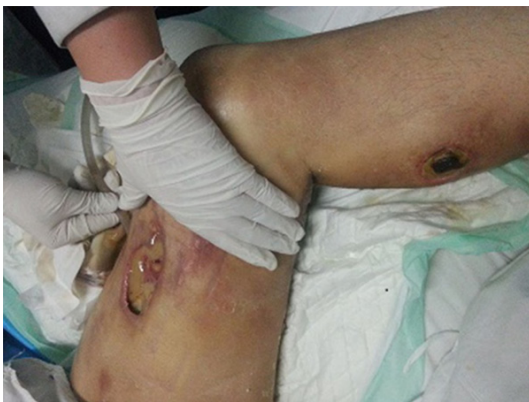

Figure 4. Fecal effusion flowing out, almost 500 ml per day when using negative pressure suction.

(400 mg per day), then discharged with relieved abdominal pain.

The patient was regularly treated with imatinib (400 mg/d). CT reexamination of the pelvic had no abnormal lesion in September 2009, and he withdrew imatinib in June 2010. In September 2011, the patient received PET-CT for reexamination, and the results showed multiple nodular and crumb abnormal radioactive accumulations in the left lower abdomen and pelvic cavity, which maybe malignant tumor or metastasis. Therefore, imatinib (400 mg/d) was reused. In March 2012, the patient was hospitalized for the third time for abdominal pain. With the consideration of GISTs recurrence, he received recurrent stromal tumor resection, during which a mass about 2 cm in diameter in the left colon ditch was found adhesion to omentum and an irregular and fragile mass was occupied in the left of the upper rectum, both of which were removed, and the wound was dipped in dehydrated alcohol to inactivate the tumor cells. The gene test after surgery showed KIT E11 mutation and KIT E9, E13, E17 and PDGF α E12, E18 without mutation. Therefore, the patient was treated with imatinib (400 mg/d) continually for adjuvant therapy. In January 2013, pelvic CT showed no abnormal lesion. However, the patient felt abdominal pain on July 17th 2014 and abdominal CT showed GISTs recurrence (**Figure 1**). Considering imatinib resistance, sunitinib (37.5 mg per day) was administrated for relieving dis-

Recurrent pelvic stromal tumor with colon fistula of left leg: a case report

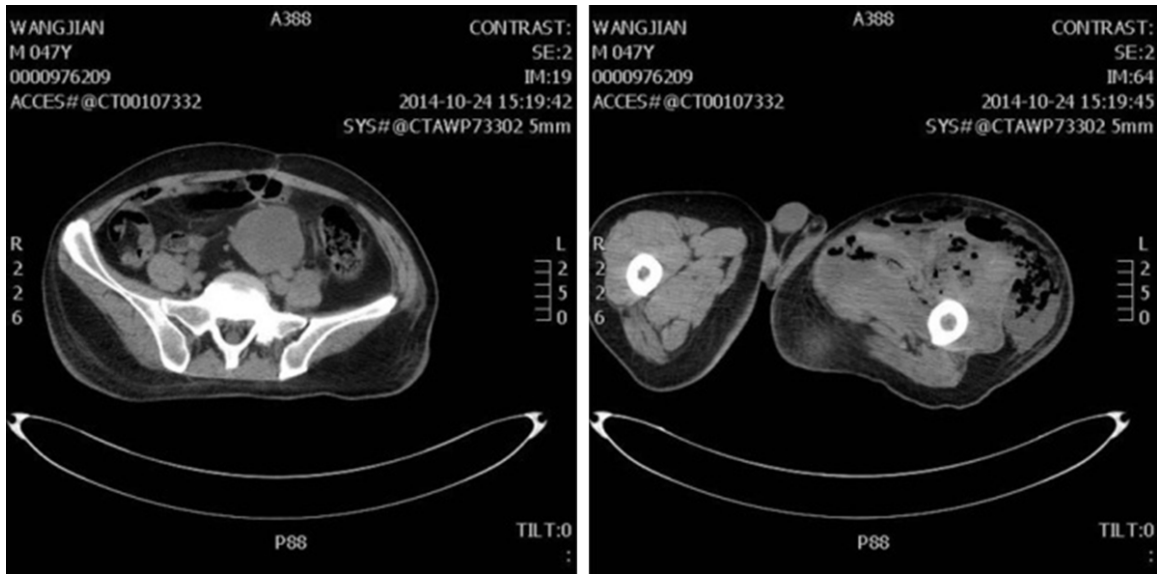


Figure 5. CT of the pelvic and the left leg on October 24th 2014.

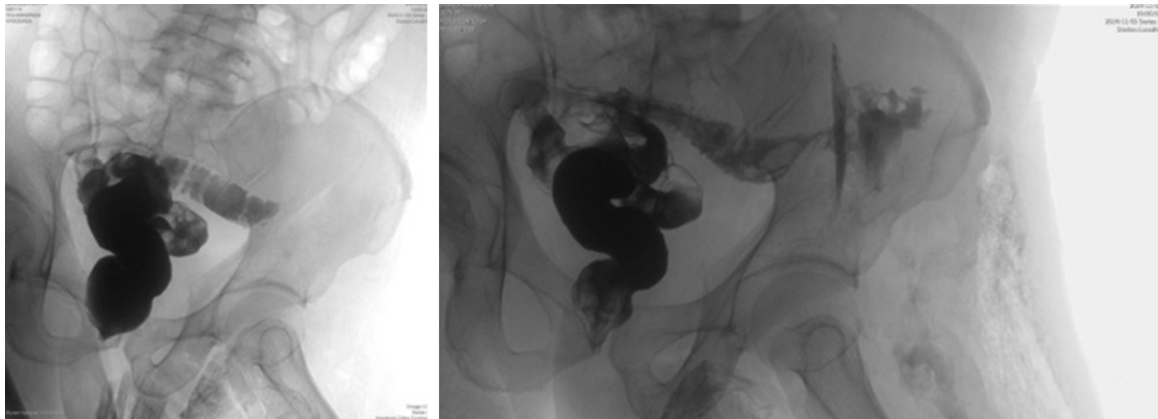


Figure 6. The barium examination of the whole digestive tract showed decreased gastrointestinal motility and soft tissue emphysema of the left thigh.

comfort. New symptoms appeared, including mild diarrhea, anorexia and insomnia. CT re-examination on August 18th 2014 showed recurrent GISTs (Figure 2). On September 22, with the abdominal pain worsen, and considering that sunitinib was invalid, the patient returned to imatinib (600 mg per day), and added to 800 mg per day in 4 days. On September 24, symptom of pain in the inner left leg appeared, which was persistently swollen without wandering pain. The patient was admitted to our hospital for the fourth time.

For previous medical history, in 2011, he underwent thyroid papillary carcinoma resection without recurrence until now. The family history was

unremarkable. Physical examination showed a 16 cm old surgery scar in lower abdomen and the left leg was swelling with high temperature and ecchymosis distributed, without blisters. Other physical examination was normal. During hospitalization, the vascular ultrasound and venography of the left leg were both normal, and abdominal CT showed that the mass in left lower abdomen was smaller with 77 mm×64 mm and density was lower (Figure 3).

The patient withdrew imatinib on October 6 (Table 1). The more and more swollen leg resulted in blisters, then blisters bursted, followed by fecal effusion flowing out, almost 500 ml per day when using negative pressure suc-

Recurrent pelvic stromal tumor with colon fistula of left leg: a case report

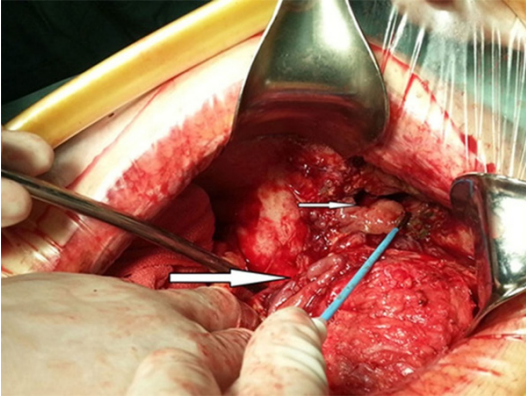


Figure 7. Fistula and the sinus tracts. The coarse arrow showed the fistula and the thin arrow showed the intestinal contents corrosion formation from the sinus tracts.

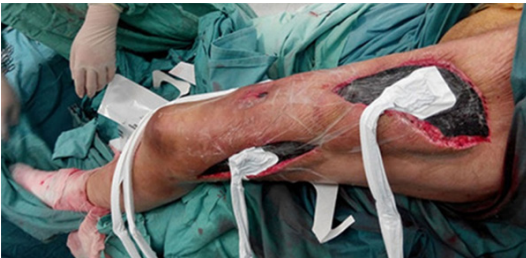

Figure 8. VAC for the left leg after operation.

tion (**Figure 4**). Effusion bacterial culture showed a wide range of drug-resistant *Escherichia coli* and the effective antibiotics were used. CT of the pelvic and the left leg on October 24th, 2014 showed smaller mass in the left pelvic (64 mm×63 mm), and incomplete lower part of descending colon and connected enteric cavity with air of low abdominal wall, intestinal fistula was suspected; the left thigh became gangrenous and enlarged lymph nodes in the left groin (**Figure 5**). The barium examination (**Figure 6**) of the whole digestive tract showed decreased gastrointestinal motility and soft tissue emphysema of the left thigh. Barium enema showed that the distal part of descending colon was connected with the soft tissue of the left thigh, conforming to the diagnosis of intestinal fistula; subcutaneous emphysema of the left thigh. According to the examinations above, the diagnosis of intestinocutaneous fistula was confirmed. And at this moment, the patient still had amounts of fecal effusion, and significantly swollen left thigh and the whole left leg, with red skin and high temperature, and many burs-

ted abscesses, the large stone was 5 cm×6 cm. And the muscle strength of the left leg was in grade 1. The patient's condition was complicated for severe hypoalbuminemia, moderate anemia, severe infection of abdominal cavity and left leg, severe abdominal cavity adhesion after several previous surgeries and many exudates. Therefore, case discussion and full consultation were organized to comprehensively assess the case, and we fully communicated with his family members, finally chose the limb salvage surgery. After some symptomatic and supportive treatments, the patient received Exploratory laparotomy + Sigmoid colon resection + Tumor resection + Sigmoid colostomy + the left leg debridement drainage + VAC + Left ureter repairing and Double J tube surgery under general anesthesia on November 6 2014. During the operation, a mass about 6 cm on the pelvic sidewall and in front of the left iliac blood vessels was found in the sigmoid colon and the left ureter, and a cleavage about 1.5 cm in the sigmoid colon was also found to break through the abdominal wall and connected with left leg through femoral canal (**Figure 7**). The surgery was successful and the wound on abdomen healed well. The patient received liquid diet with anastomosis ventilated well on November 9, and normal diet on November 14 and took out stitches on abdomen on November 20. Due to the necrotizing fasciitis of left leg, the patient received several infectious wounds debridements + VAC coverage on November 18, November 26, December 4, December 11 and December 17, December 24, 2014 and January 4, 2015, respectively (**Figure 8**). When the fester was drainage clean, we sutured wounds on the left leg, and the wound healed well without skin grafting. Finally, the patient restored well, and could walk on crutches. Imatinib at a dose of 600 mg per day was continued, and blood concentration of the drug was detected regularly after discharged. The pathological diagnosis: (abdominal mass) several tissues with a size of 13 cm×10 cm×5 cm, among which there is a piece of intestine about 8 cm long and a rough region with a size of 4 cm×3 cm on the serous surface of the intestine. Other parts of these tissues are tumors. GISTs recurrence (medium-high risk) with adhesion to intestine wall but no invasion was confirmed. And no tumor both in the two incisal edges of the intestine and in slices from lymphonodus around intestine (0/4).

Recurrent pelvic stromal tumor with colon fistula of left leg: a case report

Immunohistochemistry: CD117(+), CD34(focal +), Dog-1(+), SMA(weak+), S100(-); (the left leg): one piece of bean-size tissue. Microscopically, many inflammatory exudation, necrosis material and proliferative granulation tissue can be seen, without mucous membrane covered, and there are many neutrophils infiltrated in mesenchyme, all of which conforms with purulent inflammation, without tumors (GISTs) invasion. The gene test showed KIT E11 mutation and KIT E9, E13, E17, PDGF α E12 and E18 without mutation. After discharged in January 2015, the patient did the CT reexamination every month, none of which had a relapse performance. The last follow up was performed in November 2016, the patient is survived now and can walk by himself.

Discussion

The patient in our report had received three recurrent lesions resections since diagnosed with low-grade malignant leiomyosarcoma of small intestinal in 1995 and received imatinib for adjuvant therapy for diagnosed GISTs in 2008. The Expert Consensus on Diagnosis and Therapy of GISTs suggested that for patients diagnosed with limitedly recurrent or metastatic GISTs, if the molecular targeted drugs are effective and only one or several lesions progress, tumor cytoreduction can be chosen by removing progressive or metastatic lesions as many as possible [15]. Therefore, for these patients with repeatedly recurrent or metastatic GISTs, if the molecular targeted drugs are useful and the baseline performance status are well, tumor cytoreduction can be chosen for removing lesions and prolonging RFS and OS.

Pain and swollen in the left leg was one of the main symptoms of this patient. In consideration of the tumor history for many years, clinicians may tend to diagnose the patient with vascular embolization, especially the cancer embolus, which has been confirmed wrongly by the following examinations, and intestinocutaneous fistula was the correct diagnosis. Intestinocutaneous fistula did not occur during the administration of imatinib, then after several repeated recurrences, imatinib treatment was replaced with sunitinib (37.5 mg/d) in consideration of imatinib resistance. Although the abdominal pain relieved gradually, the abdominal pain aggravated suddenly 2 months later, accompanied with a new symptom of pain in the left leg,

which made us choose the imatinib (800 mg/d) treatment. Previous studies have confirmed that sunitinib has the effect of anti-angiogenesis, and has the ability to decrease the numbers of blood vessels and blood flow in the center of tumor to shrink tumor and promote tumor cells necrosis through inhibiting VEGF-VEGFR pathway [8]. However, the anti-angiogenesis effects may significantly affect injured mucosal homeostasis and wound healing. In March 2012, when the patient had the third surgery, tumors in the left colon ditch and in the left of the upper rectum were resected, and the wound was dipped in dehydrated alcohol to inactivate tumor cells. And the anti-angiogenesis effects of sunitinib caused intestinal perforation, which led to the concentration of intestinal contents in the left iliac fossa. And through the left femoral canal, the intestinal contents flowed into the left leg, resulting in pain and swollen. The more the drainage was, the more the pressure in the left leg was, and finally, blisters appeared and ruptured. Many previous studies showed that patients tolerate sunitinib well and fistula formation hardly occurs. However, a literature in 2006 has reported a case report about gastric-intestinal perforation happened in patients with GISTs when using sunitinib at a high dose of more than 75 mg per day [16]. In our case, the enterocutaneous fistula occurred when the patient using sunitinib for 2 months, and the intestinal content leakage was localized to the intestinal wall that adhered to GISTs, and flowed to the left inner thigh which is far away from the primary lesion through the physical channel-femoral canal, leading the left thigh to gangrene.

The patient received infected wound debridement for many times due to severe necrotizing fasciitis of left leg, and soft tissue and skin were seriously damaged. Besides, in order to promote wound healing and avoid skin graft, we determined to use VAC, also called NPWT. Fleischmann, *et al* reported that VAC was effectively used in treating damaged soft tissue of open fractures for the first time, followed by lectures about effective treatment of VAC in dissected wounds of skin and fascia and acute and chronic infected wounds by the same investigators [17-20]. VAC promotes wounds healing through macroscopic and microscopic pathways. Macroscopically, vacuum aspiration can promote concentration of wound edges and helps to discharge infections and necrotic

Recurrent pelvic stromal tumor with colon fistula of left leg: a case report

materials. Microscopically, it can inhibit edematization and promote tissue perfusion and stimulate the formation of granulation tissue [21]. Since VAC was introduced into clinical practice, it has been widely applied to many fields including wound surface of open fractures, osteofascial compartment syndrome, unhealing wound after amputation, osteomyelitis, skin-grafting and chronic ulcer, and the curative effects of which have been confirmed by many clinicians [22-26]. However, there are no professional studies that can confirm the curative effect of VAC, and how to setup the optimum parameter according to the different types of wounds is still unclear, therefore, further research is needed.

In conclusion, this is the first description of recurrent pelvic stromal tumor with colon fistula of left leg under sunitinib treatment. The anti-angiogenesis effect of the drug maybe partially related to the intestinal perforation and fistula formation. Therefore, for patients with GISTs involved in gastrointestinal tract or had residual tumor cells after resection, and receiving molecular targeted drugs, especially sunitinib, clinicians should take the possibility of intestinal perforation or enterocutaneous fistula formation into consideration.

Disclosure of conflict of interest

None.

Abbreviations

GISTs, gastrointestinal stromal tumors; CT, computer tomography; EUS, endoscopic ultrasonography; NPWT, negative pressure wound therapy; RFS, recurrent-free-survival; OS, overall survival; PFS, progression free survival; TKI, tyrosine kinase inhibitors; VAC, vacuum-assisted closure; VEGF, vascular endothelial growth factor; PET-CT, positron emission tomography-computed tomography.

Address correspondence to: Hongliang Yao, Department of Gastrointestinal Surgery, Second Xiangya Hospital, Central South University, Renmin Road, Changsha 410011, Hunan, China. Tel: 1380845-2603; E-mail: yaohl0326@csu.edu.cn

References

[1] Shinomura Y, Kinoshita K, Tsutsui S and Hirota S. Pathophysiology, diagnosis, and treatment

of gastrointestinal stromal tumors. *J Gastroenterol* 2005; 40: 775-780.

- [2] Fletcher CD, Berman JJ, Corless C, Gorstein F, Lasota J, Longley BJ, Miettinen M, O'Leary TJ, Remotti H and Rubin BP. Diagnosis of gastrointestinal stromal tumors: a consensus approach. *Hum Pathol* 2002; 10: 81.
- [3] Huizinga JD, Thuneberg L, Klüppel M, Malysz J, Mikkelsen HB and Bernstein A. W/kit gene required for interstitial cells of Cajal and for intestinal pacemaker activity. *Nature* 1995; 373: 347.
- [4] Demetri GD, von Mehren M, Blanke CD, Van den Abbeele AD, Eisenberg B, Roberts PJ, Heinrich MC, Tuveson DA, Singer S, Janicek M and Fletcher JA. Efficacy and safety of imatinib mesylate in advanced gastrointestinal stromal tumors. *New Engl J Med* 2002; 347: 472-480.
- [5] Blanke CD, Rankin C, Demetri GD, Ryan CW, Mehren MV, Benjamin RS, Raymond AK, Bramwell VH, Baker LH and Maki RG. Phase III randomized, intergroup trial assessing imatinib mesylate at two dose levels in patients with unresectable or metastatic gastrointestinal stromal tumors expressing the kit receptor tyrosine kinase: S0033. *J Clin Oncol* 2008; 26: 626-632.
- [6] Joensuu H, Eriksson M, Sundby HK, Hartmann JT, Pink D, Schütte J, Ramadori G, Hohenberger P, Duyster J and Albatran SE. One vs three years of adjuvant imatinib for operable gastrointestinal stromal tumor: a randomized trial. *JAMA* 2012; 307: 1265-1272.
- [7] Dematteo RP, Ballman KV, Antonescu CR, Maki RG, Pisters PW, Demetri GD, Blackstein ME, Blanke CD, Von MM and Brennan MF. Adjuvant imatinib mesylate after resection of localised, primary gastrointestinal stromal tumour: a randomised, double-blind, placebo-controlled trial. *Lancet* 2009; 373: 1097.
- [8] Demetri GD, Oosterom AT, Garrett CR, Blackstein ME, Shah MH, Verweij J, Mearthur G, Judson IR, Heinrich MC and Morgan JA. Efficacy and safety of sunitinib in patients with advanced gastrointestinal stromal tumour after failure of imatinib: a randomised controlled trial. *Lancet* 2006; 368: 1329.
- [9] Verhagen PC. Sunitinib versus interferon alfa in metastatic renal-cell carcinoma. *Eur Urol* 2007; 51: 1444.
- [10] Terashima A, Tamagawa N and Mori H. Phase I/II study of sunitinib malate in Japanese patients with gastrointestinal stromal tumor after failure of prior treatment with imatinib mesylate. *Invest New Drugs* 2010; 28: 866-875.
- [11] Judson I. Gastrointestinal stromal tumours (GIST): biology and treatment. *Ann Oncol* 2002; 13 Suppl 4: 287-289.
- [12] Watanabe K, Otsu S, Morinaga R, Kawano S, Hirashima Y, Sakashita H and Shirao K. Vesico-

Recurrent pelvic stromal tumor with colon fistula of left leg: a case report

- cutaneous fistula formation during treatment with sunitinib malate: case report. *BMC Gastroenterol* 2010; 10: 1-4.
- [13] Chow H, Jung A, Talbott J, Lin AM, Daud AI and Coakley FV. Tumor fistulization associated with targeted therapy: computed tomographic findings and clinical consequences. *J Comput Assist Tomogr* 2011; 35: 86.
- [14] Wang B, Thomas R, Moskovic E, Benson C and Linch M. Fistulation as a complication of intra-abdominal soft-tissue sarcomas; a case series. *J Radiol Case Rep* 2013; 7: 15-21.
- [15] Chinese Diagnosis and Treatment Experts Group for Gastrointestinal Stromal Tumors. Chinese consensus in diagnosis and treatment of gastrointestinal stromal tumor [J]. *Chinese Journal of Pathology* 2009; 38: 697.
- [16] Ffaivre S, Delbaldo C, Vera K, Robert C, Lozhic S, Lassau N, Bello C, Deprimo S, Brega N, Massimini G, Armand JP, Scigalla P, Raymond E. Safety, pharmacokinetic, and antitumor activity of SU11248, a novel oral multitarget tyrosine kinase inhibitor, in patients with cancer. *J Clin Oncol* 2006; 24: 25-35.
- [17] Fleischmann W, Strecker W, Bombelli M and Kinzl L. Vacuum sealing as treatment of soft tissue damage in open fractures. *Unfallchirurg* 1993; 96: 488-492.
- [18] Fleischmann W, Lang E and Kinzl L. Vacuum assisted wound closure after dermatofasciotomy of the lower extremity. *Unfallchirurg* 1996; 99: 283.
- [19] Fleischmann W, Russ M and Marquardt C. Closure of defect wounds by combined vacuum sealing with instrumental skin expansion. *Unfallchirurg* 1996; 99: 970-974.
- [20] Fleischmann W, Lang E and Russ M. Treatment of infection by vacuum sealing. *Unfallchirurg* 1997; 100: 301-304.
- [21] Patmo AS, Krijnen P, Tuinebreijer WE and Breederveld RS. The effect of vacuum-assisted closure on the bacterial load and type of bacteria: a systematic review. *Adv Wound Care* 2014; 3: 383-389.
- [22] Huang XF, Yu WH. Treatment of the wounds following type III open fractures with vacuum sealing drainage. *Orthopedic Journal of China* 2010; 18.
- [23] Lejay A, Creton O, Thaveau F, Bajcz C, Stephan D, Kretz JG and Chakfé N. Current clinical applications of vacuum-assisted closure (VAC) in vascular surgery. *J Mal Vasc* 2008; 33: 196-201.
- [24] Lam WL, Garrido A and Stanley PR. Use of topical negative pressure in the treatment of chronic osteomyelitis. A case report. *J Bone Joint Surg Am* 2005; 87: 622.
- [25] Genecov DG, Schneider AM, Morykwas MJ, Parker D, White WL and Argenta LC. A controlled subatmospheric pressure dressing increases the rate of skin graft donor site reepithelialization. *Ann Plast Surg* 1998; 40: 219-225.
- [26] Labanaris AP, Polykandriotis E and Horch RE. The effect of vacuum-assisted closure on lymph vessels in chronic wounds. *J Plast Reconstr Aesthet Surg* 2009; 62: 1068-1075.