

## Original Article

# Surgical treatment of comminuted patellar fractures by a percutaneous Pырford technique

Kaihua Zhou, Jun Yang, Fugen Pan

Department of Orthopedic Surgery, Qingpu Branch of Zhongshan Hospital of Fudan University, Shanghai, China

Received March 16, 2017; Accepted October 12, 2017; Epub November 15, 2017; Published November 30, 2017

**Abstract:** *Objective:* In this study, we introduce a novel application of the percutaneous Pырford technique to fix comminuted patellar fractures and evaluate its outcome. *Methods:* A total of 28 patients admitted to our hospital, from February 2008 to June 2013, with comminuted patellar fractures were included in this study. Radiographs, pain, surgery time, range of motion, functional score and complications were evaluated. *Results:* The mean operation time was  $72.3 \pm 31.9$  minutes. Intraoperative fluoroscopy was  $7.6 \pm 2.4$  times. All patients were followed up for a mean period of 34.4 months (13 to 53 months). Radiographic evidence of solid fracture union was observed in all cases in a mean time period of  $13.7 \pm 2.6$  weeks. The Visual Analog Scale (VAS) score for pain was  $3.4 \pm 1.0$  at 4 weeks after surgery, and  $1.2 \pm 1.0$  when radiographic fracture healing occurred. At the latest follow-up, the range of motion was on average  $139.8 \pm 5.4^\circ$ . The average Bostman score was  $28.8 \pm 1.0$  at 1 year after surgery, and an evaluation of "excellent" was given to 26 patients at the final follow-up. We only encountered one case with a broken steel wire, but the fracture had already been united. There were no other complications, such as broken K-wire, fracture displacement, wound infection or non-union. *Conclusion:* Surgical treatment of the comminuted patellar fractures by the percutaneous Pырford technique achieved satisfactory clinical outcomes and knee function in the selected patients. Its advantage is small incision, simple operation, anatomical reduction, fixation stability, and achieves early mobilization.

**Keywords:** Minimally invasive technique, comminuted patellar fracture, Pырford technique

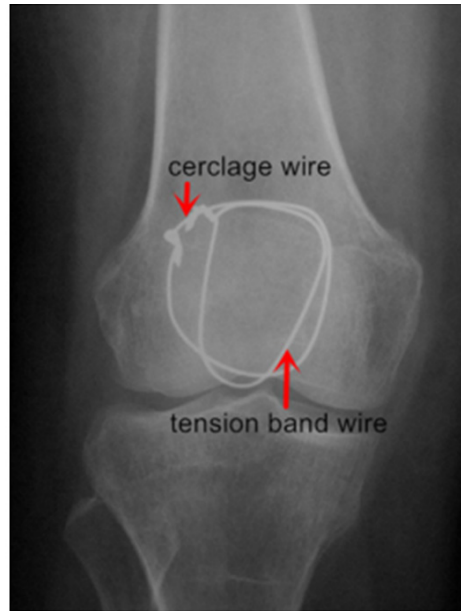
## Introduction

The patella plays a crucial role in the process of knee extension [1]. It accounts for about 0.5-1.5% of all fractures [2]. For the comminuted patellar fractures, we need to anatomically reduce the articular surface, rigidly fix it and accelerate the ability of the patients to perform functional exercise. Traditional open reduction with AO tension band principles has gained great popularity, but it also results in some postoperative complications, such as infection and prolonged rehabilitation [3-9]. There have been several reports about the use of percutaneous minimally invasive surgery for simple transverse fractures to reduce the incision-associated complications [1, 10-15]. Although, it must be noted that simple transverse fractures are different from comminuted patellar fractures. On the one hand, simple transverse fractures are usually caused by indirect injuries due to the traction between the quadriceps

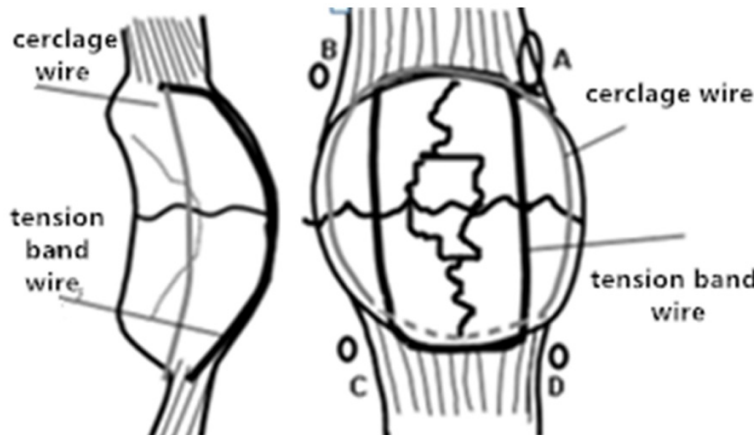
femoris tendon and the femoral fascia attached to the superior pole of the patella and the patellar tendon at the inferior pole. On the other hand, the comminuted patellar fractures are usually caused by direct injuries and the peripatellar soft tissue is almost unbroken. Accordingly, theoretically, percutaneous minimally invasive surgery should be much more suitable for the treatment of the comminuted patellar fractures [16-18]. In the current article, we present the results of a small trial using the percutaneous Pырford technique for comminuted patellar fractures and evaluate the outcome.

## Materials and methods

In this study, we retrospectively review all the patella fracture patients treated in our hospital from February 2008 to June 2013. Only the patients treated by the percutaneous minimally invasive technique were included in this study. The exclusion criteria included the following:



**Figure 1.** Pyrford technique: two wires, one is cerclage wire, another is tension band wire.



**Figure 2.** Surgical technique. A: Incision. B, C and D: Another three puncture points.

simple patellar fracture, open fractures, patient with a history of knee joint surgery. The study was approved by the ethics review committee of the Qingpu branch of Zhongshan hospital of Fudan University and written informed consent was obtained from all patients. In total, there were 28 patients included, 17 of whom were male and 11 of whom were female. The average age was 57.7 years old (33 to 78 years old). According to Muller's AO classification, nine cases were C2.1, five were C2.2, two were C2.3, six were C3.1, two were C3.2 and four were C3.3. The mode of injury included simple

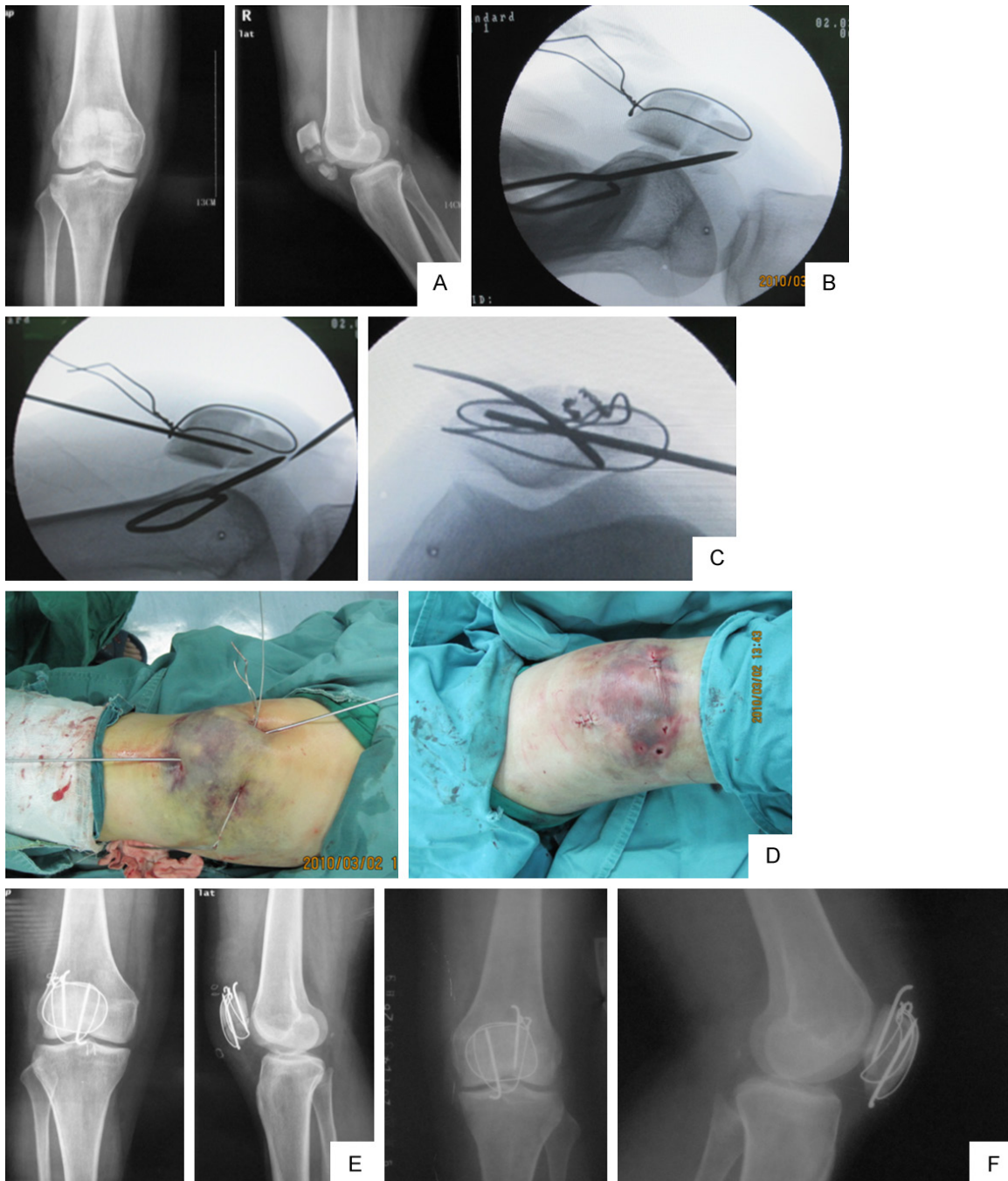
falls (n = 23) and road traffic accidents (n = 5). The average waiting time for surgery was 1.7 d (0~4 d).

*Surgical technique*

General anesthesia or combined spinal-epidural anesthesia was used. The patient was in supine position and knee was draped in the extended position. A thigh tourniquet was not used. The fixation method used was the Pyrford technique with two wires described by Curtis [19]. A circumferential cerclage wire was passed in a purse-string fashion close to the bone. A second wire was passed through the quadriceps tendon, looping anteriorly across the patella and through the patellar tendon to act as a tension band (**Figure 1**). First, we aspirated the hematoma in the articular cavity using a needle. Next, a longitudinal incision of about 0.5-1 cm was made at the superolateral aspect of the patella. And three other puncture points were chosen over the lateral limits of the upper and lower borders of the patella (**Figure 2**). A self-made passer was used to transversely penetrate from the superlateral incision to the supermedial puncture point horizontally across the superior border of the

patella. The knee was then elevated and flexed at about 20°. The passer was then reintroduced and pierced out of the inferomedial puncture point. Then, the passer was passed through the patellar tendon along the inferior border of the patella to the inferolateral puncture point. Ultimately, the passer was back to the superlateral incision, the  $\Phi$  1.5 mm wire was punctured with the passer and the two ends of the wire came out through the superlateral incision. Then, the cerclage wire was tightened to gather the comminuted fragments and maintain the reduction. Next, the knee joint

## Minimal invasive treatment of patellar fractures



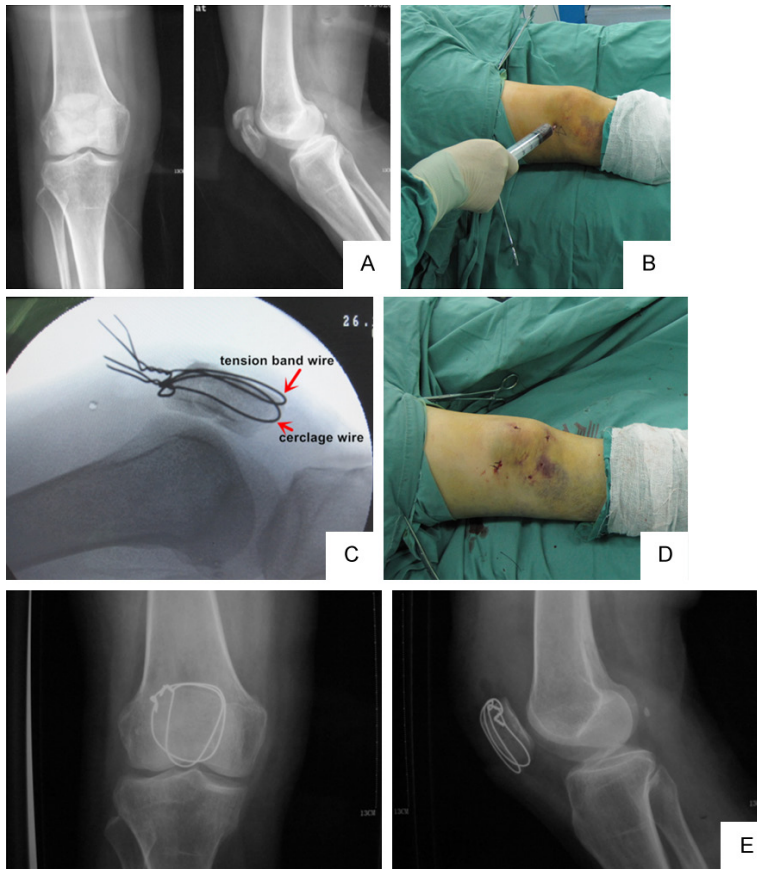**Figure 3.** Patient, female, 44 y, traffic accident, right comminuted patellar fracture, AO C2.1. A. A preoperative AP and lateral view radiograph shows the comminuted patellar fracture. B. The bundling wire was fixed first, and then the articular was pry-poked repositioned by the K-wire under minimally invasive technique. C. Fixation by the K-wire and the lateral view and axial view to judge the articular surface. D. Incision: only 3 longitudinal incision and 3 puncture points. E. AP and lateral view post-operation. F. AP and lateral view when the fracture was united.

was flexed several times and the wire was tightened again when the knee was at the extended position. Lastly, the reduction was confirmed by fluoroscopy. If the anterior part of the patella was opened, the tension band wire was tight-

ened, whereas if the articular surface of the patella was still opened, the cerclage wire was tightened and then the knee joint was extremely flexed to make the reduction better. If the close manipulative reduction was not success-



## Minimal invasive treatment of patellar fractures



**Figure 4.** Patient, Female, 63 y, car accident, right comminuted patellar fracture, AO C3.2. A. AP and lateral view pre-operation. B. We extracted the hematoma in the articular cavity with the needle. C. The tension band wire and bundle wire were used to fix the fracture. D. Incision: only 1 longitudinal incision and 3 puncture points. E. AP and lateral view when the fracture was united.

ful, the fracture reduction can be assisted percutaneously using a Kirschner wire (K-wire) or a Weber clamp.

For comminuted fracture with larger fracture fragments, the K-wire can also be used to fix the fracture fragments. The fractures were first reduced using the procedures described above. After the patellar reduction was confirmed by fluoroscopy, the knee was flexed at 30°, and the entry point of the K-wire was subsequently confirmed. Usually they were located in the middle-outer 1/3 and middle-inner 1/3 of the superior or inferior patella. Next, two longitudinal incisions of about 0.5-1 cm were made at the entry point and two 2-mm K-wires were passed percutaneously to fix the fracture fragments. The K-wire was best located at the middle-posterior 1/3 of the patella on the sagittal plane. Subsequently, we made sure that there was no step-offs in the articular surface. Then,

the knee was flexed and extended again before the wire was ultimately tightened and the K-wires were twisted, knotted and shortened. Finally, the small incisions were sutured and closed (Figures 3 and 4).

### Postoperative management

The fractures did not require external fixation, such as plaster or brace. The isometric contraction exercise of the quadriceps femoris muscle was allowed one day after the surgery. Afterwards, the knee flexion and extension were performed at 2~3 d postoperatively. The active flexion could reach above 90° at 4~5 d postoperatively. The patients were allowed to gradually walk with stitches after the knee active extension was powerful enough in 7 d. Stitches were removed in 2~3 weeks.

### Follow-up

Follow-up assessment, including clinical and radiographic examinations, was performed once a month until the fracture united. Solid union was defined by the presence of cross trabeculations. Pain was measured using the Visual Analog Scale (VAS) with scores from 0 (no pain) to 10 (the most intense pain). Clinical outcomes were assessed using the Bostman score one year after surgery.

### Statistical analysis

Data analyses were performed using the SPSS 18.0 software (IBM Corp. Armonk, NY, USA). General data is analyzed by descriptive analysis, and quantitative data are expressed as the mean  $\pm$  standard deviation. The t-test was used to compare outcomes. A *p*-value of < 0.05 was considered statistically significant.

### Results

The mean surgery time was 72.3  $\pm$  31.9 minutes and the intraoperative fluoroscopy was 7.6

## Minimal invasive treatment of patellar fractures

$\pm 2.4$  times. K-wires were used as accessory fixation in 5 patients: 1 in C2.1, 2 in C2.2, 1 in C2.3 and 1 in C3.1. All patients were followed up for a mean time period of 34.4 months (13-53 months). Radiographic evidence of the union of the solid fracture was observed in all cases in a mean time period of  $13.7 \pm 2.6$  weeks. The VAS score was  $3.4 \pm 1.0$  at 4 weeks after surgery and  $1.2 \pm 1.0$  when the healing of the radiographic fracture was achieved. At the last follow-up, the range of active flexion and extension of the knee joint was  $139.8^\circ \pm 5.4^\circ$ . The mean Bostman score was  $28.8 \pm 1.0$  at 1 year after surgery, and an evaluation of "excellent" was rendered in 26 patients at the final follow-up. We only encountered one case with broken steel wire, but the fracture had already united. There were no other complications, such as broken K-wire, fracture displacement, wound infection and non-union of bone. A total of 24 patients had the implants removed about 1.5 year after the first surgery.

### Discussion

The objective of treating patellar fractures is to restore its function. An anatomical reduction of the articular surface should be performed in order to prevent traumatic arthritis. Open reduction followed by fixation with a tension band wire has been widely performed to treat patellar fractures. Although it should be noted that percutaneous tension band wiring for mildly displaced patellar fractures have also achieved excellent results [10]. With the development of the minimally invasive surgical approach, minimally invasive surgery is the current trend to treat the patellar fractures, as it can significantly reduce the damage to the local blood supply, allow early functional exercise and rehabilitation, which can result in good knee joint function, as well as reduce the iatrogenic adhesion formation of the joint and muscular injury.

Compared with traditional open reduction and internal fixation surgery, not only was the VAS score of the patients treated with the minimally invasive method lower, but the patients were also able to start rehabilitation earlier and suffered less postoperative complications [11-14]. However, these studies were focused on simple transverse patellar fractures with tension band. To the best of our knowledge, our study is the first to use the percutaneous Pylford tech-

nique to treat the comminuted patellar fractures. Compared with the modified tension band, in the biomechanical test, the Pylford technique provides greater strength of fixation and the patients can achieve early mobilization, especially the comminuted fracture of the patella that can be difficult to fix with interfragmentary K-wires and a simple tension band, which highlights the advantages of the Pylford technique [19, 20]. The surgical process and clinical results suggest that the treatment of comminuted patellar fracture with percutaneous Pylford treatment is feasible and achieves good clinical outcomes.

Only one longitudinal incision and three puncture points were required in the whole surgical procedure. If the K-wire was used for strengthening the fracture fixation, another two longitudinal incisions were made. The soft tissue does not require to be widely exposed. All the above procedures were in accordance with the minimally invasive requirements. Patients end up with smaller scars and there was less interference with soft tissue, which can result in lower postoperative pain. The VAS scores of the patients at 1 m postoperative and fracture healing were  $3.4 \pm 1.0$  and  $1.2 \pm 1.0$  respectively, which were consistent with clinical results previously reported by Mao [7]. Specifically, Mao's research showed that the VAS scores in the open reduction group were  $5.6 \pm 1.3$  and  $2.6 \pm 1.2$  at 1 m postoperative and fracture healing, respectively. The decrease of VAS score showed an advantage of minimally invasive operation. Specifically, the patient's postoperative pain and discomfort were also reduced. In addition, the rigid internal fixation made it possible for the patients to start rehabilitation earlier, which can also lead to better functional activity performance. The knee activity degree was  $139.8 \pm 5.4^\circ$  at the last follow-up in our patients, which was much higher than that of the open reduction group reported by Chiang [12]. There was little blood supply disruption around the fracture during the surgical procedure, and this can promote the healing of the fractures. We only found one case with broken steel wire, but the fracture had already united. There were no other complications, such as broken K-wire, fracture displacement, wound infection or non-union of bone. The removal of the implants was much easier, as we only needed to use the original incision to perform the operation.

## Minimal invasive treatment of patellar fractures

However, it is important to point out that this percutaneous Pырford technique also had its disadvantages in the treatment of comminuted patellar fracture. For instance, the patellar articular surface requires anatomic reduction, but the articular surface cannot be seen or touched directly, so we had to use fluoroscopy to visualize the articular surface. Admittedly, the intraoperative fluoroscopy times also increased. For instance, our fluoroscopy time was  $7.6 \pm 2.4$ , which was higher than the minimally invasive treatment of simple transverse patella fracture [14]. Moreover, the operation time was also increased, with an average operation time of  $72.3 \pm 31.9$  min in our group. Such operation time is significantly higher than those of the minimally invasive and open reduction groups reported by Mao [13], whose patients presented with simple transverse patellar fracture, as well as those by Li [15], who treated patients with comminuted patellar fractures by open reduction and internal fixation. Nevertheless, like with any new technology, there is a learning curve to master this new procedure. Indeed, we have been able to effectively control the fluoroscopy and operation times in more recent surgeries.

We now summarize the clinical experience and further clarify the indication for the percutaneous Pырford technique to treat the comminuted patellar fracture. The indications are as follows:

The fracture fragments in the upper and lower pole of the patella were relatively intact.

The articular surface displacement should be no more than 2.5 cm. This is based on the fact that there is failure in 5 patients whose articular surface displacement was larger than 2.5 cm and were therefore instead treated by open reduction and internal fixation. Maybe in the future, the indication can be expanded with the improvement of our percutaneous Pырford approach.

The anterior knee soft tissue contusion was not suitable for open reduction and internal fixation.

The relative contraindications were as follows:

The percutaneous Pырford technique was not suitable for the repair of quadriceps of femoris avulsion fracture.

The closed reduction was difficult during the operation and the soft tissue was suspected to be embedded in the fracture.

Conspicuous compressive fracture or the articular surface fracture fragments were dissociated in the articular cavity.

We also have some additional recommendations for the proper use of this technique. First, the surgeon should be familiar with the anatomy of the knee joint and master the technique of open reduction and internal fixation. Second, the surgeon should pay close attention to the following points:

The hematoma should be extracted before reduction, which not only allows the surgeon to feel the patella and judge its position much better, but also reduces the postoperative joint adhesion formation, resulting from hematoma fibrosis and bound muscle, as well as the damage to the articular cartilage.

Dedicated needle holder forceps should be used to hold the puncture passer tail, which contributes to control the puncture direction and intensity.

The puncture passer should be much closer to the upper and lower pole of the patella and pierce the middle-posterior layer of the quadriceps tendon and patellar ligament as far away as possible. Anatomical studies have shown that quadriceps tendon attachment to the patella is relatively deep, while the patellar ligament is superficial. Thus, to pass the suitable channel, after the puncture passer enters the tissue, the distance from the posterior patella should be carefully explored with its tip, so as to determine the optimal position of the puncture.

The knee should be flex at  $25^\circ$  when the puncture passer is pierced. The steel wire should be fixed close to the anterior patella, which contributes to reduce the fracture fragments and stabilizes the fixation during the process of tightening the steel wire.

The steel wire bending or distorting should be prevented. The preselected wire length should be 2.5 times larger than the circumference of the patella. A shorter steel wire would cause twisting, and even bending and breakage of the steel wire.

## Minimal invasive treatment of patellar fractures

If the fracture fragments comminution is not serious, especially in young patients, a K-wire should be used to assist the fixation. This is because the less the fracture lines, the smaller the patella strain value, and when the patients flex and extend the knee, the stress is prone to be concentrated. Accordingly, without the K-wire fixation, the fracture appears to be displaced, resulting in the failure of the operation. The wire should be bundled up for fracture reduction and temporarily fixed before the K-wire is inserted in order to avoid the displacement of the fracture fragments when the K-wire is inserted. The two K-wires should be placed at the junction of the middle-medial 1/3 and the middle-lateral 1/3 of the patella on the coronary view, the middle-posterior 1/3 of the patella on the sagittal view. The patella is thicker and its bone quality is relatively stiff. Moreover, the stability is better after internal fixation, which is conducive to the stability of the articular surface and early rehabilitation.

The fracture reduction should be assessed by fluoroscopy. If the anteroposterior and lateral views do not clearly display the reduction, the oblique view can be used to judge the reduction. To determine whether the lateral patellar articular surface is anatomically reduced, the knee joint should be placed with an extortion of about 30°, while a 20° intorsion of the knee can display the medial patellar articular surface.

If the closed reduction is difficult, it is probably due to the embedding of soft tissue in the fracture interspace. In such cases, a K-wire or other instruments can be used to percutaneously remove the soft tissue from the fracture interspace.

If, after trying this closed method 2-3 times, the articular surface can still not be anatomically reduced, then the surgical approach should be changed to the open reduction and internal fixation method, so as to avoid the aggravation of the fracture due to an iatrogenic injury. In our study, 5 patients who were originally planned to be treated by the minimally invasive surgery underwent open reduction and internal fixation instead because we could not perform the articular surface anatomical reduction percutaneously during the surgery.

Overall, we can conclude that the treatment of comminuted patellar fracture by the percutane-

ous Pylford technique is feasible and achieves satisfactory clinical outcomes. The incision is small, the internal fixation is rigid and reliable, and the patients can start rehabilitation much earlier.

### Acknowledgements

The study was funded by the Department of Orthopedics, Qingpu branch of Zhongshan Hospital of Fudan University.

### Disclosure of conflict of interest

None.

**Address correspondence to:** Jun Yang, Department of Orthopedic Surgery, Qingpu Branch of Zhongshan Hospital of Fudan University, 1158 Gongyuan East Road, Qingpu District, Shanghai 201700, China. Tel: +86 21 69719190\*7720; E-mail: burker1983216@aliyun.com

### References

- [1] Matsuo T, Watari T, Naito K, Mogami A, Kaneko K and Obayashi O. Percutaneous cerclage wiring for the surgical treatment of displaced patella fractures. *Strategies Trauma Limb Reconstr* 2014; 9: 19-23.
- [2] Galla M and Lobenhoffer P. [Patella fractures]. *Chirurg* 2005; 76: 987-997; quiz 998-989.
- [3] Perry CR, McCarthy JA, Kain CC and Pearson RL. Patellar fixation protected with a load-sharing cable: a mechanical and clinical study. *J Orthop Trauma* 1988; 2: 234-240.
- [4] Us AK and Kinik H. Self locking tension band technique in transverse patellar fractures. *Int Orthop* 1996; 20: 357-358.
- [5] Wu CC, Tai CL and Chen WJ. Patellar tension band wiring: a revised technique. *Arch Orthop Trauma Surg* 2001; 121: 12-16.
- [6] Gosal HS, Singh P and Field RE. Clinical experience of patellar fracture fixation using metal wire or non-absorbable polyester—a study of 37 cases. *Injury* 2001; 32: 129-135.
- [7] Hung LK, Chan KM, Chow YN and Leung PC. Fractured patella: operative treatment using the tension band principle. *Injury* 1985; 16: 343-347.
- [8] Smith ST, Cramer KE, Karges DE, Watson JT and Moed BR. Early complications in the operative treatment of patella fractures. *J Orthop Trauma* 1997; 11: 183-187.
- [9] Luna-Pizarro D, Amato D, Arellano F, Hernandez A and Lopez-Rojas P. Comparison of a technique using a new percutaneous osteosynthesis device with conventional open

## Minimal invasive treatment of patellar fractures

- surgery for displaced patella fractures in a randomized controlled trial. *J Orthop Trauma* 2006; 20: 529-535.
- [10] Leung PC, Mak KH and Lee SY. Percutaneous tension band wiring: a new method of internal fixation for mildly displaced patella fracture. *J Trauma* 1983; 23: 62-64.
- [11] Rathi A, Swamy MK, Prasantha I, Consul A, Bansal A and Bahl V. Percutaneous tension band wiring for patellar fractures. *J Orthop Surg (Hong Kong)* 2012; 20: 166-169.
- [12] Chiang CC, Chen WM, Jeff Lin CF, Chen CF, Huang CK, Tzeng YH and Liu CL. Comparison of a minimally invasive technique with open tension band wiring for displaced transverse patellar fractures. *J Chin Med Assoc* 2011; 74: 316-321.
- [13] Mao N, Liu D, Ni H, Tang H and Zhang Q. Comparison of the cable pin system with conventional open surgery for transverse patella fractures. *Clin Orthop Relat Res* 2013; 471: 2361-2366.
- [14] Mao N, Ni H, Ding W, Zhu X, Bai Y, Wang C, Zhao Y, Shi Z, Li M and Zhang Q. Surgical treatment of transverse patella fractures by the cable pin system with a minimally invasive technique. *J Trauma Acute Care Surg* 2012; 72: 1056-1061.
- [15] Yang L, Yueping O and Wen Y. Management of displaced comminuted patellar fracture with titanium cable cerclage. *Knee* 2010; 17: 283-286.
- [16] Melvin JS and Mehta S. Patellar fractures in adults. *J Am Acad Orthop Surg* 2011; 19: 198-207.
- [17] Carpenter JE, Kasman R and Matthews LS. Fractures of the patella. *Instr Course Lect* 1994; 43: 97-108.
- [18] Rhee SJ, Pavlou G, Oakley J, Barlow D and Haddad F. Modern management of patellar instability. *Int Orthop* 2012; 36: 2447-2456.
- [19] Curtis MJ. Internal fixation for fractures of the patella. A comparison of two methods. *J Bone Joint Surg Br* 1990; 72: 280-282.
- [20] Burvant JG, Thomas KA, Alexander R and Harris MB. Evaluation of methods of internal fixation of transverse patella fractures: a biomechanical study. *J Orthop Trauma* 1994; 8: 147-153.