

Case Report

Correction of horizontal mandibular position in an edentulous patient accustomed to mandibular protrusion and deviation using the Gothic arch tracer

Xu Wei, Xiao Ping Luo

Department of Prosthodontics, Nanjing Stomatological Hospital, Medical School of Nanjing University, Nanjing, Jiangsu Province, P. R. China

Received January 5, 2017; Accepted October 7, 2017; Epub November 15, 2017; Published November 30, 2017

Abstract: Objective: Due to the patient long-term habitual mandibular protrusion and deviation, the use of the bilateral manipulation to guide the patient to the centric relation (CR) failed. A technique to obtain the CR by mounting the Gothic arch tracer to an existing complete denture is described in the present report. Methods: A 51-year-old man who had an unsatisfactory complete denture for approximately five years presented to our hospital to make a better complete denture. He complained about poor stability and retention, frequent ulcers and the unaesthetic appearance. The maxillomandibular relationship record (MMRR) was obtained through the conventional bimanual manipulation method. In the customary manner, a new complete denture was finished. After one week of insertion, the patient complained about a sense of suffocation when chewing for a long time. When the patient was told to relax, the anterior artificial teeth were horizontally overlapped by approximately 2 mm. We hypothesized that the previous MMRR may be inappropriate. A Gothic arch tracer was mounted to the existing complete denture to obtain the new MMRR in the CR, and the mandibular artificial teeth were rearranged. Results: The patient did not report any discomfort or a sense of suffocation with the new complete denture. Conclusions: The Gothic arch tracer mounted to the existing complete denture can be used to successfully correct erroneous MMRR and precisely obtain the accurate CR.

Keywords: Gothic arch tracer, complete denture, mandibular protrusion, mandibular deviation

Introduction

The determination of the correct maxillomandibular relationship record (MMRR) is one of the most sensitive and rigorous procedures in complete denture manufacture. The centric relation (CR) is recorded for the edentulous patients due to its relative reproducibility [1]. For some patients, it is difficult to determine the CR due to the habitual closure induced by the previous inadequate dentures.

There are two kinds of methods to determine the CR: patient-guided recording methods and operator-guided recording methods [2]. It can be a challenge both for dentists and patients when using the operator-guided recording method. Inexperienced dentists are prone to obtain an erroneous MMRR, especially for the patients with long-term habitual mandible protrusion and deviation. The Gothic arch tracer has been acknowledged as one of the most reliable

and accurate patient-guided methods for obtaining the CR, which is especially suitable for the patients who could not obtain the correct MMRR by operator-guided recording methods.

A method for determining the CR using the Gothic arch tracer mounted to an existing complete denture is described in the present article. This article describes this technique that used to correct the erroneous MMRR complete denture for a 51-year-old patient accustomed to mandibular protrusion and deviation.

Case report

Clinical information

A 51-year-old man came to our hospital for a new complete denture. He had a maxillary complete denture and a mandibular removable partial denture (RPD) seven years ago. Five years

Correction of jaw position using the Gothic arch tracer

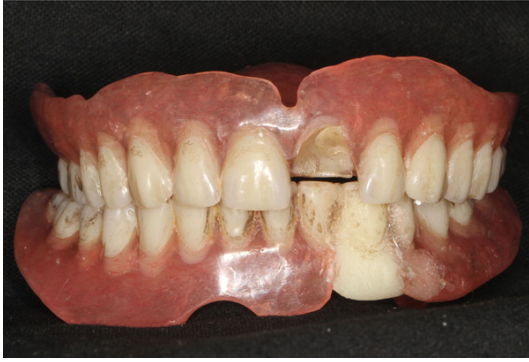

Figure 1. Old complete denture.

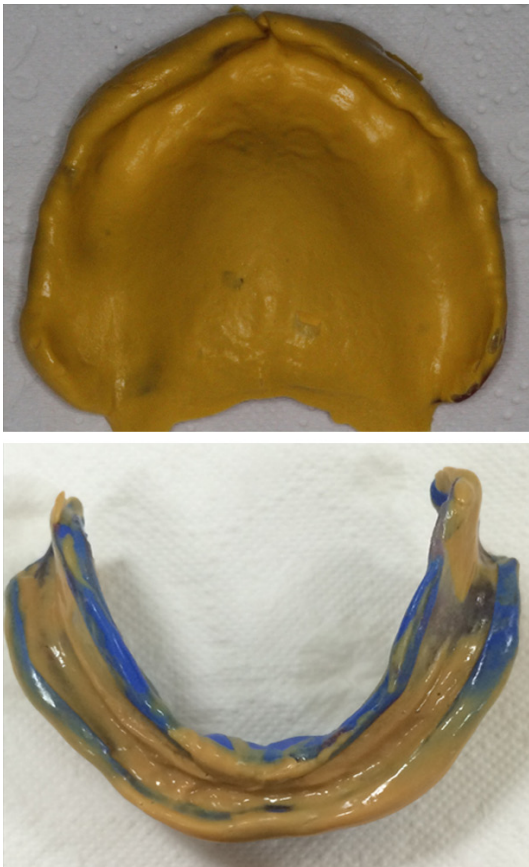


Figure 2. Definitive impressions.

ago, his left mandibular lateral incisor fell off. The dentist grounded off the RPD clasp and added an artificial tooth. He was dissatisfied with the complete denture due to the poor stability and retention, frequent ulcers and the unaesthetic appearance. Hence, the patient wanted a better complete denture. The old denture revealed a significant occlusion wear and the broken left upper first central incisor (**Figure 1**).

Therapeutic process

Definitive impressions were made with silicone impression material (Virtual, Ivoclar Vivadent AG, Liechtenstein) using individual acrylic-resin impression trays (Individuo Lux, VOCO, Germany) (**Figure 2**). Visible light-cured bases (Individuo Lux, VOCO, Germany) were adapted to the casts for making accurate MMRR bases. Softened wax (Paraffin wax, GC, Japan) was gradually added onto the occlusion rims to achieve simultaneous bilateral contact. MMRR was detected and verified using the bilateral manipulation method [3]. During the complete denture try-in, the patient felt comfortable. In the customary manner, a new complete denture was finished.

After one week from insertion, the patient reported that the denture bases were suitable without pain. However, when chewing for a long time, he felt that the mandible was in the protrusion position by force, followed by the sense of suffocation. It was found that when the patient's mandible deliberately protruded, he could achieve simultaneous bilateral contact (**Figure 3**). However, when the patient was told to relax, the anterior artificial teeth were horizontally overlapped by approximately 2 mm (**Figure 4**).

According to the patient's complaints and MMRR conditions, we hypothesized that the previous MMRR may be inappropriate. Because the denture bases were suitable and the maxillary complete denture esthetic appearance was good, the mandibular artificial teeth were rearranged to correct the erroneous MMRR. Due to the patient long-term habitual mandibular protrusion and deviation, the use of the bilateral manipulation to guide the patient to the CR failed. The Gothic arch tracer (Centrofix, Amann Girrbach AG, Austria) was mounted to the existing complete denture with visible light-cured material (Individuo Lux, VOCO, Germany) (**Figure 5**). The tracing ball was set on the maxilla, and the tracing recording table was set on the mandible. The other end of the tracing ball was a screw, and the vertical dimension of occlusion (VDO) could be adjusted through it. Since the patient's VDO was acceptable, the screw and the tracing ball was adjusted to contact the tracing recording table, and the investigator made sure that the recording table was parallel to the Camper's line. The tracing ball and recording table

Correction of jaw position using the Gothic arch tracer

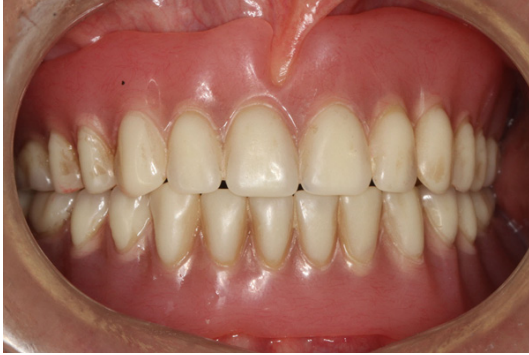

Figure 3. Simultaneous bilateral contact in the protrusion position.

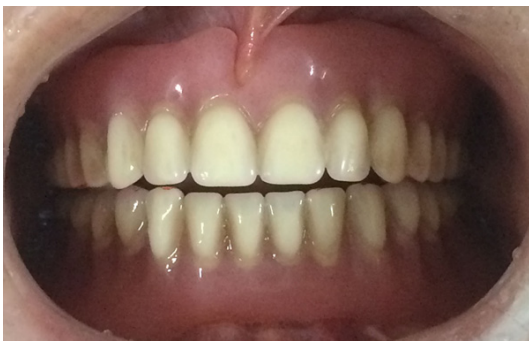

Figure 4. Anterior artificial teeth were horizontally overlapped by approximately 2 mm in the relaxation position.



Figure 5. Mounting the Gothic arch tracer to the existing complete denture.

were the only point of contact during the mandibular protrusion and laterotrusion movement by grinding the bilateral mandibular artificial teeth for approximately 2 mm. Repetitious trainings were performed for the patient's mandibular protrusion and laterotrusion movements until an accurate arrow point tracing (Gothic arch apex, GoA) was obtained (Fig-

ure 6). A fine hole in the plastic cover was placed at the GoA to engage the stylus in the CR when the interocclusal recording material (O-bite, DMG, Germany) was being made.

The mandibular position was observed in the articulator. It is obvious that the CR obtained through the Gothic arch tracer was posterior to the previous mandible position (Figure 7). This suggests that the previous mandible position was protruded. In the new maxillomandibular relationship, the mandibular artificial teeth were rearranged. During the complete denture try-in, the patient felt comfortable during mastication and relaxation without the sense of suffocation. When the final complete denture was inserted for a month, the patient did not report any discomfort or the sense of suffocation (Figure 8). Recall appointments were scheduled 3 months, 6 months and 12 months, the patient reported improvements in chewing and speaking in addition to his appearance.

Discussion

The accuracy of the maxillomandibular relationship is very important for an appropriate complete denture [4]. Fenlon has demonstrated a positive correlation between complete denture usage and the accuracy of the MMRR [5]. Although how to obtain the maxillomandibular relationship record has been reported in some case reports (Table 1), our patient was specific and required a specific method.

An inappropriate complete denture would lead to mandibular protrusion and deviation [11]. The patient's old complete denture, which was used for approximately five years, was modified from the removable partial denture by adding an artificial tooth. The uneven wear of the artificial teeth occlusal surface, unsuitable tissue surface and poor conditions of the retention and stability of the complete denture allowed the patient to be accustomed to unilateral mastication (UM). The occlusal abrasion reinforced the habitual mandibular protrusion [12]. Using the patient-guided recording methods to obtain the MMRR should be prone to be failure.

Due to the habitual closure induced by the previous unsuitable complete denture, obtaining the CR failed when using the Dawson's bilateral manipulation method (BM). BM is a kind of

Correction of jaw position using the Gothic arch tracer

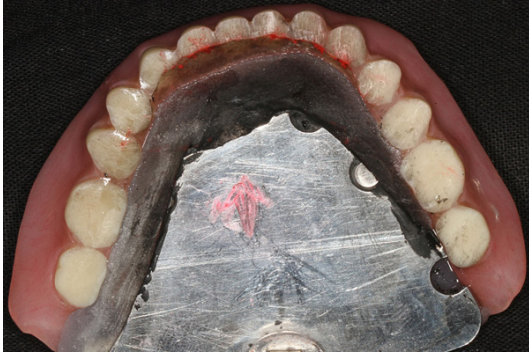

Figure 6. The Gothic arch apex for the CR was obtained.

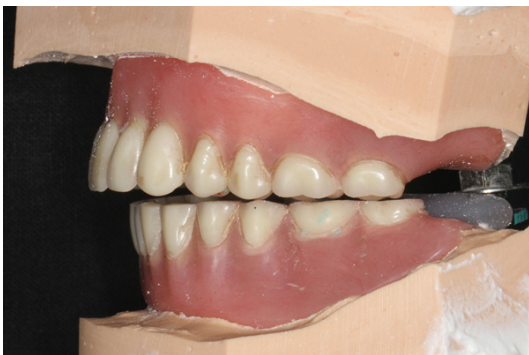

Figure 7. The new mandibular position obtained by the Gothic arch tracer was posterior to the previous mandibular position.

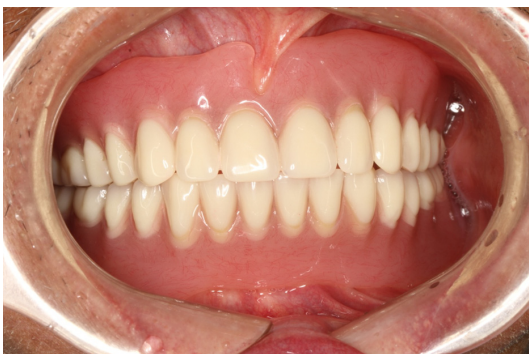

Figure 8. Intra oral view of the new complete denture.

operator-guided recording method. The little finger is placed behind the angle of the mandible with the other four fingers positioned on the lower border of the mandible. Thumbs should touch and fit into the notch above the symphysis. The operator manipulates the jaw hinged to the CR with a very gentle touch. Forceful mandibular retrusion by the operator

may cause patient discomfort, which will result in reflex mandibular protrusion and hence erroneous recording.

Compared to the force by the operator, the force applied by the patient from the muscles of the mastication is beneficial when locating the mandible in the appropriate position [13]. In addition, it has been suggested that restoring a patient to this position may result in enhanced masticatory efficiency and occlusal stability. The Gothic arch tracer is a patient-guided method to obtain the CR. It can record the motion track of the patient's mandible objectively and take the tip of the arrow angle as the CR. Due to its easy-operation and repeatability, the Gothic arch tracer has been acknowledged as one of the most reliable means of recording the CR.

The Gothic arch tracer was used to obtain the CR for a newly fabricated complete denture with wax occlusion rims [14]. The purpose of this article was to present a method of mounting the Gothic arch tracer to an existing complete denture to correct the previous erroneous MMRR. The accurate Gothic arch tracing needs stable and retentive bases to obtain the correct MMRR. The stability and fitness of the existing complete denture bases are better than the temporal record bases or wax bases. The Biofunctional Prosthetic System (BPS, Ivoclar Vivadent AG, Liechtenstein) for complete denture uses the 'Gnathometer M', which consists of wax rims and the Gothic arch tracer mounted to the final impression. This can provide better retention and stability, and is also easier to operate compared with the traditional Gothic arch tracer [15]. But the 'Gnathometer M' is an expensive and special device. Using the existing complete denture mounted with the Gothic arch tracer is an inexpensive, simple and reliable alternative.

In previous literature reports, complaints from patients with unsatisfactory complete dentures were frequent ulcers, poor retention, attritional denture teeth, low vertical dimension, dissatisfaction with the appearance, and repeated denture fractures. Recurrent headache and mandible dysfunction were also reported [16]. However, the complaint from a complete denture wearer, which was the sense of suffocation, has not been reported. We hypothesized that the inappropriate MMRR would change the

Correction of jaw position using the Gothic arch tracer

Table 1. Methods used to obtain maxillomandibular relationship record (MMRR) of the edentulous patients

Author	Patient	Recording method
Millet C, Jeannin C, Vincent B and Malquarti G	Edentulous patient	The soft wax cones was fixed in the record base, the patient was asked to swallow saliva until the wax cones were in the even contact [6].
Boulos PJ	Edentulous patient	Wax wafer was fixed in the anterior region of the mandibular base. The patient should be asked to put the tip of his or her tongue on the top of wax situated on the posterior border of the maxillary base, according to the Schuyler technique. Fast-setting impression plaster should be injected to the posterior portions [7].
Michalakis KX, Touloumi F, Calvani L, Bedi A and Hirayama H	A patient required converting an interim maxillary complete denture to an interim implant-support fixed complete denture.	Using the old complete denture as the record base, the MMRR was registered using the bilateral manipulation technique [8].
Alfano SG and Leupold RJ	Edentulous patient	The mandibular rim is made from modeling plastic impression compound on a record base formed by the patient into the neutral zone. The practice guided the patient into the centric relation position [9].
Legami CM, Lopes DDM, Nakamae AEM, Uehara PN and Tamaki R	A persistent involuntary protruding complete denture wearer due to an old and worn pair of complete denture.	The Paterson technique was chosen to obtain the MMRR. A mixture of carborundum and plaster is used to individualize the plane of occlusion and to get the horizontal MMRR [10].
Watanabe Y	The edentulous patient's existing dentures showed a decreased vertical dimension of occlusion and occlusal plane abnormalities.	A digital gothic arch tracing device was used to obtain the horizontal mandibular positions and to evaluate the therapeutic effect of the diagnostic dentures [11].

Correction of jaw position using the Gothic arch tracer

stomatognathic muscles and mucous system, and change the size and shape of the airway. This might be the reason of the patient's sense of suffocation with the previous complete denture. This indicates that recording the CR for this kind of patient requires clear guidance though a clinical apparatus rather than through the operator-guided method.

Conclusion

This clinical report describes a technique to correct an erroneous MMRR of a patient with habitual mandibular protrusion and deviation using the Gothic arch tracer mounted to an existing complete denture. It is a simple method to correct the existing erroneous MMRR complete dentures and precisely obtain the CR in the patients with long-term mandibular protrusion and deviation.

Acknowledgements

This work was supported by grants from the Medical Science and Technology Development Foundation, Nanjing (YKK16159).

Disclosure of conflict of interest

None.

Address correspondence to: Xu Wei, Department of Prosthodontics, Nanjing Stomatological Hospital, Medical School of Nanjing University, 30 Zhongyuan Street, Nanjing, Jiangsu Province, P. R. China. Tel: +86 25 83620263; Fax: +86 25 83620200; E-mail: weixu982003@163.com; weixu982003@hotmail.com

References

- [1] Kabcenell JL. Effect of clinical procedures on mandibular position-Journal of prosthetic dentistry. *J Prosthet Dent* 1964; 14: 266-278.
- [2] Wilson PH and Banerjee A. Recording the retruded contact position: a review of clinical techniques. *Br Dent J* 2004; 196: 395-402.
- [3] Dawson P. Determining centric relation. Functional occlusion. Edited by Dawson P. St. Louis, Mosby Elsevier, 2006. pp. 286-303.
- [4] Critchlow SB and Ellis JS. Prognostic indicators for conventional complete denture therapy: a review of the literature. *J Dent* 2010; 38: 2-9.
- [5] Fenlon MR and Sherriff M, Walter JD. Association between the accuracy of intermaxillary relations and complete denture usage. *J Prosthet Dent* 1999; 81: 520.
- [6] Millet C, Jeannin C, Vincent B and Malquarti G. Report on the determination of occlusal vertical dimension and centric relation using swallowing in edentulous patients. *J Oral Rehabil* 2003; 30: 1118-22.
- [7] Boulos PJ. Simplified method for recording maxillomandibular relations in complete dentures. *N Y State Dent J* 2007; 73: 24-27.
- [8] Michalakis KX, Touloumi F, Calvani L, Bedi A and Hirayama H. Simplifying prosthetic procedures while converting an interim maxillary removable complete denture to an interim implant-supported fixed complete denture. *J Prosthodont* 2011; 20: 408-13.
- [9] Alfano SG and Leupold RJ. Using the neutral zone to obtain maxillomandibular relationship records for complete denture patients. *J Prosthet Dent* 2001; 85: 621-623.
- [10] Legami CM, Lopes M, Nakamae AE, Uehara PN and Tamaki R. Different occlusal schemes in a persistent protruding complete denture wearer. *Case Rep Dent* 2016; 2016: 7418686.
- [11] Watanabe Y. Observation of horizontal mandibular positions in an edentulous patient using a digital gothic arch tracer: a clinical report. *J Prosthet Dent* 2004; 91: 15-19.
- [12] Arafa KA. The effects of clinical wear on the incidence of temporomandibular disorders among patients with complete dentures. *J Taibah University Med Sci* 2016; 11: 250-254.
- [13] Keshvad A and Winstanley RB. An appraisal of the literature on centric relation. Part II. *J Oral Rehabil* 2000; 27: 1013-1023.
- [14] Mysore AR and Aras MA. The magic slate as recording medium for gothic arch tracing. *J Prosthet Dent* 2012; 108: 60.
- [15] Abe J, Kokubo K and Sato K. Procedure for fabrication of Gnathometer M-mounted custom trays. Mandibular suction-effective denture and BPS: a complete guide: 4 steps from start to finish: for all types of fully edentulous cases. Edited by Abe Jiro. Tokyo: Quintessence Publishing Co. Ltd; 2012. pp. 137-139.
- [16] Magnusson T. Prevalence of recurrent headache and mandibular dysfunction in patients with unsatisfactory complete dentures. *Community Dent Oral Epidemiol* 1980; 8: 159-164.