

## Original Article

# Anterior cervical surgery combined with manipulative reduction for treatment of lower cervical spine dislocation

Cheng Chen<sup>1\*</sup>, Qingguo Gu<sup>2\*</sup>, Guohua Shi<sup>1\*</sup>, Jie Zhao<sup>2</sup>, Xinwei Wang<sup>1</sup>

<sup>1</sup>Department of Spine Surgery, Changzheng Hospital, The Second Military Medical University, Shanghai, China;

<sup>2</sup>Shanghai Key Laboratory of Orthopaedic Surgery, Shanghai Ninth People's Hospital, Shanghai Jiao Tong University School of Medicine, Shanghai, China. \*Equal contributors.

Received June 24, 2017; Accepted September 28, 2017; Epub November 15, 2017; Published November 30, 2017

**Abstract:** Surgical treatment is a generally accepted and widely used for lower cervical spine dislocation. However, there remains controversy and uncertainty over the best surgical approach. This study aimed to explore the clinical effect of anterior cervical surgery combined manipulative reduction on patients with lower cervical spine dislocation who failed in closed reduction. Retrospective analysis was performed on the clinical data of patients with lower cervical spine fracture and dislocation, as well as small joint loose, who were surgically treated between December 2013 and January 2015. The injured intervertebral disc segments were removed. Dislocated segments that could not be repositioned were subjected to manipulative reduction to facilitate the recovery of the zygapophysial joints and dislocated vertebral body in a normal physiological sequence. Segments that fail to reposition were subjected to surgery with posterior approach. Ten patients with failed closed reduction achieved complete reduction via anterior reduction and internal fixation with manipulative reduction. Six out of the 10 patients were improved by one American Spinal Injury Association (ASIA) grade, whereas the preoperative and postoperative ASIA scores in the other 4 patients remain the same. The average visual analog scale (VAS) scores were significantly reduced after surgery ( $P < 0.001$ ). No aggravation of neurofunction and failure of internal fixation were observed in all patients. In conclusions, anterior cervical surgery with perioperative manipulative reduction can avoid unnecessary combined anterior-posterior surgery and is effective and safe approach for patients with lower cervical spine dislocation who failed in closed manipulative reduction or anterior distraction.

**Keywords:** Cervical spine, dislocation, reduction, surgery

## Introduction

Low cervical vertebra (C3-7) injury is a severe traumatic cervical vertebra disease and frequently encountered in clinical practice. This injury is often caused by traffic accidents and falls from high altitudes, leading to fractures and dislocations in the cervical spine, spinal cord injuries or nerve root injuries, and high disability rates [1]. The prognosis of low cervical vertebra injury is poor. Patients often have cervical deformity, and complete or incomplete paralysis, and thus have decreased quality of life, as well as economic burden because of expensive treatment [2, 3]. Furthermore, some patients die of respiratory complications [4].

It has been demonstrated that cervical spine dislocation occurs in approximately 6.7% of

patients with low cervical vertebra injury, mostly in the C5/6 and C6/7 segments [5]. Currently, there is still no standard surgical management method for lower cervical spine dislocation. Some researchers proposed anterior-posterior-anterior approach for patients with severe lower cervical spine dislocation [4, 6]. However, this approach is a high skill demanding surgery, and need to change the patient's position during the operation, thus prolonging the surgery and increasing the risk of massive hemorrhage. Accordingly, some physicians perform close manipulative reduction before the operation or after anesthesia administration to simplify the procedure [7, 8]. Approximately 40% of patients with lower cervical spine dislocation have intervertebral disk herniation [9]. Spinal cord injury can be aggravated by close-

## Lower cervical spine dislocation

up manipulative reduction when cervical intervertebral disk herniation is present. In addition, the anterior approach has some advantages such as low incidence of complication and simple surgical patient positioning, and herniated disc can be removed before the reduction to prevent secondary spinal cord injury [8, 10]. The surgical procedure is greatly simplified when the dislocated cervical vertebra is restored only through anterior cervical surgery. On the basis of our own experiences, we have improved the reduction method and therapy procedure. Patients with lower cervical spine dislocation who were more difficult to achieve reduction were treated by removing the cervical intervertebral disk, and perioperative manipulative reduction was performed. Ten patients with lower cervical spine dislocation who failed in closed reduction were treated using the anterior approach in combination with perioperative manipulative reduction since December 2013. A satisfactory clinical effect was achieved in all the cases.

### Materials and methods

#### *Patients*

Ten patients with lower cervical spine dislocation with unilateral or bilateral zygapophysial joint noose who failed in closed reduction were treated through anterior cervical surgery with perioperative manipulative reduction from December 2013 to January 2015. The patients comprised 8 males and 2 females, with an average age of 44.7 years (23-60 years). Four cases were caused by falls from high altitudes, 5 cases were caused by traffic accidents, and the cause of 1 case was unidentified. The preoperative anteroposterior and lateral X-ray films of the cervical vertebrae and three-dimensional reconstruction of computed tomography (CT) suggested the presence of lower cervical spine dislocation with zygapophysial joint noose. Four patients had bilateral zygapophysial joint noose, and 6 patients had unilateral zygapophysial joint noose. The magnetic resonance imaging (MRI) showed that patients had the different degrees of protrusions at the intervertebral discs of the dislocated segments, which put pressure on the spinal cord. Two patients had cervical dislocation at the C5/6 segments, and 5 patients had cervical dislocation at the C6/7 segment. Three patients had cervical dislocations at the C2/3, C3/4, and C4/5 seg-

ments, respectively. Subaxial injury classification (SLIC) scoring was performed for all patients prior to surgery. The SLIC score ranged from 6 to 9 points, indicating that patients must undergo surgical treatment [11]. At the same time, the neurological function and the extent of pain patients experienced were evaluated using the ASIA and VAS scores, respectively, before surgery. Two patients had preoperative ASIA grade A impairment, 4 had grade C impairment, 3 had grade D impairment, and 1 had grade E impairment. In addition, patients had varying extents of neck or limb pain, and the average VAS score was 7.03 (4.3-8.7). After admission, patients were provided by persistent skull traction with a weight of 1-3 kg to restrict the movement of neck and prevent the recurrence of spinal cord injury [4]. This study was approved by the Ethics Committee of Changzheng Hospital.

#### *Surgical procedure*

Before the operation, the heavy object for skull traction was removed, whereas the traction bow was retained. Patient lied down on the operating table at supine position, and his or her cervical vertebra was mildly hyperextended. Conventional managements such as tracheal intubation, anesthesia, and muscle relaxation, were then performed. The extent of cervical dislocation and the state of dislocated segment were observed under fluoroscopy. Surgery was initiated under accurate monitoring of the vital signs. Incision through conventional anterior cervical surgery was performed to expose the dislocated segments, and the intervertebral space was opened using a vertebral screw and Caspar distractor for cervical discectomy. The Caspar distractor was removed after the intervertebral disc was removed. Vertebral body was opened using a vertebral screw and deep distractor for reduction. However, the reduction failed because the zygapophysial noose was severe. Thus, manipulative reduction was performed for the dislocated segments.

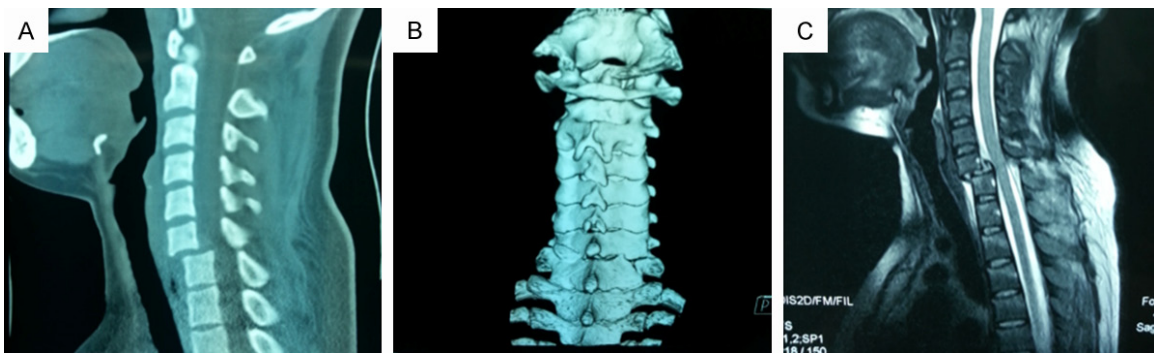
The reduction method was described as follows. The traction bow was held by one hand to tract the cervical vertebra to excessive flexion posture, and the dislocated segment was fixed by the other hand, which was placed at the back of the neck. Proper traction was then applied on the cervical vertebra along the axial

## Lower cervical spine dislocation

**Table 1.** Patient characteristics

Patients	Sex	Age	Cause	Level	SLIC	ASIA		VAS		Dislocation type	Duration of OP
						Preoperation	Postoperation	Preoperation	Postoperation		
A	M	60	Fall	C2/3	9	C	D	4.3	1.2	UFD	90
B	M	23	MVA	C6/7	8	A	A	8.7	2.5	UFD	131
C	M	39	MVA	C5/6	8	D	E	5.4	1.5	BFD	87
D	M	30	MVA	C3/4	9	D	E	6.4	2.0	UFD	70
E	M	36	MVA	C6/7	9	C	D	8.0	3.5	BFD	150
F	F	43	Fall	C6/7	9	C	D	7.8	4.0	BFD	137
G	M	56	Fall	C4/5	8	C	C	6.6	3.8	UFD	80
H	M	51	UNK	C5/6	6	D	E	6.5	1.7	BFD	65
I	M	55	Fall	C6/7	8	A	A	8.1	4.0	BFD	120
J	F	54	MVA	C6/7	9	D	E	8.5	2.0	UFD	134

M, male; F, female; MVA, motor vehicle accident; UNK, unknown; UFD, unilateral facet dislocation; BFD, bilateral facet dislocation.



**Figure 1.** Imaging examination. A and B: CT scan showed a dislocation at C6/7 with left zygapophysial joint noose. C: MRI showed that fibrous ring of the C6/7 intervertebral disk ruptured and the vertebral pulp was pushed into the vertebral canal and put pressure on the spinal cord.

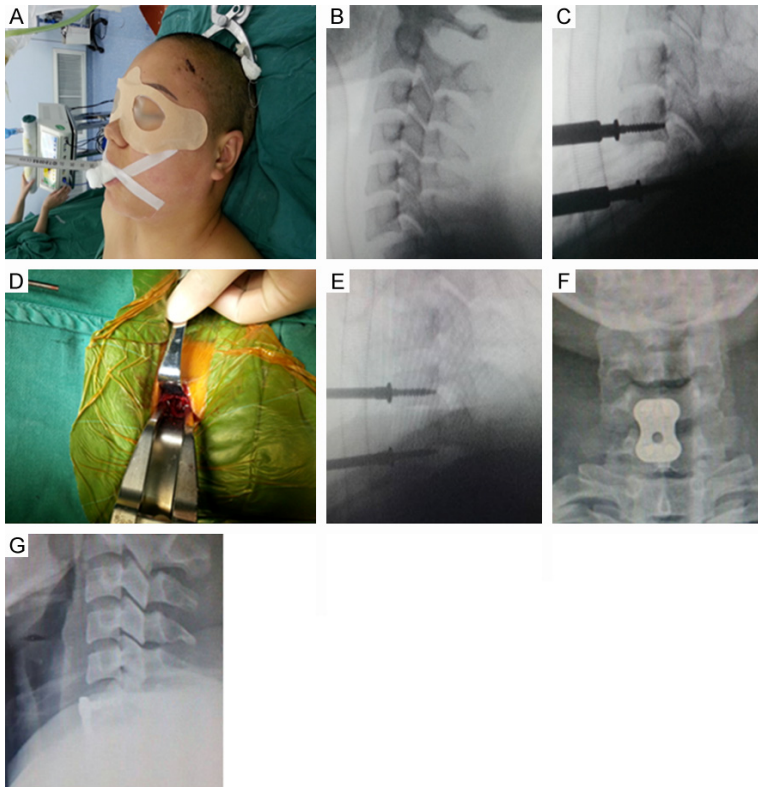
direction (the axial rotation toward the noose side was necessary when the unilateral zygapophysial joint noose was present). The vertebral body under the dislocated segment was pushed forward toward the back of the neck. Mild hyperextension posture for cervical vertebra was returned after the noosed zygapophysial joints and dislocated segments reverted to their normal sequences as observed under fluoroscopy using a C-arm X-ray machine. Fusion operation was performed conventionally after the cervical dislocation had been corrected through manipulative reduction, and the interbody fusion cage was placed while fixation was performed using titanium plates and screws. Interbody fusion surgery for single segment was performed on 8 patients. By contrast, interbody fusion surgery for two segments was performed in the other 2 patients because they have intervertebral disk herniation in other segments and anterior longitudinal ligament tear.

The surgeries lasted no more than 3 hours for all 10 patients, who were performed by physicians with extensive experiences on cervical vertebra surgery. Philadelphia neck care was used to stabilize the cervical vertebra of the patients after the operation.

### Results

The clinical characteristics of 10 patients were listed in **Table 1**. The physiological sequence of the dislocated segment was successfully restored in all 10 patients with lower cervical spine dislocation that was more difficult to reduce. Therefore, patients avoided to be treated with anterior-posterior-anterior approach surgery. After 1 year of follow-up, no obvious aggravation of neurological function and complications resulted from surgery were observed in all patients. The neurological function improved in 3 patients from ASIA grade C to D, 4

## Lower cervical spine dislocation



**Figure 2.** Surgery. A: Heavy object for traction was removed, whereas the traction bow was retained. The patient was laid on the operation table at a supine position, while intubation and anesthesia was administered. B: Fluoroscopy after anesthesia was performed and C6/7 segments were found to be at the state of dislocation. C, D: Intervertebral disc was removed, while vertebral screw and deep distractor were used to perform reduction. However, the reduction of the C6/7 segments still failed. E: The reduction of C6/7 segments become successful, and the normal physiological sequence was recovered after manipulative reduction. F, G: Anterior interbody fusion operation was performed for the C6/7 segments.

patients from ASIA grade D to E, and 3 patients remained no changes which were grade A (2 patients) and grade C (1 patient). Furthermore, pain of all 10 patients was significantly ameliorated compared with preoperative state. The average VAS score at the last follow up was 2.6, which was statistically lower than preoperative pain score (7.0,  $P < 0.001$ ).

One patient (54 years old, female; patient J, **Table 1**) had experienced temporary unconsciousness as a result of a traffic accident. Her limb muscle strength was deteriorated, and the muscle strength of her right upper limb was grade 3. She had experienced pain in her neck and right upper limb after she regained consciousness. Three-dimensional reconstruction of CT showed the dislocation of the C6/7 segment and presence of zygapophysial joint

noose on the left (**Figure 1**). The MRI image of the cervical vertebra indicated the rupture of the fibrous ring of the intervertebral disk. The vertebral pulp was crushed and intruded into the vertebral canal and thus put pressure on the spinal cord. The SLIC, AVAS, and VAS scores were 9, grade D, and 8.5, respectively (**Table 1**). The patient underwent skull traction to restrict her action in order to prevent secondary spinal cord injury after diagnosis (**Figure 2**). The heavy object for traction was removed and the traction bow was kept before her operation. Meanwhile, the C6/7 intervertebral disc was firstly removed after anesthesia administration and muscle relaxation. We tried to use a vertebral screw and deep distractor to open vertebral body for reduction, but the recovery of cervical vertebral sequence was unsuccessful because of severe noose of the zygapophysial joint. Manipulative reduction of C6/7 segments was performed using traction bow, and fluoroscopy under C-arm X-ray fluoroscopic machine showed that the

physiological sequence of C6/7 was restored. No anterior longitudinal ligament tear and instability was found at the segments near the injury site during the perioperative period, and interbody fusion surgery for single segment was performed at C6/7. The surgery lasted 2 hours and 14 minutes, with a hemorrhage volume of 195 ml. The patient wore a cervical collar to protect the cervical vertebra after surgery. The patient was observed for one week in the hospital without any complications and eventually discharged at stable condition. Preoperative symptoms were found to be significantly improved during the last follow-up (1 year). The ASIA and VAS scores were grade E and 2, respectively. No relevant symptoms, such as instability of cervical vertebra, were observed.

### Discussion

Currently, no unified standard for surgical treatment of cervical spine dislocation is available worldwide. The strategies primarily include anterior, posterior, and combined approaches [12, 13]. Previous studies have revealed that posterior approach has some advantages such as high reduction rate and stable biomechanical features after fixation and thus is more earlier and widely used in clinical practice [14]. However, combined intervertebral disc injury occurs in 40% of the patients with cervical spine dislocation [9, 15]. Thus, posterior approach may make nerve injury more severe and consequently lead to aggravation of neurological function. For anterior approach, protruded or injured intervertebral disc can be preferentially managed, which can prevent nerve damage during reduction. However, traditional anterior approach only depends on distraction to perform reduction, and thus is difficult to restore successfully in cases with combined joint noose.

Close reduction is used to recover the sequence of injured cervical vertebra and simplify the course of operation. Close reduction primarily comprises traction and manipulative reduction, and its success rate is approximately 50%-94% [7, 16]. The common causes of failure include difficulty tolerating pain and presence of joint fracture. Moreover, the aggravation of the nerve symptoms after close reduction usually results from excessive traction, omission of injury at non-approaching sites, intervertebral disk hernia, epidural hematoma, and spinal cord edema [17]. Shen *et al.* [2] suggested that instant manipulative reduction under general anesthesia and cervical anterior-posterior combined fusion surgery can avoid difficulty tolerating pain resulting from manipulative reduction under conscious state, and was preferred treatment for lower cervical dislocation. However, it has demonstrated that complications, such as respiratory disturbance and aggravation of neurological functions, still occur in some patients even if reduction under general anesthesia and muscle relaxation are performed [18]. Therefore, a more rational treatment strategy, anterior-posterior-anterior approach, was proposed [6]. The approach was also initially proposed and applied in the Spine Surgery Department of Shanghai Changzheng Hospital. The issues of almost all cases of

severe lower cervical spine dislocation can be resolved by this strategy. Even if it is difficult to achieve a completely anatomical reduction for obvious adhesion of peripheral tissue of old dislocation or fracture of articular process, the line of force and physiological curvature for cervical vertebra can be restored via posterior approach surgery, which can extend the vertebral canal volume and facilitate decompression and correction of instability. Thus, the strategy is constantly used as the general procedure for the treatment of severe cervical spine dislocation in our hospital. However, this method has obvious disadvantages, such as immense technological demand, long operation time, and massive hemorrhage volume. Moreover, posterior approach can cause major damage to posterior cervical muscle group, which can lead to postoperative cervical pain more easily.

Therefore, we introduce innovative perioperative off-table manipulative reduction method for treating lower cervical spine dislocation. This method involves the manipulative reduction of the dislocated vertebral body under the assistance of a muscle relaxation drug. The manipulative reduction is performed after the removal of inferior intervertebral disc of dislocated segment. Meanwhile, only the anterior fusion surgery is performed on the injured segment after the reduction is conducted. For patients with combined protrusion resulting from intervertebral disc injury, the potential secondary injury of spinal cord caused by close-up reduction is prevented by the new surgical method. In addition, unnecessary posterior fusion and fixation operation is avoided, and perioperative body posture for patient is simplified. The risk of secondary spinal cord injury caused by changing the body posture during surgery is prevented, the time of operation is shortened, and the hemorrhage volume is reduced. The number of patients with lingering postoperative neck pain is decreased because posterior surgery is not performed. We retrospectively analyzed cases with lower cervical spine dislocation treated in recent years. A total of 24 patients with lower cervical spine dislocation were treated by surgery between December 2013 and January 2015. Perioperative off-table manipulative reduction was used to achieve reduction in 10 cases where reduction cannot be achieved by preoperative traction, reduction under anesthesia or via simple anterior distraction. Meanwhile, different degrees

of improvement for neurological function and pain were observed at the last follow-up after the surgery. In the selection of single- or multi-segment anterior cervical fusion after reduction, the presentation of combined anterior longitudinal ligament injury is one of the consulted indications apart from the presentation of intervertebral disk hernia in the adjacent dislocated segments, which can result in neurological compression. When the anterior longitudinal ligament among the adjacent segments is already injured and broken, these segments were fused and fixed to correct the instability resulting from ligament breakage [19]. Early reduction of cervical spine dislocation can help facilitate the recovery of motor function [20], our surgical strategy may conduce to achieve reduction in time for these patients who were difficult to achieve reduction and improve their outcomes.

In conclusion, we proposed the following strategy for the treatment of lower cervical spine dislocation. After cervical spine dislocation is clearly diagnosed by imaging examination and neurological function is evaluated, skull traction with a weight of 1-3 kg is then performed to confine the movement of the cervical vertebra in order to prevent secondary spinal cord injury. For patients with incomplete paralysis, the anterior intervertebral disc is removed for decompression, and reduction via distraction is attempted. If the reduction is successful, anterior fusion surgery is performed. If the reduction fails, off-table manipulative reduction is performed. Anterior fusion surgery is then performed for patients achieving successfully reduction, whereas posterior reduction and anterior fusion surgery were performed for those failing to achieving reduction. For patients with complete paralysis, manipulative reduction under general anesthesia can be tried to performed, and only anterior fusion surgery is performed if reduction can be achieved.

### Acknowledgements

This study was supported by the National Natural Scientific Foundation of China (grant No. 81472128).

### Disclosure of conflict of interest

None.

**Address correspondence to:** Xinwei Wang, Department of Spine Surgery, Changzheng Hospital, The

Second Military Medical University, N415 Fengyang Road, Shanghai 200003, China. Tel: +86-21-8188-6999; Fax: +86-21-63520020; E-mail: 2273881-049@qq.com; Jie Zhao, Shanghai Key Laboratory of Orthopaedic Surgery, Shanghai Ninth People's Hospital, Shanghai Jiao Tong University School of Medicine, 639 Zhizhaoju Road, Shanghai 200011, China. Tel: +86-21-63138341; Fax: +86-21-6313-6856; E-mail: 13301815365@189.cn

### References

- [1] Kocis J, Wendsche P, Visna P, Muzik V and Pasa L. [Injuries to the lower cervical spine]. *Acta Chir Orthop Traumatol Cech* 2004; 71: 366-372.
- [2] Shen Y, Shen HL, Feng ML and Zhang WB. Immediate reduction under general anesthesia and single-staged anteroposterior spinal reconstruction for fracture-dislocation of lower cervical spine. *J Spinal Disord Tech* 2015; 28: E1-8.
- [3] Razack N, Green BA and Levi AD. The management of traumatic cervical bilateral facet fracture-dislocations with unicortical anterior plates. *J Spinal Disord* 2000; 13: 374-381.
- [4] Wang XW, Yuan W, Chen DY, Chen XS, Zhou XH, Ye XJ, Chen HJ, Han Z and Kang J. [Surgical strategy for severe cervical spine dislocations]. *Zhonghua Wai Ke Za Zhi* 2007; 45: 379-382.
- [5] Joaquim AF, Lawrence B, Daubs M, Brodke D and Patel AA. Evaluation of the subaxial injury classification system. *J Craniovertebr Junction Spine* 2011; 2: 67-72.
- [6] Payer M and Tessitore E. Delayed surgical management of a traumatic bilateral cervical facet dislocation by an anterior-posterior-anterior approach. *J Clin Neurosci* 2007; 14: 782-786.
- [7] Wang B, Zhu Y, Jiao Y, Wang F, Liu X, Zhu H, Tu G and Liang D. A new anterior-posterior surgical approach for the treatment of cervical facet dislocations. *J Spinal Disord Tech* 2014; 27: E104-109.
- [8] Reindl R, Ouellet J, Harvey EJ, Berry G and Arlet V. Anterior reduction for cervical spine dislocation. *Spine (Phila Pa 1976)* 2006; 31: 648-652.
- [9] Vaccaro AR, Falatyn SP, Flanders AE, Balderston RA, Northrup BE and Cotler JM. Magnetic resonance evaluation of the intervertebral disc, spinal ligaments, and spinal cord before and after closed traction reduction of cervical spine dislocations. *Spine (Phila Pa 1976)* 1999; 24: 1210-1217.
- [10] Song C, Wang K, Yu Z, Zhang L and Yang Y. Anterior decompression and internal fixation for lower cervical spine dislocation. *Int J Clin Exp Med* 2016; 9: 4143-4147.

## Lower cervical spine dislocation

- [11] Dvorak MF, Fisher CG, Fehlings MG, Ramper-saud YR, Oner FC, Aarabi B and Vaccaro AR. The surgical approach to subaxial cervical spine injuries: an evidence-based algorithm based on the SLIC classification system. *Spine (Phila Pa 1976)* 2007; 32: 2620-2629.
- [12] Kwon BK, Vaccaro AR, Grauer JN, Fisher CG and Dvorak MF. Subaxial cervical spine trauma. *J Am Acad Orthop Surg* 2006; 14: 78-89.
- [13] Cao P, Liang Y, Gong YC, Zheng T, Zhang XK and Wu WJ. Therapeutic strategy for traumatic instability of subaxial cervical spine. *Chin Med J (Engl)* 2008; 121: 1364-1368.
- [14] Do Koh Y, Lim TH, Won You J, Eck J and An HS. A biomechanical comparison of modern anterior and posterior plate fixation of the cervical spine. *Spine (Phila Pa 1976)* 2001; 26: 15-21.
- [15] Hart RA. Cervical facet dislocation: when is magnetic resonance imaging indicated? *Spine (Phila Pa 1976)* 2002; 27: 116-117.
- [16] Liu P, Zhao J, Liu F, Liu M and Fan W. A novel operative approach for the treatment of old distractive flexion injuries of subaxial cervical spine. *Spine (Phila Pa 1976)* 2008; 33: 1459-1464.
- [17] Cotler JM, Herbison GJ, Nasuti JF, Ditunno JF Jr, An H and Wolff BE. Closed reduction of traumatic cervical spine dislocation using traction weights up to 140 pounds. *Spine (Phila Pa 1976)* 1993; 18: 386-390.
- [18] Lee AS, MacLean JC and Newton DA. Rapid traction for reduction of cervical spine dislocations. *J Bone Joint Surg Br* 1994; 76: 352-356.
- [19] Stemper BD, Yoganandan N, Pintar FA and Rao RD. Anterior longitudinal ligament injuries in whiplash may lead to cervical instability. *Med Eng Phys* 2006; 28: 515-524.
- [20] Nagata K, Inokuchi K, Chikuda H, Ishii K, Kobayashi A, Kanai H, Nakarai H and Miyoshi K. Early versus delayed reduction of cervical spine dislocation with complete motor paralysis: a multicenter study. *Eur Spine J* 2017; 26: 1272-1276.