

## Case Report

# Blood cyst of mitral valve causing left ventricular outflow tract obstruction: a case report

Xinchun Yuan, Lu Chen, Shuping Guo, Pan Xu, Aiyun Zhou, Li Chen

Department of Medical Ultrasound, The First Affiliated Hospital of Nanchang University, Nanchang, China

Received July 5, 2017; Accepted October 11, 2017; Epub November 15, 2017; Published November 30, 2017

**Abstract:** Blood cysts of the heart are rare benign tumors, usually involving the cardiac valves. They are found mainly in the first month of life and in children, but rarely seen in adults. Here, We reported a rare case of mitral valve blood cyst causing left ventricular outflow tract obstruction in a 50-year-old female.

**Keywords:** Blood cyst, mitral valve, outflow tract obstruction, echocardiography

### Introduction

Intracardiac blood cysts are congenital benign cardiac tumors with a rare clinical incidence and can occur in the valve or papillary muscle [1]. They are mainly seen during autopsy in fetuses and infants under the age of 6 months. The cysts regress spontaneously in most patients and are consequently rare in adults. Blood cysts are often asymptomatic but a few cases resulting in embolization and valvular dysfunctions have been reported [2, 3]. Finding a blood cyst on the mitral valve causing left ventricular outflow tract obstruction in an older adult prompted this case report.

### Case report

A 50-year-old female patient was admitted to the hospital due to chest tightness after activity, shortness of breath for 3 years, and worsening of symptoms for 1 month. Physical examination: pulse rate was 69 per minute, respiratory rate was 18 breaths per minute, normal cardiac rhythm, blood pressure was 134/72 mmHg. There was a grade 4/6 holosystolic murmur at the sternal left margin of the third intercostal, and there was a grade 3/6 holosystolic murmur at the apex. Electrocardiogram showed sinus bradycardia with arrhythmia.

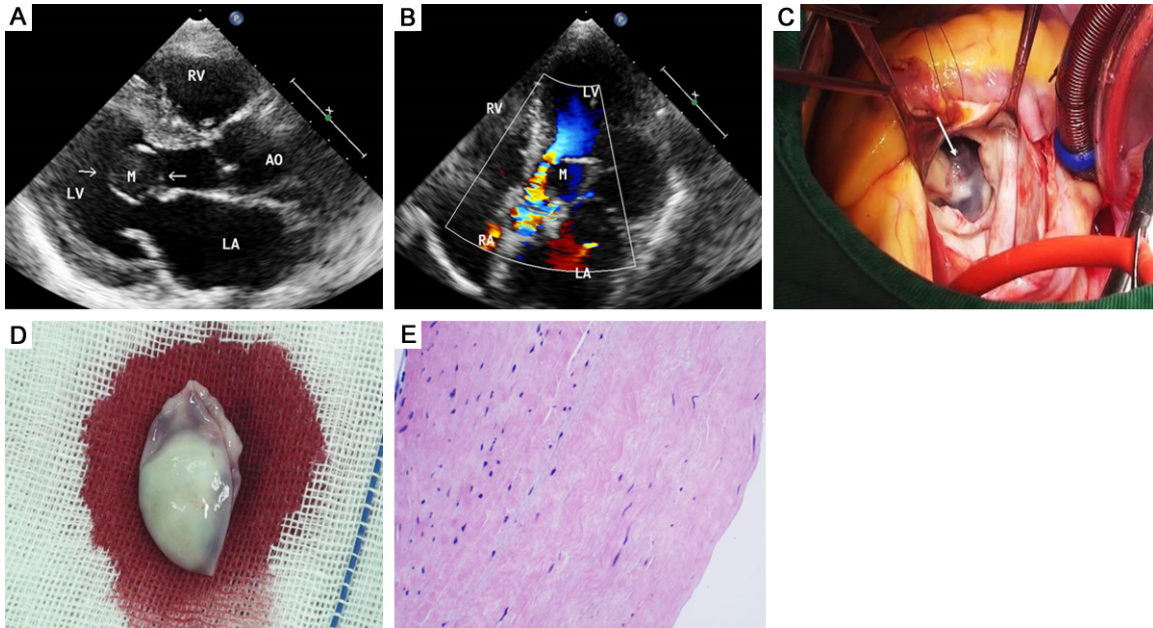
Transthoracic echocardiogram showed a dilated left ventricle and a left atrium with an ejec-

tion fraction of 59%. A rounded cystic mass (approximately 2.4 cm × 2.2 cm) was attached to the ventricular side of the anterior tip of the mitral valve causing left ventricular outflow tract obstruction (**Figure 1A**), which presented during both systole and diastole. Colour Doppler flow imaging showed high-speed turbulence signals in the systolic left ventricular outflow tract and fast blood flow around the wall with increasing blood flow of approximately 5.3 m/s (**Figure 1B**), with a difference in the peak pressure of approximately 113 mmHg, mild mitral regurgitation was seen in the left atrium.

During surgery, a joint incision was made at the right atrium, atrial septum, and the top of the left atrium to explore the mitral valve and subvalvular structure. A spherical bluish cystic mass (approximately 2.4 cm × 2.2 cm) was observed at the anterior mitral valve leaflet, and the base was attached to the edge of the anterior mitral valve and some subvalvular chordae tendineae (**Figure 1C**). The cystic mass was successfully resected. The mitral annulus was measured, a No. 30 St Jude “Saddle-shaped” mitral valve ring was implanted, and mitral valvuloplasty was performed. The cyst cavity was filled with old blood and serosanguineous fluid (**Figure 1D**). The patient recovered well postoperatively.

Pathological findings: fibrous tissue hyperplasia in the mitral valve was observed under the

## Blood cyst of mitral valve



**Figure 1.** The blood cyst of the mitral valve in a 50-year-old female. A. Transthoracic echocardiography in the parasternal long-axis view shows the blood cyst (arrows) attached to the ventricular side of the anterior mitral leaflet. B. Transthoracic echocardiography in the apical 5-chamber view with color Doppler shows fast blood flow around the wall. C. Intraoperative findings shows a bluish cyst mass (arrows) was seen attached to the edge of the anterior mitral valve and some subvalvular chordae tendineae. D. Cystic mass was excised and revealed old blood in the cyst. E. Cystic wall composed of dense fibrous connective tissue with flat lining cells ( $\times 20$ ). LA, left atrium; LV, left ventricle; RA, right atrium; RV, right ventricle; Ao, aortic; M, mass.

microscope, and the cyst wall was composed of a dense layer of fibrous connective tissue with flat lining cells (**Figure 1E**). Pathology diagnosis: hyaline fibrosis was found within the mitral valve and was accompanied by cyst formation.

### Discussion

Intracardiac blood cysts are congenital benign cardiac tumours with a rare clinical incidence and can occur in the valve or papillary muscle. They are mainly seen during autopsy in fetuses and infants under the age of 6 months. The cysts regress spontaneously in most patients and are consequently rare in adults. Elsasser first described intracardiac blood cysts in 1844 and considered them a rare congenital abnormality [4].

The histological manifestations of blood cysts are cystic masses filled with blood, a cyst wall of fibrous connective tissues, which may be due to mucous degeneration or calcification, and endothelial cells in the interior of the wall [5, 6]. Blood cysts can occur in any part of the heart but mostly occur in the cardiac valve with some possible occurrence in the left ventricular

endocardium and papillary muscle. These cysts can occur not only in the normal heart but also in the heart of patients with organ disease (atrial septal defect and ventricular septal defect).

There are several hypothesis about the pathogenesis of blood cysts. First, abnormal development of cardiac mesothelial progenitor cells may be involved in the formation of cardiac fibrous scaffolds. Second, inflammation, hypoxia, irritation, and other factors may lead to sudden occlusion of blood vessels, resulting in haematoma formation. Third, orifices may be closed in response to blood infiltration at scratches over the surface of the valve during the process of valve formation. Fourth, cysts may be due to vasodilation or benign haemangioma. However, there is still no consensus regarding the development of blood cysts [7, 8].

There is no consensus regarding the management of blood cysts. Pelikan *et al.* suggested that asymptomatic cysts, because of their benign character, can be monitored with echocardiography, and resection should be reserved for cysts that interfere with normal cardiac function [9]. Paşaoğlu *et al.* advised surgical

## Blood cyst of mitral valve

excision of all cystic tumors of the heart, especially in a valvular location, because the precise diagnosis can be made only by intraoperative examination [10]. However, due to the special location of this cyst, left ventricular outflow tract obstruction may occur, affecting the left ventricular ejection function; in those cases, the patient must immediately receive surgical treatment. Postoperative echocardiography will indicate that the left ventricular outflow tract obstruction has been lifted, and the heart haemodynamics have been recovered.

### Disclosure of conflict of interest

None.

**Address correspondence to:** Dr. Xinchun Yuan, Department of Medical Ultrasound, The First Affiliated Hospital of Nanchang University, Nanchang 330-006, China. Tel: 0086 1370 7911 078; E-mail: yespring97@163.com

### References

- [1] Kurtoğlu N, Yildirim T, Uzunlar B, Cevik C, Incedere O and Dindar I. A rare case: blood cyst of the mitral valve. *Anadolu Kardiyol Derg* 2005; 5: 346.
- [2] Bonenfant F, Essadiqi B, Gahide G, Jeanmart H and Farand P. Mitral valve blood cyst detected by multimodality imaging. *Can J Cardiol* 2014; 30: 1109, e5-6.
- [3] Lodha A, Patel J, Haran M, Sadiq A and Shani J. Blood cyst of the mitral valve: a rare cause of stroke. *Echocardiography* 2009; 26: 736-738.
- [4] Kuvın J, Saha P, Rastegar H, Salomon RN, Pandian N and Denofrio D. Blood cyst of the mitral valve apparatus in a woman with a history of orthotopic liver transplantation. *J Am Soc Echocardiogr* 2004; 17: 480-482.
- [5] Ansari E, Akhyari P and Lichtenberg A. Blood cyst of the anterior leaflet of the mitral valve in an asymptomatic adult: is surgery an objective? *Heart Surg Forum* 2015; 18: E196-197.
- [6] Park MH, Jung SY, Youn HJ, Jin JY, Lee JH and Jung HO. Blood cyst of subvalvular apparatus of the mitral valve in an adult. *J Cardiovasc Ultrasound* 2012; 20: 146-149.
- [7] Cianciulli TF, Ventrici JF, Marturano MP, Saccheri MC, Medus MJ and Redruello MF. Blood cyst of the mitral valve: echocardiographic and magnetic resonance imaging diagnosis. *Circ Cardiovasc Imaging* 2015; 8: e002729.
- [8] Akinci S and Celikyurt U. Mitral valve blood cyst with regurgitation. *Heart Asia* 2010; 2: 112.
- [9] Pelikan HM, Tsang TS and Seward JB. Giant blood cyst of the mitral valve. *J Am Soc Echocardiogr* 1999; 12: 1005-1007.
- [10] Paşaoğlu I, Doğan R, Demircin M and Bozer AY. Blood cyst of the pulmonary valve causing pulmonary valve stenosis. *Am J Cardiol* 1993; 72: 493-494.