

## Original Article

# Clinical compare between ultrasound-guided double tract percutaneous cholecystostomy combined with a choledochoscope for performing cholecystolithotomies and laparoscopic-choledochoscopy-assisted cholecystolithotomy after cholecystostomy in high-risk surgical patients

Hui Zhang<sup>1\*</sup>, Guangyu Chen<sup>1\*</sup>, Xiao Ma<sup>1\*</sup>, Yugang Liu<sup>2\*</sup>, Tao Wang<sup>1</sup>, Lijun Tang<sup>1</sup>

<sup>1</sup>General Surgery Center, <sup>2</sup>Department of Clinical Chemistry, Center of Laboratory Medicine, Chengdu Military General Hospital, No. 270, Rongdu Road, Jingniu District, Chengdu, China. \*Equal contributors.

Received September 24, 2016; Accepted November 26, 2016; Epub February 15, 2017; Published February 28, 2017

**Abstract:** *Background and Aims:* We compared the clinical outcomes between double tract cholecystostomy combined with choledochoscope for cholecystolithotomy and laparoscopic-choledochoscopy-assisted removal of cholecystolithotomy (LRCL) after cholecystostomy in high risk patient. *Methods:* 19 cases of cholecystolithotomy and 20 cases of LRCL were collected in Chengdu Military General Hospital from January 2011 to november 2012. The therapeutic effect such as surgery time, bleeding volume, hospital stay, hospitalization cost and the quality of life were retrospectively analyzed. The follow-up time was ranged from 6-24 months after discharge, respectively. *Results:* All the cholecystostomy were performed successfully. Gallbladder stones of 19 patients in cholecystolithotomy group were completely and successfully removed without any complications such as bleeding, biliary leakage. In LRCL group, 20 patients successfully underwent laparoscopy combined with choledochoscopy and cholelithotomy. In this group, biliary fistula was detected in two patients, and one of which showed signs of bleeding. The incidence rate of gastrointestinal adverse reaction was higher than that of double-channel cholelithotomy. *Conclusions:* The effect of double-channel cholelithotomy was better and showed fewer complications than LRCL method. Thus, double-channel cholelithotomy can be used as the preferred strategy to treat critical cholecystolithiasis in elderly patients.

**Keywords:** Cholecystolithotomy, minimally invasive therapy, percutaneous cholecystostomy, choledochoscope, laparoscopic-choledochoscopy-assisted cholecystolithotomy

## Introduction

The prevalence of cholecystolithiasis accounted for 10% of the normal population. A high morbidity rate of this disease is observed in the elderly [1]. Surgical treatment for cholecystolithiasis has been introduced more than 100 years ago. Considering the development of minimally invasive techniques and new cognition on the functions of the gallbladder, we should re-examine the traditional treatment scheme of cholecystolithiasis and develop novel therapeutic strategies for this special group of elderly patients with critical cholecystolithiasis. The cholelithotomy operation involves three stages,

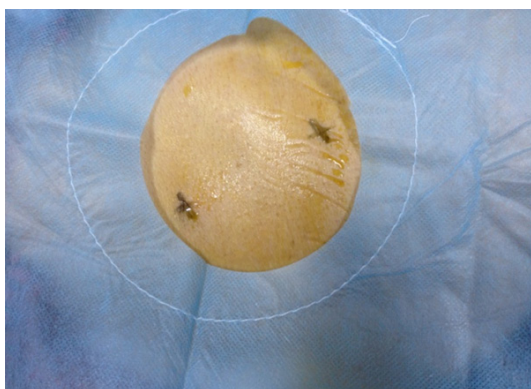
including gallbladder fistula lithotomy invented by American surgeon Bobbos in 1867, through which the right small subcostal incision is combined with choledochoscopy and cholelithotomy under a laparoscope combined with choledochoscope. However, these subjects represent an "active preserving gallbladder" group. The group with the ultrasound-guided double-channel gallbladder puncture fistulization combined with choledochofiberscope preserving gallbladder cholelithotomy mainly aimed to achieve "passively preserving gallbladder" patients who are of advanced age, high risk, cannot tolerate anesthesia during operation, exhibited pneumoperitoneum, or had obvious operation con-

## Clinical compare between DTPC and LRCL

**Table 1.** Comparison of general data in two groups

|                               | Double-channel lithotomy group (n = 19) | LRCL group (n = 20) | P Value |
|-------------------------------|---|---------------------|---------|
| Age (years)                   | 68.74.0                                 | 68.93.4             | 0.894   |
| Gender                        | Male                                    | 6                   | 0.416   |
|                               | Female                                  | 13                  |         |
| Size of the stones            | 11.8±2.7                                | 12.2±2.8            | 0.736   |
| Number of stones              | Single                                  | 4                   | 0.394   |
|                               | Multiple                                | 15                  |         |
| Thickness of gallbladder wall | 6.4±1.7                                 | 7.3±1.7             | 0.141   |
| Gallbladder volume            | 103.1±6.6                               | 102.2±6.9           | 0.696   |
| APACH-II                      | 11.4±1.8                                | 11.3±1.8            | 0.905   |

\*B ultrasound shows the gallbladder maximum diameter (L), anteroposterior diameter (H), transverse diameter (W), and gallbladder volume =  $\pi/6 * L * H * W$ .



**Figure 1.** Ultrasound-guided surface puncture point.

traindication. To assess the safety and effectiveness of the proposed method, the elderly acute gallstone patients, who received cholelithotomy after dual-channel gallbladder puncture fistulation, were admitted in our department and compared with the elderly acute gallstone patients who underwent LRCL after gallbladder fistula at the same period in this study.

### Patients and methods

#### Patients

The 45 patients were treated from January 2011 to november 2012 at the Chengdu Military General Hospital. The patients were selected on the basis of the following conditions: signs and symptoms of typical acute cholecystitis, elderly patients requiring gallbladder fistulation, ultrasound-confirmed cholecystolithiasis, gallbladder volume > 90 ml, wall thick-

ening and edema (wall thickness  $\geq$  5 mm; double-ring sign), and APACH-II  $\geq$  8. Up to 19 patients underwent choledochoscope choledocholithotomy after double-channel gallbladder puncture fistulation (dual-channel preserving gallbladder cholelithotomy group); 26 patients underwent LRCL after gallbladder fistula (LRCL group). In the initially included LRCL group, two cases were converted to laparoscopic cholecystectomy because the adhesive tissue was difficult to be separated. Three cases were converted to laparotomy because cholecystitis was severe, the gallbladder wall was decayed, and

operation cannot be conducted. The oxygen saturation continued to fall under general anesthesia. One patient exhibited pneumoperitoneum, which cannot be relieved after oxygen inhalation through oxygen mask. The operation was terminated emergently, and the patient was transferred to the ICU. The above unsuccessful LRCL cases were excluded. Therefore, 20 patients were eventually included in the LRCL group. In addition, 19 patients were included in the double-channel preserving gallbladder cholelithotomy group. The general data showed no significant difference between the two groups ( $P > 0.05$ ), but the results were comparable (**Table 1**). This research was carried out in accordance with the Helsinki Declaration.

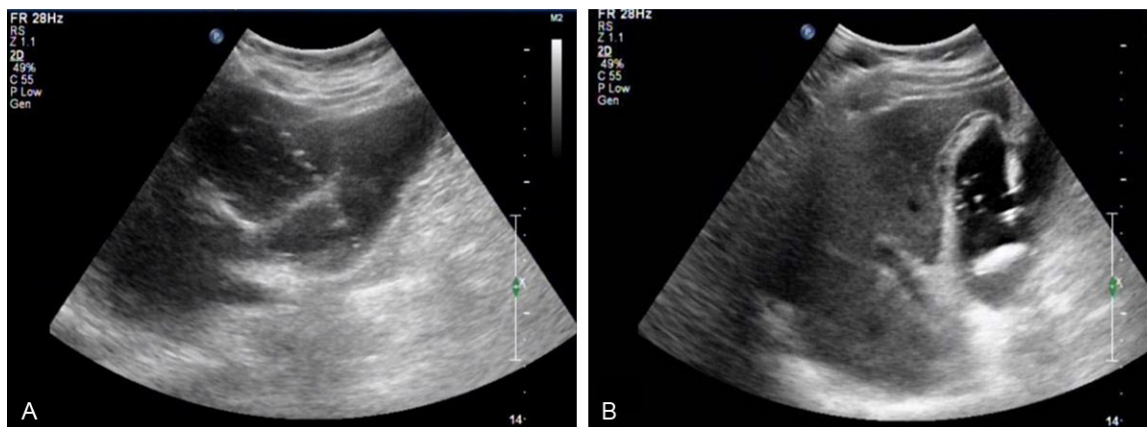
#### Materials and equipment

A Philips iu22 ultrasound diagnosis system (Philips, Amsterdam, the Netherlands) was used to perform the operation, and a Pentax EPM-3500/ECN-1530 (Pentax, Tokyo, Japan) choledochoscope system was used to remove the gallbladder stones. The electrohydraulic lithotripsy was made by pudong company (Guangzhou, China). The percutaneous cholecystostomy catheter was a Pigtail Drainage Catheter Set (7-Fr and 16-Fr; Bioteque, Taipei, China) and Amplatz Dilator Set (12 to 22-Fr; Cook, Bloomington, IN, USA).

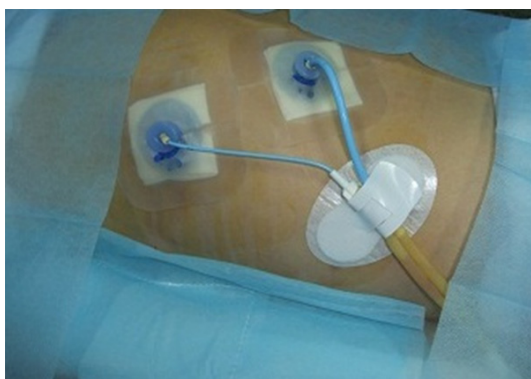#### Methods

*Steps of gallbladder fistula operation:* The patient was placed in supine or left lateral position. The right anterior axillary line to the right

## Clinical compare between DTPC and LRCL



**Figure 2.** Dual channels were established under ultrasound guidance. A. A drainage channel was established through percutaneous transhepatic gallbladder puncture; B. A channel for stone removal was established through percutaneous puncture rather than through right subcostal liver puncture.



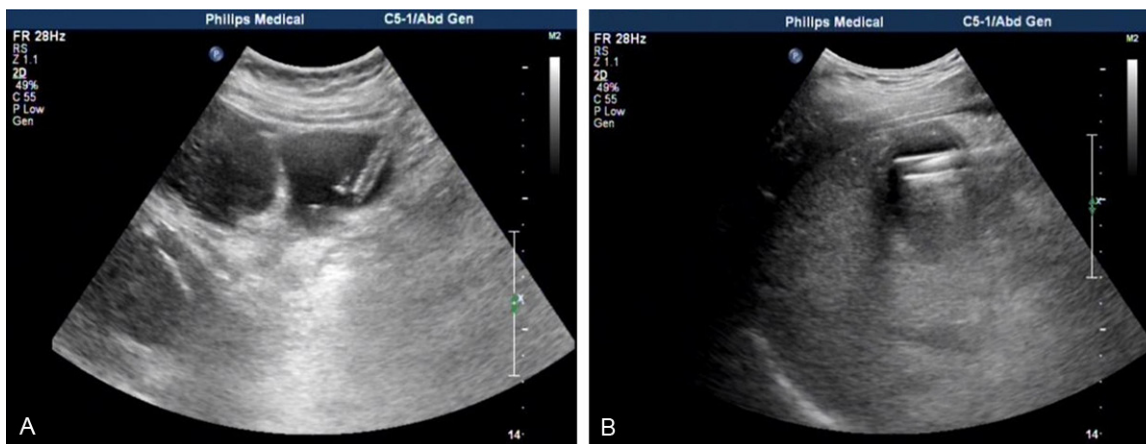
**Figure 3.** Drainage tube fixation after establishment of double channels.

midclavicular line seventh or eighth intercostal space under the guidance of ultrasound was selected as the puncture point (**Figure 1**). One-third area from the gallbladder neck was selected as the target (gallbladder bed). The path length of liver tissue measured 2.5 cm to 3.5 cm. F7 pigtail catheter with a stylet was directly punctured. The stylet was drawn out when it entered the gallbladder cavity. After the bile was smoothly drawn out, the outer catheter was placed to serve as the drainage channel (**Figure 2A**).

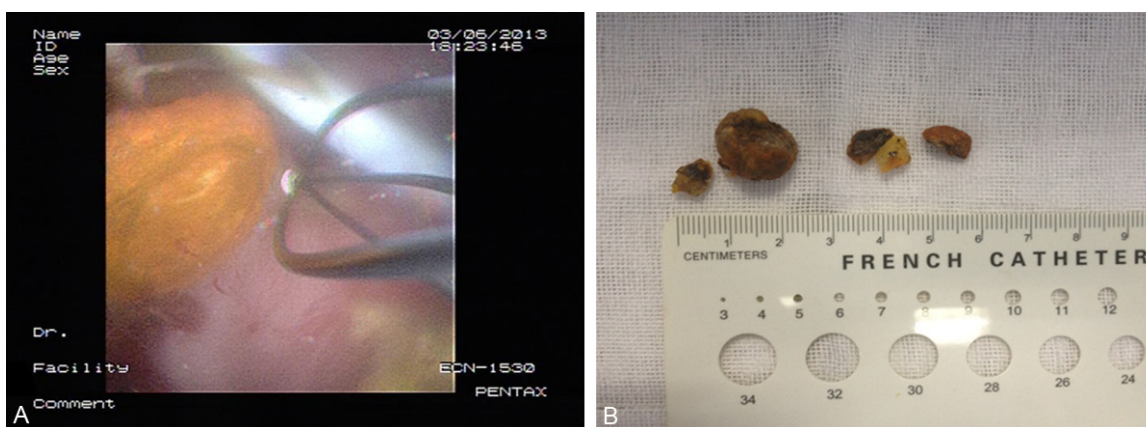
*Double-channel preserving gallbladder cholelithotomy group:* First, the channel for stone removal and the gallbladder fistula were established simultaneously. Bile in the gallbladder cavity was extracted using a syringe via F7 pigtail outer catheter; the amount of bile was recorded. Equivalent saline was then injected

to fill the gallbladder. The drainage catheter was closed prior to stone removal. The puncture point for stone removal channel was the right costal margin, and the gallbladder bottom surface projection area was selected as the target. The F16 pigtail puncture needle was pointed at the direction of the bottom of the gallbladder; the needle was punctured as far as possible into the gallbladder. After it entered the gallbladder cavity, the outer catheter was pushed 4 cm to 6 cm into the neck of the gallbladder. The stylet was pulled out [3] to establish the channel for stone removal (**Figure 2B**); the two drainage tubes were then fixed (**Figure 3**). The sinus was expanded. After 4 weeks, a sinus did not form in the two patients following extubation. The catheter was then replaced. The sinus expansion was smooth during the eighth week. Preoperative fasting lasted for 10 h, and the drainage catheter was kept closed for 24 h to fill the gallbladder. Before the sinus was expanded, B ultrasound was used to measure the gallbladder maximum long diameter (L), anteroposterior diameter (H), width (W), and gallbladder volume, which was calculated as:  $V = (\pi/6) \times L \times H \times W$ . Bile in the gallbladder cavity was pumped out. The amount of bile was recorded. The equivalent physiological saline was repeatedly used to replace the bile in the gallbladder cavity and ultimately maintain the original volume of the gallbladder. Under ultrasound guidance, the guide wire was inserted into the F16 drainage tube. After the guide wire entered the gallbladder cavity, the tube was retracted. In the process of sinus expansion,

## Clinical compare between DTPC and LRCL



**Figure 4.** Expanded sinus for stone removal under ultrasound guidance. A. Expanded sinus with F14 COOK expansion tube; B. Expanded outer sheath with F20 COOK expansion tube.



**Figure 5.** Cholechofiberscope used in stone removal. A. Stone removal by using cholechofiberscope; B. Stones successfully removed by cholechofiberscopy.

the isometric saline was continuously injected through the F7 drainage tube to establish a manmade filling gallbladder without bile. The sinus was expanded along the guide wire with the COOK expansion tube kit from F14 to F22 (**Figure 4A**). Finally, the F20 outer sheath was implanted (**Figure 4B**). At that point, cholechofiberscope-guided choledocholithotomy was conducted as follows: cholechofiberscope was placed from the bottom of the gallbladder F20 outer sheath into the gallbladder cavity, and the stones were removed under direct vision (**Figure 5A**). If the gallbladder stones were larger than 2 cm, they would be removed through electrohydraulic lithotripsy by using a lithotripter. Sand-like stones were drawn out using an aspirator (**Figure 5B**). After extubation, cholechofiberscopy revealed no residual stones in the gallbladder cavity; B ultrasound review

showed no stones; and angiography showed no stones in the gallbladder cavity and neck. Moreover, a contrast agent was injected through the drainage tube, and it smoothly entered into the common bile duct and duodenum.

*LRCL group:* After gallbladder fistulation, a subsequent operation was implemented when the condition of the patient was stable, that is, the patient can withstand the risk of anesthesia. The pneumoperitoneum was established by puncturing the umbilical hole under general anesthesia. Bedside ultrasound determined the surface projection of the bottom of the gallbladder (proximal point from the gallbladder bottom below the right subcostal margin). Gallbladder lesions were explored by laparoscopy to determine whether choledocholithotomy needed to be implemented first. Subse-

## Clinical compare between DTPC and LRCL

**Table 2.** Comparison of intraoperative and postoperative conditions in two groups ( $\bar{x} \pm s$ )

|                                    | Double-channel cholelithotomy group (n = 19) | LRCL group (n = 20) | P Value |
|------------------------------------|--|---------------------|---------|
| Operation time* (min)              | 23.2±3.3                                     | 40.9±4.2            | 0.000   |
| Intraoperative bleeding (ml)       | 8.6±1.6                                      | 14.6±1.9            | 0.000   |
| Hospitalization time** (d)         | 2.8±0.7                                      | 5.3±1.0             | 0.000   |
| Hospitalization A cost (US dollar) | 1121.3±82.9                                  | 1979.8±123.4        | 0.000   |
| Time of first feeding (h)          | 2.2±0.8                                      | 32.1±9.9            | 0.000   |
| Incidence of bile leakage no. (%)  | 0  | 1 (5)               | 0.5     |
| Gastrointestinal event-no. (%)***  |  |                     |         |
| Nausea                             | 4 (21)                                       | 11 (55)             | 0.020   |
| Vomiting                           | 0  | 7 (35)              | 0.004   |
| Aspiration                         | 0  | 2 (10)              | 0.243   |
| Ileus                              | 0  | 0                   | -       |
| Diarrhea                           | 0  | 0                   | -       |

\*Operation time referred to the time from successful anesthesia to the completion of suture.

\*\*Hospitalization time referred to the time when the patient underwent LC or preserving gallbladder cholelithotomy; the hospitalization time of gallbladder fistulation was not included.

\*\*\*Gastrointestinal events were assessed during each day of hospital stay.

**Table 3.** Postoperative follow-up conditions (case) in the two groups

| Follow-up time                              | Double-channel cholelithotomy group (n = 19) |      |      | LRCL group (n = 20) |      |      |
|---|--|------|------|---------------------|------|------|
|   | 6 m  | 12 m | 24 m | 6 m                 | 12 m | 24 m |
| The gallbladder function was normal*        | 10   | 14   | 17   | 5                   | 8    | 11   |
| The gallbladder wall thickness was normal** | 12   | 15   | 16   | 14                  | 14   | 16   |
| Reccurrence of stones                       | 0  | 2    | 4    | 0                   | 2    | 5    |

\*Normal gallbladder contraction percentage  $\geq 30\%$ . \*\*Normal gallbladder wall thickness  $\leq 3$  mm.

quently, the gallbladder bottom was punctured with a pneumoperitoneum needle without stylet, and the bile was extracted. Incision at the bottom of the gallbladder was extended and sutured using three needles. The gallbladder was then pulled on the basis of the gallbladder stone size obtained upon preoperative ultrasonic measurement. The fibrous choledochoscope was repeatedly inserted into the gallbladder cavity to remove the stones. After the stones were removed completely, 4-0 absorbable thread was used to suture the gallbladder incision. The abdominal cavity was sutured layer by layer.

For 6 months, the patients in the two groups were orally administered with daily dose of 0.5 g TUDCA.

### Statistical analysis

SPSS 16.0 for Windows (Statistical Product and Service Solutions, Chicago, USA) performed the statistical analysis. Numerical data was represented by the Mean  $\pm$  SD of the groups. Variables were compared with One-Way ANOVA, and chi square test. Two-tailed P < 0.05 was considered statistically significant.

### Results

Catheterization was successfully completed in the two groups. Pain was relieved within 2 h after the procedure. Body temperature returned to normal within 48 h, and the pain symptoms disappeared. The condition of the patients was basically stable within 8 weeks, but further treatment was still conducted. Nine-

teen patients in the double-channel gallbladder-preserving cholelithotomy group successfully underwent choledochoscope-guided choledocholithotomy. The stone clearance rate was 100%. Bleeding, bile leakage, secondary common bile duct stones, infection of incision, and other complications did not occur during the actual stone removal. The patients in the other group successfully underwent LRCL. However, encapsulated effusion in the gallbladder bed area occurred in one patient. In addition, right subphrenic encapsulated effusion and right lower abdominal effusion occurred in another patient. These two patients underwent diagnostic puncture, and the bile-like liquid was extracted. Biliary leakage was diagnosed. The patients underwent ultrasound-guided puncture catheter drainage of abdominal cavity effu-

sion and nasal biliary drainage conservative treatment. After the diagnosis, puncture of lower abdominal effusion occurred on another patient, who showed no signs of blood clotting. This patient underwent percutaneous catheterization drainage and conservative treatment. The intraoperative and postoperative conditions of the patients in the two groups are summarized in **Table 2**. All the patients were followed up after 6, 12, and 24 months. Ultrasound observations showed the gallbladder wall thickness (normal  $\leq 3$  mm) and gallbladder function level (normal gallbladder contraction rate  $\leq 30\%$ ). The stone recurrence rate is presented in **Table 3**.

### Discussion

Given the aging of the current population, the number of elderly patients with cholecystolithiasis increases annually. Bodily functions in elderly patients with cholecystolithiasis have declined and are often accompanied by internal diseases. Conventional surgical treatment for cholecystolithiasis has demonstrated high operation risk, slow postoperative recovery, evident gastrointestinal complications, much long-term sequelae, and other shortcomings [2-4]. Thus, the search for novel therapeutic strategies for elderly patients with critical condition has become the new trend in the treatment of cholecystolithiasis.

Surgical treatment of cholecystolithiasis, known as gallbladder fistula lithotomy, was accidentally discovered by American surgeon Bobbos in 1867. However, this method was replaced by laparotomy cholecystectomy, which was created by Langenbuch in 1882, because of high relapse rate [5-7]. The subsequent laparoscopic cholecystectomy became the gold standard to treat cholecystolithiasis because of the "minimally invasive" idea [8, 9]. The introduction of lens systems, optical fiber, and soft endoscope has successfully contributed to biliary tract imaging, removal of stones, catheterization, and other complex but minimally invasive operations. Further understanding about the gallbladder functions (i.e., gallbladder as an organ in the digestive and immune systems; various complications appear after resection, a condition after cholecystectomy; incidence of colon cancer was increased; and incidence of common bile duct increased) [10-14] and

recent studies on drugs controlling stone recurrence have drawn research attention to gallbladder-preserving cholelithotomy [15-17]. The mainstream operation technique of gallbladder-preserving cholelithotomy is laparoscopy combined with choledochoscope-guided cholelithotomy. However, elderly patients often exhibit other medical conditions, such as cardiovascular diseases, diabetes, respiratory system diseases, and chronic renal insufficiency. These patients often cannot bear general anesthesia, which is required for laparoscopy, and the risks of operation and difficulty in postoperative recovery increase [18], thereby forcing patients and the medical team to seek a less invasive solution.

Dual-channel method [19] involved an F7 drainage tube, which was implanted from the intercostal puncture point under ultrasound guidance. An F16 drainage tube was then implanted at the bottom of the gallbladder. These two drainage tubes formed a contra-aperture drainage. Saline or metronidazole solution was injected through the F7 drainage tube. Sand-like stones, necrotic tissues, and purulent bile, among others, were discharged smoothly in the gallbladder via the F16 drainage tube to avoid inadequate drainage for bile containing bacteria and prevent toxins from entering the blood circulation, resulting in infectious shock, multiple organ failure, or even death [20, 21]. The F16 drainage tube was a late removing stone channel because the tube diameter was thick, and the puncture was percutaneous but not transhepatic. The drainage tube was not fixed by the liver tissue and easily slid out of the gallbladder cavity. As a drainage path, the F7 drainage tube can be used to avoid bile peritoneal leakage caused by F16 drainage tube slippage. The gallbladder fistula was formed within 4 weeks to 8 weeks after the operation. After the inflammation and edema of the gallbladder were relieved, choledochoscopy was performed. The diameter of stone channel must be greater than that of F16 to allow the choledochoscope to smoothly pass through. In sinus expansion, saline would overflow from the Cook expansion tube after gallbladder replacement. Thus, the gallbladder was not filled. The toughness of the unfilled gallbladder wall increased. The expansion tube cannot easily enter the gallbladder cavity. Isometric saline was continuously injected into the F7 drainage tube to

## Clinical compare between DTPC and LRCL

expand the gallbladder. Some factors affected the sinus formation, including poor nutrition, local infection, and poor greater omentum in some elderly patients. If the sinus was not formed as a result of the failure of pipe expansion, bile is still drained via the F7 tube to avoid bile leakage. Choledochofiberscope-guided cholelithotomy was the main procedure used to remove the stones [22]. Stones with diameter of > 2 cm in the removing stone reticular cover cannot pass through the outer sheath with the diameter of F20. Electrohydraulic lithotripsy is commonly used to break the stones, and the stones are gradually removed afterward. When the stones blocked the neck, no gap existed between the stones and gallbladder wall; hence, stone basket removal was difficult. The stones in the gallbladder should be removed first. The stones in the neck were broken into pieces by a knapper and removed after the gallbladder cavity was washed. The gallbladder mucosa should be carefully protected during electrohydraulic lithotripsy. In some patients, stones were small in size, and the extended period of time to remove the stones is beyond the tolerance of the elderly patients. The gallbladder fistula can be replaced along the sinus, and multiple choledochoscope-guided cholelithotomy can be performed.

Our clinical study indicated that the dual-channel method demonstrated more obvious advantages than those of the LRCL method. First, the operation scheme only required regional anesthesia on the puncture area to avoid the risk caused by general anesthesia [23]. Laparoscopic operation requires much amount of anesthesia (to ensure muscular relaxation, safety, painlessness, and good operation view), and preoperative and intraoperative patients should be treated with sedatives, antispasmodics, and muscle relaxants, among others. CO<sub>2</sub> pneumoperitoneum was also established. Drugs increased the intra-abdominal pressure after pneumoperitoneum and other mechanical factors, such as CO<sub>2</sub> diffusion into the blood circulation through the peritoneum, ruptured blood vessels, and abdominal organs, which produced significant physiological interference in the patients' circulation and respiration [24, 25]. In elderly patients with cardiopulmonary dysfunction, varying degrees of hypercapnia always occur even after artificial ventilation was administered. Thus, end-tidal carbon diox-

ide partial pressure and sharp increase of blood pressure occurred in these patients. One patient in the LRCL group, who has been prepared for analysis of pneumoperitoneum, was excluded in this study. Oxygen saturation declined continuously and did not improve after oxygen inhalation by mask. Operation was stopped, and the patient was transferred to the ICU for first aid. The intended treatment on the stones was not performed because the patient's life was threatened. Administration of regional anesthesia in dual-channel gallbladder-preserving cholelithotomy enabled many elderly patients who cannot tolerate general anesthesia to receive treatment for stone problems. This technique also significantly reduced the treatment risks. Second, the operation time, intraoperative bleeding, hospitalization time, cost, postoperative feeding time, and postoperative gastrointestinal complications in the gallbladder cholelithotomy-preserving group were significantly superior to those of the LRCL group. This finding suggests the advantages of dual-channel gallbladder-preserving cholelithotomy in reducing trauma, promoting recovery, and reducing patients' hospitalization cost. The dual-channel method was also superior to LRCL with respect to most common complications of biliary tract operation, including bile leakage and hemorrhage. In this study, two patients in the LRCL group experienced right inferior phrenic encapsulated effusion and right lower abdominal effusion after the gallbladder bed area effusion. Diagnostic puncture showed that the extracted bile sample presented biliary leakage. Our results showed that the gallbladder wall became pachyotic or atrophic during the aging process. Chronic inflammation appeared in the gall bladder wall resulting from repeated stimulation by the stones. The wall became brittle and ischemic, resulting in local necrosis of the gallbladder wall. Cystic artery was the terminal branch of the liver artery. The massive embolism in the arteriole occurred in the gallbladder wall during inflammation. Arteriosclerosis in elderly patients aggravated the blood circulation disorder in the gallbladder wall. The gallbladder bottom incision was expanded and then sutured thrice. The gallbladder was removed via LRCL treatment method. Choledochofiberscope was repeatedly inserted into the gallbladder cavity, and the stones were removed. Finally, the gallbladder incision was sutured with 4-0 absorbable

thread. This process may pull the gallbladder wall. The pinpoint gap and the suture led to postoperative bile leakage. In this study, lower abdominal effusion occurred in one patient in the LRCL group within 3 days after the operation. Diagnostic puncture showed that the bleeding was not coagulated. The possible causes of this hemorrhage included the following: 1) the gallbladder wall was crisp, ischemic, necrotic, and leaking through seton and suture; 2) coagulation dysfunction resulted from long-term exposure of the elderly patients to aspirin and other anticoagulant agents; and 3) laparoscopic puncture damaged the abdominal wall or the abdominal blood vessels. The puncture needle used in double-channel gallbladder-preserving cholelithotomy was thin because the needle punctures must be very thin. The continuous drainage of the F7 drainage tube effectively prevented bile leakage, although bleeding was observed. This method was superior to LRCL group in terms of safety, reliability, and feasibility of operation. Our follow up also showed a significant difference in the contraction of the gallbladder, which was found better in the double-channel group than in the LRCL group. This result may be attributed to less damage to the gallbladder wall in the dual-channel method than in the LRCL method [26]. With reference to the recurrence rate of cholecystolithiasis, no difference existed between the two groups. This finding may be ascribed to the short duration of follow up with the patients. Consequently, the long-term effects of these procedures require further studies.

This research revealed that ultrasound-guided double-channel gallbladder puncture fistulization combined with gallbladder-preserving choledochoscope-guided cholelithotomy demonstrates significant advantages, such as suitability to patients regardless of age, pain level, and number of complications, compared with the traditional LRCL. The proposed method is suitable for the modern biological-psychological-social medical model requirement. This minimally invasive operation is also highly significant because it is safe and effective for treating elderly patients with acute calculous cholecystitis. Simultaneously, this method requires several requirements for ultrasound guidance and endoscopy, which limited the promotion of the technology to a certain extent. With the improvement and popularization of ultrasound

and endoscope technology, this method will become the preferred strategy in the treatment of cholecystolithiasis in elderly patients.

### Acknowledgements

This study was supported by a grant from the National Natural Science Foundation of China (No. 81001695).

### Disclosure of conflict of interest

None.

**Address correspondence to:** Dr. Lijun Tang, General Surgery Center, Chengdu Military General Hospital, No. 270, Rongdu Road, Jingniu District, Chengdu, China. Tel: +86-28-86570350; Fax: +86-28-8657-0350; E-mail: acecgy@gmail.com

### References

- [1] Elías Pollina J, Delgado Alvira R, Martínez-Pardo NG, Ros Mar L, Calleja Aguayo E, Esteban Ibarz JA. Must we change the surgical treatment of gallstones? *Cir Pediatr* 2008; 21: 96-99.
- [2] Welschbillig-Meunier K, Pessaux P, Lebigot J, Lermite E, Aube Ch, Brehant O, Hamy A, Arnaud JP. Percutaneous cholecystostomy for high risk patients with acute cholecystitis. *Surg Endosc* 2005; 19: 1256-1259.
- [3] Chen MF, Wang CS. A prospective study of the effect of cholecystectomy on duodenogastric reflux in humans using 24 hour gastric hydrogen monitoring. *Surg Gynecol Obstet* 1992; 175: 52-56.
- [4] O'Donnell LJ. Post-cholecystectomy diarrhoea: a running commentary. *Gut* 1999; 45: 796-797.
- [5] Sparkman RS. 100th anniversary of the first cholecystectomy. *Arch Surg* 1982; 117: 1525.
- [6] Casal MA. 100 years ago: 1882-1982. Carl Langenbuch, the 1st cholecystectomy and a brief history of a famous polemic. *Acta Gastroenterol Latinoam* 1982; 12: 181-184.
- [7] Chauvin KL, O'Leary JP. Carl Langenbuch and the first cholecystectomy. *Am Surg* 1995; 61: 746-7.
- [8] Bueno Lledó J, Planells Roig M, Arnau Bertomeu C, Sanahuja Santafé A, Oviedo Bravo M, García Espinosa R, Martí Obiol R and Espí Salinas A. Outpatient laparoscopic cholecystectomy: a new gold standard for cholecystectomy. *Rev Esp Enferm Dig* 2006; 98: 14-24.
- [9] Mosimann F. Laparoscopic cholecystectomy has become the new gold standard for the management of symptomatic gallbladder



## Clinical compare between DTPC and LRCL

- stones. *Hepatogastroenterology* 2006; 53: 1p preceding I; author reply 1 p preceding I.
- [10] Porr PJ, Szántay J, Rusu M. Post-cholecystectomy syndrome and magnesium deficiency. *J Am Coll Nutr* 2004; 23: 745S-747S.
- [11] Manifold DK, Anggiansah A, Owen WJ. Effect of cholecystectomy on gastroesophageal and duodenogastric reflux. *Am J Gastroenterol* 2000; 95: 2746-50.
- [12] Vernick LJ, Kuller LH, Lohsoonthorn P, Rycheck RR and Redmond CK. Relationship between cholecystectomy and ascending colon cancer. *Cancer* 1980; 45: 392-395.
- [13] Lorusso D, Misciagna G, Mangini V, Messa C, Cavallini A, Caruso ML, Giorgio P, Guerra V. Duodenogastric reflux of bile acids, gastrin and parietal cells, and gastric acid secretion before and 6 months after cholecystectomy. *Am J Surg* 1990; 159: 575-578.
- [14] Madácsy L, Fejes R, Kurucsai G, Joó I, Székely A, Bertalan V, Szepes A and Lonovics J. Characterization of functional biliary pain and dyspeptic symptoms in patients with sphincter of Oddi dysfunction: effect of papillotomy. *World J Gastroenterol* 2006; 12: 6850-6856.
- [15] Tudyka J, Wechsler JG, Kratzer W, Maier C, Mason R, Kuhn K and Adler G. Gallstone recurrence after successful dissolution therapy. *Dig Dis Sci* 1996; 41: 235-241.
- [16] Adamek HE, Buttmann A, Weber J and Riemann JF. Can aspirin prevent gallstone recurrence after successful extracorporeal shock-wave lithotripsy? *Scand J Gastroenterol* 1994; 29: 355-359.
- [17] Villanova N, Bazzoli F, Taroni F, Frabboni R, Mazzella G, Festi D, Barbara L and Roda E. Gallstone recurrence after successful oral bile acid treatment. A 12-year follow-up study and evaluation of long-term postdissolution treatment. *Gastroenterology* 1989; 97: 726-731.
- [18] Smoot RL, Oderich GS, Taner CB, Greenlee SM, Larson DR, Cragun EB and Farley DR. Postoperative hematoma following inguinal herniorrhaphy: patient characteristics leading to increased risk. *Hernia* 2008; 12: 261-265.
- [19] Wang T, Chen T, Zou S, Lin N, Liang HY, Yan HT, Li NL, Liu LY, Luo H, Chen Q, Liu WH and Tang LJ. Ultrasound-guided double-tract percutaneous cholecystostomy combined with a choledochoscope for performing cholecystolithotomies in high-risk surgical patients. *Surg Endosc* 2014; 28: 2236-42.
- [20] Ito K, Fujita N, Noda Y, Kobayashi G, Kimura K, Sugawara T and Horaguchi J. Percutaneous cholecystostomy versus gallbladder aspiration for acute cholecystitis: a prospective randomized controlled trial. *AJR Am J Roentgenol* 2004; 183: 193-196.
- [21] Chu DW. Percutaneous cholecystostomy for the treatment of acute cholecystitis in the critically ill and elderly. *Hong Kong Med J* 2004; 10: 389-93.
- [22] Yoon YS, Han HS, Shin SH, Cho JY, Min SK and Lee HK. Laparoscopic treatment for intrahepatic duct stones in the era of laparoscopy: laparoscopic intrahepatic duct exploration and laparoscopic hepatectomy. *Ann Surg* 2009; 249: 286-291.
- [23] Chopra S, Dodd GD 3rd, Mumbower AL, Chintapalli KN, Schwesinger WH, Sirinek KR, Dorman JP and Rhim H. Treatment of acute cholecystitis in non-critically ill patients at high surgical risk: comparison of clinical outcomes after gallbladder aspiration and after percutaneous cholecystostomy. *AJR Am J Roentgenol* 2004; 176: 1025-1031.
- [24] Wang PH, Lee WL, Yuan CC, Chao HT, Liu WM, Yu KJ, Tsai WY and Wang KC. Major complications of operative and diagnostic laparoscopy for gynecologic disease. *J Am Assoc Gynecol Laparosc* 2001; 8: 68-73.
- [25] Vilos GA, Ternamian A, Dempster J and Lamberge PY; Society of Obstetricians and Gynaecologists of Canada. Laparoscopic entry: a review of techniques, technologies, and complications. *J Obstet Gynaecol Can* 2007; 29: 433-465.
- [26] Van Aken R, Taylor B. Emerging from depression: the experiential process of Healing Touch explored through grounded theory and case study. *Complement Ther Clin Pract* 2010; 16: 132-137.