

## Original Article

# Evaluation of a novel fully bioresorbable poly-L-Lactic acid/amorphous calcium phosphate scaffolds in porcine coronary arteries by quantitative coronary angiography and histopathology

Xin-Gang Wang<sup>1</sup>, Chang Hou<sup>1</sup>, Bo Zheng<sup>1</sup>, Qiu-Ping Shi<sup>1</sup>, Bin Zhang<sup>1</sup>, Qiao Qin<sup>1</sup>, Dan-Dan Chen<sup>2</sup>, Ming Chen<sup>1</sup>

<sup>1</sup>Department of Cardiology, Peking University First Hospital, Beijing, China; <sup>2</sup>National Institutes for Food and Drug Control, Beijing, China

Received October 23, 2016; Accepted December 19, 2016; Epub February 15, 2017; Published February 28, 2017

**Abstract:** Background: Sirolimus-eluting coronary stents (SES) reduced rates of restenosis but also raised clinical adverse events caused by metallic platform. The novel bioresorbable vascular scaffolds (BVS) can degrade its platform completely after 2-3 years in vivo may overcome the limitations of SES. This study was sought to evaluate the efficacy and safety of the BVS. Methods: 48 stents (BVS n = 24, SES n = 24) were randomly implanted in 24 pigs. Quantitative coronary angiography (QCA) and histopathologic analysis were performed at 14 days, 28 days, 90 days and 180 days follow-up. Results: There was no evidence of stent thrombosis in two groups. The lumen loss (LL) and area stenosis of BVS group were slightly higher than SES group ( $P > 0.05$ ), whereas the neointimal area was smaller ( $P > 0.05$ ) at 14 days. Compared to SES group, the LL, neointimal area and area stenosis of BVS group showed a slightly decreased tendency without statistical difference at 28 days and 90 days. At 180 days, the LL of BVS group was numerically smaller than SES group ( $P = NS$ ). Notably, significantly reduced of neointimal area and area stenosis were observed in BVS group ( $1.13 \pm 0.23 \text{ mm}^2$  vs.  $2.29 \pm 0.91 \text{ mm}^2$ ,  $P = 0.013$  and  $31.13 \pm 4.59\%$  vs.  $51.46 \pm 10.61\%$ ,  $P = 0.002$ , respectively). In histopathologic analysis, there were no significant differences in inflammation score, injury score and endothelialization score between two groups. Conclusions: The novel BVS showed similar safety profile compared with SES, whereas may provide potential advantage in the long-term inhibition of neointimal proliferation.

**Keywords:** Bioresorbable vascular scaffolds, drug-eluting stent, porcine coronary model, restenosis, stent thrombosis

## Introduction

Drug-eluting stents (DES) have significantly reduced rates of restenosis and target vessel revascularization after percutaneous coronary interventions (PCI) by decreasing the excessive growth of neointima. However, the permanent presence of the metallic platform and the durable polymer might impair the natural healing process of the coronary vessel wall, leading to the prolonged inflammatory response and untoward clinical outcomes, such as very late stent thrombosis or neoatherosclerotic evolution [1, 2]. Recently, PCI with bioresorbable vascular scaffolds (BVS) have emerged as an interesting alternative since the presence of the

prosthesis in the coronary artery is transient. This technology enables to restore the normal vasomotor tone and allows positive remodeling, simultaneously reducing the trigger for persistent inflammation and facilitating further interventions by percutaneous or surgical means. Also, in theory it should offer reduced or even abolished late/very late stent thrombosis risk [3].

The novel fully BVS (PowerScaffold™) with a layer of sirolimus blended in the biodegradable carrier poly-L-lactic acid (PLLA)/amorphous calcium phosphate (ACP) composite which shows improved biocompatibility and greater radial strength can release more than 70 percent of

## Evaluation of a novel fully bioresorbable vascular scaffolds in porcine model

**Table 1.** Summary of quantitative coronary angiography

	BVS	SES	P value
14 days	n = 6	n = 6	
RVD, mm	2.05 ± 0.25	2.31 ± 0.36	0.16
PMLD, mm	1.94 ± 0.41	2.30 ± 0.38	0.14
FMLD, mm	1.65 ± 0.54	2.25 ± 1.94	0.03*
LL, mm	0.29 ± 0.55	0.05 ± 0.49	0.46
Diameter stenosis, %	16.4 ± 23.5	8.8 ± 8.7	0.48
28 days		n = 6	n = 6
RVD, mm	2.49 ± 0.22	2.14 ± 0.18	0.01\$
PMLD, mm	2.34 ± 0.18	2.31 ± 0.22	0.80
FMLD, mm	2.13 ± 0.18	1.99 ± 0.43	0.51
LL, mm	0.20 ± 0.18	0.32 ± 0.32	0.47
Diameter stenosis, %	8.85 ± 7.52	13.94 ± 14.39	0.46
90 days		n = 6	n = 6
RVD, mm	2.42 ± 0.23	2.45 ± 0.36	0.87
PMLD, mm	2.20 ± 0.27	2.41 ± 0.19	0.15
FMLD, mm	1.37 ± 0.22	1.41 ± 0.47	0.87
LL, mm	0.83 ± 0.33	1.00 ± 0.62	0.55
Diameter stenosis, %	36.92 ± 12.92	40.45 ± 23.63	0.76
180 days		n = 6	n = 6
RVD, mm	2.66 ± 0.26	2.48 ± 0.44	0.39
PMLD, mm	2.14 ± 0.30	2.39 ± 0.29	0.18
FMLD, mm	1.55 ± 0.15	1.60 ± 0.42	0.80
LL, mm	0.59 ± 0.29	0.79 ± 0.50	0.41
Diameter stenosis, %	26.57 ± 10.72	32.44 ± 19.56	0.53

\*the FMLD of BVS group was significantly smaller than SES group, \$the RVD of BVS group was larger than SES group with statistical differences. RVD, reference vessel diameters; PMLD, post-stent minimal lumen diameters; FMLD follow-up minimal lumen diameters; LL, lumen lost; LL = PMLD-FMLD.

eluting drug within 28 days and degrade its polymer as well as platform completely after 2-3 years in vivo, which may solve the long-term adverse reactions of currently used biodegradable-polymer SES. This randomized and controlled animal study was sought to evaluate the efficacy and safety of the novel BVS.

### Methods

#### Experimental studies

All experimental studies were conducted after approval by the Institutional Animal Care and Use Committee in accordance with Peking University Health Science Department and China Heart Association Guidelines for animal research. 24 Chinese mini-pigs of either sex (25 to 35 kg) underwent stent placement in the left anterior descending, circumflex or right coronary arteries randomly, with 24 BVS (Power-

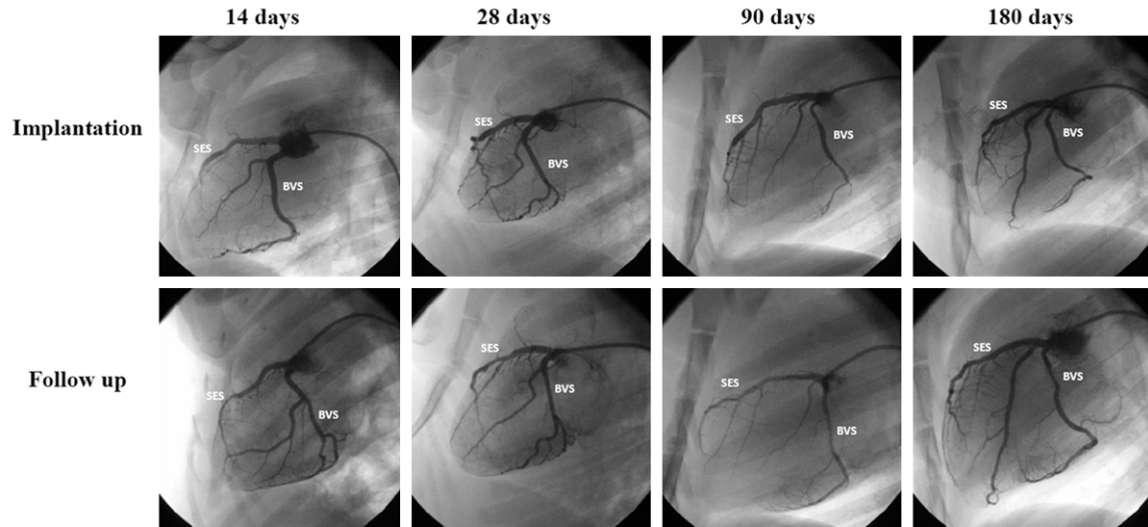
Scaffold™, TT Medical. Inc) and 24 SES (Helios™ stent, Kinheily Bio-tech co., Ltd.) as control. Each animal received one BVS and one SES deployment into 2 different epicardial coronary arteries randomly. Three days prior to the procedure, all animals received 300 mg aspirin/day and 75 mg clopidogrel/day. Afterwards, they were returned to the care facilities to recover, were fed a normal diet, and received 100 mg aspirin/day for the duration of the study and 75 mg clopidogrel/day for 3 months. At 14 days (n = 6), 28 days (n = 6), 90 days (n = 6) and 180 days (n = 6), the animals were euthanized after the follow up coronary angiography and the stented segments were processed for histological analysis.

Under general anesthesia, the pigs underwent placement of a 6 Fr introducer sheath into the porcine femoral arteries according to a modified Seldinger technique [4]. Through the femoral approach, 6 Fr left 4 and right 4 catheters were used for the left main and right ostia. After heparin administration (100 IU/kg) and coronary angiography, each animal underwent placement of the stents in the coronary arteries. The guiding catheter was used as a reference to obtain a 1.1:1 stent/artery ratio compared with the baseline vessel diameter. At 14 days (n = 6), 28 days (n = 6), 90 days (n = 6), 180 days (n = 6), the animals were euthanized to obtain specimens of stented arterial segments for histological analysis.

#### Quantitative coronary angiography

Angiographic images of stent implants were saved on a CD-ROM disk in a standard DICOM format and analyzed using a quantitative coronary angiographic analysis software program (INOVA 2100 GE Company, America). The guiding catheter served as a reference for the calibration for all measurements and the baseline reference vessel diameters, follow-up reference vessel diameters, balloon inflated diameters, post-stent lumen diameters, follow-up lumen diameters and follow-up percent diame-

## Evaluation of a novel fully bioresorbable vascular scaffolds in porcine model



**Figure 1.** Representative photographs of quantitative coronary angiography.

ter stenosis. The balloon to artery ratio was calculated as the balloon inflated diameter/base-line reference vessel diameter. The percent diameter stenosis was calculated as  $[1 - (\text{follow-up lumen diameter} / \text{post-stent reference vessel diameter})] \times 100\%$ .

### *Pathologic evaluation*

Immediately following euthanasia, the hearts were harvested and the coronary arteries were perfusion-fixed with 10% buffered formalin at 100 mmHg. The stented coronary artery segments were processed for plastic embedding, staining and morphometric analysis [5-7]. All specimens were embedded in methyl-methacrylate, sections were obtained with a Beuhler-isomet saw (Beuhler, Evanston, IL), polished, mounted on a glass slide and stained with hematoxylin-eosin.

Morphometric measurements were determined from the digitized pictures using a computer assisted program (Image Pro-Plus software). The lumen, internal elastic lamina (IEL), and external elastic lamina (EEL) were traced and area measurements obtained. The neointimal area was determined by subtracting the area of the lumen from the area within the stent wires. The percent area stenosis was defined as follows:  $[1 - (\text{luminal area} / \text{IEL area}) \times 100]$ .

Morphologic analysis of injury, inflammation and endothelialization were performed according to published methods [5-7]. Stent endothe-

lialization score was defined as the extent of the circumference of the arterial lumen covered by endothelial cells and graded from 1 to 3 (1 = 25%, 2 = 25% to 75%, 3  $\geq$  75%). The injury score was determined according to the method of Schwartz et al [6], and the average score for each segment was calculated by dividing the sum of the injury scores by the total number of struts on the examined section. Inflammation was graded as 0 = no inflammatory cells, 1 = scattered inflammatory cells, 2 = inflammatory cells encompassing 50% of a strut in at least 25%-50% of the circumference of the artery and 3 = inflammatory cells surrounding a strut in at least 25% to 50% of the circumference of the artery [7].

### *Statistical analysis*

Data are expressed as the mean  $\pm$  SEM; n represents the number of stents or animals. The mean angiographic, histological, morphological, and densitometric data for each stent were compared by ANOVA with post-hoc analysis for multiple comparisons. A value of  $P < 0.05$  was considered statistically significant. All statistical analyses were performed with SPSS 11.0 system software.

### **Results**

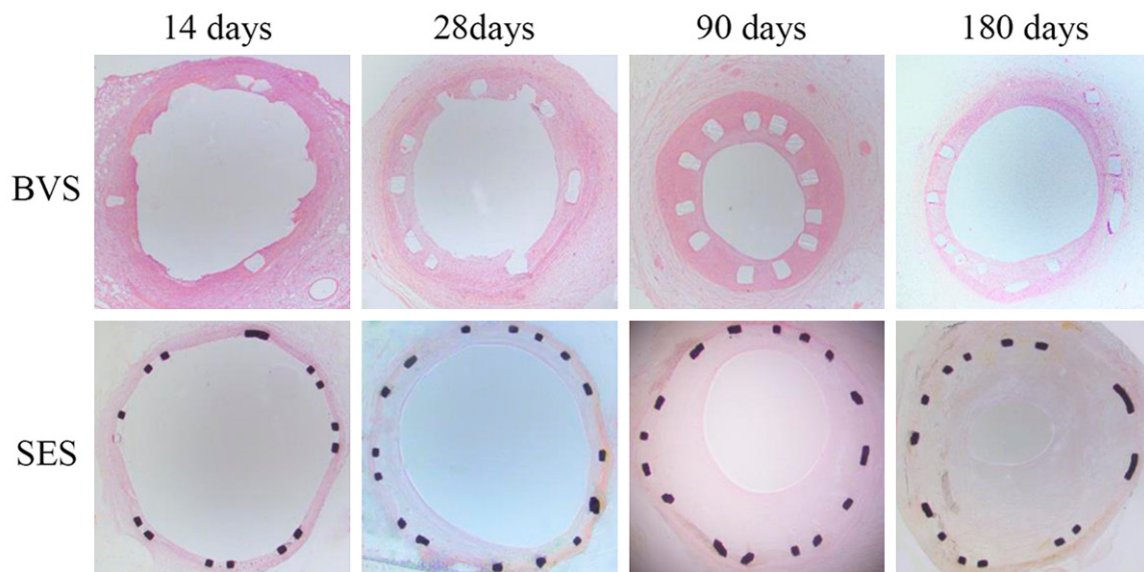
A total of 48 stents were successfully implanted in the coronary arteries of 24 pigs. All animals survived the intended study interval without clinical complications or angiographic stent

## Evaluation of a novel fully bioresorbable vascular scaffolds in porcine model

**Table 2.** Summary of histomorphometric findings

		Stent area (mm <sup>2</sup> )	IEL area (mm <sup>2</sup> )	Neointimal area (mm <sup>2</sup> )	P-value	Area stenosis (%)	P-value
14 days	BVS (n = 6)	2.76 ± 1.05	3.83 ± 1.16	1.07 ± 0.24	0.313	29.45 ± 9.28	0.969
	SES (n = 6)	3.86 ± 1.21	5.48 ± 0.72	1.62 ± 1.25		29.08 ± 20.93	
28 days	BVS (n = 6)	4.66 ± 1.21	7.56 ± 1.73	2.90 ± 1.72	0.779	37.20 ± 17.98	0.280
	SES (n = 6)	3.16 ± 1.24	6.33 ± 1.05	3.18 ± 1.56		49.52 ± 19.40	
90 days	BVS (n = 6)	3.13 ± 1.95	4.74 ± 2.23	1.61 ± 0.35	0.227	38.76 ± 12.52	0.592
	SES (n = 6)	2.73 ± 1.07	4.82 ± 1.01	2.09 ± 0.84		43.50 ± 16.83	
180 days	BVS (n = 6)	2.51 ± 0.51	3.64 ± 0.63	1.13 ± 0.23	0.013#	31.13 ± 4.59	0.002&
	SES (n = 6)	2.32 ± 1.18	4.61 ± 1.85	2.29 ± 0.91		51.46 ± 10.61	

#the neointimal area of BVS group was significantly smaller than SES group, &the area stenosis of BVS group was lower than SES group with statistical differences. IEL, internal elastic lamina.



**Figure 2.** Representative low-power photomicrographs (magnification × 4 and hematoxylin-eosin stain).

thrombosis. Stent migration and fragmentation were not observed either during the procedure or at follow-up.

### Quantitative coronary angiography

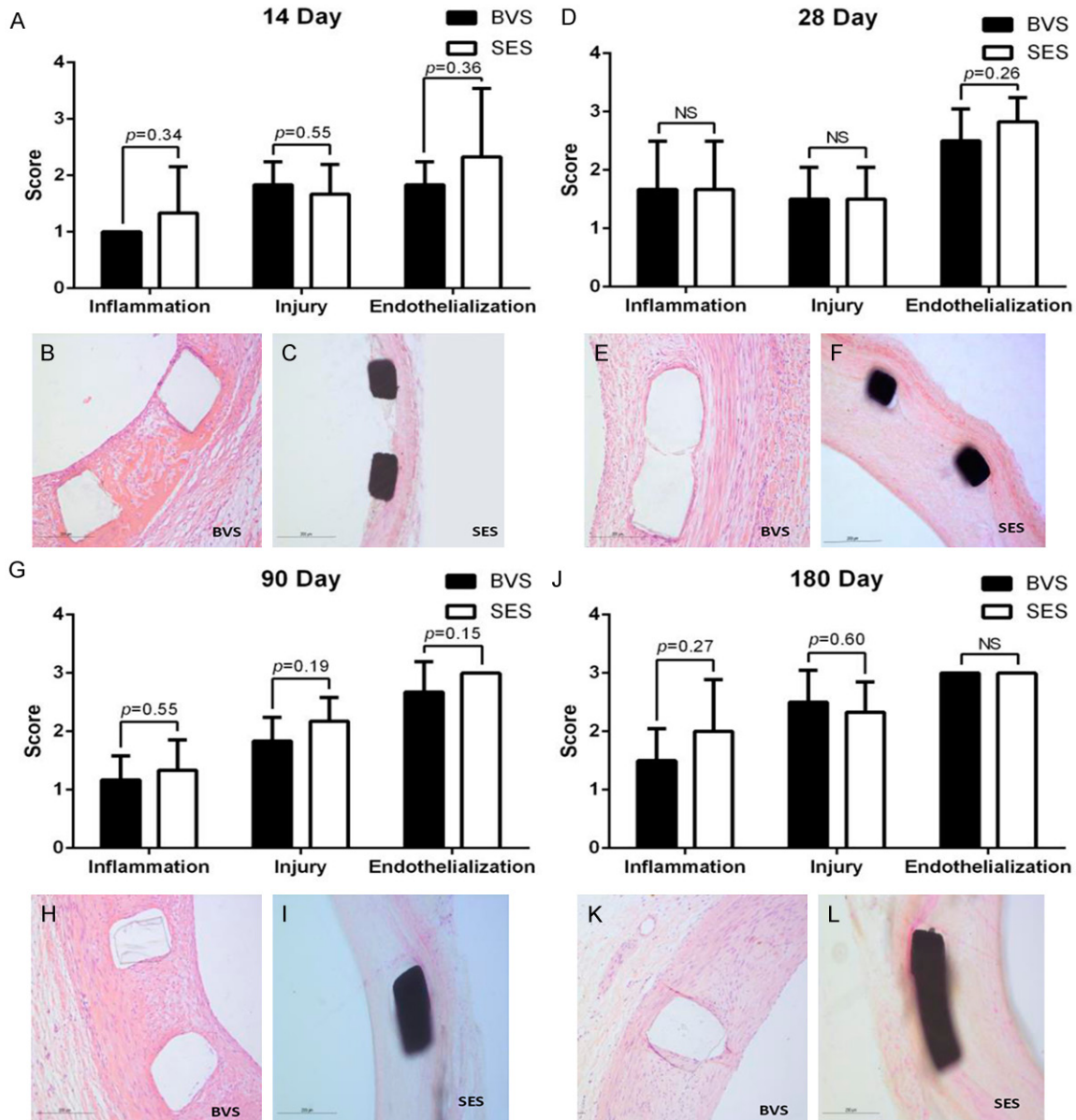
The results of QCA were showed in **Table 1** and representative photographs were shown in **Figure 1**. The LL and percentage diameter stenosis of BVS group were slightly higher than SES group ( $0.29 \pm 0.55$  mm vs.  $0.05 \pm 0.49$  mm,  $P = 0.46$  and  $16.4 \pm 23.5\%$  vs.  $8.8 \pm 8.7\%$ ,  $P = 0.48$ , respectively) at 14 days follow-up. Compared to SES group, the LL and percentage diameter stenosis of BVS group showed a slightly decreased tendency without statistical significant difference, at both 28 days and 90 days. At 180 days, QCA analysis indicated that

lumen loss and percentage diameter stenosis of BVS group were numerically smaller than those of SES group ( $0.59 \pm 0.29$  mm vs.  $0.79 \pm 0.50$  mm,  $P = 0.41$  and  $26.57 \pm 10.72\%$  vs.  $32.44 \pm 19.56\%$ ,  $P = 0.53$ , respectively).

### Histology

The summary of histomorphometric findings was shown **Table 2** and representative low-power photomicrographs were shown in **Figure 2**. The percentage neointimal proliferation was also higher in BVS group ( $29.45 \pm 9.28\%$  vs.  $29.08 \pm 20.93\%$ ,  $P = 0.969$ ) whereas the neointimal area was smaller ( $1.07 \pm 0.24$  mm<sup>2</sup> vs.  $1.62 \pm 1.25$  mm<sup>2</sup>,  $P = 0.313$ , respectively) with no significant difference at 14 days follow-up. The neointimal area and percentage neointimal

## Evaluation of a novel fully bioresorbable vascular scaffolds in porcine model



**Figure 3.** Pathological evaluation of BVS and SES groups at each single time point. (A, D, G and J) Illustrate the inflammation score, injury score and endothelialization score of two groups at 14 days, 28 days, 90 days and 180 days follow-up respectively. (B, E, H and K) Represent the high-power field histopathologic images of BVS group at 14 days, 28 days, 90 days and 180 days follow-up respectively. The high-power field histopathologic images of SES group at 14 days, 28 days, 90 days and 180 days follow-up are shown in (C, F, I and L) respectively.

proliferation of BVS group at 28 days follow-up showed a slightly decreased tendency without statistical significant difference ( $2.90 \pm 1.72 \text{ mm}^2$  vs.  $3.18 \pm 1.56 \text{ mm}^2$ ,  $P = 0.779$  and  $37.20 \pm 17.98\%$  vs.  $49.52 \pm 19.40\%$ ,  $P = 0.280$ , respectively) so as the result at 90 days follow-up ( $1.61 \pm 0.35 \text{ mm}^2$  vs.  $2.09 \pm 0.84 \text{ mm}^2$ ,  $P = 0.227$  and  $38.76 \pm 12.52\%$  vs.  $43.50 \pm 16.83\%$ ,  $P = 0.592$ , respectively). Notably, sig-

nificantly reduced neointimal area and percentage neointimal proliferation were observed in BVS group compared with SES group ( $1.13 \pm 0.23 \text{ mm}^2$  vs.  $2.29 \pm 0.91 \text{ mm}^2$ ,  $P = 0.013$  and  $31.13 \pm 4.59\%$  vs.  $51.46 \pm 10.61\%$ ,  $P = 0.002$ , respectively) at 180 days.

In histopathologic analysis, there were no significant differences in inflammation score, inju-

ry score and endothelialization score between two groups at each single time point (**Figure 3**).

### Discussion

DES have significantly improved long-term outcomes of PCI by decreasing the excessive growth of neointima. However, the permanent presence of the metallic platform might lead to the prolonged inflammatory response and untoward clinical outcomes [1, 2]. BVS have emerged as an interesting alternative since the presence of the prosthesis in the coronary artery is transient. This technology enables to restore the normal vasomotor tone and allows positive remodeling, simultaneously reducing the trigger for persistent inflammation and facilitating further interventions by percutaneous or surgical means. Absorb® BVS was definitely proved to be safe and effective device in the treatment of symptomatic coronary artery disease [8].

As always with new technologies there are many issues in the prototype device can be improved. A series of preliminary in-vivo and in-vitro studies [9-12] had confirmed that PLLA/ACP scaffolds had a superior radial strength performance compared with PLLA scaffolds, with the added advantages of neutralizing the acidic metabolites of PLLA, reducing inflammatory reactions and promoting endothelial repair. Meanwhile, Feng G et al [13] have demonstrated that vascular elastic recoil and scaffold expansion are adaptive support mechanisms, which is a unique advantage of the PLLA/ACP composite scaffold.

In the present, we used QCA and histomorphological methods to assess the preclinical performance of a novel bioresorbable PLLA/ACP scaffold implanted to the porcine coronary arteries. The 6-month follow-up results demonstrate the biological safety of the BVS, with no adverse cardiovascular events or in-stent thrombosis occurring during the observational period. The intensity of the inflammatory response associated with BVS implantation was most obvious at 28 days follow-up, without statistical significant difference from SES group. The inflammatory response of BVS group gradually decreased throughout follow-up with a trend of slighter than SES group and early endothelial repair, demonstrating the good biocompatibility of BVS.

Numerous studies have demonstrated, in order to prevent vascular collapse and late negative vascular remodeling, stents must maintain their mechanical structure for at least six months [14, 15]. In the study, the BVS group maintained an equivalent radial strength as the SES group through 6 months follow up without scaffold collapse or fracture. The fact that the BVS retained their in-vivo radial strength is in consistent with the results of some previous study [16], and demonstrate the scaffolds meet the necessary supporting performance requirements for their use in clinical practice.

SES have shown markedly reduced rates of restenosis with biodegradable polymer technique. But the permanent residual stent platform brings the prolonged inflammatory response which maybe induce new atherosclerosis and intimal hyperplasia further leading restenosis. BVS degraded its polymer as well as platform completely after 2-3 years in vivo may solve the long-term adverse reactions and reduce the restenosis. Notably, in the study, compared with SES group, significantly reduced neointimal area and percentage neointimal proliferation were observed in BVS group at 180 days. This result showed potential advantage of BVS in the long-term inhibition of neointimal proliferation.

Lumen gain is another advantage of the BVS for the treatment of coronary artery disease [17]. Feng G et al [13] had reported the lumen expansion of the PLLA/ACP scaffolds-stented segments occurred gradually within 12 months of implantation. On the other hand, the stent area and lumen area of SES stents remained relatively stable likely because of the permanent restriction of the stent. In the present, we used LL instead of the late lumen gain. The LL of BVS group was slightly higher than that of SES group at 14 days, however, it showed a decreased tendency compared to SES group through the follow up at 28 days, 90 days and 180 days. This result was likely attribute to the BVS degradation over time which allowed the recovery of the artery segment plasticity and remodeling ability. In SES group, due to the characteristics of the limited plasticity of metal materials, the stent area did not change statistically from post-implantation to 6 months. One can assume the lumen area of the stented segment

## Evaluation of a novel fully bioresorbable vascular scaffolds in porcine model

will always be smaller than its reference vessel area irrespective of follow-up time points.

### Limitations and future studies

First, the coronary arteries of the miniature pigs were not atherosclerotic and, as such, the mechanisms of vascular endothelial repair may be different from that observed in human. Second, because of the small sample size and short-term follow-up, our results need to be further confirmed in a larger number of animals. Third, the current study was not a serial observation so that we could not further investigate the dynamic change of the porcine coronary arteries after the novel BVS implantation.

### Conclusion

The novel BVS showed similar safety profile compared with SES, whereas may provide potential advantage in the long-term inhibition of neointimal proliferation. Further investigations are needed to validate these efficacy and safety in clinical trials.

### Acknowledgements

This study was sponsored by TT Medical, Inc.

### Disclosure of conflict of interest

None.

**Address correspondence to:** Dr. Ming Chen, Department of Cardiology, Peking University First Hospital, No. 8, Xishiku St., Xicheng District, Beijing 100034, China. Tel: +86 (10) 83572283; E-mail: cm6141@sohu.com

### References

- [1] Stettler C, Wandel S, Allemann S, Kastrati A, Morice MC, Schomig A, Pfisterer ME, Stone GW, Leon MB, de Lezo JS, Goy JJ, Park SJ, Sabate M, Suttorp MJ, Kelbaek H, Spaulding C, Menichelli M, Vermeersch P, Dirksen MT, Cervinka P, Petronio AS, Nordmann AJ, Diem P, Meier B, Zwahlen M, Reichenbach S, Trelle S, Windecker S and Juni P. Outcomes associated with drug-eluting and bare-metal stents: a collaborative network meta-analysis. *Lancet* 2007; 370: 937-948.
- [2] Kandzari DE, Leon MB, Meredith I, Fajadet J, Wijns W and Mauri L. Final 5-year outcomes from the endeavor zotarolimus-eluting stent clinical trial program: comparison of safety and efficacy with first-generation drug-eluting and bare-metal stents. *JACC Cardiovasc Interv* 2013; 6: 504-512.
- [3] Rzeszutko L, Depukat R and Dudek D. Biodegradable vascular scaffold ABSORB BVS-scientific evidence and methods of implantation. *Postepy Kardiol Interwencyjnej* 2013; 9: 22-30.
- [4] Lowe HC, Schwartz RS, Mac Neill BD, Jang IK, Hayase M, Rogers C and Oesterle SN. The porcine coronary model of in-stent restenosis: current status in the era of drug-eluting stents. *Catheter Cardiovasc Interv* 2003; 60: 515-523.
- [5] Otsuka F, Pacheco E, Perkins LE, Lane JP, Wang Q, Kamberi M, Frie M, Wang J, Sakakura K, Yahagi K, Ladich E, Rapoza RJ, Kolodgie FD and Virmani R. Long-term safety of an everolimus-eluting bioresorbable vascular scaffold and the cobalt-chromium XIENCE V stent in a porcine coronary artery model. *Circ Cardiovasc Interv* 2014; 7: 330-342.
- [6] Schwartz RS, Huber KC, Murphy JG, Edwards WD, Camrud AR, Vlietstra RE and Holmes DR. Restenosis and the proportional neointimal response to coronary artery injury: results in a porcine model. *J Am Coll Cardiol* 1992; 19: 267-274.
- [7] Carter AJ, Aggarwal M, Kopia GA, Tio F, Tsao PS, Kolata R, Yeung AC, Llanos G, Dooley J and Falotico R. Long-term effects of polymer-based, slow-release, sirolimus-eluting stents in a porcine coronary model. *Cardiovasc Res* 2004; 63: 617-624.
- [8] Stone GW, Gao R, Kimura T, Kereiakes DJ, Ellis SG, Onuma Y, Cheong WF, Jones-McMeans J, Su X, Zhang Z and Serruys PW. 1-year outcomes with the absorb bioresorbable scaffold in patients with coronary artery disease: a patient-level, pooled meta-analysis. *Lancet* 2016; 387: 1277-1289.
- [9] Lan Z, Lyu Y, Xiao J, Zheng X, He S, Feng G, Zhang Y, Wang S, Kislauskis E, Chen J, McCarthy S, Laham R, Jiang X and Wu T. Novel biodegradable drug-eluting stent composed of poly-L-lactic acid and amorphous calcium phosphate nanoparticles demonstrates improved structural and functional performance for coronary artery disease. *J Biomed Nanotechnol* 2014; 10: 1194-1204.
- [10] Zheng X, Wang Y, Lan Z, Lyu Y, Feng G, Zhang Y, Tagusari S, Kislauskis E, Robich MP, McCarthy S, Sellke FW, Laham R, Jiang X, Gu WW and Wu T. Improved biocompatibility of poly(lactic-co-glycolic acid) orv and poly-L-lactic acid blended with nanoparticulate amorphous calcium phosphate in vascular stent applications. *J Biomed Nanotechnol* 2014; 10: 900-910.
- [11] Combes C and Rey C. Amorphous calcium phosphates: synthesis, properties and uses in

## Evaluation of a novel fully bioresorbable vascular scaffolds in porcine model

- biomaterials. *Acta Biomater* 2010; 6: 3362-3378.
- [12] Dorozhkin SV. Amorphous calcium (ortho) phosphates. *Acta Biomater* 2010; 6: 4457-4475.
- [13] Feng G, Xiao J, Bi Y, Lan Z, Zheng X, Lu Z, Li J, Wu K, Kislaukis E, McCarthy S, Hu Q, Jiang X, Wu T and Laham R. 12-month coronary angiography, intravascular ultrasound and histology evaluation of a novel fully bioabsorbable poly-L-Lactic acid/amorphous calcium phosphate scaffolds in porcine coronary arteries. *J Biomed Nanotechnol* 2016; 12: 743-752.
- [14] Joner M, Finn AV, Farb A, Mont EK, Kolodgie FD, Ladich E, Kutys R, Skorija K, Gold HK and Virmani R. Pathology of drug-eluting stents in humans: delayed healing and late thrombotic risk. *J Am Coll Cardiol* 2006; 48: 193-202.
- [15] Virmani R, Farb A, Guagliumi G and Kolodgie FD. Drug-eluting stents: caution and concerns for long-term outcome. *Coron Artery Dis* 2004; 15: 313-318.
- [16] Xiao J, Feng G, Kang G, Lan Z, Liao T, Kislaukis E, Chen J, Xia J, Wang Z, Huo Z, Wang Q, Xi T, McCarthy S, Jiang X, Wu T and Laham R. 6-month follow-up of a novel biodegradable drug-eluting stent composed of poly-L-Lactic Acid and amorphous calcium phosphate nanoparticles in porcine coronary artery. *J Biomed Nanotechnol* 2015; 11: 1819-1825.
- [17] Lane JP, Perkins LE, Sheehy AJ, Pacheco EJ, Frie MP, Lambert BJ, Rapoza RJ and Virmani R. Lumen gain and restoration of pulsatility after implantation of a bioresorbable vascular scaffold in porcine coronary arteries. *JACC Cardio-vasc Interv* 2014; 7: 688-695.