Int J Clin Exp Med 2017;10(5):8535-8544
www.ijcem.com /ISSN:1940-5901/IJCEM0027213

Case Report

Diagnosis and treatment of heterotopic pancreas coexisting with digestive tract tumor: a report of 26 cases

Chao-Yong Tu[1], Wan-Lin Zhu[1], Chu-Xiao Shao[1], Jin-De Zhu[1], Jian-Fei Tu[1], Xin-Mu Zhou[2], Qiao-Mei Lin[1], Kun Zhang[1], Zhuo-Kai Li[1], Wei Tan[1], Chuan Jiang[1], Wei Chen[3]

Departments of [1]General Surgery, [2]Pathology, Lishui Central Hospital, No. 289, Kuochang Road, Lishui 323000, Zhejiang Province, China; [3]Institute for Molecular Engineering, University of Chicago, 5640 South Ellis Ave, Chicago, IL 60637, USA

Received March 3, 2016; Accepted June 5, 2016; Epub May 15, 2017; Published May 30, 2017

Abstract: Heterotopic pancreas (HP) coexisting with digestive tract tumor is scarce. Its diagnosis and treatment isn't well known. In the present study, clinical data of 26 cases of HP coexisting with digestive tract tumor diagnosed with pathology from January 1996 to December 2015 were analysed retrospectively. Each pathological slide was reviewed. Patients data included age, gender, symptoms, diagnostic methods, coexisting digestive tract tumor' characteristics, treatment and follow up. Follow up data were completed by telephone. 25 cases owned digestive tract symptoms. Coexisting diseases included 20 cases of gastric cancer, 3 cases of ascending colon adenocarcinoma, 1 case of gastric stromal tumor, stromal tumor of proximal jejunum and duodenal hemangioma, respectively. 1 cases was diagnosed preoperatively. Intraoperatively, 10 cases were found, 4 cases of which were confirmed by frozen section. 15 cases were diagnosed postoperatively. All cases underwent resection. HP didn't recur in all cases. 16 cases of coexisting digestive malignant tumor died of tumor recurrence and/or metastasis. Therefore, symptoms of HP coexisting with digestive tract tumor are atypical. It's helpful to diagnose it with preoperative ultrasonic endoscopy, imaging examinations and intraoperative frozen section. Benign lesions should undergo resection.

Keywords: Digestive tract tumor, heterotopic pancreas, coexisting. diagnosis and treatment

Introduction

Heterotopic pancreas (HP) is a congenital malformation which lacks anatomic vascular and duct continuity with the main body of the pancreas. Other names for it include ectopic, aberrant or accessory pancreas [1]. Its incidence in autopsy can be as high as 14% [2, 3]. Although the origin of HP is controversial, two main theories have been suggested. One theory postulates the embryologic origin involves abnormal detachment of one or more branching pancreatic buds during embryonic rotation so that it commonly occurs near the stomach, especially in the gastric, duodenum and proximal jejunum [4]. The other one is that in the growth of the ventral pancreatic bud a proportion is transported by the longitudinal growth of the intestines [5, 6]. Nowadays there are more and more cases of HP reported. However, it is easily misdiagnosed preoperatively. Many of them are incidently found during autopsy or laparotomy for other diseases. Till now, few cases of HP coexisiting with digestive tumors have been reported. Chen HL et al [7] reported 39 cases of HP, 24 cases of which were accidently found and only 4 of them coexisted with digestive tumors. Herein, we reported 26 cases which were found from January 1999 to December 2015.Clinical data were analyzed retrospectively. Diagnosis and treatment was intensively studied.

Materials and methods

Patients

This is a retrospective study performed at the Lishui Central Hospital, Zhejiang Province, China. From January 1991 to December 2015,

Table 1. Clinical features of 26 cases of heteroptic pancreas coexisting digestive tract tumor

Patient no./gender/age (years)	Complaints	Diagnostic time	Operative procedure	Coexisting digestive tract tumor	Location of HP	Layer	Size of HP (cm)	Type of HP
1/M/64	Abdominal pains	Postoperatively confirmed	Dismally subtotal gastroectomy	Gastric antrum carcinoma	Gastric antrum	Sreosa	0.8	I
2/M/42	Change in bowel habits	Intraoperatively found, postoperatively confirmed	Right hemicolectomy	Ascending colon carcinoma	Ileocecus	Submucosa	1.5	I
3/M/41	Abdominal pains	Intraoperatively found, postoperatively confirmed	Right hemicolectomy	Ascending colon carcinoma	Ileocecus	Muscularis	1.0	II
4/M/70	Abdominal pains	Postoperatively confirmed	Dismal subtotal gastroectomy with jejunal lesion resection	Gastric antrum carcinoma	Gastric antrum	Sreosa	0.6	I
5/M/42	Abdominal pains	Postoperatively confirmed	Dismal subtotal gastroectomy with jejunal lesion resection	Gastric antrum carcinoma	Gastric antrum	Sreosa	0.5	I
6/M/71	Change in bowel habits	Intraoperatively found, postoperatively confirmed	Total colectomy with jejunal lesion resection	Ascending colon carcinoma, sigmoid colon tubular adenoma	Jejunum	Sreosa	2.0	I
7/F/65	Abdominal distension	Intraoperatively found, postoperatively confirmed	Dismal subtotal gastroectomy with jejunal lesion resection	Carcinoma of gastric angle	Jejunum	Sreosa	2.0	II
8/F/66	Abdominal pains	Preoperatively confirmed	Total gastroectomy	Carcinoma of gastric cardia	Gastric antrum	Submucosa	1.2	II
9/F/63	Abdominal pains	Postoperatively confirmed	Total gastroectomy	Carcinoma of gastric cardia	Gastric cardia	Submucosa	0.9	I
10/F/72	Abdominal distension	Postoperatively confirmed	Dismally subtotal gastroectomy with splenectomy	Gastric antrum carcinoma	Accessory spleen	-	1.5	I
11/M/67	Abdominal pains	Postoperatively confirmed	Dismally subtotal gastroectomy	Gastric antrum carcinoma	Gastric antrum	Sreosa	2.0	I
12/M/74	Abdominal distension	Postoperatively confirmed	Dismally subtotal gastroectomy	Carcinoma of gastric angle	Gastric antrum	Muscularis	1.0	I
13/F/71	Abdominal distension	Intraoperatively found, postoperatively confirmed	Dismally subtotal gastroectomy	Gastric antrum carcinoma	Gastric corpus	Submucosa	1.0	I
14/M/53	Abdominal pains	Postoperatively confirmed	Dismally subtotal gastroectomy	Gastric antrum carcinoma	Gastric antrum	Mucosa	0.8	I
15/M/66	Abdominal pains	Postoperatively confirmed	Pallatively total gastroectomy	Carcinoma of gastric cardia	Gastric antrum	Submucosa	1.0	I
16/M/54	Vomit, hematemesis black, angular anemia	Postoperatively confirmed	Pallatively total gastroectomy	Carcinoma of gastric corpus	Gastric cardia	Muscularis	1.0	II
17/M/59	Dysphagia	Intraoperatively found, postoperatively confirmed	Total gastroectomy	Carcinoma of gastric cardia	Mesostenium	-	1.5	I
18/M/56	Abdominal pains	Postoperatively confirmed	Dismally subtotal gastroectomy	Gastric antrum carcinoma	Canales pyloricus	Submucosa	1.2	I
19/M/58	Abdominal pains	Intraoperatively found, intraoperatively confirmed by frozen section	Total gastroectomy	Carcinoma of gastric corpus	Duodenal bulb	Sreosa	2.0	I
20/F/67	Abdominal pains	Intraoperatively found, intraoperatively confirmed by frozen section	Partial jejunal resection	Intestinal stromal tumor	Jejunum	Submucosa	2.0	I
21/F/61	Abdominal distension, vomit, hematemesis black	Postoperatively confirmed	Pallatively subtotal gastroectomy	Gastric antrum carcinoma	Gastric antrum	Sreosa	0.5	I
22/F/75	Dysphagia	Postoperatively confirmed	Proximally subtotal gastroectomy	Carcinoma of gastric cardia	Gastric corpus	Submucosa	0.8	I
23/F/72	Abdominal distension	Intraoperatively found, intraoperatively confirmed by frozen section	Total gastroectomy wtih jejunal tumor resection	Stromal tumor of fundus in the stomach	Jejunum	Muscularis	2.0	I
24/M/53	Abdominal pains	Postoperatively confirmed	Dismally subtotal gastroectomy	Gastric antrum carcinoma	Gastric corpus	Mucosa	0.8	I
25/M/61	Dysphagia	Postoperatively confirmed	Pallatively total gastroectomy	Carcinoma of gastric cardia	Gastric antrum	Submucosa	1.0	I
26/M/56	None	Intraoperatively found, intraoperatively confirmed by frozen section	Duodenal tomor resection	Duodenal hemangioma	Duodenal descending part	Submucosa	2.0	I

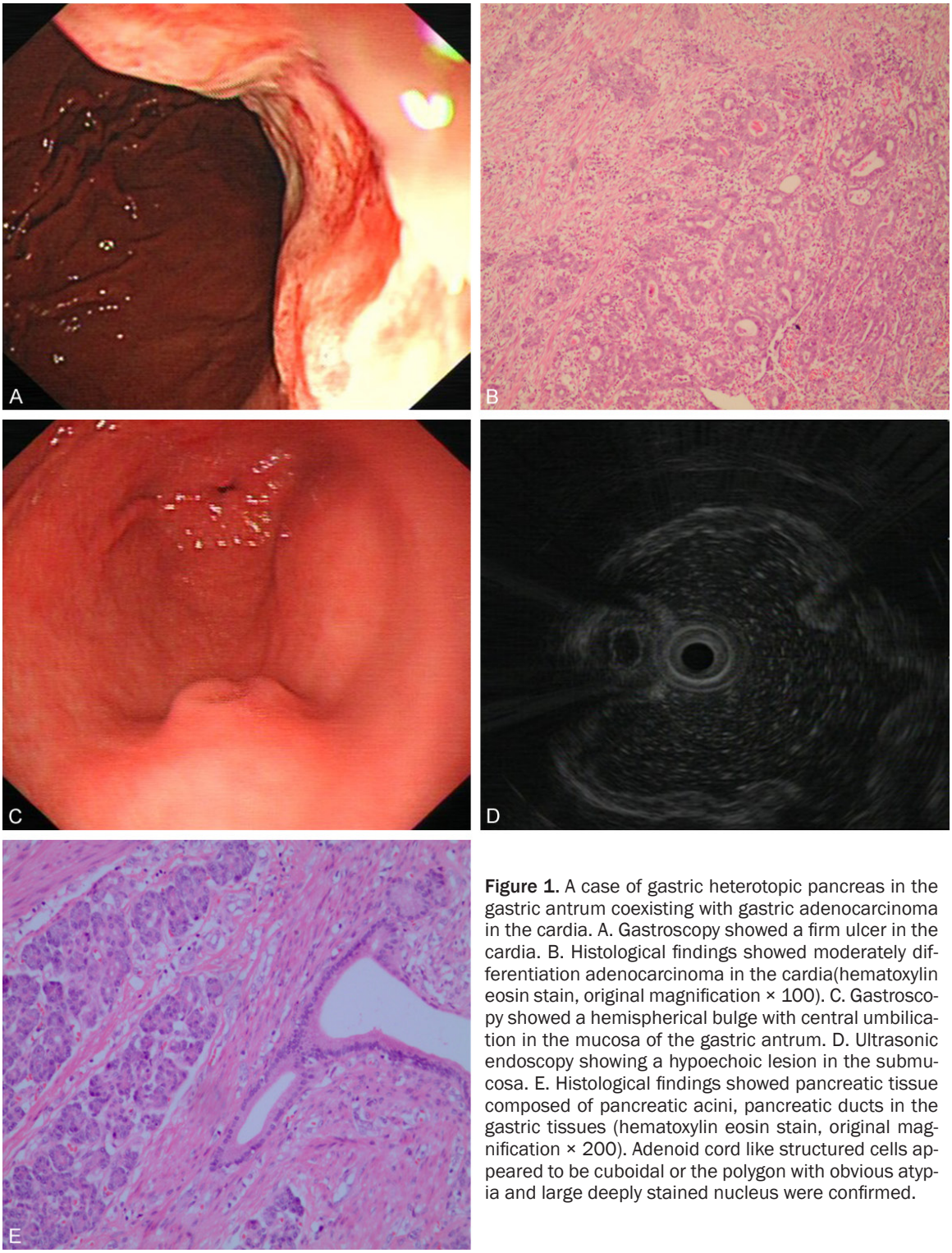

Figure 1. A case of gastric heterotopic pancreas in the gastric antrum coexisting with gastric adenocarcinoma in the cardia. A. Gastroscopy showed a firm ulcer in the cardia. B. Histological findings showed moderately differentiation adenocarcinoma in the cardia(hematoxylin eosin stain, original magnification × 100). C. Gastroscopy showed a hemispherical bulge with central umbilication in the mucosa of the gastric antrum. D. Ultrasonic endoscopy showing a hypoechoic lesion in the submucosa. E. Histological findings showed pancreatic tissue composed of pancreatic acini, pancreatic ducts in the gastric tissues (hematoxylin eosin stain, original magnification × 200). Adenoid cord like structured cells appeared to be cuboidal or the polygon with obvious atypia and large deeply stained nucleus were confirmed.

5293 consecutive cases of digestive tract tumor which underwent operations were analyzed. All cases that coexisted with HP were included. We then reviewed the data and each pathological slide that had been stained with hematoxylin and eosin in order to determine whether the components of pancreatic tissue including acini, ducts and islets of Langerhans were present. The HP types were classified according to Heinrich's classification [8]. Patients data included age, gender, symptoms, diagnostic methods, coexisting digestive tract

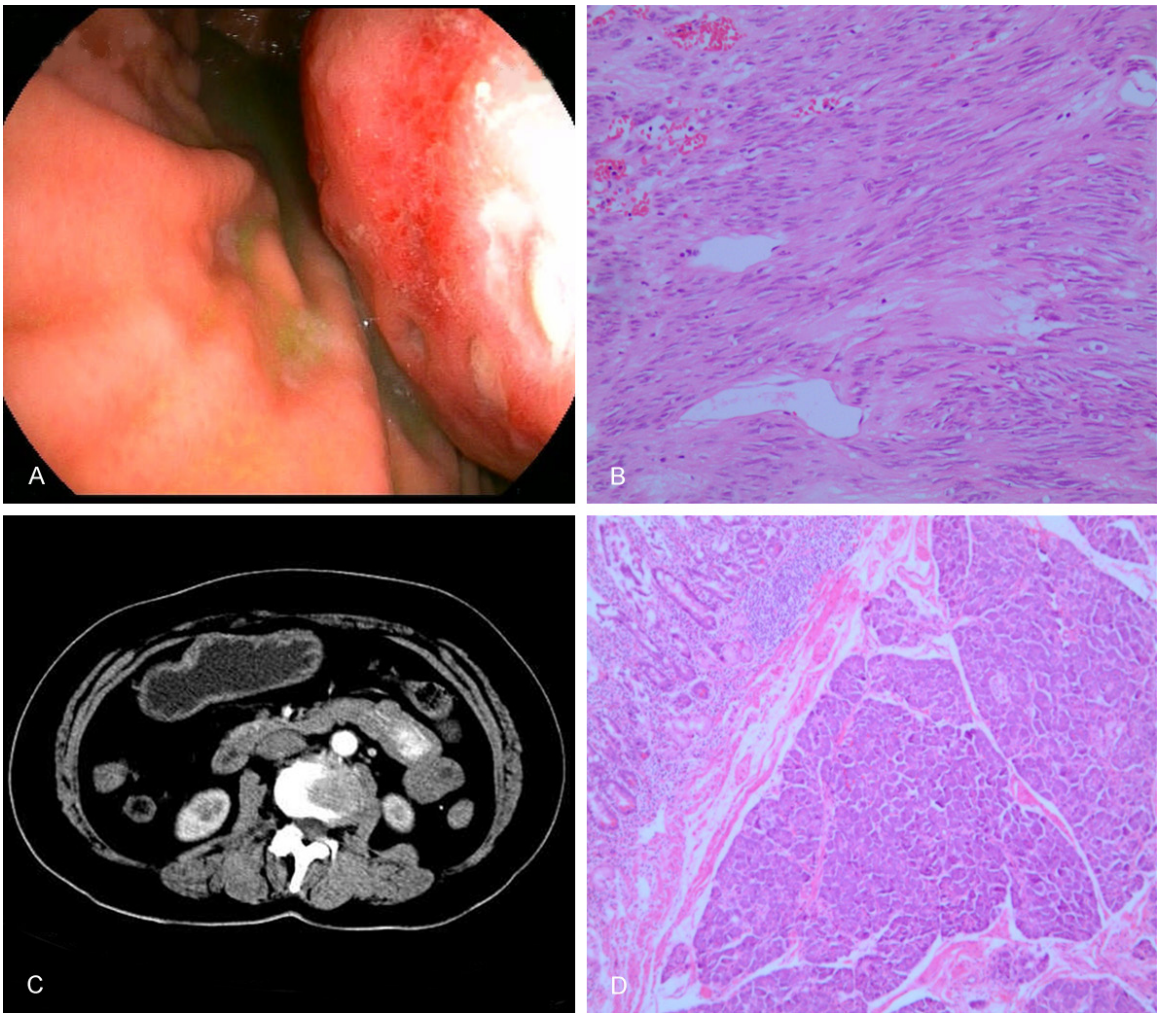

Figure 2. A case of jejunal heterotopic pancreas coexisting with gastric stromal tumor. A. Gastroscopy showed a huge submucosal lesion with small ulceration in the gastric corpus. B. Histological findings showed a highly risk stromal tumor in the gastric corpus (hematoxylin eosin stain, original magnification × 100). The tumor was composed of moderately heterogeneous fusiform cells which were in interlacing or turbulence arrangement was considered. C. Contrast computed tomography showing an obviously contrast enhanced lesion in proximal jejunum which was suspected as a stromal tumor. D. Histological findings showed pancreatic tissue composed of pancreatic acini, pancreatic ducts and islets of Langerhans in the jejunal tissues (hematoxylin eosin stain, original magnification × 100).

tumor' characteristics, treatment and follow up. Stage of malignant cases were clsassified using the seventh edition of UICC/AJCC TNM stage system. Cases confirmed by pathology and cases with complete clinical data were included regardless of age and gender. Cases which lacked of typical pathological features or complete clinical data were excluded. Follow up data were completed by telephone. The date of last follow-up was December 31, 2015.

Ethics statement

Written consent was obtained from the patients for their information to be stored in the hospital database and used for research.

Statistical analysis

All statistical analyses were performed using the software, Statistical Package for Social Science (SPSS) for Windows, version 16.0 (SPSS Inc., Chicago, IL, USA). A two-tailed Student's t test was used to compare continuous variables. A P value of <0.05 was considered to indicate statistical significance.

Results

Clinical presentations

26 patients were diagnosed with HP coexisting with digestive tract tumor. They constituted to

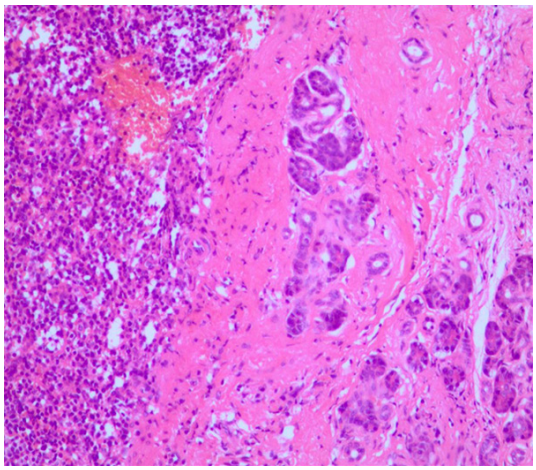

Figure 3. A case of heteroptic pancreas in accessory spleen coexisting with gastric antrum carcinoma. Histological findings showed pancreatic tissues in splenic tissues. (hematoxylin eosin stain, original magnification × 200). Composed of pancreatic acini, pancreatic ducts.

60.47% (26/43) of all the cases of HP and 0.49% (26/5293) of all digestive tumor in the meantime. Average age was 61.50±9.79 years (range 41~75), with 17 (65.38%) patients of male gender. Course of disease varied from 5 days to 3 years. Except 1 case was asymptomatic, the remaining 25 cases owned symptoms including abdominal pains in 13 cases, abdominal distension in 6 cases, dysphagia in 3 cases, hematemesis black in 2 cases, change in bowel habits in 2 cases, vomiting in 2 cases and angular anemia in 1 cases. 10 cases owned the signs of abdominal tenderness. 1 cases were diagnosed preoperatively. Intraoperatively, 10 cases were found, 4 of which were diagnosed by frozen section. 15 cases were confirmed postoperatively. All cases underwent regional resection (see in **Table 1**).

Diagnosis

Carcinoembryonic antigen (CEA) increased in 5 cases coexisting with gastric adenocarcioma. Gastroenterography was performed in 6 cases. Although coexisting digestive tumors were found in 4 cases, HP couldn't be discovered. Edoscope was performed in 25 cases, in all of which digestive tract tumors were discovered. What's more, other lesions were revealed in 2 cases so that ultrasonic endoscope (EUS) was performed. HP was confirmed in 1 case (see in **Figure 1**) and gastric stromal tumor was suspected in the other. Computed tomography was performed in 13 cases, new lesions were detected in 3 cases in addition to digestive tumors. 1 case of lesion in proximal jejunum was suspected as stromal tumor because of obvious contrast enhancement (**Figure 2**). 2 cases of ileocecal lesion were diagnosed as lipoma for lack of enhancement.

Treatment and outcome

All patients underwent surgery (see in **Table 1**). All lesions were singular. The mean tumor size of all cases was 1.25±0.53 cm (range from 0.5 cm to 2.0 cm). The mean tumor size of cases which were found intraoperatively was 1.70±0.42 cm (range from 1.0 cm to 2.0 cm). The mean tumor size of cases which were found postoperatively was 0.97±0.39 cm (range from 0.5 cm to 2.0 cm). There was significantly different in the tumor size between the former and the latter ($P<0.01$). The location of the HP included gaster in 16 cases (2 cases in cardia, 3 cases in corpus, 10 cases in antrum and 1 case in canales pyloricus), duodenum in 2 case (duodenal bulb in 1 case and duodenal desending part in 1 case), proximal jejunum in 4 cases, ileocecus in 2 cases, accessary spleen in 1 case (**Figure 3**), mesostenium in 1 case. There were 18 cases of HP coexisted with digestive tumor in the same organ. Among them, 16 cases were in the gaster, 1 case in the duodenum and 1 case in the jejunum. In digestive HP, 2 cases located in mucosa, 10 cases in the submucosa, 4 cases in muscularis and 8 cases in serosa. 20 cases coexisted with gastric carcinoma. The histological types included highly differentiated adenocarcinoma in 5 cases, moderately differentiated adenocarcinoma in 9 cases, poorly differentiated adenocarcinoma in 4 cases and poorly differentiated mucinous adenocarcinoma in 2 cases. There were 6 cases in stage IA, 1 cases in stage IB, 1 case in stage IIA, 4 cases in stage IIIB, 6 cases in stage IIIA, 2 cases in stage IIIB and no cases in stage IV. 3 cases coexisted with ascending colonic well differentiated adenocarcinoma (one case coexisting with multiple colonic polyps), all of which were at stage IIB. Other coexsiting disgestive tumors included 1 case of of gastric high risk stromal tumor, of low risk stromal tumor in proximal jejunum and of duodenal hemangioma (**Figure 4**). According to HP lesions, there were 22 cases of type I, 4 cases type II and none case of type III.

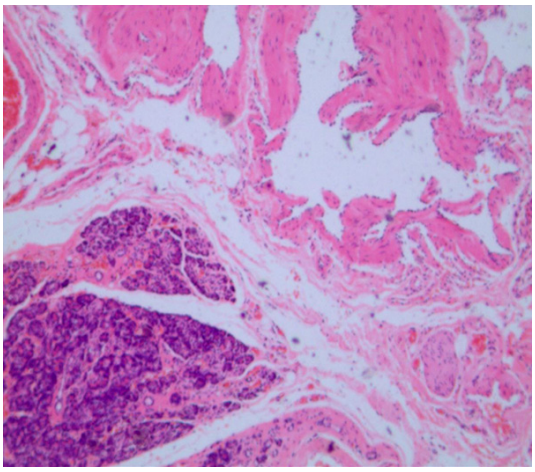

Figure 4. A case of duodenal hemangioma coexisting with heteroptic pancreas. Histological findings showed pancreatic tissue in duodenal hemangioma. (hematoxylin eosin stain, original magnification × 100). Composed of pancreatic acini, pancreatic ducts.

There weren't any perioperative death. Postoperatively, 1 case of pancreatic fistula and 1 case of incision infection occured, both of which were cured with conservative treatment. In the 90 months [rang 22 months to 195 months] following up time, HP didn't recur in all cases. 16 cases of coexisting digestive malignant tumor died of tumor recurrence and/or metastasis. The remaining cases were all healthy.

Discussion

The incidence of HP was reported in 0.6-5.6% of autopsy cases and in 0.2% of upper abdominal laparotomies [9]. Nowadays, continuous cases of HP are reported, which occurs more frequently near the normal site of pancreatogenesis to the jejunum. It seldom locates in liver [10], spleen [11], gallbladder [12], lung [13], omentum [14], mesentery, umbilicus, mediastinum [3], fallopian tube [15, 16], Mechek diverticulum [17], common bile duct [18] etc. In this study, 84.62% (22/26) cases located in the gaster, duodenum and proximal jejunum. It's often discovered intraoperatively or posteratively and is challengable to be preoperatively diagnosed. HP can often be mistaken for GIST or leiomyoma for it is difficult to diagnose definitively even though invasive endoscopic biopsy and its radiologic characteristics are similar to US and CT scanning [19]. Few cases coexisting with digestive tumors have been reported. In this study, there are 60.47% cases coexisting with digestive tumors. The reason is warranted for further study. It often occurs in patients aged from 40-60 year with male bias [20], which is similar with digestive malignant tumors. As a congenital disease, it's needed to study whether it owns such genetic susceptibility as digestive tumors. In cases of HP coexisting with digestive malignant tumors, no special characteristics of differentiation degree and the staging could be found. There are 18 cases of which HP and the digestive tumor coexist in the same organ. 14 cases are gastric HP coexisting with gastric carcinoma. It's warranted to make clear whether the origin of gastric carcinoma is related to the continuous stimulating of pancreas secretions in the around gastric tissues. There are more cases coexisting with malignant tumors than those with benign tumors, which is explained by that more digestive malignant cases underwent operation. As a normal pancreatic tissue, HP tissue specimens can contain pancreatic acini, ducts and occasionally islets of Langerhans [21]. Pediatric cases are rarely reported, because it is slow growing and tends to remain as a small lesion and is usually overlooked [22]. Orri et al [5] reported 32 cases, of which there were only 3 cases in the pediatric age group. In this study, there was none of HP in children. Heinrich's classification is commonly accepted, being as follows: type I (all elements of a normal pancreatic gland], type II (pancreatic gland devoid of pancreatic islet cells), and type III (only pancreatic ducts are present) [8]. Macroscopically HP is often located in the submucosal layer, but can also be found in the muscularis, mucosa, sub-serosa and serosa [23].

Symptoms of HP are related to its location, size and growth pattern. Lesions are usually asymptomatic when they are small. Orrti et al [5] reported 14 of 30 cases had symptoms. However, Ogata H et al [24] reported symptom only in 1 of 12 cases. Armstrong et a [25] found that symptoms are related to the size of the gastric heterotopic pancreas lesion and considered that size greater than 1.5 cm is more likely to be of clinical significance. They also found that involving the mucosal surface was more likely to produce symptoms. Atypical symptoms such as abdominal pain, abdominal distention, melena and anorexia are common. Intussusception involving heterotopic pancreatic tissue have

been reported [26, 27]. Pancreatitis, hemorrhage and canceration could happen in severe cases [28-30]. In order to confirm the malignant transformation of a HP, the following three criteria must be met: (1) the tumor must be found within or near the HP tissue; (2) direct transition between pancreatic structures and the carcinoma must exist malignant transformation of the HP must be differentiated from the metastatic lesion or direct invasion from a neighboring digestive cancer; and (3) the nonneoplastic pancreatic tissue must include at least fully developed acini and ductal structures [31]. In our study, 18 cases located in the same organ, all which could be excluded from the existence of malignant transformation according to the above criteria. No symptoms can only attribute to the HP because all of them were all nonspecific.

Predominantly digestive tumors could be diagnosed by endoscopic biopsy and pathology. An HP usually invades the submucosa or muscle layer, and has histologically normal pancreatic tissue [32]. Because the HP was often surrounded by normal surfaces, routine upper endoscopy was not helpful for diagnosis. The typical endoscopical finding of HP is a firm round or oval subepithelial lesion with a central depression, which corresponds to the opening of a duct [20]. But Hazzan et al [33] suggested that, although central umbilication of the lesion is one of the characteristic features of a HP, it is difficult to diagnose because umbilication is often absent in tumors of less than 1.5 cm in diameter. What's more, the small lesion of HP is easily ignored by endoscopists for they are often satisfied with diagnosis of coexisting tumors. EUS is superior to ordinary endoscopy because it can not only accurately position different layer structure of the digestive tract, but also biopsy the submucosal tissues. HP usually appears hypoechoic and heterogeneous with indistinct margins during EUS and most commonly originates from the third or fourth layer or a combination of these two layers of the gastrointestinal (GI) tract [34]. By EUS, Ryu et al [35] also identified the anechoic duct structure in some cases of HP. EUS was shown to be more useful than CT in visualizing the pancreatic duct [36] in other work. Endoscopic removal of gastric aberrant pancreas is also useful for accurate diagnosis and treatment [37]. Multiple biopsies should be taken with a large biopsy forceps in order to increase the possibility of a diagnosis. We undertook EUS examination in 2 cases, one of which was diagnosed. However, about 50% of cases of cytological examinations are inconclusive [38]. Kobara H et al [39] suggested to identify HP by endoscopic direct imaging with submucosal endoscopy for it may distinguish these lesions from neoplastic submucosal tumors. HP in the stomach or duodenum cannot be distinguished HP from other submucosal tumors because the nonspecific CT findings. However, CT with arterial, portal and equilibrium phase IV contrast may demonstrate the lesions which enhance similarly with the normal pancreatic tissue [40]. Kim et al [1] reported that HP with predominantly pancreatic acini showed a homogeneous enhancement pattern, whereas lesions with mixed composition of acini and cystic ducts showed a heterogeneous enhancement. For the distension of the jejunum in routine abdominal CT protocols is usually insufficient, it might be difficult to detect surface dimpling and prominent overlying mucosa. Kim JY et al [1] found that when 2 or more characteristics of typical position [prepyloric antrum and duodenum], endoluminal growth pattern ill-defined border, prominent enhancement of overlying mucosa and an LD/SD (long diameter/short diameter) ratio of greater than 1.4 existed in CT, the sensitivity and specificity for diagnosing ectopic pancreas were 100% and 82.5% respectively. As resolution ability of CT is about 1cm and it's less sensitive in diagnosing holly organs than in solid organs, HP of the digestive tract is difficult to be diagnosed by CT alone. In this study, none cases were confirmed preoperatively by CT. For capsule endoscopy provides high-quality images with a negligible rate of adverse events and complications, it's becoming the procedure of choice for evaluation of patients with suspected small bowel lesions. A German multicenter trial of 56 patients showed a better diagnostic yield with capsule endoscopy than with push enteroscopy, enteroclysis, or angiography [41]. The main disadvantage is that it couldn't allow for biopsy. Okuhata T et al [42] first described the features of dynamic gadolinium-enhanced magnetic resonance imaging [MRI] findings in HP, which was that the similarity with the normal pancreas in fat-suppressed T1-weighted images was useful as a diagnostic indicator. Jiang KM et al [43] compared MRI findings in HP with that in other submucosal tumors in upper gastrointestinal tract and found abdominal MRI with DWI can be a valuable tool for dif-

ferentiating ectopic pancreases from UGI submucosal tumors. Dong A et al [44] reported two cases of increased FDG uptake of HP in the stomach and suggested HP should be included in the differential diagnosis of abnormal gastric FDG accumulation along with tumor and infectious processes.

Comprehensive exploration of all the abdominal cavity and timely frozen section of tiny lesion is necessary. Among 10 cases of HP which were found intraoperatively, most ones located in the same organ of tumor location (i.e. gastric corpus HP coexisting with gastric antrum carcinoma) or near the tumor location (i.e. ileocecal HP coexisting with ascending colon carcinoma). 4 cases were confirmed by intraoperative frozen section. Tumor size of cases which were found intraoperatively was significantly bigger than those found postoperatively. Cases which were discovered postoperatively may attribute to smaller lesions and resting content with the diagnosis of malignant tumors introperatively. There was one case of HP with the size of 2 cm, which was introperatively regarded as metastatic lymph node for it located in the greater curvature.

For HP owns the risk of malignant change or other serious complications such as pancreatitis and digestive tract bleeding, it should be removed whenever it is found during laparotomy. Surgical procedures depend on the location of HP and the coexisting diseases. With intraoperative frozen section 4 cases were confirmed in this study, we suggest it should be extensively used. Regional resection is enough for non-canceration HP in order to preserve organic function and lessen surgical trauma. While the HP is within the scope of tumor resection, surgical trauma won't be increased. There were 17 cases belonging to it, of which 14 cases coexisted with gastric cancer, 3 cases coexisted ascending colon carcinoma. HP and coexisting tumor should be resected separately when they don't locate in the scope of tumor resection. In the modern laparoscopic era, laparoscopic procedures are suggested in order to decrease surgical trauma and enhance recovery. The intraoperative frozen section is emphasized in the ampulla HP. As long as the malignancy is excluded, trying to perform regional resection instead of pancreatoduodenectomy is helpful for patients to recover. We encountered 2 cases of lesions in lower common bile duct, which were performed PD because of lack of experiences of regional resection and the intraoperative diagnosis of malignancy [45].

The present study has some limitations. Firstly, a relative small number of patients were included so that few cases of other origins except of stomach, duodenum and proximal jejunum. Secondly, noncomplete characters were reported because of a retrospective study. However, it is the largest study in English literature that has investigated the Diagnosis and treatment of HP coexisting with digestive tract tumor.

In conclusion, HP coexisting with digestive tract tumor is rare. Preoperative diagnosis is challengeable for its atypically clinical features. Because of the risk of malignant change or other serious complications such as pancreatitis and digestive tract bleeding, it should be removed whenever it is found during laparotomy.

Disclosure of conflict of interest

None.

Address correspondence to: Chao-Yong Tu and Zhuo-Kai Li, Department of General Surgery, Lishui Central Hospital, No. 289, Kuochang Road, Lishui 323000, Zhejiang Province, China. E-mail: tcy7409@163.com (CYT); lizhuokai@hotmail.com (ZKL); Wei Chen, Institute for Molecular Engineering, University of Chicago, 5640 South Ellis Ave, Chicago, IL 60637, USA. E-mail: viogro@163.com

References

[1] Kim JY, Lee JM, Kim KW, Park HS, Choi JY, Kim SH, Kim MA, Lee JY, Han JK, Choi BI. HP: CT findings with emphasis on differentiation from small gastrointestinal stromal tumor and leiomyoma. Radiology 2009; 252: 92-100.

[2] Dolan RV, ReMine WH, Dockerty MB. The fate of heterotopic pancreatic tissue. A study of 212 cases. Arch Surg 1974; 109: 762-765.

[3] Lai EC, Tompkins RK. Heterotopic pancreas: review of a 26 year experience. Am J Surg 1986; 151: 697-700.

[4] Orri TO, Ingibjorg, Ronald M. Diagnosis and treatment of gastric heterotopic pancreas. World J Surg 2006; 30: 1682-1689.

[5] Ben-Baruch D, Sandbank Y, Wolloch Y. Heterotopic pancreatic tissue in the gallbladder. Acta Chir Scand 1986; 152: 557-558.

[6] Inceoglu R, Dosluoglu HH, Kullu S, Ahiskali R, Doslu FA. An unusual cause of hydropic gallbla-

dder and biliary colic-heterotopic pancreatic tissue in the cystic duct: report of a case and review of the literature. Surg Today 1993; 23: 532-534.
[7] Chen HL, Chang WH, Shih SC, Bair MJ, Lin SC. Changing pattern of HP: 22 years of experience in a medical center. J Formos Med Assoc 2008; 107: 932-936.
[8] Von Heinrich H. Ein Beitrag zur Histologie des sogen. akzessorischen Pankreas. Virchows Arch A Pathol Anat Histopathol 1909; 198: 392-401.
[9] Deastrobarbosa JJ, Docketry MB, Waugh JM. Pancreatic heterotopia; review of the literature and report of 41 authenticated surgical cases, of which 25 were clinically significant. Surg Gynecol Obstet 1946; 82: 527-542.
[10] Fukueda M, Hamada N, Kaieda M, Kadono J, Nakamura N, Ishizaki N. A case of heterotopic pancreas in the liver with primary cholesterol hepatolithiasis. Nippon Shokakibyo Gakkai Zazzhi 2000; 97: 1057-1061.
[11] Mourra N, Balladur P, Parc R, Flejou JF. Intrasplenic mucinous cystadenoma with mesenchymal stroma arising in pancreatic heterotopia. Histopathology 2003; 42: 616-618.
[12] Pilloni L, Cois A, Uccheddu A, Ambu R, Coni P, Faa G. Complete pancreatic heterotopia of gallbladder with hypertrophic duct simulatig an adenomyoma. World J Gastroentero 2006; 12: 1786-1787.
[13] Marchevsky AM. Lung tumors derived from ectopic tissue. Semin Diagn Pathol 1995; 12: 172-184.
[14] Tornoczky T, Kalman E, Jakso P, Mehes G, Pajor L, Kajtar GG, Battyany I, Davidovics S, Sohail M, Krausz T. Solid and papillary epithelial neoplasm arising in heterotopic pancreatic tissue of the mesocolon. J Clin Pathol 2001; 54: 241-245.
[15] Beltrán MA, Barría C. Heterotopic pancreas in the gallbladder: the importance of an uncommon condition. Pancreas 2007; 34: 488-490.
[16] Slack JM. Developmental biology of the pancreas. Development 1995; 121: 1569-1580.
[17] Koh HC, Page B, Black C, Brown I, Ballantyne S, Galloway DJ. Ectopic pancreatic-type malignancy presenting in a Meckel's diverticulum: a case report and review of the literature. World J Surg Oncol 2009; 7: 54-57.
[18] Maisonnette F, Abita T, Lachachi F, Pichon N, Durand-Fontanier S, Valleix D, Descottes B. Aberrant pancreas: report of five cases. Ann Chir 2004; 129: 241-243.
[19] Milosavljevic T, Perisic V, Opric D, et al. Ectopic pancreas in the gastric wall. Arch Gastroenterohepatol 2000; 19: 24-27.
[20] Chen SH, Huang WH, Feng CL, Chou JW, Hsu CH, Peng CY, Yang MD. Clinical analysis of HP with endoscopic ultrasonography: an experience in a medical center. J Gastrointest Surg 2008; 12: 877-881.
[21] Qualia CM, Rossi TM and Ullah A. Heterotopic pancreatic tissue fond in the esophagus of a 14-year-old girl. Gastroenterol Hepatol [NK] 2007; 3: 939-940.
[22] Feldman M, Weinberg T. Aberrant pancreas: a cause of duodenal syndrome. JAMA 1952; 148: 893-898.
[23] Rubbia-Brandt L, Huber O, Hadengue A, Frossard JL. An unusual case of gastric heterotopic pancreas. JOP 2004; 5: 484-487.
[24] Ogata H, Oshio T, Ishibashi H, Yagi M. Heterotopic pancreas in children: review of the literature and report of 12 cases. Pediatr Sug Int 2008; 24: 271-175.
[25] Armstrong CP, King PM, Dixon JM, Macleod IB. The clinical significance of heterotopic pancreas in the gastrointestinal tract. Br J Surg 1981; 68: 384-387.
[26] Kazez A, Ozel SK, Kocakoc E, Kiris A. Double intussusception in a child: the triple-circle sign. J Ultrasound Med 2004; 23: 1659-1661.
[27] Scholz S, Loff S, Wirth H. Double ileoileal intussusception caused by a giant polypoid mass of heterotopic pancreas in a child. Eur J Pediatr 2000; 159: 861-862.
[28] Christodoulidis G, Zacharoulis D, Barbanis S, Katsogridakis E, Hatzitheofilou K. Heterotopic pancreas in the stomach: a case report and literature review. World J Gastroenterol 2007; 13: 6098-6100.
[29] Eisenberger CF, Gocht A, Knoefel WT, Busch CB, Peiper M, Kutup A, Yekebas EF, Hosch SB, Lambrecht W, Izbicki JR. Heterotopic panceas-clinical presentattion and pathology with review of the literature. Hepatogastroenterology 2004; 51: 854-858.
[30] Kinoshita H, Yamaguchi S, Shimizu A, Sakata Y, Arii K, Mori K, Nasu T. Adenocarcinoma arising from heterotopic pancreas in the duodenum. Int Surg 2012; 97: 351-355.
[31] Guillou L, Nordback P, Gerber C, Schneider R. Ductal adenocarcinoma arising in a heterotopic pancreas situated in a hiatal hernia. Arch Pathol Lab Med 1994; 118: 568-571.
[32] Kim JL. Disease of Digestive System. In: Kim WH, editor. Gastric polyp. Stuttgart: Thieme; 2000. pp. 209-210.
[33] Hazzan D, Peer G, Shiloni E. Symptomatic heterotopic pancreas of stomach. Isr Med Assoc J 2002; 4: 388-389.
[34] Matsushita M, Hajiro K, Okazaki K, Takakuwa H. Gastric aberrant pancreas: EUS analysis in comparison with the histology. Gastrointest Endosc 1999; 49: 493-497.
[35] Ryu DY, Kim GH, Park do Y, Lee BE, Cheong JH, Kim DU, Woo HY, Heo J, Song GA. Endoscopic removal of gastric ectopic pancreas: an initial

experience with endoscopic submucosal dissection. World J Gastroenterol 2010; 16: 4589-4593.
[36] Pessaux P, Lada P, Etienne S, Tuech JJ, Lermite E, Brehant O, Triau S, Arnaud JP. Duodenopancreatectomy for cystic dystrophy in heterotopic pancreas of the duodenal wall. Gastroenterol Clin Biol 2006; 30: 24-28.
[37] Lee TH, Wang HP, Lin JT. Application of endoscopic mucosal resection for diagnosis of aberrant pancreas. Gastroenterol J Taiwan 2004; 21: 215-215.
[38] Tolentino LF, Lee H, Maung T, Stabile BE, Li K, French SW. Islet cell tumor arising from a heterotopic pancreas in the duodenal wall with ulceration. Exp Mol Pathol 2004; 76: 51-56.
[39] Kobara H, Mori H, Fujihara S, Nishiyama N, Tsutsui K, Masaki T. Gastric heterotopic pancreas can be identified by endoscopic direct imaging with submucosal endoscopy. J Gastrointestin Liver Dis 2013; 22: 345-348.
[40] Cho JS, Shin KS, Kwon ST, Kim JW, Song CJ, Noh SM, Kang DY, Kim HY, Kang HK. Heterotopic pancreas in the stomach: CT findings. Radiology 2000; 217: 139-144.
[41] Neu B, Ell C, May A, Schmid E, Riemann JF, Hagenmüller F, Keuchel M, Soehendra N,Seitz U, Meining A, Rösch T. Capsule endoscopy versus standard tests in influencing management of obscure digestive bleeding: results from a German multicenter trial. Am J Gastroenterol 2005; 100: 1736-1742.
[42] Okuhata Y, Maebayashi T, Furuhashi S, Abe K, Takahashi M, Kanamori N, Inoue K, Takayama T. Characteristics of ectopic pancreas in dynamic gadolinium-enhanced MRI. Abdom Imaging 2010; 35: 85-87.
[43] Jang KM, Kim SH, Park HJ, Lim S, Kang TW, Lee SJ, Choi D. Ectopic pancreas in upper gastrointestinal tract: MRI findings with emphasis on differentiation from submucosal tumorActa Radiologica 2013; 54: 1107-1116.
[44] Aisheng Dong A, Wang Y, Dong TH, Zuo CJ. Increased FDG Uptake of Heterotopic Pancreatitis in the Stomach. Clin Nucl Med 2013; 38: e438-440.
[45] Tu CY, Shao CX, Zhu JD, Xiang YQ, Liu L, Liang TB. The diagnosis and treatment of heteroptic panceas: reports of 30 cases. Zhong Huang Gan Dan Wai Ke Zha Zhi 2010; 16: 220-221.