

Original Article

Intra-operative cholangiography for donor gallbladder-sparing left lateral hepatic lobectomy in pediatric living donor liver transplantation

Wei Gao^{1,2,4}, Nan Ma^{2,3,4}, Chong Dong^{2,3,4}, Chao Sun^{2,3,4}, Jisan Sun^{2,3,4}, Shanni Li^{2,3,4}, Dahong Teng^{2,3,4}, Zhongyang Shen^{2,3,4}

¹Department of Transplant Surgery, Tianjin First Center Hospital Clinic Institute, Tianjin Medical University, China;

²Department of Transplant Surgery, Tianjin First Center Hospital, China; ³Key Laboratory of Organ Transplant of Tianjin, China; ⁴Tianjin Clinical Research Center for Organ Transplantation, China

Received March 16, 2016; Accepted April 16, 2017; Epub May 15, 2017; Published May 30, 2017

Abstract: Objective: To explore the feasibility of intra-operative cholangiography via the division line of the IV segment bile duct in gallbladder-sparing left lateral hepatic lobectomy for pediatric living-donor liver transplantation. Methods: To perform the gallbladder-sparing left lateral hepatic lobectomy in pediatric living-donor liver transplantation, the liver parenchyma was dissected in the right of falciform ligament, the relative thick IV segment bile duct was dissected and cut off, and the real-time cholangiography was performed through intubation via the proximal bile duct division line. From April 2012 to December 2013, 52 cases of donor were implemented left lateral hepatic lobectomy with this method. According to the result of cholangiography, the type of bile duct and bile duct division line were determined to observe the changes of the donor maximum gallbladder emptying rate. Results: 52 cases of donor intraoperative cholangiography images were clear, with no operation complications, and the mean postoperative hospital stay was 7 days. The maximum gallbladder emptying rate of preoperative and postoperative 1, 3, 6 months were respectively 81.3%, 81.6%, 75.9% and 79.2%. Conclusion: By the intraoperative cholangiography through the division line of the IV segment bile duct, we can obtain clear image, which may replace the angiography via the cystic gall duct to perform living-donor gallbladder-sparing left lateral hepatic lobectomy.

Keywords: Liver transplantation, living-donor, cholangiography, gallbladder sparing

Introduction

Due to the intrahepatic bile duct has many variations [1], it is in need of performing intraoperative cholangiography in living donor liver transplantation operation, to accurately determine the division line of bile duct, so as to ensure the donor safety, and reduce the complications of donor bile duct [2-4], which also be conducive to reduce the difficulty of recipient operation. Magnetic resonance cholangiopancreatography can be used to evaluate the donor bile duct anatomy before operation [5], but can't be used for the positioning of division line of bile duct. Researches have shown that intraoperative cholangiography may not affect the postoperative recovery of donor liver function [6], so real-time intraoperative cholangiography is necessary for living donor liver transplantation op-

eration. The general cholangiography method is to perform the real-time intraoperative cholangiography through bile duct intubation after the resection of gallbladder [7]. However, in recent years, along with the progress and development of medical technology, it is found out that the gallbladder has complex and extremely important function, which is indispensable and irreplaceable, and there are a large number of clinical reports about various side effects after cholecystectomy, such as indigestion reflux gastritis, diarrhea, decreased immune function, and mental disorders [8-10]. It is unknown whether the gallbladder sparing is suitable for living-donor liver transplantation. We have tried to perform gallbladder-sparing left lateral hepatic lobectomy and use intra-operative cholangiography via the division line of the IV segment bile duct in instead of the traditional




Figure 1. Diagram of cholangiography via the IV bile duct division line.

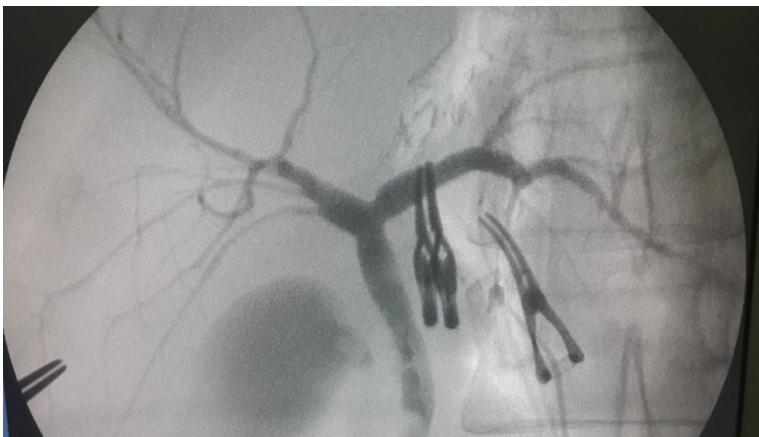


Figure 2. Intraoperative cholangiography images.

method. The objective of this study is to explore the feasibility of this method, and to observe the postoperative donor gallbladder function.

Subjects and methods

Subjects

From April 2012 to December 2013, our hospital had a total of 62 children living-donor left lateral hepatic lobectomy with biliary atresia, including 52 cases of donor with gallbladder sparing. Of the 52 cases of donors there was 14 cases males, 38 cases females, with the average age of 32 years old.

Intraoperative real-time cholangiography

To precise dissect the bile duct, we dissected the IV segment bile duct after split of the liver

parenchyma, and inserted the catheter from the proximal IV segment bile duct (**Figure 1**) to perform the intraoperative real-time cholangiography with C arm, which could obtain clear image (**Figure 2**), to determine the type of bile duct and the precise division line of the bile duct. Type of bile duct was classified with Nakamura biliary classification system [11].

This study was conducted in accordance with the declaration of Helsinki. This study was conducted with approval from the Ethics Committee of Tianjin Medical University. Written informed consent was obtained from all participants.

Operation procedure

Taking epigastric median incision with the upper end to the xiphoid, length 10-12 cm, adjacent to the first hepatic portal, the left hepatic artery and portal vein left branch was isolated, to explore whether there was variant left hepatic artery in the hepatogastric ligament, and if there was no variant left hepatic artery, the hepatogastric ligament wasn't dissected. The liver parenchyma was dissected with cut ultrasound aspiration (CUSA) in 0.5 cm right to the falcoform ligament, isolating the thicker IV segment of Glisson branches, undergoing distal ligation or suture and cut off the proximal, suturing the division line of the IV segment portal vein and hepatic artery, isolating the IV bile duct division line, inserting the angiography catheter, clamping the lower end of the common bile duct with the artery clamp, and performing the intraoperative real-time cholangiography through the C arm to determine the position of bile duct division line. The liver parenchyma was continued to be dissected, not isolating the surrounding tissue of the bile duct, the bile duct and its surrounding tissue was underwent dissection at predetermined position, and if a predetermined

Cholangiography for donor hepatectomy in pediatric LDLT

Table 1. Type of the donor bile duct

Anatomic classification	Cases (%)	The number of bile duct opening in the liver division line			The number of donor-recipient anastomosis stoma	
		1	2	3	1	2
Type I, II, III	45 (86.5)	45	0	0	45	0
Type IV	5 (9.6)	5	0	0	5	0
Type V	2 (3.8)	0	2	0	0	2
Total	52 (100)	50	2	0	50	2

Table 2. Evaluation of gallbladder contraction function before and after operation

Time of follow up	The mean maximum gallbladder emptying rate (%) \pm SD?	P value
Preoperation	81.3 \pm 9.7	
1 month after operation	81.6 \pm 7.9	P>0.01
3 months after operation	75.9 \pm 12.4	
6 months after operation	79.2 \pm 12.7	

bile duct division line is difficult to be determined, it should be performed the cholangiography again to confirm. The left hepatic artery, portal vein and left hepatic vein was in turn cut off for the completion of left lateral lobe hepatic lobectomy.

Postoperative treatment and observation parameters

Donors were transferred to the ICU after operation, and then transferred to a general ward in the next day, which were given routine antibiotics to prevent infection in postoperative 24 hours. The donors were drawn blood to test the blood routine, blood coagulation function and liver function in the postoperative days 1, 3, 7. The patients were performed ultrasound to measure the gallbladder contraction rate to evaluate the gallbladder contraction function at the preoperative and postoperative 1, 3, 6 months. The subjects were performed B-ultrasound measurement of fasting gallbladder length, width and maximum transverse diameter, which were repeated measurement at 30 minutes, 60 minutes, 90 minutes after eating fat meal, and the rate of gallbladder emptying (%) = (1-product of minimal three postprandial sizes/product of three fasting sizes)*100%.

Statistical methods

Comparison of preoperative and postoperative gallbladder contraction function was used the

variance analysis of multiple samples, and P<0.05 was taken as significant differences.

Results

The donor operation and postoperative basic situation: the operation process of 52 cases donors were successful, with the average operation time of 325 minutes (260-400 minutes); the average time of cholangiography was 18 minutes (8-31 minutes); the average graft weight was 198 \pm 50 g. The donor had no surgical complications, such as postoperative bile leakage, bile duct stenosis, with the average postoperative hospitalization time of 7 days.

Classification of bile duct

52 cases were performed the intraoperative real-time cholangiography, and the determined type of bile duct was shown in **Table 1**, in which 2 cases of donors had 2 bile duct openings after dissection of the bile duct, and the other donors had 1 bile duct opening.

Maximum rate of gallbladder emptying

The maximum gallbladder emptying rate of 52 cases donors measured by ultrasound in preoperative and postoperative in 1, 3, 6 months were respectively 81.3%, 81.6%, 75.9% and 79.2%, as shown in **Table 2**, and there was no significant difference between the preoperation and postoperation (P>0.01).

Discussion

Living-donor liver is an important source of liver transplantation, especially in pediatric liver transplantation, and it is mainly the left lateral lobe for living-donor liver transplantation. The premise for living donor transplantation is oper-

ation safety in absolute assurance, which also should fully consider the recipient operation risk. However, although the surgical techniques continue to improve, preoperative assessment is more and more accurate, and postoperative management is quite mature, it is still not possible to completely avoid the donor complications [12], and the postoperative complication of left lobe graft can reach 18.8% [13]. Bile duct anatomic variations is the main reason for the high incidence of bile duct complications, therefore, detailed preoperative evaluation of variant anatomy, and not excessive dissection of the surrounding tissue of the bile duct for protection of peribiliary blood supply are the keys to reduce the complications of bile duct. Application of real-time intraoperative cholangiography can accurately determine the precise division line of the bile duct [3], and reduce the incidence of postoperative bile duct complications of donors and recipients.

As reported in the literature, with the use of real time intraoperative cholangiography and corresponding improved surgical techniques, the donor bile duct complication rate decreased from 6.4% to 1.8%, bile duct complication rate of the recipients decreased from 25.9% to 10.5% [14]. According to the Nakamura bile duct classification [11], type 1, 2, 3 bile duct variations may not influence the division of bile duct for the left lateral lobe hepatic lobectomy, but type 4 and 5 bile duct exist multi-branches bile duct, in which the type 4 bile duct poses higher requirement for the position of bile duct division line. There were 5 cases of type 4 bile duct in this group, under the precise guidance of intraoperative cholangiography, we can undergo the single branch division to reduce the operation difficulty and risk in the premise to ensure the safety of donors. For the type 1, 2, 3 of bile duct, because of clearly intraoperative angiography, we can distinguish the caudate lobe and four segments bile duct branches in the operation to pick out the proper position of bile duct division line, so as to achieve the single branch division, to reduce the operation difficulty.

The traditional approach of intraoperative cholangiography is to perform cholangiography through cystic duct, but this method must perform cholecystectomy. Whether the healthy people will or not lead to specific abdominal

symptoms after cholecystectomy are not yet clear. 27% patients with cholelithiasis who performed cholecystectomy will have clinical symptoms [9], such as abdominal pain, diarrhea, and nausea etc. It has been reported that due to intraoperative cholecystectomy, 31% (26/84) donors are postoperative intolerance to fatty meal, and there is nausea, vomiting, abdominal distension, diarrhea and other symptoms [10]. Another study showed that 11% living-donor liver donors may have postoperative diarrhea [15], and which may be related to the resection of gallbladder.

In view of the above complications, we began to perform gallbladder-sparing left lateral hepatic lobectomy in April 2012. As for the IV bile duct of liver must be cut off in left lateral lobe hepatic lobectomy, we chose the cholangiography via the IV bile duct division line, which retained the gallbladder, and avoided blind division of bile duct. 52 cases donors of this group were performed cholangiography through this way, which had received satisfactory effect.

Gallbladder contraction and emptying function is regulated by neural and humoral factors. It is not clear that whether the gallbladder function will be affected after the gallbladder-sparing left lobe hepatic lobectomy. Fan [16] believes that, due to the dominant gallbladder nerve was cut off, it may likely develop the secondary gallstone formation, so that the retention of the gallbladder may lost value. For the preservation of gallbladder function, we took the following measures in the operation: (1) without division of the hepametogastric ligament, vagus nerve stimulation can promote gallbladder contraction and emptying, while the vagal hepatic branches run in the hepatogastric ligament; (2) when we dissected the first hepatic portal, we tried to manipulate close to liver parenchyma, only isolated the left hepatoduodenal ligament, and just dissected the left hepatic artery and portal vein. Through the above method, we tried to preserve the gallbladder nerve as far as possible. Donors of this group were evaluated of the gallbladder contraction function through the ultrasound, the maximum gallbladder emptying rate of preoperation, and postoperative 1, 3, 6 months were respectively 81.3%, 81.6%, 75.9% and 79.2%, compared with the preoperative, gallbladder contraction function did not decrease, but the follow-up time was short, and

long term postoperative gallbladder function remained to be further observed.

The patient's quality of life may be directly affected after cholecystectomy, and the side effect should be attached great importance to the doctor. Intraoperative cholangiography through intubation via the IV bile duct division line is technically feasible, which can get clear cholangiography image, and this method can replace the traditional method of cholangiography through cystic duct, and provide technical support for living-donor gallbladder-sparing left lateral hepatic lobectomy. How the gallbladder function after operation of living-donor gallbladder-sparing left lateral hepatic lobectomy will be, and whether there is risk of secondary gallstones, still need further observation.

Acknowledgements

This work was supported by National Key Clinical Specialty Construction Project of Organ Transplantation Department (Grant No. 2013-544); Tianjin health industry key research projects of Tianjin Health Bureau (2014KG129; 16KG107); Tianjin Science and Technology Project (12ZCZDSY02600).

Disclosure of conflict of interest

None.

Address correspondence to: Zhongyang Shen, Department of Transplant Surgery, Tianjin First Center Hospital Clinic Institute, Tianjin Medical University, China; Department of Transplant Surgery, Tianjin First Center Hospital, No.24, Fu-Kang Road, Nankai District, Tianjin 300192, China. Tel: +86138030-19898; E-mail: szy97188@126.com

References

- [1] Delić J, Savković A, Isaković E, Marković S, Bajtarević A, Denjalić A. Intrahepatic transposition of bile ducts. *ISRN Surg* 2012; 2012: 283527.
- [2] Jeng KS, Huang CC, Lin CK, Lin CC, Chen KH, Chu SH. Repeated intraoperative cholangiography is helpful for donor safety in the procurement of right liver graft with supraportal right bile duct variants in living-donor liver transplantation. *Transplant Proc* 2014; 46: 686-688.
- [3] Ochiai T, Ikoma H, Inoue K, Murayama Y, Komatsu S, Shiozaki A, Kuriu Y, Nakanishi M, Ichikawa D, Fujiwara H, Okamoto K, Kokuba Y, Sonoyama T, Otsuji E. Intraoperative real-time cholangiography and C-tube drainage in donor hepatectomy reduce biliary tract complications. *J Gastrointest Surg* 2011; 15: 2159-2164.
- [4] Takatsuki M, Eguchi S, Yamanouchi K, Hidaka M, Soyama A, Kanematsu T. Technical refinements of bile duct division in living donor liver surgery. *J Hepatobiliary Pancreat* 2011; 18: 170-175.
- [5] Uysal F, Obuz F, Uçar A, Seçil M, Igci E, Dicle O. Anatomic variations of the intrahepatic bile ducts: analysis of magnetic resonance cholangiopancreatography in 1011 consecutive patients. *Digestion* 2014; 89: 194-200.
- [6] Gao F, Xu X, Zhu YB, Wei Q, Zhou B, Shen XY, Ling Q, Xie HY, Wu J, Wang WL, Zheng SS. Impact of intra-operative cholangiography and parenchymal resection to donor liver function in living donor liver transplantation. *Hepatobiliary Pancreat Dis Int* 2014; 13: 259-263.
- [7] Li C, Li C, Wen T, Yan L, Li B, Zeng Y, Wang W, Yang J, Xu M, Wei Y. Biliary variations and biliary complications in living donor liver transplantation. *Hepatogastroenterology* 2012; 59: 1526-1528.
- [8] Lamberts MP, Lugtenberg M, Rovers MM, Roukema AJ, Drenth JP, Westert GP, van Laarhoven CJ. Persistent and de novo symptoms after cholecystectomy: a systematic review of cholecystectomy effectiveness. *Surg Endosc* 2013; 27: 709-718.
- [9] Vetrhus M, Berhane T, Søreide O, Søndena K. Pain persists in many patients five years after removal of the gallbladder. Observations from two randomized controlled trials of symptomatic, noncomplicated gallstone disease and acute cholecystitis. *J Gastrointest Surg* 2005; 9: 826-831.
- [10] Sotiropoulos GC, Radtke A, Molmenti EP, Schroeder T, Baba HA, Frilling A, Broelsch CE, Malagó M. Long-term follow-up after right hepatectomy for adult living donation and attitudes toward the procedure. *Ann Surg* 2011; 254: 694-700.
- [11] Nakamura T, Tanaka K, Kiuchi T, Kasahara M, Oike F, Ueda M, Kaihara S, Egawa H, Ozden I, Kobayashi N, Uemoto S. Anatomical variations and surgical strategies in right lobe living donor liver transplantation: lesions from 120 cases. *Transplantation* 2002; 73: 1896-1903.
- [12] Hwang S, Lee SG, Lee YJ, Sung KB, Park KM, Kim KH, Ahn CS, Moon DB, Hwang GS, Kim KM, Ha TY, Kim DS, Jung JP, Song GW. Lessons learned from 1,000 living donor liver transplantations in a single center: how to make living donations safe. *Liver Transpl* 2006; 12: 920-927.
- [13] Iida T, Ogura Y, Oike F, Hatano E, Kaido T, Egawa H, Takada Y, Uemoto S. Surgery-related

Cholangiography for donor hepatectomy in pediatric LDLT

- morbidity in living donors for liver transplantation. *Transplantation* 2010; 89: 1276-1282.
- [14] Taketomi A, Morita K, Toshima T, Takeishi K, Kayashima H, Ninomiya M, Uchiyama H, Soejima Y, Shirabe K, Maehara Y. Living donor hepatectomies with procedures to prevent biliary complications. *J Am Coll Surg* 2010; 211: 456-464.
- [15] Renz JF, Roberts JP. Long-term complications of living donor liver transplantation. *Liver Transpl* 2000; 6: S73-76.
- [16] Fan ST. Segment II/III graft. In: living donor liver transplantation. Hongkong: takungpao publishing Co.; 2008. pp. 27-46.