Int J Clin Exp Med 2017;10(5):8295-8300
www.ijcem.com /ISSN:1940-5901/IJCEM0036381

Case Report

Aggressive vertebral hemangioma treated by TES and posterior multisegmental stabilization: a case report

Cheng-Long Tan, Bin Liu, Feng Han, Feng Zhou, Jun Lin, Hui-Lin Yang

Department of Orthopedic Surgery, The First Affiliated Hospital of Soochow University, Suzhou 215006, China

Received July 21, 2016; Accepted October 31, 2016; Epub May 15, 2017; Published May 30, 2017

Abstract: Vertebral hemangiomas are usually considered as benign tumor mostly characterized by insidious and asymptomatic. A fraction of them referred to symptomatic vertebral hemangiomas (SVHs) can lead to compressive neurological symptoms. We present a case of a 49-year-old male patient diagnosed with thoracic vertebral hemangioma who suffered from severe neurological defects. The atypical radiological appearances of this patient increased the difficulty in making an accurate diagnosis. To minimize the risk of intraoperative nerve injury, total *en bloc* spondylectomy via anterior-lateral transthoracic approach combined with posterior multisegmental fixation was performed. The clinical results proved to be satisfactory and pathologic biopsy confirmed the final diagnosis of cavernous hemangioma.

Keywords: Vertebral hemangioma, radiological appearance, treatment protocols, transthoracic approach

Introduction

Vertebral hemangiomas are usually discovered incidentally due to its asymptomatic peculiarity, while only a small share of them which were known as symptomatic vertebral hemangiomas (SVHs) ultimately leads to compressive neurological symptoms. Since the symptoms and radiologic appearance of SVHs are somewhat similar to other diseases, it is difficult to make an accurate tentative diagnosis. The differential diagnosis includes aneurysmal bone cysts, solitary myeloma, metastatic tumors and Paget disease. An aggressive vertebral hemangioma with atypical radiological appearances and extraosseous extension treated by spondylectomy was presented in this case report.

Case report

A 49-year-old male presented with slightly progressive weakness of bilateral lower extremities over the previous 6 weeks, but he paid little attention to it. About 3 weeks ago, the lower extremity weakness accompanied by paresthesia progressed rapidly due to a thoracic spine injury caused by a fall. The patient's neurological symptoms did not improve with conservative treatment in another hospital. Physical examination revealed hypoesthesia below the level of T7 and decreased muscle strength of bilateral lower extremities. Hyper-reflexia with bilateral patellar and ankle clonus were noted. The patient also complained of dysuria.

On admission to our hospital, X-ray demonstrated expansive and osteolytic changes at T7 level (**Figure 1**). MRI scan showed hypointensity in T1- and hyperintensity in T2-weighted images. The lesion involved the entire T7 vertebral body and extended into the spinal canal compressing the spinal cord. Additionally, the mass also involved left pedicle and transverse process of T7 (**Figure 2**). CT scan demonstrated severe destruction of the trabecular structure by homogeneous mass within the T7 vertebral body, which was not consistent with the typical characteristic "polka dot" appearance and parallel linear streaks (**Figure 2**). Bone scan showed significant radionuclide accumulation only in T7, which confirmed a primary lesion (**Figure 3**). Preoperative CT-guided biopsy failed to confirm the pathological diagnosis. Spinal angiography revealed hypervascular characteristic of the lesion, so superselective intra-arterial embolization of the feeding arteries of the

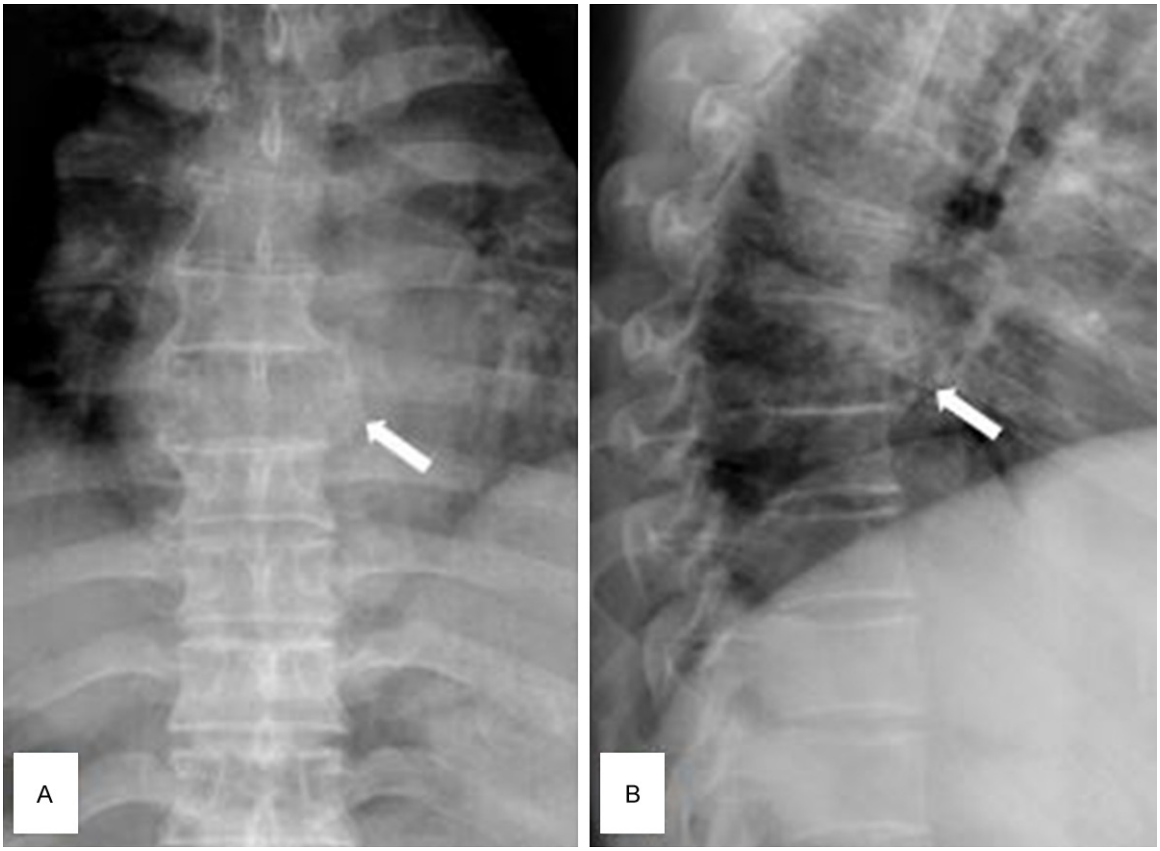

Figure 1. Roentgenogram of the thoracic spine showed expansile change in T7 (A and B) where decreased intensity (A and B) can be found compared with adjacent vertebral body.

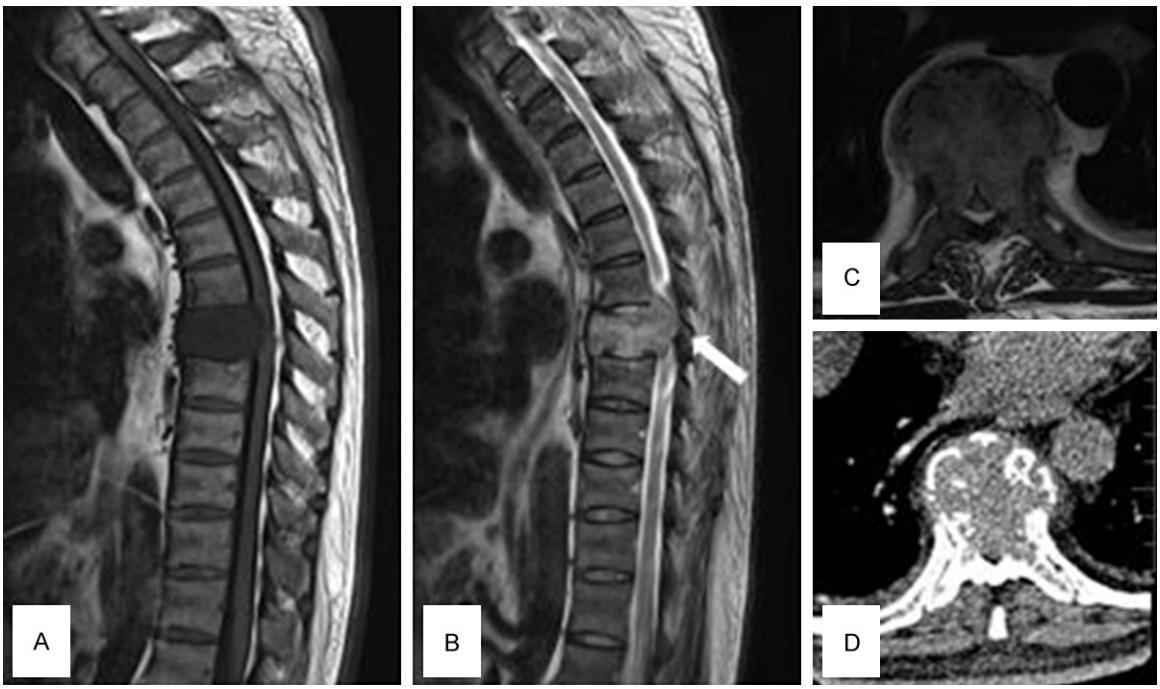

Figure 2. Preoperative sagittal MRI showing the spinal cord compression with a hypointense lesion on T1-weighted MRI (A) while hyperintense lesion on sagittal T2-weighted MRI (B). The hemangioma involved the entire T7 vertebral body, left pedicle and transverse process (C and D) causing severe spinal cord compression.

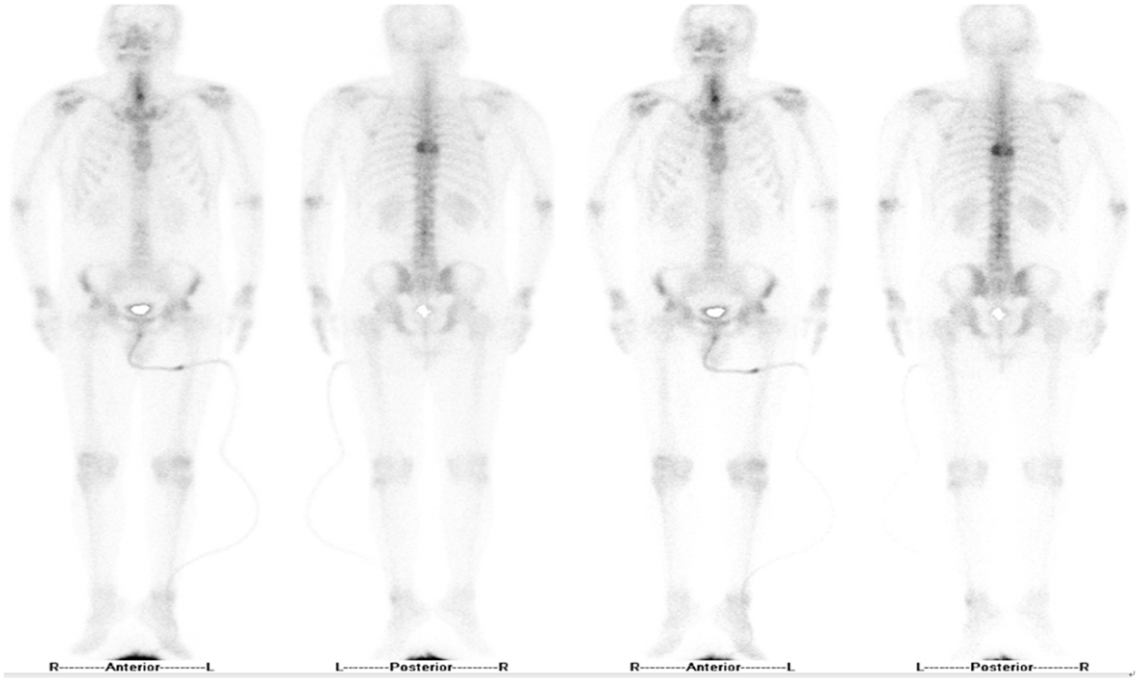

Figure 3. Bone scan showed significant radionuclide accumulation only in T7.

Figure 4. Preoperative angiogram of the hemangioma showed hypervascular lesion and the feeding arteries were subsequently embolized except the right T7 intercostal artery which was connected to the adamkiewicz artery.

spinal lesion (except the right seventh intercostals artery connected to the adamkiewicz artery) was performed one day before surgery (**Figure 4**).

As the lesion mainly intruded into the left pedicle, total spondylectomy and posterior multisegmental stabilization were performed through posterior approach combined with left-side anterolateral transthoracic approach in order to minimize the intraoperative nerve injury (**Figure 5**). We retracted the left lung by breathing machine and excised a portion of 7th rib so that the operative field can be thoroughly exposed. Postoperative pathology examination confirmed the final diagnosis of cavernous hemangioma (**Figure 6**). The neurological symptoms significantly improved after the surgery (**Table 1**).

Discussion

Vertebral hemangiomas, which are usually considered to be benign, are characterized by proliferation of blood capillary and expansion of blood sinus. They are found in approximately 10-12% of autopsies and radiographs of the spine [1-3]. Most of them are insidious in onset causing neurological defects while rarely could be rapidly progressive [4, 5].

The typical radiological appearance of VHs can be found by plain radiography, CT and MRI. On plain films, the density of lesions decreases asymmetrically leading to “corduroy cloth” appearance and “honeycomb” change [6]. CT scan could provide better diagnostic value com-

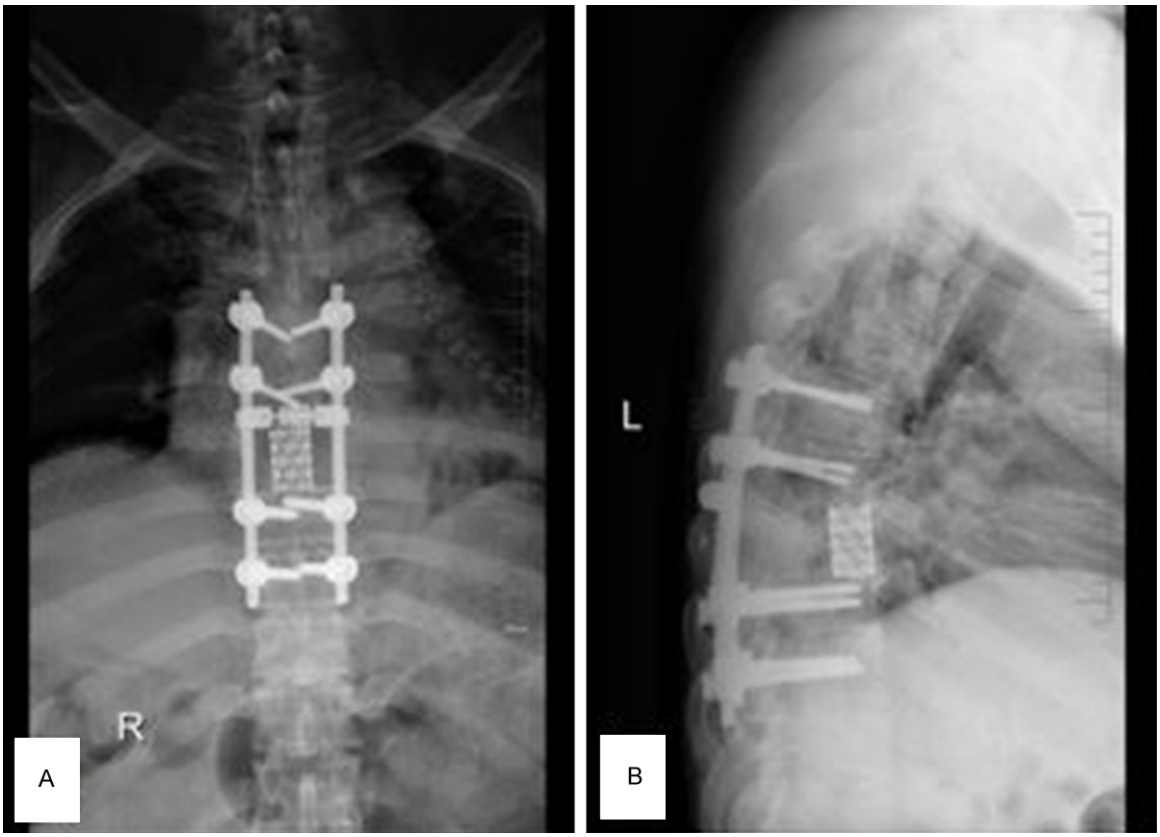

Figure 5. Total spondylectomy and posterior multisegmental stabilization were performed, and the spinal stabilization was also achieved by multi-segmental pedicle screw fixation from T5 to T9 except T7 (A and B).

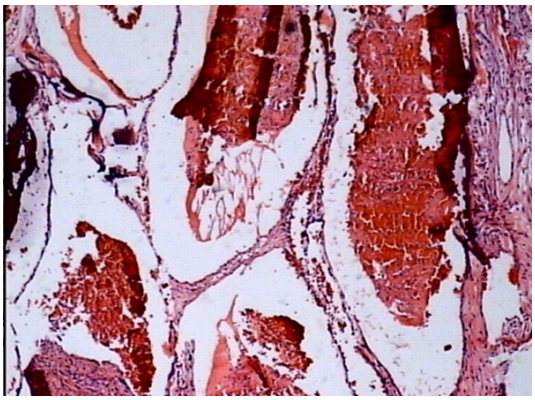

Figure 6. Postoperative pathology examination demonstrated thin-walled vessels and hyperplastic spindle cells. A cavernous hemangioma was confirmed by Haematoxylin & Eosin staining, original magnification ×100.

pared with plain radiography. It can determine the involvement of VHs and assess the spinal cord compression [4, 7]. MRI also plays a crucial role in the diagnosis of VHs for its advantage in evaluating the spinal cord compression and soft tissue involvement. T1-weighted MRI of VHs reveals hypointensity, while T2-weighted presents with hyperintensity because of hypervascular contents [4, 8, 9]. Bone scan can be utilized to detect multiple or metastatic lesions. In addition, CT-guided biopsy has a feasible diagnostic value of VHs [10]. However, sometimes it's still very difficult to make an accurate diagnosis based on radiologic examinations and repeat biopsy. In this case, we were unable to make an accurate diagnosis preoperatively without positive biopsy finding and typical radiological manifestations.

There are several treatment options for symptomatic hemangiomas without the spinal cord compression, including radiotherapy, kyphoplasty/vertebroplasty, embolization and intralesional direct ethanol injection. Radiotherapy was deemed to be an effective treatment protocol, and the therapeutic efficacy will be much better when radiation dose ≥34 Gy [11]. Kyphoplasty/Vertebroplasty can quickly relieve pain and restore vertebral height with the potential

Table 1. Summary table of symptomatic vertebral hemangiomas

Nature	Vascular malformation, rather than tumor.
Incidence	10-12%, about 3% need to be treated.
Age predilection	Most in middle age or later, more common in women.
Etiology	Undefined, require deep-going research.
Clinical symptoms	Variable, depending on lesion localization and disease progression.
Supplementary examinations	X-ray: osteolytic bony destruction, "corduroy cloth" appearance and parallel linear streaks can be found. CT: typical "polka dot" appearance on axial images, corduroy pattern on coronal and parallel linear streaks on sagittal images. MRI: evaluate soft tissue extension and spinal cord compression; hypointensity in T1- and hyperintensity in T2-weighted images.
Differential diagnosis	Aneurysmal bone cysts, Solitary myeloma, Metastatic tumors and Paget disease.
Treatment protocols	Radiation therapy, Embolization, kyphoplasty/vertebroplasty and Surgical interventions.
Prognosis	Favorable, rarely condition worsening after treatment.

complications of cement leakage [12]. Transpedicular anhydrous ethanol injection has also proved effective and workable in practice [13-15]. Arterial embolization had been suggested as a safe and effective option which can observably improve neurological function [12, 16, 17].

The surgical therapy is a preferred option in cases with the spinal cord compression and neurological symptoms [1, 17]. Anterior corpectomy and reconstruction is deemed to be suitable for patients who suffered from vertebral body involvement, but just anterior spinal cord compression [1]. While SVHs break through the back wall of the vertebra invading vertebral arch and posterior elements causing acute and progressive neurological compromise, total *en bloc* spondylectomy (TES) may be a good treatment option. In this case, as the lesion mainly intruded into the left pedicle, we performed total spondylectomy and posterior multisegmental stabilization through left-side anterolateral transthoracic approach combined with posterior approach. In addition, preoperative superselective arterial embolization was adopted to minimize intraoperative bleeding [1, 9, 17, 18].

Conclusion

Vertebral hemangiomas are usually considered to be benign. A very rare subtype of vertebral hemangiomas can be aggressive and leading to the spinal cord compression. We reported the case with aggressive vertebral hemangioma treated by TES and posterior multisegmental stabilization.

Disclosure of conflict of interest

None.

Address correspondence to: Drs. Feng Zhou and Jun Lin, Department of Orthopedic Surgery, The First Affiliated Hospital of Soochow University, 188 Shizi St, Suzhou 215006, Jiangsu Province, China. Tel: +81 13338000485; E-mail: Liw72@126.com (FZ); Tel: +81 18913165996; E-mail: jasonosfc@163.com (JL)

References

[1] Fox MW and Onofrio BM. The natural history and management of symptomatic and asymptomatic vertebral hemangiomas. J Neurosurg 1993; 78: 36-45.
[2] Lang EF Jr and Peserico L. Neurologic and surgical aspects of vertebral hemangiomas. Surg Clin North Am 1960; 40: 817-823.
[3] Laredo JD, Reizine D, Bard M and Merland JJ. Vertebral hemangiomas: radiologic evaluation. Radiology 1986; 161: 183-189.
[4] Templin CR, Stambough JB and Stambough JL. Acute spinal cord compression caused by vertebral hemangioma. Spine J 2004; 4: 595-600.
[5] Ergun T, Lakadamyali H, Lakadamyali H and Mukaddem A. Acute spinal cord compression from an extraosseous vertebral hemangioma with hemorrhagic components: a case report. J Manipulative Physiol Ther 2007; 30: 602-606.
[6] Sainani NI, Pungavkar SA, Patkar DP, Lawande MA and Naik M. Multiple hemangiomas involving the vertebral column. Acta Radiol 2005; 46: 510-513.
[7] Murphey MD, Fairbairn KJ, Parman LM, Baxter KG, Parsa MB and Smith WS. From the archives of the AFIP. Musculoskeletal angiomatous lesions: radiologic-pathologic correlation. Radiographics 1995; 15: 893-917.
[8] Castel E, Lazennec JY, Chiras J, Enkaoua E and Saillant G. Acute spinal cord compression due to intraspinal bleeding from a vertebral hemangioma: two case-reports. Eur Spine J 1999; 8: 244-248.

[9] Urrutia J, Postigo R, Larrondo R and Martin AS. Clinical and imaging findings in patients with aggressive spinal hemangioma requiring surgical treatment. J Clin Neurosci 2011; 18: 209-212.
[10] Lis E, Bilsky MH, Pisinski L, Boland P, Healey JH, O'Malley B and Krol G. Percutaneous CT-guided biopsy of osseous lesion of the spine in patients with known or suspected malignancy. AJNR Am J Neuroradiol 2004; 25: 1583-1588.
[11] Heyd R, Seegenschmiedt MH, Rades D, Winkler C, Eich HT, Bruns F, Gosheger G, Willich N, Micke O; German Cooperative Group on Radiotherapy for Benign D. Radiotherapy for symptomatic vertebral hemangiomas: results of a multicenter study and literature review. Int J Radiat Oncol Biol Phys 2010; 77: 217-225.
[12] Acosta FL Jr, Sanai N, Chi JH, Dowd CF, Chin C, Tihan T, Chou D, Weinstein PR and Ames CP. Comprehensive management of symptomatic and aggressive vertebral hemangiomas. Neurosurg Clin N Am 2008; 19: 17-29.
[13] Bas T, Aparisi F and Bas JL. Efficacy and safety of ethanol injections in 18 cases of vertebral hemangioma: a mean follow-up of 2 years. Spine (Phila Pa 1976) 2001; 26: 1577-1582.
[14] Doppman JL, Oldfield EH and Heiss JD. Symptomatic vertebral hemangiomas: treatment by means of direct intralesional injection of ethanol. Radiology 2000; 214: 341-348.
[15] Degulmadi D, Brahmajoshyula V, Mayi S and Teegala S. Two-stage surgical management of multilevel symptomatic thoracic haemangioma using ethanol and iliac crest bone graft. Asian Spine J 2014; 8: 502-505.
[16] Gabal AM. Percutaneous technique for sclerotherapy of vertebral hemangioma compressing spinal cord. Cardiovasc Intervent Radiol 2002; 25: 494-500.
[17] Acosta FL Jr, Dowd CF, Chin C, Tihan T, Ames CP and Weinstein PR. Current treatment strategies and outcomes in the management of symptomatic vertebral hemangiomas. Neurosurgery 2006; 58: 287-295; discussion 287-295.
[18] Nicola N and Lins E. Vertebral hemangioma: retrograde embolization-stabilization with methyl methacrylate. Surg Neurol 1987; 27: 481-486.