

Original Article

Bipolar hemiarthroplasty vs. total hip replacement in elderly

Fusheng Xu, Rongjun Ke, Yongfu Gu, Wei Qi

Department of Orthopedics, China People's Liberation Army 359 Hospital, No. 8, East Zhongshan Road, Zhenjiang 212000, Jiangsu, China

Received September 29, 2016; Accepted January 7, 2017; Epub May 15, 2017; Published May 30, 2017

Abstract: This study aimed to compare bipolar hemiarthroplasty (BH) vs. total hip replacement (THR) in elderly patients with neglected femoral neck fracture. Neglected femoral neck fractures in young people are treated using internal fixation, intertrochanteric valgus osteotomy, non-vascularized fibular bone graft, or vascularized bone graft, but treatment of these fractures in elderly (≥ 60 years old) has been rarely reported. Patients aged ≥ 60 years old ($n=76$) undergoing arthroplasty for neglected femoral neck fractures at the 359 Hospital of the People's Liberation Army between June 2000 and November 2009 were recruited and randomized to BH or THR. Operation time, blood loss, hospital stay, HHS score, complications, and reoperation were recorded. The primary outcome was hip joint function (HHS score). The secondary outcomes were operation time, blood loss, and complications. There were 27 males and 49 females, aged of 75.86 ± 0.73 years. Compared with BH ($n=38$), operation time ($P<0.001$) and blood loss ($P<0.001$) were significantly higher in the THR group ($n=38$). There was no difference in hip function at 1 year ($P=0.51$), but it was significantly higher in the THR group at 5 years (87.6 ± 4.0 vs. 82.8 ± 11.7 , $P=0.029$). In the THR group, one patient suffered from dislocation of hip joint and two patients from periprosthetic femoral fractures. In the BH group, three patients suffered from hip osteoarthritis and three from periprosthetic femoral fractures. Compared with BH, THR for elderly patients with neglected femoral neck fracture had better hip function and lower risk of reoperation.

Keywords: Bipolar hemiarthroplasty, total hip replacement, neglected femoral neck fracture, hip fracture

Introduction

Hip fracture is an international public health problem mainly occurring in elderly patients and resulting in a high mortality. Its annual incidence is 0.2-3.8 per 1000 people worldwide [1, 2]. With the aging population, the incidence of these fractures is steadily increasing [3, 4]. Indeed, decreased reflexes and visual impairment lead to a higher number of falls; in addition, osteoporosis is more common in the elderly [5]. Femoral neck fracture is the most common hip fracture [5]. Extracapsular hip fractures often lead to significant bleeding. Delirium affects 10-16% of patients [6]. Hip fracture is also associated with severe pain, increased risk of venous thromboembolism, avascular necrosis, and non-union [6]. The 1-year mortality after hip fracture is 8% in women and 18% in men [7].

Neglected femoral neck fractures are common in developing countries [8-10]. However, a clear definition of neglected femoral neck fracture is actually lacking. The present study used the definition proposed by Myers et al. in 1973 [11] a diagnosis delayed by ≥ 30 days is considered as neglected femoral neck fracture. The most common reason is that patients mainly adopt bed rest, splinting, and other non-medical treatments after fracture, and they visit the hospital only because of intolerable continuous bed rest, hip pain, limping, etc. In addition, non-significant symptoms after non-violent trauma may not attract attention and patients fail to receive timely diagnosis and treatment, until hip pain appears.

Surgery is the treatment of choice for hip fractures. However, the risk of perioperative and postoperative complications is high [12, 13].

Studies suggest that total hip replacement reduces residual pain and results in good hip function compared with hemiarthroplasty [14], and that total hip replacement is associated with a decreased failure rate at 10 years compared with internal fixation [15].

However, most studies on the treatment of neglected femoral neck fracture were performed in patients aged <60 years, and studies in patients aged ≥60 years are rare. Therefore, this single-center, randomized controlled study aimed to compare bipolar hemiarthroplasty and total hip replacement in patients aged ≥60 years and with neglected femoral neck fracture, hoping to provide a reference for the best treatment in elderly patients with neglected femoral neck fracture.

Material and methods

Study design

This was a single-center, open-label, randomized controlled trial comparing bipolar hemiarthroplasty and total hip replacement in patients ≥60 years old with neglected femoral neck fracture. Patients were consecutively recruited at the 359 Hospital of the People's Liberation Army between June 2000 and November 2009.

This study was performed according to the Chinese laws and regulations, and was approved by the ethics committee of the hospital. All patients signed a written informed consent.

Patients

Inclusion criteria were: 1) neglected femoral neck fracture, defined as diagnosed >30 days after injury [11], and confirmed by X-ray; 2) aged ≥60 years; 3) being able to walk without aids (crutches, walkers) before injury; and 4) able to provide an informed consent. Exclusion criteria were: 1) refusal to undergo surgery; 2) any contraindication to surgery or anesthesia; 3) chronic hip pain and imaging revealing osteoarthritis or atrophic arthritis; 4) metastatic cancer; or 5) active inflammatory disease.

Grouping

Patients were randomized using a computer-generated random number table. A statistician independent to the study prepared sequential

sealed envelopes that were opened by the surgeon the day of the surgery. There was no blinding.

Surgical approaches

All surgeries were performed by an experienced chief orthopedist specialized in hip joint surgery. They were performed using the posterolateral approach with spinal anesthesia (total hip replacement was performed with combined spinal/epidural anesthesia) [16]. All prostheses used in this study were uncemented prostheses produced by Johnson & Johnson (U.S.A.), Aesculap (Germany) and Irene (Tianjin, China). The femur was reamed to a diameter for inserting the uncemented prosthesis. For patients undergoing total hip replacement, the metal-polyethylene and ceramic-polyethylene interfaces of hip joint were used, where the acetabular bone was ground to a diameter of 1 mm smaller than the inserted prosthesis, and screws were used to enhance the fixation stability. In the anteroposterior X-ray of the hip joint, patients with an angle between the long axis of prosthetic stem and that of the femur of ≤3° underwent central fixation, while those with an angle >3° underwent varus or valgus fixation. No drainage tube was placed after surgery. Patients received 2 g intravenous of second-generation cephalosporin to prevent infection half hour before surgery and at 6 and 12 hours after surgery.

Postoperative care

The following measures were applied to prevent deep vein thrombosis: 1) patients started oral rivaroxaban tablets on the first day after surgery (10 mg, once per day), and they began functional exercises of the lower extremities on the day of the surgery including isometric muscle contraction and relaxation, abduction, and hip and knee extension not exceeding 90°. Activity intensity and frequency were determined based on individual tolerance. After X-ray verification and incision oozing disappearance, patients were guided to walk with aids with partial weight loading. Patients were informed of the risk factors for postoperative dislocation of hip joints such as excessive internal and external rotation, excessive flexion, flexion adduction, internal rotation, and other special positions. All patients aimed to be able to walk with full weight loading 6 weeks after

surgery, without any restriction in daily life 3 months after surgery.

Data collection

Demographic and clinical data such as age, affected side, medical history, etc. were recorded. Surgical data such as operation time (from skin incision to end of skin closure), hospital stay, intraoperative blood loss, postoperative length discrepancy of lower extremities, etc. were recorded. The Harris hip score (HHS) was determined before and after surgery, and during follow-up.

In the first X-ray examination after surgery, the initial locations of the femoral stem and acetabular prosthesis and the matching of femoral stem and medullary cavity were assessed according to the method proposed by Teloken et al. [17]. The distance between the apex of the lesser trochanter and medial apex of the femoral stem was measured using the method by Phillips et al. [18].

The matching between femoral stem and medullary cavity was determined by measuring the ratio of the width of the prosthesis over the width of medullary cavity using the method by Kim et al. [19], where a satisfactory matching referred to a ratio >80% in the anteroposterior film and >70% in the lateral X-ray. Position of the acetabular prosthesis was determined according to the method by Hirakawa et al. [20], where the horizontal and vertical distances as well as the abduction angle of the acetabular prosthesis were recorded.

Follow-up

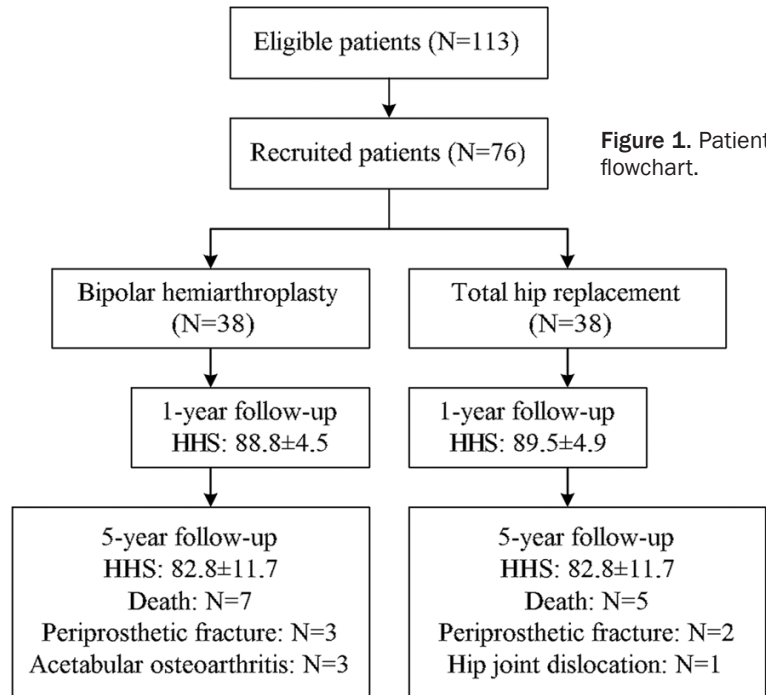
Patients underwent annual follow-up. HHS, complications, reoperation, and death were recorded. Anteroposterior pelvic and lateral hip joint X-rays were observed by two experienced physicians, and correlated to the HHS. Complications were defined as any medical event arising from the surgery including hip osteoarthritis, dislocation of hip joint, intraoperative and postoperative periprosthetic fracture, prosthetic loosening, deep vein thrombosis, severe prosthetic deformation or even failure, superficial or deep infections, etc. Non-surgery-related complications such as urinary tract infection, lung infection, and cerebral infarction were not considered. Superficial infection in the hip area

was defined as “no evidence showing that the infection extended to the periprosthetic area”, while deep infection in the hip area was defined as “periprosthetic infection”. Reoperation included reoperation due to acetabular osteoarthritis, loosening, infection, dislocation, and postoperative periprosthetic fracture. Follow-up ended with death or reoperation of hip joints.

Follow-up X-rays were compared with the initial X-rays, and the changes in the locations of femoral stem and acetabular prosthesis, heterotopic ossification, acetabular liner wear as well as wear and osteolysis of acetabular bone were recorded. The stability of the femoral prosthesis was determined using the Engh criteria [21]: bone ingrowths and no prosthesis subsidence (stem subsidence referred to a reduction of 5 mm of the distance between the apex of the lesser trochanter and medial apex of femoral stem) without or less hardening lines in prosthetic area. Stable fiber fixation referred to the presence of ≤ 1 mm periprosthetic radiolucent lines that were continuous and parallel to the prosthesis while there was no progressive displacement. Instable prosthesis meant that there was conclusive evidence showing progressive prosthetic subsidence, or presence of new varus and valgus, or appearance of separation of porous surface or prosthetic fracture.

The stability of the acetabular prosthesis was determined using the Kawamura criteria [22]. The stable fiber fixation referred to no displacement of the acetabular cup, and presence of <1 mm radiolucent lines. Possible loosening referred to no loosening of acetabular cup, but presence of discontinuous >2 mm progressive radiolucent lines. Clear loosening referred to displacement of acetabular cup or presence of continuous >2 mm radiolucent lines or fracture of screws.

Polyethylene linear wear was measured using a method proposed by Martell et al. [23]. The vector displacement of the femoral head relative to the acetabular center was measured to determine the size and direction of the articular surface wear. The osteolysis referred to the presence of progressively aggravated radiolucent lines or cavitating region in the prosthesis-bone interface, and the Gruen femoral partition and Delee acetabular partition were assessed.



Results

Characteristics of the patients

Figure 1 presents the study flowchart. A total of 76 patients were enrolled in the study between June 2000 and November 2009, 38 in each group. **Table 1** presents the characteristics of the patients. There were 27 males and 49 females, with a mean age of 75.9 ± 0.7 years, and including 34 cases of left hip and 42 cases of right hip. There were three main reasons for neglected femoral neck fracture: 13 cases were undiagnosed as femoral neck fracture after injury, 48 cases refused immediate surgical treatment, and 15 cases

failed to visit the hospital timely after injury. The mean time of neglected femoral neck fracture (from injury to surgery) was 46.0 ± 10.6 (range 30-74) days. All patients had various degrees of weight-loading walking before surgery. There was no difference between the two groups for the characteristics of the patients.

Table 2 presents the surgical data. The mean shortening of the affected limb was 1.8 (range 0.8-3.2) cm. There was no difference in postoperative hospital stay. Blood loss was significantly greater in the total hip replacement group (247 ± 109 vs. 148 ± 90 ml, $P < 0.001$), and the operation time was longer (107 ± 18 vs. 72 ± 18 min, $P < 0.001$). (Data were shown in [Supplementary Table 1](#): original data).

HHS score

There was no difference in the mean HHS before surgery and at 1 year ($P = 0.91$ and $P = 0.51$, respectively). The HHS was significantly higher, and therefore better, at 5 years in the total hip replacement group (87.6 ± 4.0 vs. 82.8 ± 11.7 , $P = 0.029$) (**Table 3**).

Complications

During follow-up, 12 patients died, seven in the bipolar hemiarthroplasty group and five in the total hip replacement group. No patients under-

Heterotopic ossification was scored using Brooker grading [24]. Grade I: bone island in soft-tissues. Grade II: osteophyte in proximal pelvis or femur, with a spacing of ≥ 1 cm. Grade III: osteophyte in proximal pelvis or femur, with a spacing of < 1 cm. Grade IV: ankylosed hip.

Patients were visited at home if they were unwilling to travel to the hospital. Meanwhile, information was also collected in case of death during follow-up to determine the exact cause of death and its relation with hip surgery.

Outcomes

The primary outcome was hip joint function according to the HHS. The secondary outcomes were operation time, blood loss, and complications.

Statistical analysis

Data were managed and analyzed using SPSS 17.0 (IBM, Armonk, NY, USA). Continuous data are presented using means \pm standard deviation and were analyzed using the Student t-test for intergroup differences and using the paired t-test for intragroup testing. Categorical variables are present as frequencies and were analyzed using the Fisher's exact test. Two-sided P -values < 0.05 were considered significant.

Table 1. Characteristics of the patients

	Bipolar hemiarthroplasty (N=38)	Total hip replacement (N=38)	t value or chi-square	P
Mean age (years) (range)	75.45±6.52 (60-84)	76.16±6.53 (60-86)	0.475	0.683
Gender (%), M/F	11/27 (29%)	16/22 (42%)		0.231
Affected hip (%) left/right	14/24 (37%)	20/18 (53%)		0.166
Average shortening of the affected limb (cm) (range)	1.39±0.91 (0-2.8)	1.47±0.85 (0-3)	0.377	0.707
Time from injury to surgery (days)	45.95±10.17 (31-67)	46.05±11.17 (30-74)	0.613	0.966
Smoking (yes)	9 (24%)	11 (29%)	0.271	0.602
Drinking (yes)	10 (26%)	16 (42%)	2.1	0.147
Reason for delayed treatment			0.84	0.656
Did not visit hospital at injury	5 (13%)	8 (21%)		
Delayed diagnosis	25 (66%)	23 (61%)		
Refused surgical treatment	8 (21%)	7 (18%)		
Comorbidities*, n			2.213	0.778
0	4 (11%)	6 (16%)		
1	12 (32%)	14 (37%)		
2	17 (45%)	16 (42%)		
3	4 (11%)	2 (5%)		
>3	1 (3%)	0		

*Comorbidities include diabetes, hypertension, coronary heart disease, cerebral infarction, chronic bronchitis.

Table 2. Surgical data

	Bipolar hemiarthroplasty (N=38)	Total hip replacement (N=38)	t value	P
Intraoperative blood loss (ml) (range)	147.63±89.73 (50-300)	247.11±109.02 (150-500)	4.343	<0.001
Operation time (min) (range)	71.84±18.32 (45-100)	107.11±17.84 (80-140)	8.499	<0.001
Hospital stay (day) (range)	10.42±1.75 (7-14)	11.16±2.06 (8-16)	1.68	0.097
Postoperative length discrepancy in lower extremities (cm) (range)	0.78±0.44 (0-1.5)	0.85±0.48 (0-1.8)	0.729	0.469

Table 3. Harris hip score before and after surgery

HHS	Bipolar hemiarthroplasty (N=38)	Total hip replacement (N=38)	t value	P
Before surgery	27.63±7.71	27.74±7.51	0.063	0.910
1 year after surgery	88.79±4.51	89.50±4.89	0.658	0.512
5 years after surgery	82.81±11.74	87.64±3.99	2.144	0.029

HHS: Harris hip score.

went revision surgery. At the last follow-up, nine patients (11.8%) suffered from hip complications, 6 cases in the bipolar hemiarthroplasty group and 3 cases in the total hip replacement group, and eight underwent reoperation. There was no case of loosening or infection.

In the bipolar hemiarthroplasty group, three patients suffered from periprosthetic femoral fracture due to falling, at 5 weeks, 14 months, and 26 months after surgery, respectively. All were able to walk after 12 weeks after treatment. Three cases whose time between frac-

ture and surgery (51, 62 and 67 days) was above the mean suffered from acetabular osteoarthritis at 38 months, 46 months and 52 months after hemiarthroplasty, manifested as hip pain when walking. The treatment approaches were femoral prosthesis preservation, femoral head change, and acetabular replacement, respectively.

In the total hip replacement group, three patients suffered from complications. There were two cases of periprosthetic femoral fractures, both were able to walk at 12 weeks after treatment. There was one case of recurrent dislocation of hip joint, 2-3 times annually after surgery. It was suspected to be associated with a large acetabular angle. The patient underwent acetabular revision and femoral head

Table 4. Complications

Complications	Bipolar hemiarthroplasty (N=38)	Total hip replacement (N=38)	t value or chi-square	P
Periprosthetic infection	0	0		
Prosthetic loosening	0	0		
Dislocation of hip joint	0	1		
Periprosthetic fracture	3	2		
Acetabular osteoarthritis	3	—		
All cause death*	7	5	0.400	0.529
Total number	13	8	1.650	0.199

*No deaths were related to the hip joint fracture.

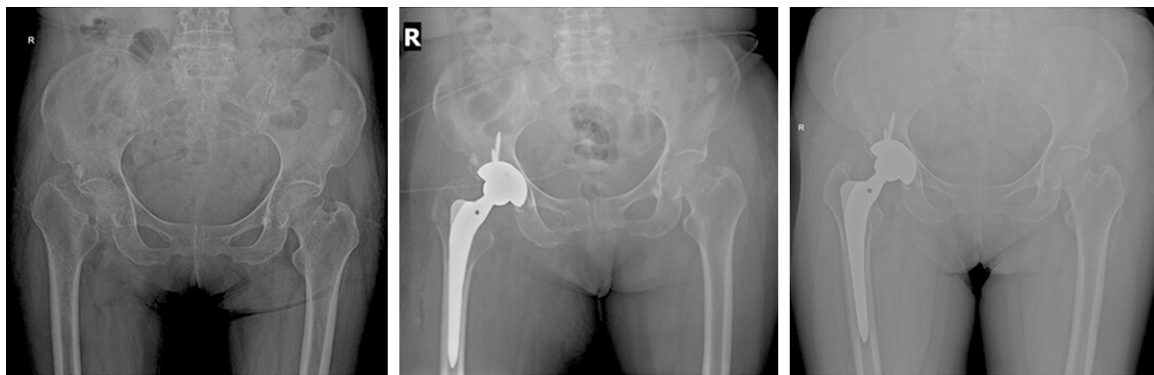


Figure 2. A typical case of total hip replacement. From left to right: before surgery, 1 year after surgery, and 6.8 years after surgery. The patient was a 70-year-old female, who fell down while walking. The patient underwent right total hip replacement.

replacement at 3 years, and did not suffer from dislocation anymore (**Table 4**).

Imaging

Among the 76 patients, 64 underwent central fixation, 11 underwent valgus fixation, and one underwent valgus fixation. The femoral prosthetic matching was satisfactory in 72 cases, and the abduction angles of the acetabular prosthesis were satisfactory in all cases.

At the last follow-up in survivors, no patient showed prosthetic loosening or heterotopic ossification at imaging. Among the 31 survivors in the bipolar hemiarthroplasty group, acetabular wear occurred in three cases, and radiolucent lines appeared in the proximal femur in four cases, in the distal femoral prosthesis in one case, and in the central area in one case, which were absent in the first postoperative X-ray. Osteolysis was found in the proximal femur in one case.

Among the 33 survivors in the total hip replacement group, no acetabular linear wear was found, and eight cases showed radiolucent lines in the acetabular region, six in the proximal femur, and one in the central area, which were absent in the first postoperative X-ray. Two cases presented osteolysis in the proximal femur.

Among the 12 deaths, follow-up was no shorter than 2 years and bone ingrowths were found in all cases. No case suffered from prosthetic loosening, heterotopic ossification, acetabular wear, or osteolysis. Four patients showed radiolucent lines in the proximal femur (one and three cases in the bipolar hemiarthroplasty and total hip replacement groups, respectively).

Typical cases

Figure 2 presents the imaging of a typical case that underwent total hip replacement. The patient was a 70-year-old female who fell down while walking. At that time, she did not visit the

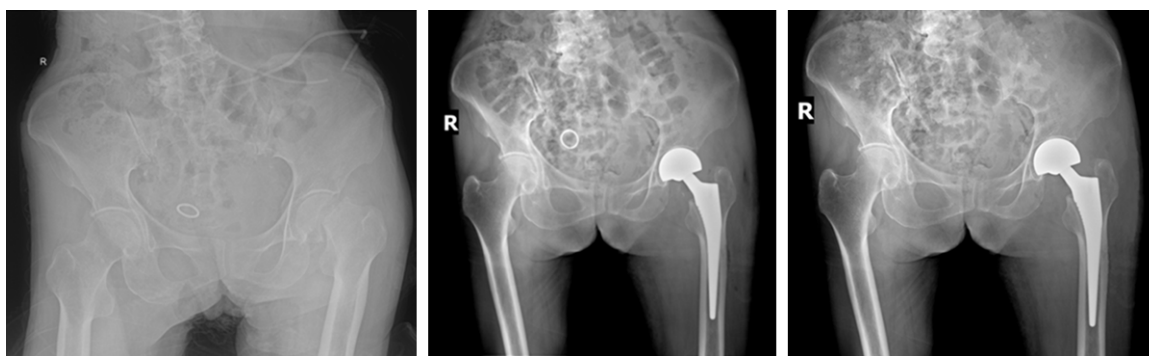


Figure 3. A typical case of bipolar hemiarthroplasty. From left to right: before surgery, after surgery, and 5 years after surgery. The patient was a 81-year-old female, who had a fall. The patient underwent left bipolar hemiarthroplasty.

hospital and stayed at home for 16 weeks, and then visited the hospital due to right hip pain when walking. X-ray revealed right femoral neck fracture, osteoporosis, smooth fracture end, large space of fracture end, femoral neck absorption, and displacement of femur to the proximal end. The patient underwent right total hip replacement.

Figure 3 presents the imaging of a typical case that underwent bipolar hemiarthroplasty. This was a female patient aged 81 years old who visited to her local hospital due to left hip pain after falling and was diagnosed with a left hip soft tissue injury. However, she still could walk on her own. Sixty days after injury, the patient felt unbearable pain in her left hip and visited our hospital. The X-ray examination showed a left femoral neck fracture, fracture end absorption and proximal femoral displacement. Left artificial femoral head replacement surgery was performed in our hospital. The location of the femoral prosthesis was good in the first X-ray examination after surgery. The obvious subsidence of femoral prosthesis and degeneration of acetabular bone were not observed during the reexamination at the fifth year after surgery.

Discussion

Four treatment options are available for new femoral neck fracture: internal fixation, unipolar or bipolar hemiarthroplasty and total hip replacement. A recent meta-analysis showed that the mortality and hip infection rate were not significantly different between total hip replacement and bipolar hemiarthroplasty in patients with new femoral neck fracture [25].

Although the dislocation rate was higher after total hip replacement, the HHS was higher and the risk of reoperation was lower. The incidence of complications, mortality, reoperation rate, and function showed that although the cost of total hip replacement is higher due to the additional acetabular prosthesis and longer operation time, total hip replacement is the most economic and effective treatment available at present [26, 27].

However, neglected femoral neck fractures differ from new femoral neck fractures because these fractures often show symptoms and signs such as pain, limping, limb shortening, imaging manifestations of osteoporosis, femoral neck absorption and nonunion or even ischemic necrosis of femoral head, as well as pathological manifestations of fracture, cataphracted shedding, or even cartilage necrosis on the cartilage's surface. Therefore, different treatment approaches are often necessary.

For neglected femoral neck fracture in patients younger than 60 years, treatments with internal fixation, intertrochanteric valgus osteotomy, non-vascularized fibular graft, vascularized bone graft, and autologous bone and marrow transplantation are likely to achieve satisfactory clinical efficacy [11, 28-30]. However, patients aged ≥ 60 years present a higher rate of bone nonunion and ischemic necrosis of the femoral head, leading to a higher risk of reoperation after surgery.

In the present study, clinical efficacy of neglected femoral neck fracture treatment in patients aged ≥ 60 years old were similar between bipolar hemiarthroplasty and total hip replacement.

However, the bipolar hemiarthroplasty tended to wear the cartilage acetabularis over time, affecting the efficacy and requiring re-operation.

In the present study, there was no patient suffering from loosening or infection, while five patients suffered from postoperative periprosthetic femoral fractures. Among them, four cases had Vancouver B1 fractures due to mild trauma including one case treated with traction and three with open reduction and fixation. Another case had a Vancouver B2 fracture and underwent long-stem femoral prosthetic revision plus fixation, and achieved good healing. Patients with periprosthetic femoral fracture are usually frail and suffering from osteoporosis. The increasing incidence of periprosthetic femoral fracture observed after hip arthroplasty is likely due to expanding indications for hip arthroplasty and increased aging of populations [31].

Although uncemented prostheses (the CORAIL stem) were selected in all cases in the present study, the use of cemented or uncemented prostheses in the treatment of femoral neck fracture is still controversial. Some studies suggest that the advantages of cemented prosthesis are to reduce postoperative thigh pain, aseptic loosening, and incidence of periprosthetic fracture [32, 33]. However, some surgeons believed that uncemented prostheses tend to eliminate cement-related complications and mortality, reduce operation time, and thereby reduce the postoperative complications [34, 35]. A randomized controlled trial by Langslet et al. [36] showed that the 5-year clinical efficacy of femoral neck fracture with uncemented and cemented arthroplasty was satisfactory, and that the hip function score as well as the probability of periprosthetic fractures were higher in uncemented arthroplasty. However, a recent case-control study has shown that the CORAIL stem presented comparable clinical efficacy and mortality with cemented stems, with significantly reduced operation time, incidence of complications, and reoperation rate including the incidence of periprosthetic femoral fracture [37].

The advantages of this randomized controlled study were that all surgeries were performed by the same surgeon, and that the clinical results and imaging were observed by the same group

of researchers. However, the present trial suffers from some limitations. Indeed, there might be detection bias by the observers while reviewing imaging data. Although the intraoperative blood loss was calculated, the total blood loss and blood transfusion in the perioperative period were not included. Finally, the trial was not blinded and the sample size was relatively small, which were likely to cause bias.

In summary, for elderly patients (≥ 60 years old) with neglected femoral neck fracture, total hip replacement had better hip function and lower risk of reoperation compared with bipolar hemiarthroplasty.

Acknowledgements

The authors acknowledge the invaluable participation of the patients, as well as the staff from the operating room, the surgical ward and radiology.

Disclosure of conflict of interest

None.

Authors' contribution

Xu FS and Ke RJ carried out the studies, participated in collecting data, and drafted the manuscript. Gu YF performed the statistical analysis and participated in its design. Qi W helped to draft the manuscript. All authors read and approved the final manuscript.

Abbreviations

BH, bipolar hemiarthroplasty; THR, hip replacement.

Address correspondence to: Wei Qi, Department of Orthopedics, China People's Liberation Army 359 Hospital, No. 8, East Zhongshan Road, Zhenjiang 212000, Jiangsu, China. Tel: +86-13952886258; Fax: +86-021-64085875; E-mail: doctor_qw@sina.com

References

- [1] Cheng SY, Levy AR, Lefaivre KA, Guy P, Kuramoto L and Sobolev B. Geographic trends in incidence of hip fractures: a comprehensive literature review. *Osteoporos Int* 2011; 22: 2575-2586.
- [2] Wittich A, Bagur A, Mautalen C, Cristofari A, Escobar O, Carrizo G and Oliveri B. Epidemiology

- of hip fracture in Tucuman, Argentina. *Osteoporos Int* 2010; 21: 1803-1807.
- [3] Johansson H, Clark P, Carlos F, Oden A, McCloskey EV and Kanis JA. Increasing age- and sex-specific rates of hip fracture in Mexico: a survey of the Mexican Institute of Social Security. *Osteoporos Int* 2011; 22: 2359-2364.
- [4] Lefavre KA, Levy AR, Sobolev B, Cheng SY, Kuramoto L and Guy P. Changes in first hip fracture rates in British Columbia Canada, 1990-2004. *Osteoporos Int* 2011; 22: 2817-2827.
- [5] Mak JC, Cameron ID, March LM; National Health and Medical Research Council. Evidence-based guidelines for the management of hip fractures in older persons: an update. *Med J Aust* 2010; 192: 37-41.
- [6] Grover M, Edwards F, Hitchcock K and Stevens MM. Clinical inquiries. What steps can reduce morbidity and mortality caused by hip fractures? *J Fam Pract* 2007; 56: 944-946.
- [7] Haentjens P, Magaziner J, Colon-Emeric CS, Vanderschueren D, Milisen K, Velkeniers B and Boonen S. Meta-analysis: excess mortality after hip fracture among older women and men. *Ann Intern Med* 2010; 152: 380-390.
- [8] Nagi ON, Dhillon MS and Goni VG. Open reduction, internal fixation and fibular autografting for neglected fracture of the femoral neck. *J Bone Joint Surg Br* 1998; 80: 798-804.
- [9] Roshan A and Ram S. Early return to function in young adults with neglected femoral neck fractures. *Clin Orthop Relat Res* 2006; 447: 152-157.
- [10] Sandhu HS, Sandhu PS and Kapoor A. Neglected fractured neck of the femur: a predictive classification and treatment by osteosynthesis. *Clin Orthop Relat Res* 2005; 14-20.
- [11] Meyers MH, Harvey JP Jr and Moore TM. Treatment of displaced subcapital and transcervical fractures of the femoral neck by musclepedicle-bone graft and internal fixation. A preliminary report on one hundred and fifty cases. *J Bone Joint Surg Am* 1973; 55: 257-274.
- [12] Lawrence VA, Hilsenbeck SG, Noveck H, Poses RM and Carson JL. Medical complications and outcomes after hip fracture repair. *Arch Intern Med* 2002; 162: 2053-2057.
- [13] Donegan DJ, Gay AN, Baldwin K, Morales EE, Esterhai JL Jr and Mehta S. Use of medical comorbidities to predict complications after hip fracture surgery in the elderly. *J Bone Joint Surg Am* 2010; 92: 807-813.
- [14] Parker MJ, Gurusamy KS and Azegami S. Arthroplasties (with and without bone cement) for proximal femoral fractures in adults. *Cochrane Database Syst Rev* 2010; CD001706.
- [15] Leonardsson O, Sernbo I, Carlsson A, Akesson K and Rogmark C. Long-term follow-up of replacement compared with internal fixation for displaced femoral neck fractures: results at ten years in a randomised study of 450 patients. *J Bone Joint Surg Br* 2010; 92: 406-412.
- [16] Mauermann WJ, Shilling AM and Zuo Z. A comparison of neuraxial block versus general anesthesia for elective total hip replacement: a meta-analysis. *Anesth Analg* 2006; 103: 1018-1025.
- [17] Teloken MA, Bissett G, Hozack WJ, Sharkey PF and Rothman RH. Ten to fifteen-year follow-up after total hip arthroplasty with a tapered cobalt-chromium femoral component (tri-lock) inserted without cement. *J Bone Joint Surg Am* 2002; 84-A: 2140-2144.
- [18] Phillips NJ, Stockley I and Wilkinson JM. Direct plain radiographic methods versus EBRA-Digital for measuring implant migration after total hip arthroplasty. *J Arthroplasty* 2002; 17: 917-925.
- [19] Kim YH and Kim VE. Uncemented porous-coated anatomic total hip replacement. Results at six years in a consecutive series. *J Bone Joint Surg Br* 1993; 75: 6-13.
- [20] Hirakawa K, Mitsugi N, Koshino T, Saito T, Hirasawa Y and Kubo T. Effect of acetabular cup position and orientation in cemented total hip arthroplasty. *Clin Orthop Relat Res* 2001; 135-142.
- [21] Engh CA, Massin P and Suthers KE. Roentgenographic assessment of the biologic fixation of porous-surfaced femoral components. *Clin Orthop Relat Res* 1990; 107-128.
- [22] Kawamura H, Dunbar MJ, Murray P, Bourne RB and Rorabeck CH. The porous coated anatomic total hip replacement. A ten to fourteen-year follow-up study of a cementless total hip arthroplasty. *J Bone Joint Surg Am* 2001; 83-A: 1333-1338.
- [23] Martell JM and Berdia S. Determination of polyethylene wear in total hip replacements with use of digital radiographs. *J Bone Joint Surg Am* 1997; 79: 1635-1641.
- [24] Brooker AF, Bowerman JW, Robinson RA and Riley LH Jr. Ectopic ossification following total hip replacement. Incidence and a method of classification. *J Bone Joint Surg Am* 1973; 55: 1629-1632.
- [25] Yu L, Wang Y and Chen J. Total hip arthroplasty versus hemiarthroplasty for displaced femoral neck fractures: meta-analysis of randomized trials. *Clin Orthop Relat Res* 2012; 470: 2235-2243.
- [26] Iorio R, Healy WL, Lemos DW, Appleby D, Lucchesi CA and Saleh KJ. Displaced femoral neck fractures in the elderly: outcomes and cost ef-

- fectiveness. *Clin Orthop Relat Res* 2001; 229-242.
- [27] Rogmark C, Carlsson A, Johnell O and Sembo I. Costs of internal fixation and arthroplasty for displaced femoral neck fractures: a randomized study of 68 patients. *Acta Orthop Scand* 2003; 74: 293-298.
- [28] Mathews V and Cabanela ME. Femoral neck nonunion treatment. *Clin Orthop Relat Res* 2004; 57-64.
- [29] Banks HH. Nonunion in fractures of the femoral neck. *Orthop Clin North Am* 1974; 5: 865-885.
- [30] Lifeso R and Younge D. The neglected hip fracture. *J Orthop Trauma* 1990; 4: 287-292.
- [31] Della Rocca GJ, Leung KS and Pape HC. Periprosthetic fractures: epidemiology and future projections. *J Orthop Trauma* 2011; 25 Suppl 2: S66-70.
- [32] Lo WH, Chen WM, Huang CK, Chen TH, Chiu FY and Chen CM. Bateman bipolar hemiarthroplasty for displaced intracapsular femoral neck fractures. Uncemented versus cemented. *Clin Orthop Relat Res* 1994; 75-82.
- [33] Khan RJ, MacDowell A, Crossman P, Datta A, Jallali N, Arch BN and Keene GS. Cemented or uncemented hemiarthroplasty for displaced intracapsular femoral neck fractures. *Int Orthop* 2002; 26: 229-232.
- [34] Lennox IA and McLauchlan J. Comparing the mortality and morbidity of cemented and uncemented hemiarthroplasties. *Injury* 1993; 24: 185-186.
- [35] Parvizi J, Ereth MH and Lewallen DG. Thirty-day mortality following hip arthroplasty for acute fracture. *J Bone Joint Surg Am* 2004; 86-A: 1983-1988.
- [36] Langslet E, Frihagen F, Opland V, Madsen JE, Nordsletten L and Figved W. Cemented versus uncemented hemiarthroplasty for displaced femoral neck fractures: 5-year followup of a randomized trial. *Clin Orthop Relat Res* 2014; 472: 1291-1299.
- [37] Bell KR, Clement ND, Jenkins PJ and Keating JF. A comparison of the use of uncemented hydroxyapatite-coated bipolar and cemented femoral stems in the treatment of femoral neck fractures: a case-control study. *Bone Joint J* 2014; 96-B: 299-305.