Int J Clin Exp Med 2017;10(5):7774-7784
www.ijcem.com /ISSN:1940-5901/IJCEM0042698

Original Article

Electrophysiological and imaging outcomes analysis in patients with peripheral nerve injury treated with biodegradable conduit small-gap (2 mm) tubulization: a 5-year follow-up

Zhongdi Liu, Na Han, Yuhui Kou, Xiaofeng Yin, Zhongguo Fu, Baoguo Jiang, Peixun Zhang

Department of Trauma and Orthopedics, Peking University People's Hospital, Beijing, China

Received April 19, 2016; Accepted March 20, 2017; Epub May 15, 2017; Published May 30, 2017

Abstract: Despite progress in understanding the pathophysiology of peripheral nervous injury and regeneration, as well as advancements in different surgical techniques, peripheral nerve repair and functional reconstruction is still a major challenge for orthopedic surgeons. We proposed a new method to reconstruct peripheral nerve injury by using a new type of biodegradable biomaterial nerve tube. This tube is suited to maximize re-innervation of the regenerating proximal stump into the degenerating distal stump by providing a conduit for nerve guidance. The purpose of this prospective study was to investigate the long-term follow-up outcomes of different nerve repair technologies (biodegradable conduit small-gap tubulization and traditional epineurial suture) for the treatment of peripheral nerve injury. The nerve functional recovery conditions and electrophysiological studies were carried out at the 3-, 6-, 24- and 60-month after first surgery. Imageological diagnosis was carried out at the 60th month of the follow-up. Reconstruction images and related data along the injured nerves were compared with normal sides and correlated with electrophysiological neurography results. Complications were also recorded. The results showed that the clinical recovery effect of the injured nerves treated with biodegradable conduit small-gap (2 mm) tubulization was better than that treated with traditional epineurial neurorrhaphy in early period in this 5-year follow-up. Thus we conclude that biodegradable small-gap (2 mm) tubulization is an effective procedure in peripheral nerve injury treatment with an early good functional outcome, and presents potentially groundbreaking possibilities to help guide peripheral nerve reconstruction after injury in the future.

Keywords: Peripheral nerve injury, nerve repair, biodegradable conduit, epineurial neurorrhaphy, tubulization

Introduction

Each year, approximately 1 million people worldwide experience peripheral nerve injury. Peripheral nerves are susceptible to various mechanisms of injury, such as crush, stretch, cutting, and penetrating traumas [1]. Functional recovery is often unsatisfactory after lesions in the peripheral nervous system despite the potential for regeneration and advancement in microsurgical techniques. Patients with peripheral nerve injuries have to face unpredictable and often suboptimal functional outcome, including loss of muscle function, pain and impairment of sensory function.

Peripheral nerves have the ability to regenerate after incomplete transection or crush, by means of complex systems of neurotrophic factors and related receptors [2]. Surgical intervention should be performed to establish continuity of the nerve stumps, with proper rotational alignment and without tension, following complete transection. An effective nerve repair is directly related to sensory, motor, and autonomic axons system making appropriate connections with their distal organs. Epineurial repair is the traditional method after mutilation of peripheral nerves; however, the effect of functional recovery is often suboptimal, and is always associated with absence of sensory and motor functions because of failure in the formation of correct nerve fiber connections [3].

Based on the phenomenon of peripheral nerve selective regeneration [4], we conceived to

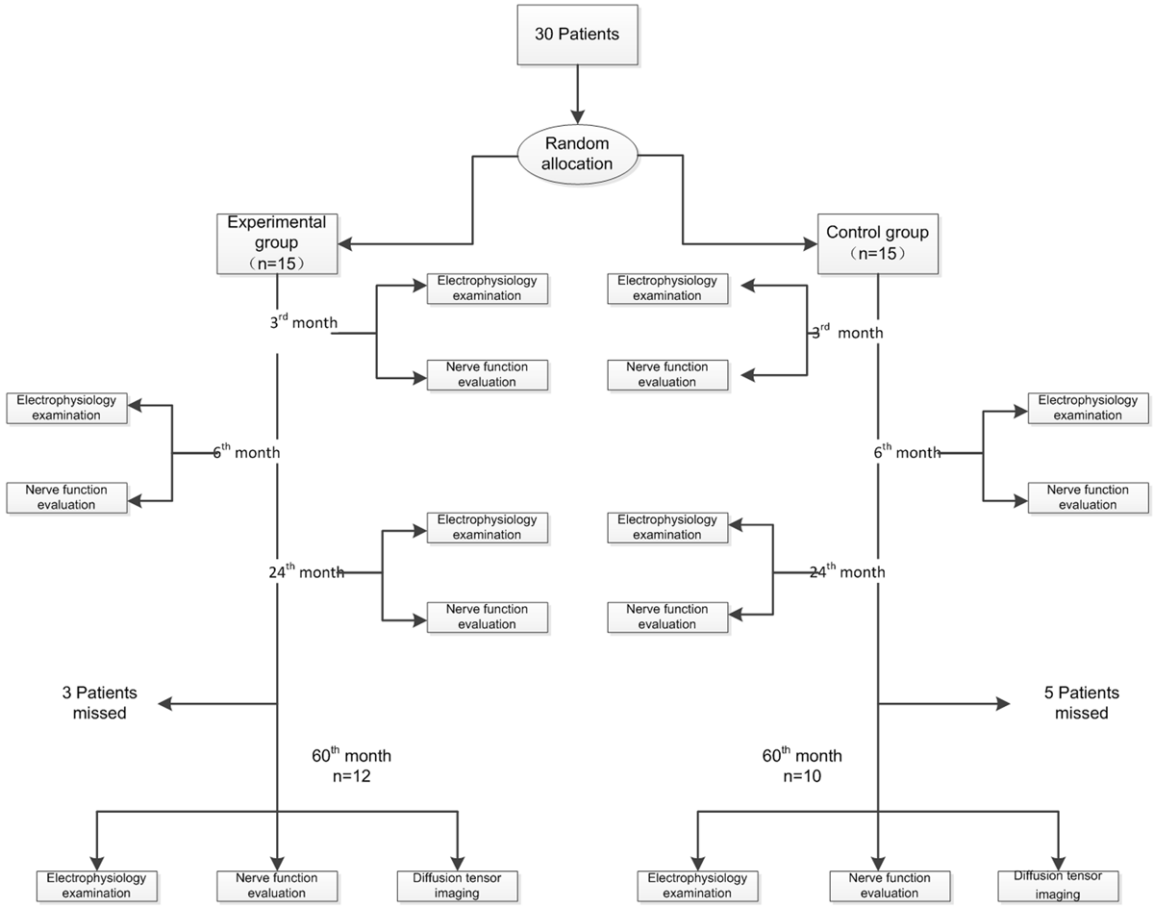

Figure 1. Flow chart for patient recruitment and follow up.

repair peripheral nerve mutilations using a new type of biodegradable biomaterial tube, in which a small gap remains between the nerve stumps for selective regeneration. This method aims to maximize re-innervation of the regenerating proximal stump into the degenerating distal stump by providing a conduit for nerve guidance. The conduits used in our study comprise of de-acetyl chitin, which were invented by Beijing University People's Hospital (China) and Chinese Textile Academy (State Patent No. 01136314.2). Experiments in rats and rhesus monkeys showed that a 2-mm small gap between the two ruptured stumps exhibits the most satisfactory selective regeneration [4-7]. After authenticating the effectiveness and safety of the conduit with a series of animal experiments, we performed this prospective study to affirm the superiority of biodegradable conduit small-gap (2 mm) tubulization in peripheral nerve injury repair in clinical practice. In this study, we evaluated the electrophysiological and imaging characteristics in patients with peripheral nerve mutilation treated with biodegradable small-gap tubulization and traditional epineurial repair during a 5-year follow-up to validate the long-term clinical availability of small-gap tubulization techniques.

Material and methods

Patients

A total of 30 patients with peripheral nerve mutilation (median or ulnar nerves without deficits) admitted to Peking University People's Hospital, from November 2008 to February 2010, were enrolled in our study. Patients were randomized into two groups, with 15 cases with peripheral nerve mutilation repaired by biodegradable conduit small-gap (2 mm) tubulization (the experimental group) and other 15 cases repaired using traditional epineurial neurorrhaphy (the control group). The mean follow-up ti-

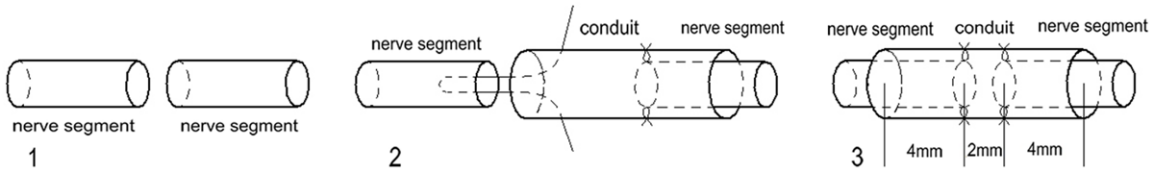

Figure 2. View of the biodegradable conduit small-gap (2-mm) tubulization method. 1, nerve segments with simple transection injurie; 2, the suture needling sequence; 3, when finished, there was 2 mm gap remained between the two ruptured stumps.

Table 1. Characteristics of patients in both groups

Characteristics	Experimental group (n=12)	Control group (n=10)	Total (n=22)	*P* value
Basic Information				
Age (years), mean ± SD	33±6	31±5	32±6	0.391
Gender				
Male	8	6	14	
Female	4	4	8	
Body mass index, mean ± SD	63.5±7.16	60.3±8.05	62.04±7.57	
Body mass index, mean ± SD	23.21±31.58	22.55±1.87	22.91±1.71	0.858
Pathogenetic condition				
Injured side				
Right	8	6	14	
Left	4	4	8	
Involved nerve				
Median nerve	8	8	16	
Ulnar nerve	4	2	6	

me was 60 months. Electrophysiological examination was performed at the 3-, 6-, 24- and 60-month after surgery, magnetic resonance imaging (MRI) of the injured peripheral nerve was performed at the 60 month, when the restoration ratio of both groups was evaluated. We also examined the availability of high-resolution diffusion tensor imaging (DTI) to inspect regeneration of injured peripheral nerves and correlated the MRI findings with electrophysiology results.

Patients enrolled in this study were all ideal candidates for direct nerve repair, with simple transection injuries, clean and well-vascularized wound beds, skeletal stability, and adequate soft-tissue coverage to avoid the influence of known influencing factors on outcomes. **Figure 1** shows the flow chart for patient recruitment and follow up.

Conduits

Hollow cylindrical de-acetyl chitin conduits (invented by Beijing University People's Hospital and Chinese Textile Academy; State Patent No. 01136314.2), of 10 mm length, 1 mm thickness, and 4-6 mm inner diameter were used in this study. The half-quality degradation time of this biodegradable conduit material is 6 months in SD rats based on our previous experiments.

Technique

Traditional epineurial neurorrhaphy was performed with the same mechanism as is commonly applied clinically, which is by directly suturing the two ruptured stumps using absorbable sutures. Biodegradable conduit small-gap tubulization was performed by bridging the two ruptured stumps using the biodegradable conduit, in which a 2-mm small gap existed between the two ruptured stumps and allows for tensionless primary docking (**Figure 2**). After nerve repair, the surgical site in patients of both groups was immobilized until wound healing to protect the repaired nerves.

Ethics statement

Written informed consent was obtained from all participants, and the study was approved by the Ethics Committee of People's Hospital,

Table 2. The combined excellent and good evaluation criteria

Grading	Mixed nerve	
	Middle and lower segment of forearm and wrist	Upper of forearm and other nerve
Excellent	M5S3A3*	M5S3A3 above
Good	M4S3A2 above	M3S3A2 above
Common	M3S2A1 above	M2S2A1 above
Poor	M2S1A0 above	M2S1A0
**Motor function evaluation		
Classification	Details	
M0	No muscle contraction	
M1	Proximal muscle contraction function recovery	
M2	Proximal and distal muscle contraction function recovery	
M3	All important muscle can joint resistance activities	
M4	All coordinated movement or freedom movement recovery	
M5	A full recovery	
***Sensory function evaluation		
Classification	Details	
S0	Single innervation area feel lost	
S1	Single innervation area deep sensation recovery	
S2	Single innervation area superficial pain and touch recovery at a certain degree	
S3	Single innervation area superficial pain and touch recover, feel allergic disappear	
S3+	On the basis of S3 feel further recovery	
S4	A full recovery	
****According to the indene ketone and bromophenol blue test, with sweat function as evaluation index of autonomic nervous function		
Classification	Details	
A3	Sweat is normal	
A2	Moderate sweat, showing blue or purple fingerprints	
A1	Sweat less, showing blue or purple dot, don't connect as fingerprint	
A0	No sweat	

*M for Motor function evaluation**; S for Sensory function evaluation***; A for Autonomic nervous function****.

Peking University, all clinical investigation was conducted according to the principles expressed in the Declaration of Helsinki.

Statistical analysis

The SPSS 19.0 software package (SPSS Inc., USA) was used for statistical analysis. Experimental data were compared using the Chi-square test. Differences were considered statistically significant when $P<0.05$.

Results

General results

Of the total 30 cases, 22 were followed up at the 5-year time point, and there were 12 cases in the experimental group and 10 cases in the control group. The operation procedure was very simple, and the mean suture time of the experimental group to repair peripheral nerve injury [(8.0±0.8) min] was 20% shorter than that of the control group [(10.0±0.6) min]. No inflammation, infection or suspicious allergic complication was observed in all the enrolled patients during the follow-up period, demonstrating the excellent biocompatibility of the biodegradable conduits. **Table 1** shows the characteristics of patients in both groups.

Criterion evaluation

We adopted the combined evaluation of excellent and good criteria, a modified version of the British Medical Research Council (BMRC)'s System, established by Zhu Jiakai and Shen Ningjiang, for the evaluation of motor and sen-

Table 3. Characteristics of 12 patients in the experimental group at the 5-year time point after surgery

Patient information				Combined functional evaluation	Nerve conduction velocity (m/s)		Quantification data of DTI*****			
Case	Sex	Age	Injured nerve		SCV***	MCV****	Average FA value (injured area)	Average FA value (normal side)	Average ADC value (injured area)	Average ADC value (normal side)
P01	M	28	LM*	M4S3A2	54	52	0.256	0.53	1.499	0.979
P02	F	30	LU	M4S3A2	50	54	0.38	0.973	1.013	0.937
P03	M	47	RM	M3S3A2	49	50	0.233	0.399	1.422	1.211
P04	M	29	RM	M4S3+A2	46	48	0.345	0.712	1.145	0.889
P05	F	33	RU**	M4S4A3	50	50	0.485	0.805	1.189	0.872
P06	F	25	RU	M4S3A2	48	51	0.574	0.733	1.414	1.157
P07	M	37	RM	M5S3+A3	53	49	0.287	0.556	1.456	0.933
P08	M	26	LM	M4S4A2	56	54	0.413	0.834	1.113	0.956
P09	M	29	LM	M4S3A2	48	52	0.256	0.413	1.434	1.218
P10	M	36	RU	M4S3+A2	53	52	0.335	0.707	1.144	0.903
P11	F	42	RM	M3S2A1	39	43	0.465	0.811	1.179	0.875
P12	M	30	RM	M3S3A2	44	43	0.575	0.719	1.443	1.176

*L for left; M for median nerve; **R for right; U for ulnar nerve; ***SCV for sensory nerve conduction velocity; ****MCV for motor nerve conduction velocity; *****DTI for Diffusion tensor imaging.

Table 4. Characteristics of 10 patients in the control group at the 5-year time point after surgery

Patient information				Combined functional evaluation	Nerve conduction velocity (m/s)		Quantification data of DTI******			
Case	Sex	Age	Injured nerve		SCV***	MCV****	Average FA value (injured area)	Average FA value (normal side)	Average ADC value (injured area)	Average ADC value (normal side)
P01	M	33	RM*	M3S2A1	37	41	0.249	0.51	1.443	0.923
P02	M	32	RM	M4S3+A2	45	46	0.393	0.807	1.114	0.934
P03	M	28	RM	M3S3A2	41	42	0.245	0.409	1.122	0.887
P04	F	47	LU**	M3S2A1	37	48	0.375	0.722	1.445	1.267
P05	F	30	RU	M4S3A2	46	43	0.495	0.823	1.194	0.892
P06	M	31	RM	M4S3A2	45	46	0.559	0.715	1.424	1.185
P07	M	27	RM	M4S3A2	50	52	0.267	0.556	1.409	0.835
P08	F	26	LM	M3S3A2	44	50	0.366	0.89	1.257	0.909
P09	F	34	LM	M4S3+A2	49	52	0.249	0.394	1.479	1.378
P10	M	28	LM	M5S3A2	51	52	0.398	0.762	1.098	0.867

*R for right; M for median nerve; **L for left; U for ulnar nerve; ***SCV for sensory nerve conduction velocity; ****MCV for motor nerve conduction velocity; *****DTI for Diffusion tensor imaging.

Table 5. Comparison of combination evaluation excellent and good rates of two groups at different follow-up time points

Time	The combination evaluation excellent and good rate %		*P* value
	Experimental Group (n)	Control Group (n)	
3rd month	33.3 (15)	13.3 (15)	0.323
6th month	71.4 (14)	23 (13)	0.030
24th month	83.3 (12)	50 (10)	0.172
60th month	91.7 (12)	80 (10)	0.571

sory recovery. This criteria involved motor function evaluation grading (M), sensory function grading (S), and autonomic nerve function evaluation grading (A) (**Table 2**). Visual analog scale (VAS) assessment was used to evaluate pain release in patients. Detailed data of the combination evaluation excellent and good rate of the patients in different groups are listed in **Tables 3** and **4**. The combined functional recovery excellent and good rate in the experimental group were 33.3%, 71.4%, 83.3%, 91.7%, while 13.3%, 23%, 50%, 80% in the control group at the 3-, 6-, 24- and 60-month after surgery, there was statistically significant of two groups (P=0.030) at the sixth month after surgery (**Table 5**). As for the visual analogue scale assessment, no significant difference between the two groups was observed at the 5-year time point.

Electromyography

Electrophysiology examination results at the 3-, 6-, 24- and 60-month displayed that the sensory conduction velocity recovery rate was 40.6%, 62.3%, 67.8% and 72.3% of the normal value, and motor conduction velocity recovery rate was19.4%, 46.1%, 63.3% and 77.9% in the experimental group.

The sensory conduction velocity recovery rate was 26.7%, 31.6%, 59.3% and 65.4% of the normal value, and motor conduction velocity recovery rate was 13.6%, 21.7%, 56.7% and 73.8% in the control group at the same time points during the follow-up period (**Table 6**).

The rate of sensory/motor conduction recovery of the experimental group was higher about 30.7%/24.4% when compared with the control group at the sixth month, however, the rate was similar (72.3% vs. 65.4%/77.9% vs. 73.8%) between different groups at the 5-year time point.

Diffusion tensor imaging

We applied diffusion tensor imaging (DTI), a recently developed MRI technique that reveals the microstructures of tissues based on its ability to monitor the random movements of water molecules, to visualize the injured and normal nerves in different groups. DTI can provide information complementary to clinical examination and electrophysiological recordings in peripheral nerves [8-10]. Magnetic resonance images were acquired at a 3.0 T Verio whole-body MRI system (Siemens, Erlangen, Germany). Patients were scanned in a prone position, with the arm abducted and hand alongside the head, and the contralateral wrist flexed in the most comfortable position, we obtained imaging and data of the injured limb and the normal side in each patient (**Figures 3** and **4**).

The measured diffusion-weighted images are further analyzed for parameter images that describe different characteristics of diffusion, apparent diffusion coefficient (ADC) is a measure of the strength of diffusion, and fractional anisotropy (FA) describes the asymmetry of the diffusion direction due to tissue structures. Moreover, we applied tractography technique to visualize the 3D course of nerve fibre bundles. ADC and FA are considered sensitive measures of nerve fiber integrity in different studies because they were independent of location of measurement and hand posture, our analysis focused on the data measured at different levels around the injured nerves with the hand naturally postured. ADC and FA values of patients in both groups were listed in **Tables 3** and **4**, data of different groups and injured/normal nerves in one patient were compared with the Chi-square tests.

There was no significant difference in the FA/ADC values (P=0.619; P=0.455) of the injured nerves between the two groups. However, the patients' parallel diffusivity along the nerves, measured at different levels around the injured areas, differed significantly between the injured side and the normal side in both groups (P=0.000; P=0.000). FA decreased in the

Table 6. Sensory and Motor Functional Recovery Rates in different groups

Time	Rate of sensory conduction recovery %		P1	Rate of motor conduction recovery %		P2
	Experimental Group (n)	Control Group (n)		Experimental Group (n)	Control Group (n)	
3rd month	40.6 (15)	26.7 (15)	0.756	19.4 (15)	13.6 (15)	0.599
6th month	62.3 (14)	31.6 (13)	0.021	46.1 (14)	21.7 (13)	0.312
24th month	67.8 (12)	59.3 (10)	0.807	63.3 (10)	56.7 (10)	0.081
60th month	72.3 (12)	65.4 (10)	0.814	77.9 (10)	73.8 (10)	0.352

injured side in all 22 patients, while ADC increased.

Discussion

Peripheral nerve injury affects 2.8% of patients with trauma, presenting a critical clinical issue. Autologous nerve grafting is the current 'gold standard' for large nerve defects, however, limitations like excessive tension, fascicular incongruity, reduction of nerve viability with time still pose a problem. For many years, the most commonly used method for treatment of peripheral nerve transection injuries has been the use of end-to-end suturing/primary repair of the injured nerve segments. However, functional reinnervation remains limitation for most patients, even with optimal microsurgical techniques, the recovery of motor and sensory functions are less than satisfactory [11, 12].

Axonal regeneration in mixed nerve into inappropriate pathways is a major contributing factor to this failure. The primary aim of surgical intervention is to direct the regenerating proximal fibers into the environment of the degenerating distal stump. Challenges in peripheral nerve repair have resulted in the development of nerve guides or conduits from biological and synthetic techniques [13-15]. Nerve conduits were originally developed with the goal of creating an enclosed growing space, for biologic nerve regeneration and acute docking of different nerve fibers in the setting of a significant nerve gap. Nerve conduits have been successfully used to enhance nerve regeneration in experimental and clinical models when used to span nerve gaps [16-18]. Currently, biological conduits like vein or artery, synthetic conduits made of collagen, polyglycolic acid, or caprolactone are among the most commonly employed [19]. Initial studies have shown conduits to be successful in animal model. A prospective, randomized study by Alluin O. et al. [13] demonstrated that motor axonal regeneration and locomotor recovery can be obtained with the insertion of the collagen tube. However, collagen conduits have been noted to cause a degree of inflammation and scarring that may limit their application, or may make larger conduits less amenable to use.

Degradable biological conduit small-gap tubulization for peripheral nerve mutilation provides a relatively secluded microenvironment to maximize the effectiveness of re-innervation of the regenerating proximal stump to the degenerating distal stump, according to the theory of peripheral nerve selective regeneration phenomenon [4, 6]. Indications for the use of small-gap tubulization are ruptured nerve ends without deficits. Biodegradable conduits applied in our early animal experiments showed good biocompatibility, conductivity, and degradation characteristics during the regeneration process. In a series of models of peripheral nerve mutilation in Sprague-Dawley rats and rhesus monkeys, tubulization with a gap of 2-mm between two ruptured stumps exhibited the most satisfactory regeneration results, as assessed by histology, electrophysiology, and functional assessment, and was better than traditional epineural neurorrhaphy [5, 20]. These research outcomes inspired us to use this technique to repair peripheral nerve injury in clinical practice.

After getting the permission of Chinese Government SFDA and Peking University People's Hospital Ethics Committee, we applied biological conduit small gap (2 mm) tubulization in human, confirming the possibility and feasibility for repairing peripheral nerve injury. In this study, we followed up 22 patients with complete median or ulnar nerves injury treated with biodegradable small-gap tubulization or traditional epineurial neurorrhaphy. We used the combined excellent and good evaluation criteria to assess the functional outcomes of the 22 patients at different time points after surgery. The combined functional recovery

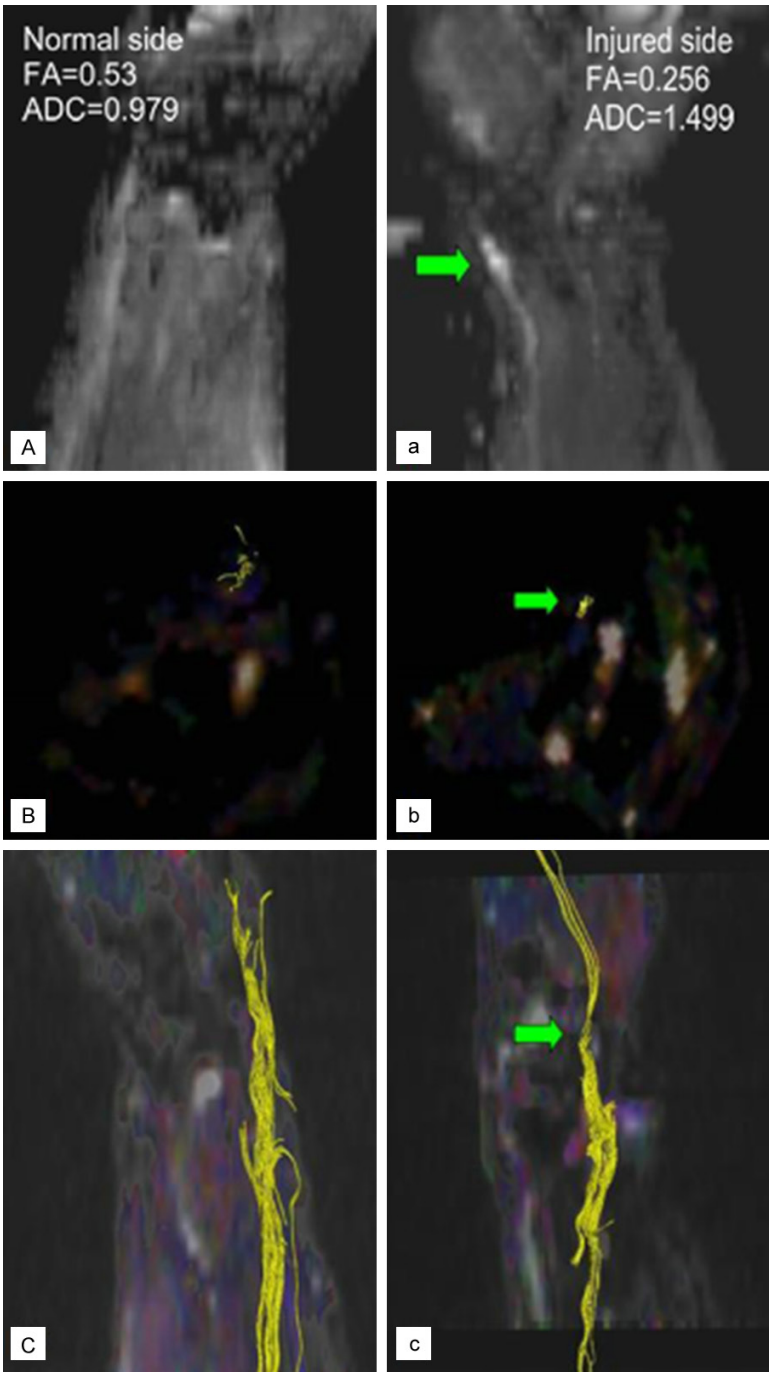

Figure 3. The DTI images of a 33-year-old man with right median nerve injury repaired by biodegradable conduit small-gap (2 mm) tubulization (Case 01 in the experimental group). A, a: Fractional anisotropy (FA) images after coronal maximum intensity projection. Green arrows indicate the injured side of the median nerve surgical site, with poor signal continuity, an enhanced and less uniform signal is seen compared with its neighboring undamaged side. B, b: Direction-encoded color maps in axial direction show the number of fibers is less in the cross section of the injured side than the normal side. C, c: Tractography of the median nerve. Green arrows indicate the surgical area of the median nerve of the injured side, representing a decrease in the number of fibers compared with the normal side. Compensatory thickening and emergence of new branches can be observed in the proximal fibers.

excellent and good rate was better in biodegradable small-gap (2 mm) tubulization group than in traditional epineurial neurorrhaphy group at the sixth month after surgery (71.4% vs. 23%, P=0.03). However, most of the patients got satisfactory functional outcomes at the 5-year time point. We also analyzed the change tendency of sensory and motor conduction velocity restoration ratio of patients in different groups at the 3-, 6-, 24-, and 60-month after nerve repair surgery. The rate of sensory/motor conduction recovery in the experimental group was much higher about 30.7%/24.4% when compared with the control group at the sixth month. However, the mean restoration ratios of SCV and MCV is similar (72.3% vs. 65.4%/77.9% vs. 73.8%) in different groups at the 5-year time point after surgery, this result was consistent with the result of the combined functional recovery excellent and good rates. These results can be explained according to the phenomenon of peripheral nerve selective regeneration, degradable biological conduit small-gap tubulization provides a relatively secluded microenvironment, the small gap provided a relatively closed space, retained the neurotrophic factors and prevented the external invasion of fibrous connective tissue, it maximized the effectiveness of re-innervation of the regenerating proximal stump to the degenerating distal stump, thus promote the early recovery of neurological function. The clinical results were positive the same as in rat and monkey [8], so we believe it

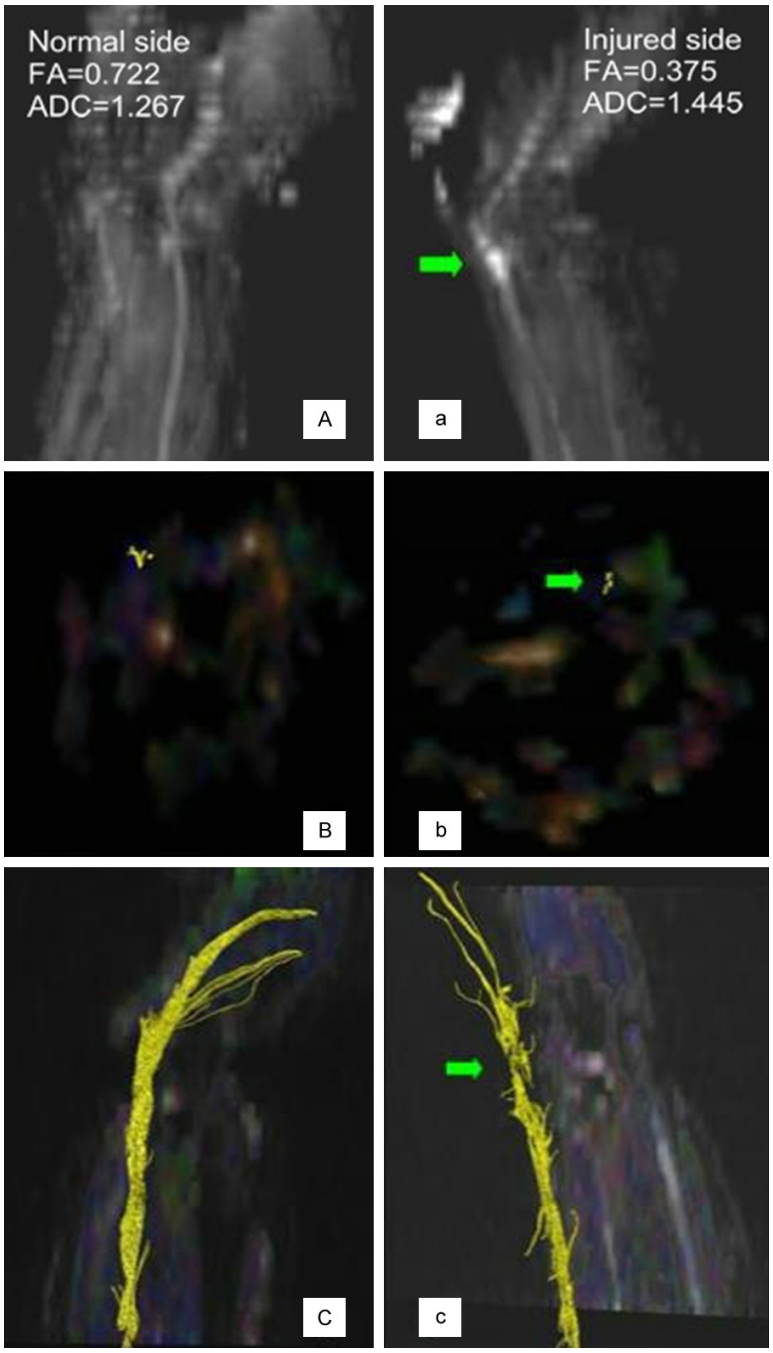

Figure 4. The DTI images of a 47-year-old woman with left ulnar nerve injury treated with traditional epineurial neurorrhaphy (Case 04 in the control group). A, a: Fractional anisotropy (FA) images after coronal maximum intensity projection. Green arrow indicates the injured side of the ulnar nerve, with poor signal continuity. B, b: Direction-encoded color maps in axial direction show the organizational structure of the nerve on the injured side is less structured compared with the normal side. C, c: Tractography of the ulnar nerve. Green arrow indicates the surgical area of ulnar nerve in the injured side, representing decrease in the number of fibers compared with the normal side. Compensatory thickening and emergence of new branches can also be observed in the proximal fibers. The traveling directions of the fibers are more cluttered in the damaged region compared with the normal side.

may be a revolutionary improvement in peripheral nerve surgery field in the near future.

In recent years, DTI has become a standard application for the examination of the central nervous system, while its application to the peripheral nervous system remains challenging. Increased ADC and reduced FA are the most common findings in brain abnormalities, generally, increased ADC may be caused by inflammation or edema, whereas decreased FA may reflect the damage of tissue microstructure, demyelination, axonal loss or increase in isotropic water volume [10]. Nevertheless, several DTI related studies of the peripheral nerve published recently suggest a potential use of this technique to detect nerve regeneration after injury and fascicular repair. Our study demonstrates the availability of using post-operative DTI to monitor nerve integrity in patients with peripheral nerve injury through imaging features. DTI shows great potential as a non-invasive technology to detect axonal injury and regeneration in peripheral nerve injury. Here we monitored nerve integrity in all enrolled patients by means of DTI and MRI at the 5-year time point after surgery. Anatomical images derives from tractography technique showed significant differences in nerve shape, thickness, trend and number of nerve fibers between the injured nerves and the contralateral normal nerves in both groups, and the mean diffusivities (ADC) and fractional anisotro-

py (FA) values along the injured nerves at different levels differ significantly with the values of the normal nerves in both groups.

Conclusion

Treatment of peripheral nerve injuries in clinical department is still challenging today, outcomes have not yet improved enough over the recent years. Peripheral nerve injury often results in substantial disability, patient age, degree of injury, and type of damage mechanism are factors often predict the outcome. In the past decade, tension-free direct repair remains the standard of care in easily approximated nerve ends. However, ongoing research in the use of conduits suggests that synthetic biomaterials, combined with proper indications, may improve outcomes. We creatively put forward this biodegradable small-gap (2 mm) tubulization technique and verified its safety and effectiveness in peripheral nerve repair in humans. This 5-year follow-up authenticated the long-term good outcomes of the treatment through electrophysiological and imaging examinations. Therefore, we believe that the new method of peripheral nerve repair should be more widely applied in clinical practice and could be a substitution for the traditional epineurial repair in the near future for its better recovery effect in early stages.

Acknowledgements

This manuscript was funded by Chinese National Ministry of Science and Technology 973 Project (2014CB542201) and 863 project (SS2015AA020501), the National Natural Science Fund (31571235, 31571236, 31271284, 31171150, 81171146, 31471144, 30971526, 31100860, 31040043, 31371210, 81372044).

Disclosure of conflict of interest

None.

Address correspondence to: Dr. Peixun Zhang, Department of Trauma and Orthopedics, Peking University People's Hospital, South Xizhimen Street, Beijing 100044, China. Tel: 86-010-88324570; Fax: 86-010-88324570; E-mail: zhangpeixun@bjmu.edu.cn

References

[1] Evans GR. Challenges to nerve regeneration. Semin Surg Oncol 2000; 19: 312-318.

[2] Muller HW and Stoll G. Nerve injury and regeneration: basic insights and therapeutic interventions. Curr Opin Neurol 1998; 11: 557-562.

[3] Li R, Liu Z, Pan Y, Chen L, Zhang Z and Lu L. Peripheral nerve injuries treatment: a systematic review. Cell Biochem Biophys 2014; 68: 449-454.

[4] Zhang P, Kou Y, Yin X, Wang Y, Zhang H and Jiang B. The experimental research of nerve fibers compensation amplification innervation of ulnar nerve and musculocutaneous nerve in rhesus monkeys. Artif Cells Blood Substit Immobil Biotechnol 2011; 39: 39-43.

[5] Zhang C, Zhang P, Wang Y, Yu K, Kou Y and Jiang B. Early spatiotemporal progress of myelinated nerve fiber regenerating through biological chitin conduit after injury. Artif Cells Blood Substit Immobil Biotechnol 2010; 38: 103-108.

[6] Jiang B and Zhang P. Advances in small gap sleeve bridging peripheral nerve injury. Artif Cells Blood Substit Immobil Biotechnol 2010; 38: 1-4.

[7] Zhang P, Zhang C, Kou Y, Yin X, Zhang H and Jiang B. The histological analysis of biological conduit sleeve bridging rhesus monkey median nerve injury with small gap. Artif Cells Blood Substit Immobil Biotechnol 2009; 37: 101-104.

[8] Meek MF, Stenekes MW, Hoogduin HM and Nicolai JP. In vivo three-dimensional reconstruction of human median nerves by diffusion tensor imaging. Exp Neurol 2006; 198: 479-482.

[9] Morisaki S, Kawai Y, Umeda M, Nishi M, Oda R, Fujiwara H, Yamada K, Higuchi T, Tanaka C, Kawata M and Kubo T. In vivo assessment of peripheral nerve regeneration by diffusion tensor imaging. J Magn Reson Imaging 2011; 33: 535-542.

[10] Hiltunen J, Kirveskari E, Numminen J, Lindfors N, Goransson H and Hari R. Pre- and post-operative diffusion tensor imaging of the median nerve in carpal tunnel syndrome. Eur Radiol 2012; 22: 1310-1319.

[11] Griffin JW, Hogan MV, Chhabra AB and Deal DN. Peripheral nerve repair and reconstruction. J Bone Joint Surg Am 2013; 95: 2144-2151.

[12] Scholz T, Krichevsky A, Sumarto A, Jaffurs D, Wirth GA, Paydar K and Evans GR. Peripheral nerve injuries: an international survey of current treatments and future perspectives. J Reconstr Microsurg 2009; 25: 339-344.

[13] Alluin O, Wittmann C, Marqueste T, Chabas JF, Garcia S, Lavaut MN, Guinard D, Feron F and Decherchi P. Functional recovery after peripheral nerve injury and implantation of a collagen guide. Biomaterials 2009; 30: 363-373.

[14] de Ruiter GC, Spinner RJ, Yaszemski MJ, Windebank AJ and Malessy MJ. Nerve tubes for pe-

ripheral nerve repair. Neurosurg Clin N Am 2009; 20: 91-105, vii.
[15] Yu K, Zhang C, Wang Y, Zhang P, Zhang D, Zhang H and Jiang B. The protective effects of small gap sleeve in bridging peripheral nerve mutilation. Artif Cells Blood Substit Immobil Biotechnol 2009; 37: 257-264.
[16] Zhang P, He X, Zhao F, Zhang D, Fu Z and Jiang B. Bridging small-gap peripheral nerve defects using biodegradable chitin conduits with cultured schwann and bone marrow stromal cells in rats. J Reconstr Microsurg 2005; 21: 565-571.
[17] Kalbermatten DF, Pettersson J, Kingham PJ, Pierer G, Wiberg M and Terenghi G. New fibrin conduit for peripheral nerve repair. J Reconstr Microsurg 2009; 25: 27-33.
[18] Pettersson J, Kalbermatten D, McGrath A and Novikova LN. Biodegradable fibrin conduit promotes long-term regeneration after peripheral nerve injury in adult rats. J Plast Reconstr Aesthet Surg 2010; 63: 1893-1899.
[19] Daly WT, Knight AM, Wang H, de Boer R, Giusti G, Dadsetan M, Spinner RJ, Yaszemski MJ and Windebank AJ. Comparison and characterization of multiple biomaterial conduits for peripheral nerve repair. Biomaterials 2013; 34: 8630-8639.
[20] Zhang P, Han N, Wang T, Xue F, Kou Y, Wang Y, Yin X, Lu L, Tian G, Gong X, Chen S, Dang Y, Peng J and Jiang B. Biodegradable conduit small gap tubulization for peripheral nerve mutilation: a substitute for traditional epineurial neurorrhaphy. Int J Med Sci 2013; 10: 171-175.