

## Case Report

# 3D CBCT reconstruction as an adjunct in the management of sialectasis of Stensen's duct: a case report and review of literature

Pradeep Singh<sup>1,2</sup>, Jiang Deng<sup>1,2</sup>, Lihua Qiu<sup>1,2</sup>, Ying Li<sup>1,2</sup>, Ping Ji<sup>1,2</sup>

<sup>1</sup>Chongqing key Laboratory of Oral Diseases and Biomedical Sciences, Chongqing, People's Republic of China;

<sup>2</sup>Department of Oral and Maxillofacial Surgery, The Affiliated Hospital of Stomatology, Chongqing Medical University, Chongqing 401147, People's Republic of China

Received September 18, 2016; Accepted December 24, 2016; Epub May 15, 2017; Published May 30, 2017

**Abstract:** Sialectasis of Parotid gland is an infrequent condition, and characterized as dilatation of a segment of Stensen's duct which generally occurs as a consequence of intra-ductal distal obstruction caused by sialoliths, intra-ductal papillomas or partial strictures of the duct. Current imaging technologies including sialendoscopy, sialography, magnetic resonance imaging (MRI), or computed tomography (CT) have their unique diagnostic profile and offer several advantages including cost-effectiveness, availability, and lower radiation dosages. However, despite these advantages, 3-Dimensional Cone Beam Computed Tomography (3D CBCT) has been in favor for the diagnosis of salivary calculus because of its superior diagnostic performance and favorable information-to-radiation-dose ratio. Herein, we presented a case of a patient with sialectasis of the Stensen's duct in whom the cause of the dilatation was not clear. The case was reported for its uncertain etiology and the use of 3D CBCT reconstruction as an adjunct in the diagnosis and management of a relatively rare lesion. In the following case report, a 46-year-old male patient diagnosed with sialectasis of Stensen's duct was treated with integrated 3D CBCT software and conservative surgical approach. Comprehensive treatment planning resulted in restoration of normal facial symmetry and smile form with no signs of relapse. In conclusion, 3D CBCT images allow proper visualization and localization of the lesion and may help in selecting the best approach for surgical intervention, which can altogether influence the management of the patient substantially.

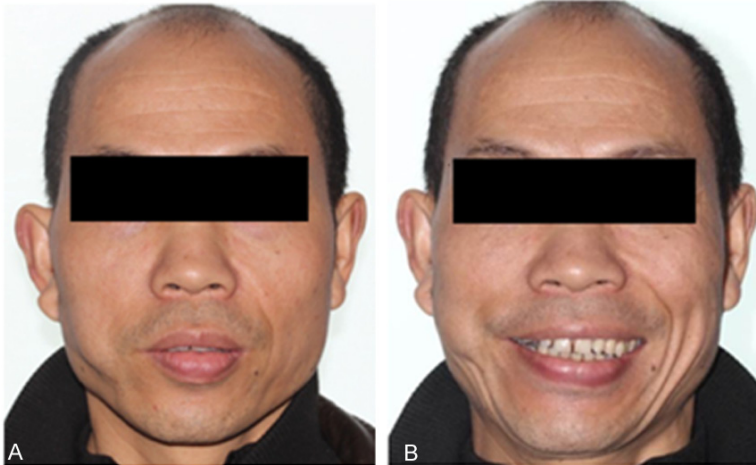**Keywords:** 3D, CBCT, sialectasis, Stensen's duct, dilatation

## Introduction

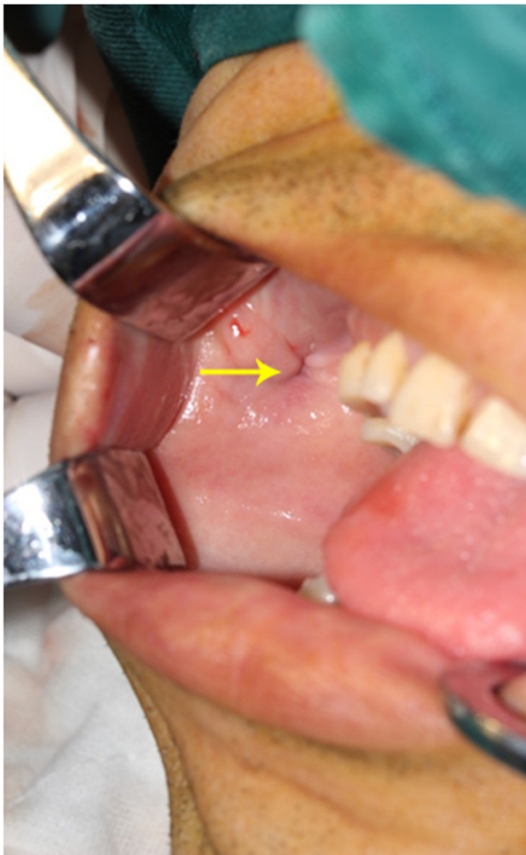Sialectasis of Parotid gland is an infrequent condition, and characterized as dilatation of a segment of Stensen's duct that generally occurs as a consequence of an intra-ductal distal obstruction [1]. The dilatation of duct is a chronic process and can result from sialoliths, intra ductal papillomas [2] or partial strictures of the duct [3]. Ductal stenosis may also occur secondary to sialolithotomy, traumatic ductal injury, or as a consequence of long-standing ductal inflammation associated with chronic parotitis [4]. Current imaging technologies including sialendoscopy, sialography, magnetic resonance imaging (MRI), or computed tomography (CT) have their unique diagnostic profile and offer several advantages including cost-

effectiveness, availability, and lower radiation dosages. However, despite these advantages, 3D CBCT has been in favor for the diagnosis of salivary calculus because of its superior diagnostic performance and favorable information-to-radiation-dose ratio [5]. The additional information provided by 3D CBCT images, such as the type of obstruction and its exact location in the three orthogonal planes, can substantially influence the management of the patient. Herein, we presented a case of a patient with sialectasis of the Stensen's duct where the cause of the dilatation was not clear. It was managed surgically with a conservative approach. The case was reported for its uncertain etiology and the use of 3D CBCT reconstruction as an adjunct in the diagnosis and management of a relatively rare lesion.

## 3D CBCT reconstruction in the management of sialiectasis of Stensen's duct



**Figure 1.** Pre-operative images of the patient. A. Well-defined swelling of the right parotid region. B. Asymmetrical smile form of the patient.



**Figure 2.** Intraoral view of the Stensen's duct orifice. A noticeable scar on the right buccal mucosa can be well appreciated (arrow).

### Case report

A 46-year-old male patient presented at Oral & Maxillofacial Surgery outpatient clinic with a

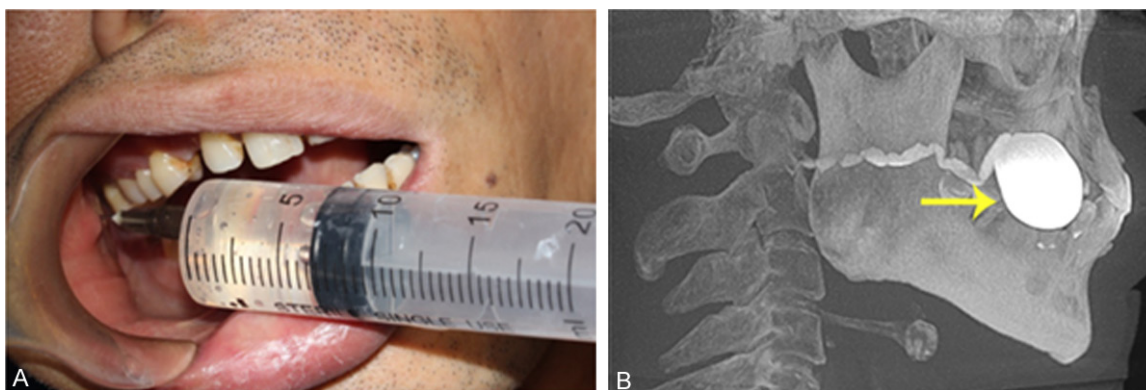
complaint of soft, painless swelling of right cheek. The patient first noticed the swelling 8 years ago, which would gradually increase in size following food intake. A watery discharge was observed from the swelling after gentle massage. Patient reported similar episodes of swelling and watery discharge over the past eight years. The patient had no history of parotid sialadenitis, facial trauma, allergies, or rheumatologic disease. However, meticulous history with patient revealed that patient was diagnosed with infection associated with sialolithiasis

of right Parotid gland 8 years ago, for which he was treated through surgical drainage and antibiotics. Following this, the patient experienced a soft, painless mass on the right cheek. He also underwent a surgery for duct diversion at some other facility, however, the mass reappeared one month post-operatively.

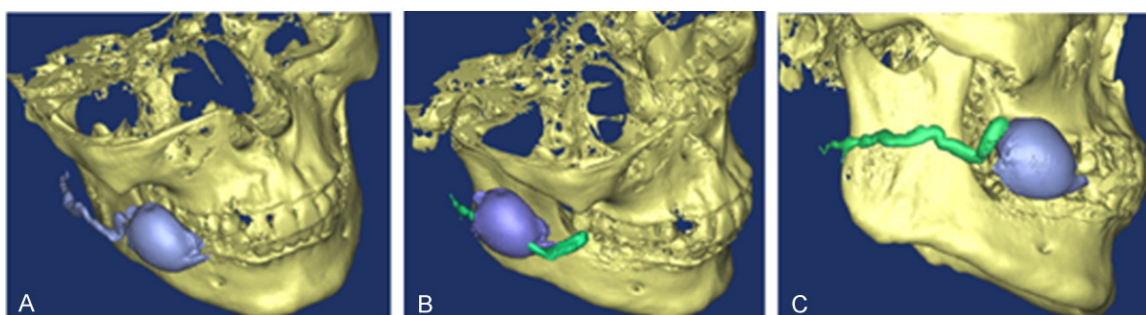
Extra-orally there was an apparent facial asymmetry with a soft palpable mass of about 2 cm in diameter on the right side of the face (**Figure 1**). The swelling extended posteriorly, approximately 2 cm from the corner of the mouth, till the mandibular molar region. Repeated massaging resulted in flabby tissue and hyperpigmentation on the right side of the face. Also, the nasolabial groove shallowed and drooping of normal smile form was noticed towards right side while smiling. However, eye closing and eyebrows raising functions were normal. No other abnormality was detected on the face. There was no cervical, submandibular, submental, or occipital lymphadenopathy.

On intra-oral examination a noticeable scar was identified, adjacent to right Stensen's duct orifice (**Figure 2**). Moreover, a significant mass was noticed on the right cheek mucosa, adjacent to the upper molar region and the degree of swelling was found to be associated with mastication. On palpation, a 2 cm sized, round, soft, fluctuating, mildly compressible, cystic mass was bimanually palpable on the right parotid region, nevertheless, palpation was negative on head position test. The cheeks were soft, well defined, and movable. The over-

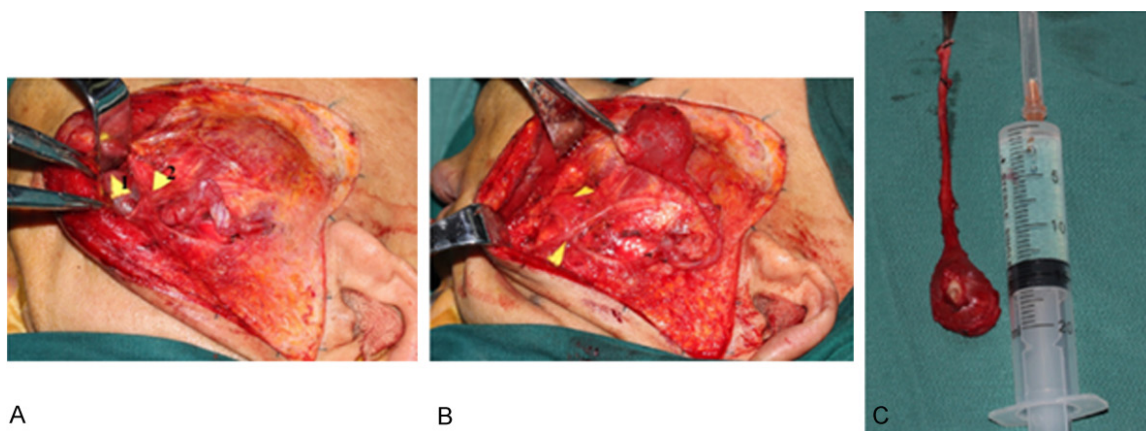
### 3D CBCT reconstruction in the management of sialectasis of Stensen's duct



**Figure 3.** A. Injection of contrast medium into ductal orifice. B. CBCT lateral projection showing radiopaque dilatation of Stensen's duct (arrow) after injection of contrast medium.



**Figure 4.** Pre-operative 3D CBCT reconstruction images showing dilatation of the Stensen's duct from different angulations (A-C).

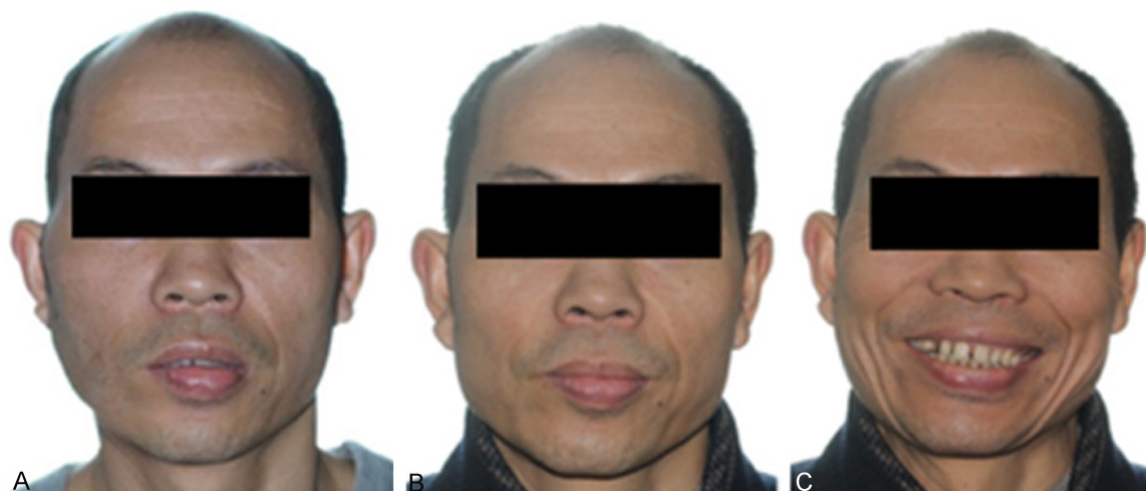

**Figure 5.** A, B. Intraoperative view showing an extensive dilatation of the Stensen's duct (yellow label 1) with preservation of the facial nerve (yellow label 2) and conservative resection of the lesion. C. A 6.5 cm long tubular resected segment, with a smooth walled cyst of 3 cm diameter at the proximal end.

lying buccal mucosa was normal in appearance. Intraoral digital compression and massage of the palpable mass for about 30 minutes, caused the release of some gas and crystalline liquid, accompanied by increased salivary discharge from the orifice of the Stensen's

duct. The ductal opening was normal in appearance, though. About 3 ml of crystalline liquid was aspirated through Fine-needle centesis which also indicated towards a cystic lesion. Blood investigations performed, were found to be within normal limits. For further investiga-

### 3D CBCT reconstruction in the management of sialectasis of Stensen's duct



**Figure 6.** A. 1 month post-operative with satisfactory healing. B. 1 year post-operative with no signs of relapse. C. 1 year post-operative showing near normal facial symmetry and smile form.

tion, CT sialography was performed, which involved meticulous probing and cannulation of the affected duct with 24G intravenous cannula, followed by an injection of 17 ml IOPAMIDOL contrast medium into the ductal system, until the patient felt fullness (**Figure 3**). No resistance was encountered while inserting the cannula. The sialogram revealed dilatation of the Stensen's duct, some distance distal to its opening into the oral cavity. In addition, 3 dimensional CBCT (KaVo 3D eXam, Germany) reconstruction images showed well-bordered, 30×30-mm wide, unilateral, tube-like dilatation of the duct running along the routes of the Stensen's duct (**Figure 4**). Furthermore, an in-office diagnostic sialendoscopy using a 1.1 mm sialendoscope was performed, however, tortuous nature of the duct and 90° turning point of the duct at the anterior border of the masseter prevented further advancement of the sialendoscope. Lastly, the ductal origin of the swelling was explained to the patient and the patient agreed to undergo an invasive procedure.

Based on pre-operative clinical and 3D CBCT findings which indicated a cystic lesion of the Stensen's duct, conservative surgical intervention was planned with facial nerve preservation and without lymph node neck dissection. After successful anesthesia intubation and following strict surgical protocol, surgery was performed. A "modified Blair" surgical incision (combined pre-auricular and retromandibular approach) was placed and full thickness mucoperiosteal flap was reflected along the parotid fascia, tak-

ing full care of Facial nerve. Resection of the dilated segment with careful preservation of the facial nerve was performed (**Figure 5A, 5B**). A 6.5 cm long tubular organization, with a smooth walled cyst of 3 cm diameter at the proximal end, having 0.1 cm thick capsular wall and containing crystalline liquid, was excised (**Figure 5C**). The intraoperative findings were suggestive of dilatation of the Stensen's duct and a normal parotid gland. Postoperative course was uneventful and one-year follow-up showed complete healing with no signs of relapse albeit, the patient is currently subjected under a long-term follow-up (**Figure 6**).

Microscopic examination of the excised segment, after staining and processing with hematoxylin and eosin (H&E) revealed extensive cystic dilatation of the Stensen's duct, wherein, the lesion was mostly lined by flattened and cuboidal epithelium with focal areas of columnar epithelium. The segment between the dilatation and orifice of the Stensen's duct was carefully examined after serial sections, however, the apparent cause of the dilatation of the duct could not be identified.

Underlying pathologies including sialocele, underlying sialolithiasis, stricture or mucus plugging can be well associated with sialectasis for the purpose of differential diagnosis.

#### Discussion

The term "sialectasis" represents an abnormal dilatation of a salivary duct. It presents itself as

### 3D CBCT reconstruction in the management of sialiectasis of Stensen's duct

recurrent painful or painless swelling which may or may not be associated with mastication. Parotid duct ectasia is a relatively rare entity characterized by the dilatation of a segment of the parotid duct, usually secondary to some kind of obstructive pathology in the duct downstream, but at times, without any obvious cause for obstruction. It usually presents with a tube-like swelling in the cheek, following the route of the Stensen's duct and may be diagnosed using sialography, ultrasonography, and CT [6, 7]. In the presented case, the ductal dilatation began about 1 cm distal to the Stensen's duct opening. Intra-operative examination of the distal undilated segment was suggestive of the absence of any intra-luminal obstruction. Besides, histopathological examination also failed to show any obstructive lesion, fibrosis or abnormality on the ductal lining.

Since only a few cases of sialiectasis have been reported in the literature, there is no unified opinion regarding its incidence, clinical manifestations, and pathophysiology. However, a review of the literature suggests that there is progressive rotting and disintegration of the alveoli which ultimately coalesce forming cysts. The debris from these cyst, pass along the duct and intermittently blocks the areas of the duct causing hypertrophy, stenosis, and duct dilatation. Repeated dilation can lead to a weakening of the ductal wall, which can be either focal or diffuse and results in permanent dilation and enlargement of the ductal caliber [8]. Evidence suggests that there are two classical pictures of sialiectasis: the first is cystic and the second is globular or saccular. The present case can be considered as the Cystic type where the alveoli coalesce and form large spaces together with the duct, stenosis, and dilatation.

On the basis of patient's previous history, two potential reasons can be associated with the stasis of salivary secretion. Firstly, the mucosal scar, which might have resulted from the previous incision & drainage or the duct diversion procedures. The exact reason for which is unknown. Secondly, narrow ductal orifice, which can also result in dilatation. These two reasons might have resulted in permanent dilation of the segment without any symptoms of pain. Besides, since the patient could massage out salivary secretions, there was no microbial colonization of the fluid which could lead to

infection and pain. Further, post-prandial swelling in the presented case can be attributed to secretomotor stimulation while eating.

Detailed imaging can play a significant role in the diagnosis and treatment planning of salivary gland diseases. In recent past, the rapid development of digital technology has led to significant advancement and comprehensive changes in oral health care equipment, such as sialendoscopy and 3D CBCT. Sialendoscopy offers a minimally invasive option that allows for a direct visualization of intraductal pathology i.e. visualization of calculi, mucosal plugs, foreign bodies and polyps for the diagnosis and management of chronic inflammatory disorders of the salivary glands and offers the option of gland and function preservation [9, 10]. However, in the present case, tortuous nature and sharp turning point (90 degrees) of the duct at the anterior border of the masseter prevented further advancement of the sialendoscope. Hence direct intraductal visualization could not be possible.

Since the introduction of 3D cone-beam CT (CBCT) to dentistry in 1998 [11], its application has become routine for pre-surgical, dental-implant, and third-molar assessments. Besides, CBCT has played a substantial role in the head and neck and dento-maxillofacial diagnosis over the years. The CBCT software provides various processed images such as multiplanar reconstruction, volume rendering, cross-sectional, and partial panoramic images [12]. Due to the isotropic voxels, the images of the anatomic structures can be reconstructed clearly and accurately in any plane [13]. In addition, the 3-dimensional visualization of the salivary duct system through CBCT helps in the diagnosis of undetected intra-glandular pathologies [14]. An interesting study by *Li* suggested that sialographic technique could be improved by the combination of sialography and CBCT, especially by 3D formatting [15]. Nevertheless, potential CBCT application such as 3D reconstruction in the diagnosis and management of salivary gland disorders has received little attention of the clinicians. *Drage* and *Brown* in their series of cases concluded that CBCT sialography was superior to conventional sialography [16]. Moreover, they suggested that 3D reconstruction could be performed and viewed from any direction and in any slice thickness,

## 3D CBCT reconstruction in the management of sialiectasis of Stensen's duct

and from which cross-sectional slices might be obtained in any direction. This might prove useful for demonstrating areas of complex anatomy and for the assessment of orthodontic treatment plan as well. Further, in addition to designing a surgical guide for dental implant surgery, 3D reconstruction can also help in simulation and navigation of an oral and maxillofacial surgery [17].

An accurate 3D reconstruction image of the maxillofacial structure is essential to make a diagnosis and to establish a treatment plan. In the presented case, pre-operative CBCT acquisitions were obtained which allowed proper visualization and localization of the lesion in addition to selecting best approach for surgical intervention. The surgical approach was based on segmentation and 3D calculations obtained from CBCT images. 3D CBCT reconstruction images were useful to determine the locational relationship between lesion and Stensen's duct orifice in addition to demonstrating the maximum size of the dilated segment. Moreover, it also helped in identifying the exact turning point of the duct i.e. the duct turned 90° into the mouth from the anterior border of masseter muscle. As far as management is concerned, dilatation of the Stensen's duct should be individualized according to the patient's symptom and the extent of the dilatation, therefore a comprehensive treatment plan was designed for successful resolution of this condition. Although previous studies have shown comparable results with sialendoscopy assisted management for slight dysfunction of the gland, and more aggressive management [1, 4] including superficial parotidectomy with excision of the duct [8, 18-20] for the sialiectasis secondary to long-standing chronic parotitis. However in the presented case, since the cause of dilation was unclear, a more conservative approach with careful preservation of Facial nerve was selected based on the location of the lesion, as observed in 3D reconstruction images. Therefore we suggest that surgical modality should be planned as follows.

1. If the lesion involves hilum and turning point-duct resection;
2. If the lesion is large and located between turning point and corner of mouth duct resection or duct ligation;
3. If the lesion is small and located between turning point and corner of mouth dilated segment resection or duct diversion or duct anastomosis.

### Conclusion

In the present case, the diagnosis and management of the obstructive salivary gland disease were based on 3D image interpretation. Currently, various management options are available, and several of these are minimally invasive and radiologically guided, however, their success depends on having adequate and accurate information provided by diagnostic imaging. Therefore, it is imperative that 3D imaging report not only a detailed description of size, shape, number, and location of the obstruction but also its effect on the glandular structures. In conclusion, this increased need for detailed diagnostic information highlights the importance of 3D reconstruction imaging, not only in diagnosis but in patient management, as well.

### Acknowledgements

Project supported by The Program for Innovation Team Building at Institutions of WHO Education in Chongqing. Project supported by Program for Innovation Team Building at Institutions of Higher Education in Chongqing in 2013. Project Supported by the National Clinical Key Specialty Constitution Program of China for 2013-2014.

### Disclosure of conflict of interest

None.

**Address correspondence to:** Jiang Deng, Chongqing key Laboratory of Oral Diseases and Biomedical Sciences, Chongqing, People's Republic of China; Department of Oral and Maxillofacial Surgery, The Affiliated Hospital of Stomatology, Chongqing Medical University, Chongqing 401147, People's Republic of China. Tel: +8613883970905; E-mail: kqjiangdeng@163.com

### References

- [1] Yoon YH, Rha KS, Choi JW and Koo BS. Sialiectasis of Stensen's duct: an unusual case of recurrent cheek swelling. *Eur Arch Otorhinolaryngol* 2009; 266: 573-576.
- [2] Alho OP, Kristo A, Luotonen J and Autio-Harminen H. Intraductal papilloma as a cause of a parotid duct cyst. A case report. *J Laryngol Otol* 1996; 110: 277-278.
- [3] Laudenbach P, Fain J and Canet E. [Duct cysts of the parotid. Complications of dilated Stensen's duct]. *Rev Stomatol Chir Maxillofac* 1990; 91 Suppl 1: 78-81.

### 3D CBCT reconstruction in the management of sialiectasis of Stensen's duct

- [4] Baurmash HD. Sialiectasis of Stensen's duct with an extraoral swelling: a case report with surgical management. *J Oral Maxillofac Surg* 2007; 65: 140-143.
- [5] Dreiseidler T, Ritter L, Rothamel D, Neugebauer J, Scheer M and Mischkowski RA. Salivary calculus diagnosis with 3-dimensional cone-beam computed tomography. *Oral Surg Oral Med Oral Pathol Oral Radiol Endod* 2010; 110: 94-100.
- [6] Mandel L. The grossly dilated Stensen's duct: Case reports. *J Oral Maxillofac Surg* 2007; 65: 2089-2094.
- [7] Ngu RK, Brown JE, Whaites EJ, Drage NA, Ng SY and Makdissi J. Salivary duct strictures: nature and incidence in benign salivary obstruction. *Dentomaxillofac Radiol* 2007; 36: 63-67.
- [8] Lohia S and Joshi AS. Idiopathic sialiectasis of the Stensen's duct treated with marsupialisation. *BMJ Case Rep* 2013; 2013.
- [9] Rzymaska-Grala I, Stopa Z, Grala B, Golebiowski M, Wanyura H, Zuchowska A, Sawicka M and Zmorzynski M. Salivary gland calculi-contemporary methods of imaging. *Pol J Radiol* 2010; 75: 25-37.
- [10] Hernandez S, Busso C and Walvekar RR. Parotitis and Sialendoscopy of the parotid gland. *Otolaryngol Clin North Am* 2016; 49: 381-393.
- [11] Mozzo P, Procacci C, Tacconi A, Martini PT and Andreis IA. A new volumetric CT machine for dental imaging based on the cone-beam technique: preliminary results. *Eur Radiol* 1998; 8: 1558-1564.
- [12] Abdel-Wahed N, Amer ME and Abo-Taleb NS. Assessment of the role of cone beam computed sialography in diagnosing salivary gland lesions. *Imaging Sci Dent* 2013; 43: 17-23.
- [13] Yajima A, Otonari-Yamamoto M, Sano T, Hayakawa Y, Otonari T, Tanabe K, Wakoh M, Mizuta S, Yonezu H, Nakagawa K and Yajima Y. Cone-beam CT (CB Throne) applied to dentomaxillofacial region. *Bull Tokyo Dent Coll* 2006; 47: 133-141.
- [14] Kroll T, May A, Wittekindt C, Kahling C, Sharma SJ, Howaldt HP, Klusmann JP and Streckbein P. Cone beam computed tomography (CBCT) sialography-an adjunct to salivary gland ultrasonography in the evaluation of recurrent salivary gland swelling. *Oral Surg Oral Med Oral Pathol Oral Radiol* 2015; 120: 771-775.
- [15] Li B, Long X, Cheng Y and Wang S. Cone beam CT sialography of Stafne bone cavity. *Dentomaxillofac Radiol* 2011; 40: 519-523.
- [16] Drage NA and Brown JE. Cone beam computed sialography of sialoliths. *Dentomaxillofac Radiol* 2009; 38: 301-305.
- [17] Eggers G, Muhling J and Hofele C. Clinical use of navigation based on cone-beam computer tomography in maxillofacial surgery. *Br J Oral Maxillofac Surg* 2009; 47: 450-454.
- [18] Yoruk O, Kilic K and Kantarci M. "Mustache sign" due to Stensen duct dilation. *Oral Surg Oral Med Oral Pathol Oral Radiol* 2013; 116: e514-516.
- [19] Witt RL. The incidence and management of siaoloele after parotidectomy. *Otolaryngol Head Neck Surg* 2009; 140: 871-874.
- [20] Wang Y, Yu GY, Huang MX, Mao C and Zhang L. Diagnosis and treatment of congenital dilatation of Stensen's duct. *Laryngoscope* 2011; 121: 1682-1686.