

Original Article

Effect of sheep tail fat on the knee joint cartilage injury induced in rats with formalin

Ferda Keskin Cimen¹, Nizamettin Kockara², Murat Turkoglu³, Cihat Dunder³, Nihal Cetin⁴, Bahadir Suleyman⁴, Abdulkadir Coban⁵, Oguzhan Yerali⁶, Ismail Malkoc⁷, Halis Suleyman⁴

¹Department of Pathology, Mengucek Gazi Education and Research Hospital, Erzincan 24030, Turkey; Departments of ²Orthopedics and Traumatology, ⁴Pharmacology, ⁵Biochemistry, Faculty of Medicine, Erzincan University, Erzincan 24030, Turkey; ³Biota Laboratories, R&D Center, Sancaktepe, Istanbul 34785, Turkey; ⁶Department of Medical Genetics, Erzurum Training and Research Hospital, Erzurum 25240, Turkey; ⁷Department of Anatomy, Faculty of Medicine, Ataturk University, Erzurum 25240, Turkey

Received December 21, 2016; Accepted March 14, 2017; Epub May 15, 2017; Published May 30, 2017

Abstract: Background: The effect of sheep tail fat (STF) on the damage induced in the knee articular joint with formalin was investigated and evaluated from the biochemical, gene expression, histopathological aspects in comparison with an extract consisting of glucosamine hydrochloride, chondroitin sulfate, methylsulfonylmethane, *Harpagophytum procumbens* and bromelain (GCMHB). Material and methods: The animals were divided into four groups: The first group received formalin injection to the knee joint as FCG control. The second group received 500 mg/kg STF + formalin (STFF). The third group was given 500 mg/kg GCMHB + formalin (GCMHBF). The fourth group was the healthy group (HG). The STF and GCMHBF were administered at 500 mg/kg dose. After 1 h of the STF and GCMHB administration 0.2 ml 1% formalin was injected into the knee joints of all rats except the HG group. The STF and GCMHB were given once a day at the specified doses over 30 days. Results: It was observed that, STF and GCMHB prevented the increase of IL-1 β , TNF- α and COX-2 gene expressions in the cartilage tissue after formalin damage. In addition, STF and GCMHB improved the histopathological disturbances in the cartilage tissue caused by formalin. Conclusion: Since it is an inexpensive and easily available natural product, Sheep Tail Fat could be used in clinical practice along with the other medicines to prevent cartilage damage.

Keywords: Sheep tail fat, biochemical processes, cartilage damage, gene expression, knee joint

Introduction

As is known, cartilage tissue is the most damaged tissue in osteoarthritis [1]. Osteoarthritis is a disease characterized by the progressive cartilage degeneration and local inflammatory manifestations [1, 2]. Osteoarthritis is known to be a pathological condition which causes physical disability [3]. Cytokines have been reported to play a crucial role in the pathogenesis of osteoarthritis and to initiate breakdown chain in the cartilage [4]. In addition, proinflammatory cytokines such as interleukin-1 (IL-1 β) and tumor necrosis factor alpha (TNF- α) have been reported to lead to the oxidative stress reactions in the cartilage tissue in osteoarthritis [5]. IL-1 β and TNF- α have been reported to cause articular damage by increasing the synthesis of metalloproteinases and plasminogen synthesis and, inhibition of the type 2 collagen

synthesis and chondrocyte replication in the matrix [6, 7]. This information suggests that osteoarthritis is a degenerative articular disease progressing with inflammation. Today pharmacologic and non-pharmacologic treatment methods are used for the treatment of osteoarthritis [8, 9]. However, many patients reject the non-pharmacologic (surgical) treatment option [10]. Medical treatment based on pharmacology is limited due to the cardiovascular, gastric and other side effects [11]. Therefore, more effective, reliable and inexpensive drugs are needed. Thus, recent studies have focused on the natural products [12, 13]. There is information in the literature about the use of the natural products such as vegetable or animal oils in knee joint pain and rheumatoid arthritis [14, 15]. Sheep tail fat (STF) that we tested its efficacy on the cartilage damage contains C_{16:0} (palmitic acid 31.5%), C_{18:0} (stearic acid 30%),

Effect of sheep tail fat on the cartilage injury

C_{18:1} (oleic acid 28%) and C_{14:0} (myristic acid 4%) [16]. Numerous studies have argued that palmitic, oleic, linoleic, stearic and myristic acids create antiinflammatory effects by the inhibition of IL-1 β , TNF- α and cyclooxygenase-2 (COX-2) [17-19]. This information suggest that STF may be useful in the cartilage damage due to osteoarthritis. In the previous study, it was demonstrated with the biochemical, gene expression and histopathological findings that formalin produced damage in the knee joint of rats [20]. There was not any information in the literature about the protective effect of STF on the articular cartilage damage. Therefore, objective of the present study was to investigate the effect of sheep tail fat (STF) on the damage induced in the knee articular joint with formalin, from the biochemical, gene expression and histopathological aspects and to evaluate the results in comparison with the formula (GCMHB) which consisted of glucosamine hydrochloride (750 mg), chondroitin sulfate (600 mg), methylsulfonylmethane (600 mg), *Harpagophytum procumbens* (97.5 mg) and bromelain (97.5 mg).

Material and methods

Animals

A total of 24 albino Wistar male rats weighing between 260 and 280 g was used in the experiment. All the rats were supplied by the Ataturk University, Experimental Application and Research Center. The animals were housed and fed in groups at normal room temperature (22°C) under appropriate conditions in the laboratory of the department of pharmacology. The protocols and procedures were approved by the local Animal Experimentation Ethics Committee. (Date: 23.10.2015; Meeting No.: 8/157).

Chemical agents

In the experiment, sheep tail fat and Nutraxin Atroflex which is the commercial form of GCMHB were obtained from BIOTA (Turkey), thiopental sodium from i.E ULAGAY, and formalin from the department of pathology.

Experimental groups

The animals were divided into four groups which received formalin injected to the knee joint as FCG controls, 500 mg/kg STF + forma-

lin as STFF, 500 mg/kg GCMHB + formalin as GCMHBF and the healthy group (HG).

Experimental procedure

Effects of STF and GCMHBF on the cartilage injury induced in the rat knee joint with formalin: STFF group (n=6) was administered STF 500 mg/kg and GCMHBF group (n=6) GCMHB mixture of 500 mg/kg doses with gavage. After 1 hour of the STF and GCMHB administration, 0.2 ml 1% formalin was injected into the knee joints of all the rats except the HG group [20]. STF and GCMHB were given once a day at the specified doses over 30 days. At the end of this period, the rats were sacrificed with high-dose thiopental sodium anesthesia. The knee joints of the rats were removed and the amounts of MDA and tGSH, and the gene expressions of IL- β , TNF- α and COX-2 were measured. The articular cartilages were histopathologically examined. All the results obtained from the experiment were evaluated statistically.

Biochemical analysis of the cartilage tissue

Preparation of the samples: For MDA analysis, the tissue was homogenized with 9 mL 1.15% KCl buffer, while for tGSH analysis the tissues collected were washed with isotonic sodium chloride solution, added on the pH=7.5 phosphate buffer and homogenized on the ice cold medium. The mixture was centrifuged at 10,000 rpm and + 4°C for 15 minutes. The supernatant was used as the analysis sample.

Determination of MDA: Based on the method developed by Ohkawa H. et al., the MDA measurement was performed spectrophotometrically based on the pink colored complex created by thiobarbituric acid (TBA) at a high temperature (95°C) at 532 nm [21].

Determination of tGSH: According to the method reported by Sedlak J. et al., DTNB [5,5'-Dithiobis (2-nitrobenzoic acid)] in the measurement environment is a disulfide chromogen and DTNB is easily reduced by the sulfhydryl group of compounds. The yellow color formed during the reduction was is spectrophotometrically measured at 412 nm [22].

Gene expression of IL-1 β , TNF- α and COX-2

RNA isolation: The RNA was isolated from the homogenized cartilage samples using the Roche Magna Pure Compact LC device (Mann-

Effect of sheep tail fat on the cartilage injury

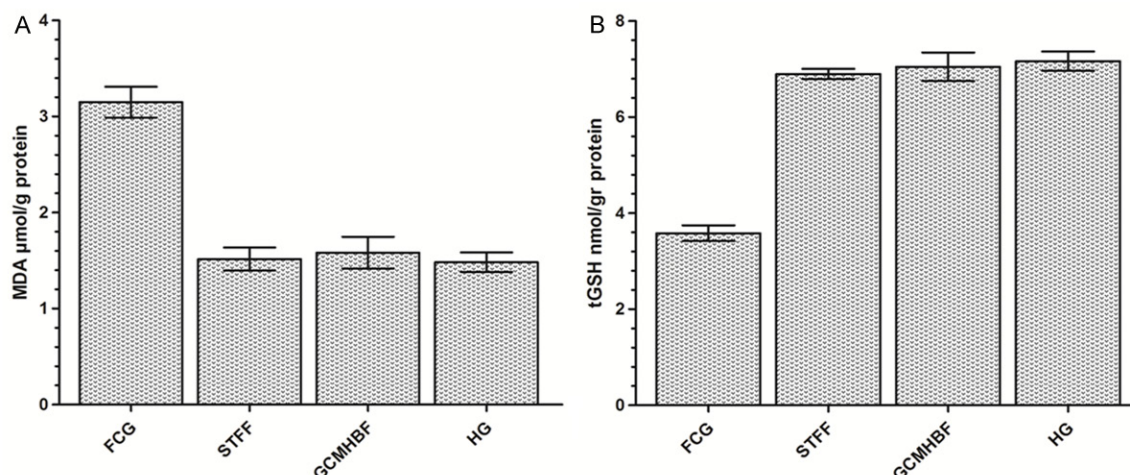


Figure 1. A. Distribution of MDA levels for each group (n=6). B. Distribution of tGSH levels for each group (n=6).

heim-Germany) with MagNA Pure LC RNA Kit (Roche Diagnostics). The quantity and quality of the isolated RNA were assessed with a nucleic acid measurement device (Maestro, Nano). 50 μ L of RNA samples was stored at -80°C .

cDNA synthesis: cDNA was synthesized from the isolated RNA samples using the Transcriptor First Strand cDNA synthesis kit (Roche Diagnostics). For each subject, 1 μ L ddH₂O, 10 μ L RNA and 2 μ L Random Primer were combined and incubated in a Thermal Cycler for 10 min at 65°C . After the incubation, 4 μ L Reaction Buffer, 0.5 μ L RNAase, 2 μ L Deoxynucleotide Mix, and 0.5 μ L Reverse Transcriptase were added and the mixture was incubated for 10 min at 25°C , 30 min at 55°C , 5 min at 85°C , then held at 4°C .

Quantitative gene expression evaluation by real-time polymerase chain reaction (RT-qPCR): For each cDNA sample, gene expression of IL-1 β , TNF- α and COX-2 the reference gene (G6PD) was analyzed using the Roche LightCycler 480 II Real-Time PCR instrument (Mannheim-Germany). PCR reactions were in a final volume of 20 μ L: 5 μ L cDNA, 3 μ L distilled water, 10 μ L LightCycler 480 Probes Master (Roche Diagnostics) and 2 μ L primerprobe set (Real-Time Ready single assay-Roche). Cycle conditions of the relative quantitative PCR (qPCR) were pre-incubation at 95°C for 10 min, followed by 45 amplification cycles of 95°C for 10 s, 6°C for 30 s, 72°C for 1 s, followed by cooling at 40°C for 30 s. qPCR analysis and calculation of quantification cycle (Cq) values for Relative

Quantification were performed with the Light-Cycler 480 Software, Version 1.5 (Roche Diagnostics). Relative quantitative amounts were calculated by dividing the target genes by the expression level of the reference gene. Reference gene was used for normalization of target gene expression.

Histopathological examination

The entire knee joint which was properly dissected from the rats was fixed with 10% neutral buffered formalin for 3 days and then decalcified with 10% formic acid for 5 days. After the routine tissue process, section of 5 μ m thickness were prepared from the paraffin blocks and these sections were stained with hematoxylin-eosin (H&E) in order to evaluate general histomorphology. All the slides were evaluated under a light microscope by a pathologist who was blind to the treatment protocols and the photographs were taken. Histopathological sections of the joint cartilage were evaluated in terms of the cartilage surface regularity, loss of chondrocytes, chondrocyte disorganization, chondrocyte degeneration, osteophyte formation, subchondral fibrosis and cyst formation.

Statistical analysis

Data from the experiments were expressed as the "mean \pm standard deviation" ($\bar{x} \pm \text{SD}$). Significance of the difference between groups was defined using One-way ANOVA test followed by Fischer *post hoc* LSD (least significant differences). All the statistical analyses were per-

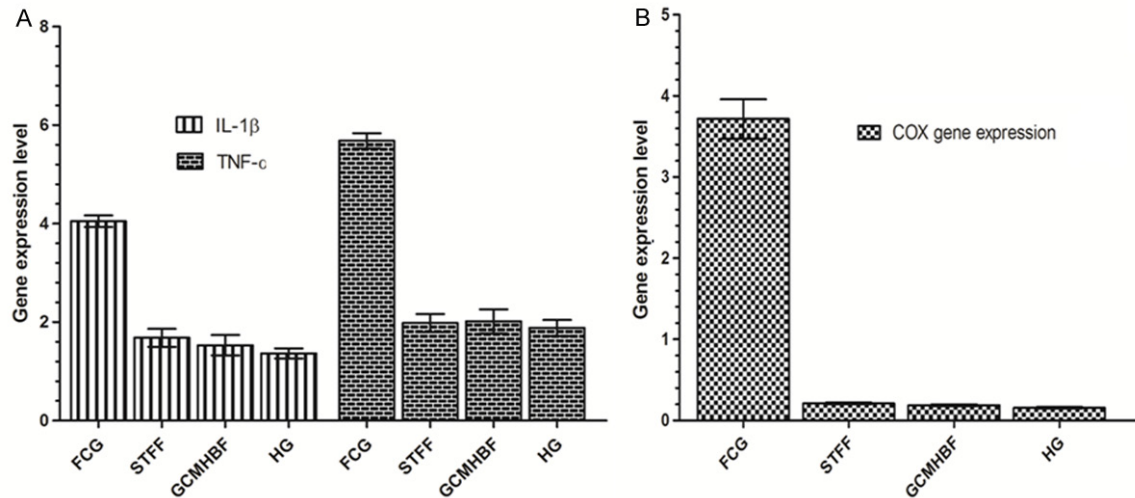


Figure 2. A. Distribution of IL-1 β and TNF- α levels for each group (n=6). B. Distribution of COX-2 levels for each group (n=6).

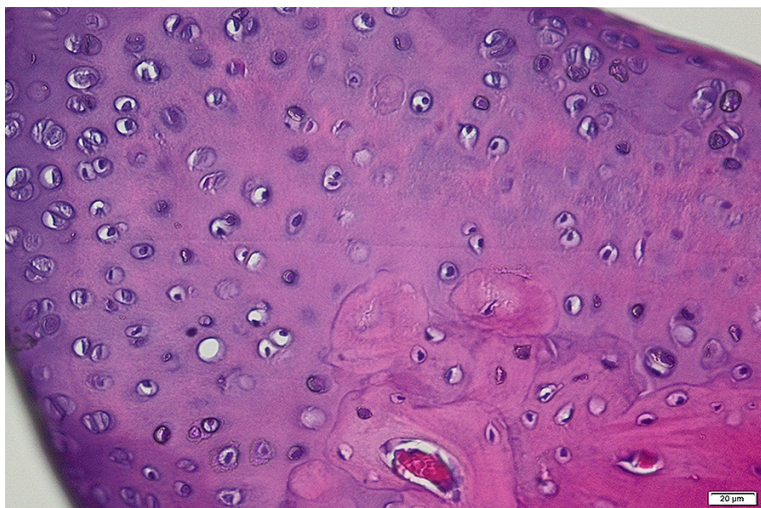


Figure 3. Cartilage section of the HG group (H&E \times 100).

formed with “SPSS for Windows 18.0” statistical software and $p < 0.05$ was considered as statistically significant.

Results

Biochemical results

The amounts of MDA and tGSH: The amount of MDA was significantly higher in the knee articular cartilage of the FCG groups in which formalin was injected than in the STFF, GCMHBF and HG groups ($p < 0.0001$) (**Figure 1A**). The difference among the STFF, GCMHBF and HG groups for MDA was statistically not significant and, The amount of tGSH was higher in the FCG

group when compared to STFF, GCMHBF and HG groups ($p < 0.0001$). However, no significant difference was found among the STFF, GCMHBF and HG groups for tGSH (**Figure 1B**).

Gene expression results

IL-1 β and TNF- α gene expressions: IL-1 β and TNF- α gene expressions were significantly increased in the knee joint cartilage of the formalin group compared to the STFF, GCMHBF and healthy groups ($p < 0.0001$). The levels of IL-1 β and TNF- α gene expression

were very close in the cartilage tissues of the STFF, GCMHBF and HG groups (**Figure 2A**).

COX-2 gene expression: STFF and GCMHBF prevented the increase of COX-2 gene expression with formalin. The level of COX-2 gene expression was almost the same with the levels of groups administered STFF and GCMHBF (**Figure 2B**).

Histopathological results

Cartilage tissue of the healthy group: In the **Figure 3**, normal histomorphologic appearance is monitored in the sections of articular cartilage with the H&E staining.

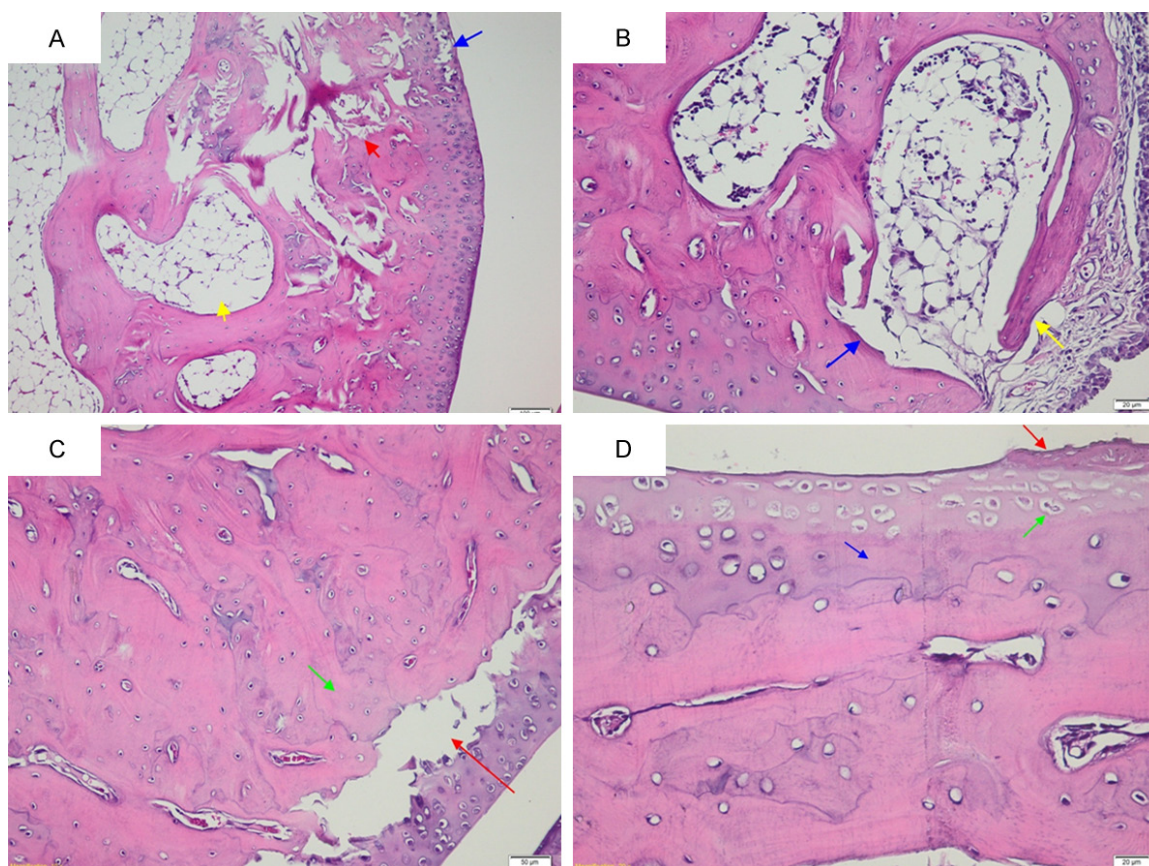


Figure 4. A. Cartilage section of the FCG group (H&E×100). B. Cartilage section of the FCG group (H&E×200). C. Cartilage section of the FCG group (H&E×200). D. Cartilage section of the FCG group (H&E×400).

Cartilage tissue of the FCG group: In the FCG group in which formalin was injected, irregularity in the cartilage surface and marked loss of chondrocytes (blue arrow), tissue damage in the subchondral distance (red arrow) and cyst formation (yellow arrow) are observed (**Figure 4A**). In addition, osteophyte formation (yellow arrow), inflammatory granulation tissue and cystic structure (blue arrow) are distinguished (**Figure 4B**). Again in this group, fragmentation in the cartilage (red arrow) and, sclerosis and congestion in the subchondrial area were observed (green arrow) (**Figure 4C**). Formalin was found to cause cartilage surface damage (red arrow), chondrocyte necrosis (green arrow) and cartilage degeneration (blue arrow) (**Figure 4D**).

Cartilage tissue of the STFF group: No irregular cartilage surface could be found in the STFF group which received STF (red arrow). There were not observed osteophyte formation, inflammatory granulation tissue, cartilage fragmentation, congestion and chondrocyte necro-

sis. There were not sclerosis and cyst formations in the subchondrial area (green arrow). However, very few number of the mild loss of chondrocytes and chondrocyte degeneration (yellow arrow) were observed (**Figure 5**).

Cartilage tissue of the GCMHB group: Irregular cartilage surface could not be found in the GCMHB group (green arrow). No pathological finding was encountered except a very few reduction in the number of chondrocytes and mild degeneration (red arrow). No cyste formation and sclerosis were observed in the subchondrial area (yellow arrow) (**Figure 6**).

Discussion

In the present study, effect of STF on the knee joint cartilage damage induced with formalin was investigated. In our previous study, GCMHB was shown to prevent the cartilage damage. [20]. Formalin is known to be used in the osteoarthritis model and creating cartilage damage [20, 23]. In this study, we investigated the chon-

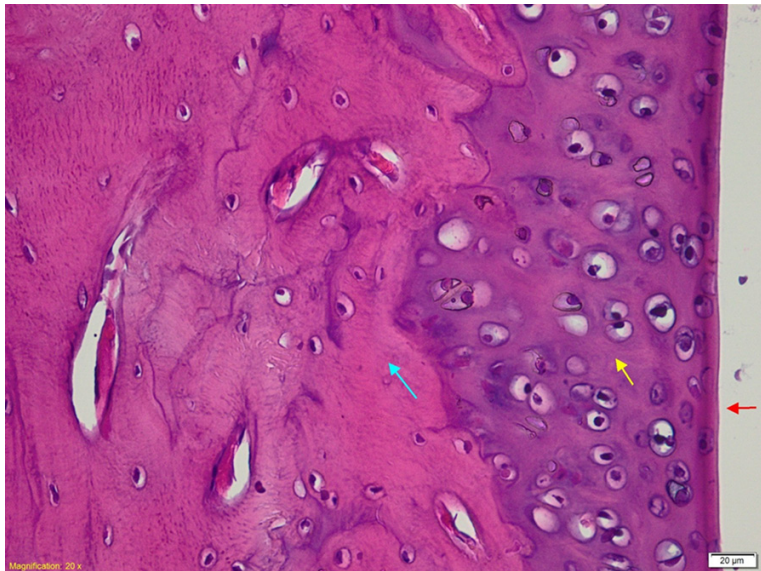


Figure 5. Cartilage section of the STFF group (H&E×400).

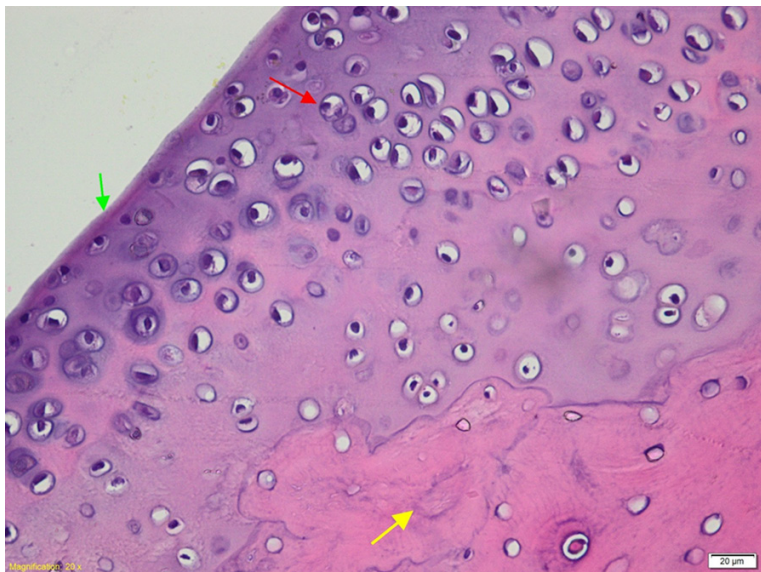


Figure 6. Cartilage section of the GCMHBF group (H&E×400).

droprotective effect of STF, the MDA was found to significantly increase and tGSH decreased in the knee joint cartilage in which formalin had been injected. It is proposed that oxidant/antioxidant balance is maintained with the superiority of antioxidants under physiological conditions [24]. Impairment of this balance in favour of oxidants leads to the tissue damage and termed as oxidative stress [25]. This information suggests that the increase of MDA in the articular tissue may lead to tissue damage which can be prevented with antioxidant thera-

py. Guo JS et al. reported that decreasing the amount of MDA is helpful in the treatment of osteoarthritis [26]. The high levels of tGSH have been reported to be crucial for the protection of the articular tissue [20]. Recent studies indicate that oxidative stress is one of the major components of osteoarthritis; furthermore, excessive oxidant production has been reported to cause functional and structural disturbances in the cartilage tissue when it exceeds the antioxidant defence capacity of the chondrocytes [27].

In the present study, proinflammatory gene expression such as IL-1 β and TNF- α was found to be stimulated in the FCG group in which MDA was found to be higher and tGSH lower. Similarly, previous studies have reported that IL-1 β increases the risk for osteoarthritis [28]. Kapoor M. et al., stated that the levels of IL-1 β were high in the synovial fluid, synovial membrane and subchondrial bone tissue of the patients with osteoarthritis [29]. In a recent study, TNF- α is underlined to be responsible of the chondrocyte damage related to osteoarthritis [30]. These increased cytokines are known to initiate the oxidative stress reaction in the cartilage tissue [5].

In addition, these cytokines have been proposed to increase COX-2 gene expression and to cause serious deterioration in the cartilage tissue [31]. COX-2 is an enzyme responsible for the synthesis of these proinflammatory prostaglandins, suggesting that its inhibition may be useful in the treatment of osteoarthritis. Giunta S. et al., demonstrated that PACAP substance that inhibits COX-2 protects the cartilage tissue against the damage in the tissue with osteoarthritis [32]. This information explains that our experimental results are consistent with the literature.

STF which was used in our study was found to significantly prevent IL-1 β , TNF- α , COX-2 expression and increase in the amount of MDA. Sheep fat is the only oil source containing important fatty acids in nutrition in many parts of the world [33]. Although there is not any study in the literature about the beneficial effects of STF [33], numerous studies have been conducted about the beneficial effects of its fatty acid contents which their antioxidant activities have been experimentally shown [17]. Karimi E. et al., reported that the herbal extract containing palmitic, palmitoleic, stearic, oleic and linoleic fat acids have antioxidant features [34]. As stated above; palmitic, oleic, linoleic fat acids create an antiinflammatory effect by the inhibition of IL-1 β and TNF- α [18]. There are several studies reporting that myristic and linoleic fatty acids exhibit antiinflammatory activity by the inhibition of COX-2 [17, 35]. Animal oils containing oleic, palmitic and linoleic fatty acids are known to be locally used against inflammation [14]. GCMHB which we compared its chondroprotective effect with STF prevented IL-1 β , TNF- α , COX-2 expression and the increase of MDA and decrease of tGSH with formalin in the cartilage tissue at almost the same level with STF. In addition it was shown that GCMHB creates antioxidant effect and inhibits IL-1 β and TNF- α expression [20]. Serious histopathologic findings including irregularity in the cartilage surface, marked loss of chondrocytes, tissue damage in the subchondrial distance, cyste formation, inflammatory granulation tissue, fragmentation in the cartilage, sclerosis and congestion in the subchondrial area, cartilage chondrocyte necrosis and cartilage degeneration were observed in the FCG group in which MDA, IL-1 β , TNF- α and COX-2 levels were found high. Osteoarthritis signs such as the cartilage disorganization, irregularity, loss of chondrocytes, subchondrial fibrosis and cyste formation were seen in the knee joint tissue in which formalin was injected [20]. Ostergaard M. et al. stated that, both inflammation and granulation tissue occur in osteoarthritis [36]. Necrosis which is seen in osteoarthritis has been proposed to be induced by cytokines [37]. In addition; subchondrial sclerosis, chondrocyte necrosis, cartilage fragmentation and tissue damage in the subchondrial distance were histopathologically demonstrated in an animal osteoarthritis model [38].

However, no pathological findings were observed in the STFF and GCMHBF in which MDA,

IL-1 β , TNF- α and COX-2 were significantly inhibited except a very slight loss of chondrocytes and chondrocyte degeneration. As it was mentioned in the introduction section of this article, there is not any literature on the beneficial effects of STF. Nevertheless, fatty acids in the STF contents have been reported to show antioxidant activity and inhibit proinflammatory cytokines [17-19]. In our previous study, GCMHB was found to largely improve the histopathological signs caused by formalin [20].

Formalin injection in the knee joint caused chondrotoxicity with oxidative stress. STF and GCMHB showed chondroprotective activity almost at the same level. STF may be more advantageous compared to the other medicines, because it is an inexpensive and easily available natural product.

Disclosure of conflict of interest

None.

Address correspondence to: Dr. Nihal Cetin, Department of Pharmacology, Faculty of Medicine, Erzinan University, Erzinan 24030, Turkey. Tel: +90-446-2261818; Fax: +90-446-2261819; E-mail: nihalcetin84@gmail.com

References

- [1] Haugh AJ. Pathology of osteoarthritis. Philadelphia: Lea & Febiger; 1993.
- [2] Suri S and Walsh DA. Osteochondral alterations in osteoarthritis. *Bone* 2012; 51: 204-211.
- [3] Cooper C. Rheumatology. London: Mosby; 1997.
- [4] Buckwalter JA, Saltzman C and Brown T. The impact of osteoarthritis: implications for research. *Clin Orthop Relat Res* 2004; 427: S6-S15.
- [5] Henrotin Y, Deby-Dupont G, Deby C, Franchimont P and Emerit I. Active oxygen species, articular inflammation and cartilage damage. In: editors. Free radicals and aging. Springer; 1992. pp. 308-322.
- [6] Mankin H and Brandt K. Pathogenesis of osteoarthritis. *Kelley's Textbook of Rheumatology* 1997; 2: 1391-1407.
- [7] Pelletier JP, Martel-Pelletier J and Howell D. Etiopathogenesis of osteoarthritis. In: editors. Arthritis and allied conditions. A textbook of rheumatology. Philadelphia: William & Wilkins; 1997. pp. 1969-1984.
- [8] Austrian JS, Kerns RD and Carrington Reid M. Perceived barriers to trying self-management approaches for chronic pain in older persons. *J Am Geriatr Soc* 2005; 53: 856-861.

- [9] Parmet S, Lynm C and Glass RM. Osteoarthritis of the knee. *JAMA* 2003; 289: 1068-1068.
- [10] Ibrahim SA. Racial variations in the utilization of knee and hip joint replacement: an introduction and review of the most recent literature. *Curr Orthop Pract* 2010; 21: 126.
- [11] Sale JE, Gignac M and Hawker G. How "bad" does the pain have to be? A qualitative study examining adherence to pain medication in older adults with osteoarthritis. *Arthritis Rheum* 2006; 55: 272-278.
- [12] Khodabakhsh P, Shafaroodi H and Asgarpanah J. Analgesic and anti-inflammatory activities of *Citrus aurantium* L. blossoms essential oil (neroli): involvement of the nitric oxide/cyclic-guanosine monophosphate pathway. *J Nat Med* 2015; 69: 324-331.
- [13] Shoara R, Hashempur MH, Ashraf A, Salehi A, Dehshahri S and Habibagahi Z. Efficacy and safety of topical *Matricaria chamomilla* L. (chamomile) oil for knee osteoarthritis: a randomized controlled clinical trial. *Complement Ther Clin Pract* 2015; 21: 181-187.
- [14] Schmeda-Hirschmann G, Delporte C, Valenzuela-Barra G, Silva X, Vargas-Arana G, Lima B and Feresin GE. Anti-inflammatory activity of animal oils from the Peruvian Amazon. *J Ethnopharmacol* 2014; 156: 9-15.
- [15] Srivastava JK, Shankar E and Gupta S. Chamomile: a herbal medicine of the past with a bright future (Review). *Mol Med Rep* 2010; 3: 895-901.
- [16] Ünsal M, Gökalp H and Nas S. Basic chemical characteristics of fresh, non-packed and vacuum-packed sheep-tail and tail-fat stored frozen for different periods. *Meat Sci* 1995; 39: 195-204.
- [17] Henry GE, Momin RA, Nair MG and Dewitt DL. Antioxidant and cyclooxygenase activities of fatty acids found in food. *J Agric Food Chem* 2002; 50: 2231-2234.
- [18] Hua KF, Hsu HY, Su YC, Lin IF, Yang SS, Chen YM and Chao LK. Study on the antiinflammatory activity of methanol extract from seagrass *Zostera japonica*. *J Agric Food Chem* 2006; 54: 306-311.
- [19] Shah AS and Alagawadi KR. Anti-inflammatory, analgesic and antipyretic properties of *Thespesia populnea* Soland ex. Correa seed extracts and its fractions in animal models. *J Ethnopharmacol* 2011; 137: 1504-1509.
- [20] Ucuncu Y, Celik N, Ozturk C, Turkoglu M, Cetin N, Kockara N, Sener E, Dundar C, Arslan A and Dogan H. Chondroprotective effects of a new glucosamine combination in rats: gene expression, biochemical and histopathological evaluation. *Life Sci* 2015; 130: 31-37.
- [21] Ohkawa H, Ohishi N and Yagi K. Assay for lipid peroxides in animal tissues by thiobarbituric acid reaction. *Anal Biochem* 1979; 95: 351-358.
- [22] Sedlak J and Lindsay RH. Estimation of total, protein-bound, and nonprotein sulfhydryl groups in tissue with Ellman's reagent. *Anal Biochem* 1968; 25: 192-205.
- [23] Guner S and Buyukbebeci O. Analyzing the effects of platelet gel on knee osteoarthritis in the rat model. *Clin Appl Thromb Hemost* 2013; 19: 194-8.
- [24] Clarkson PM and Thompson HS. Antioxidants: what role do they play in physical activity and health? *Am J Clin Nutr* 2000; 72: 637s-646s.
- [25] Yeum KJ, Russell RM, Krinsky NI and Aldini G. Biomarkers of antioxidant capacity in the hydrophilic and lipophilic compartments of human plasma. *Arch Biochem Biophys* 2004; 430: 97-103.
- [26] Guo J, Ou L, Zhou J, Wang X and Guo X. [Impact on the model of rat osteoarthritis of jingu tablet]. *Zhongguo Zhong Yao Za Zhi* 2006; 31: 232-235.
- [27] Mahdavi AM, Mahdavi R, Kolahi S, Zemestani M and Vatankhah AM. L-Carnitine supplementation improved clinical status without changing oxidative stress and lipid profile in women with knee osteoarthritis. *Nut Res* 2015; 35: 707-715.
- [28] Goldring MB and Berenbaum F. The regulation of chondrocyte function by proinflammatory mediators: prostaglandins and nitric oxide. *Clin Orthop Related Res* 2004; 427: S37-S46.
- [29] Kapoor M, Martel-Pelletier J, Lajeunesse D, Pelletier JP and Fahmi H. Role of proinflammatory cytokines in the pathophysiology of osteoarthritis. *Nat Rev Rheumatol* 2011; 7: 33-42.
- [30] Xu L, Sun C, Zhang S, Xu X, Zhai L, Wang Y, Wang S, Liu Z, Cheng H and Xiao M. Sam68 promotes NF- κ B activation and apoptosis signaling in articular chondrocytes during osteoarthritis. *Inflamm Res* 2015; 64: 895-902.
- [31] Chabane N, Zayed N, Afif H, Mfuna-Endam L, Benderdour M, Boileau C, Martel-Pelletier J, Pelletier JP, Duval N and Fahmi H. Histone deacetylase inhibitors suppress interleukin-1 β -induced nitric oxide and prostaglandin E₂ production in human chondrocytes. *Osteoarthritis Cartilage* 2008; 16: 1267-1274.
- [32] Giunta S, Castorina A, Marzagalli R, Szychlinska MA, Pichler K, Mobasheri A and Musumeci G. Ameliorative effects of PACAP against cartilage degeneration. Morphological, immunohistochemical and biochemical evidence from in vivo and in vitro models of rat osteoarthritis. *Int J Mol Sci* 2015; 16: 5922-5944.

- [33] Ünsal M and Aktaş N. Fractionation and characterization of edible sheep tail fat. *Meat Sci* 2003; 63: 235-239.
- [34] Karimi E and Jaafar HZ. HPLC and GC-MS determination of bioactive compounds in microwave obtained extracts of three varieties of *Labisia pumila* Benth. *Molecules* 2011; 16: 6791-6805.
- [35] Anand R and Kaithwas G. Anti-inflammatory potential of alpha-linolenic acid mediated through selective cox inhibition: computational and experimental data. *Inflammation* 2014; 37: 1297-1306.
- [36] Østergaard M, Stoltenberg M, Løvgreen-Nielsen P, Volck B, Jensen CH and Lorenzen I. Magnetic resonance imaging-determined synovial membrane and joint effusion volumes in rheumatoid arthritis and osteoarthritis. Comparison with the macroscopic and microscopic appearance of the synovium. *Arthritis Rheum* 1997; 40: 1856-1867.
- [37] Yoon HS and Kim HA. Prologation of c-Jun N-terminal kinase is associated with cell death induced by tumor necrosis factor alpha in human chondrocytes. *J Korean Med Sci* 2004; 19: 567-573.
- [38] Guzman RE, Evans MG, Bove S, Morenko B and Kilgore K. Mono-iodoacetate-induced histologic changes in subchondral bone and articular cartilage of rat femorotibial joints: an animal model of osteoarthritis. *Toxicol Pathol* 2003; 31: 619-624.