

## Case Report

# Intra-suprasellar paraganglioma radiographically resembling a craniopharyngioma: a case report and literature review

Guangyu Li, Yanlei Guan, Jian Wu, Yue Wang

Department of Neurosurgery, The First Affiliated Hospital, China Medical University, Shenyang 110001, China

Received December 11, 2016; Accepted April 28, 2017; Epub July 15, 2017; Published July 30, 2017

**Abstract:** Paragangliomas arising in the sellar region are extremely rare. Most of the cases presented as adenoma or meningioma. Here, we described a case of a 40-year-old woman with sellar paraganglioma presented as craniopharyngioma. She was admitted to our department with the complaint of gradually decreasing visual acuity and slightly disturbance of menstruation for 6 months. Computed tomography (CT) and magnetic resonance imaging (MRI) scan showed an intra- and supra-sellar expanding lesion which was regarded as craniopharyngioma before operation. Histological examination was diagnostic of a paraganglioma. We review the literature and discuss the characteristic feature of sellar region paragangliomas.

**Keywords:** Paraganglioma, sellar, craniopharyngioma Introduction

### Introduction

Neoplasm of the sellar region are entities with a large differential diagnosis. Pituitary adenoma, craniopharyngioma and meningioma are the most common lesion in this region. Paragangliomas are tumors derive from the neural crest cells; they include neoplasm of the adrenal medulla and paraganglia. They may occur at multiple locations within the body. Paragangliomas which arise from sellar and parasellar area are very rare and there have been reported only a few cases in the literature up to date. Here we report a further case of sellar region paraganglioma presenting as craniopharyngioma.

### Case report

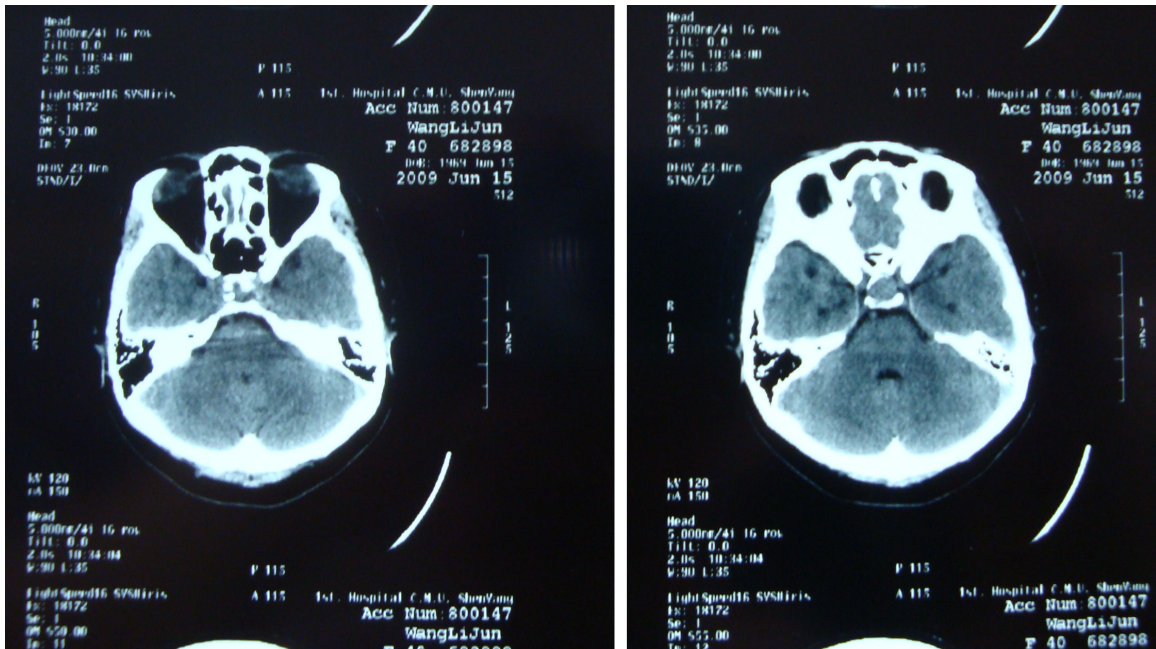
A previously healthy 40 year-old women presented with gradually decreased visual acuity accompanied with slightly disturbance of menstruation for 6 months. Neurological examination revealed bitemporal hemianopsia. Laboratory examination findings were within normal limits except slightly elevated PRL level. Computed tomography (CT) revealed a high-dense

intra-suprasellar cystic lesion (**Figure 1**). Magnetic resonance imaging (MRI) showed the cyst cavity as a hyper-intense area in T1-weighted images and slightly enhanced with gadolinium (**Figure 2**). The operation was performed through subfrontal approach. A yellow colloid mass inside the cyst and part of the cyst wall were removed. The optic nerve compression was released. After the operation the patient recovered her visual acuity and menstruation. External beam radiation at a dose of 50 Gy was applied to the residual tumor. During 3-year postsurgical follow-up, the patient remained in good health.

### Pathological findings

Under operation microscope, the tumor was red cyst with highly vascularized cystic wall, yellow colloid mass and a piece of confirm mass inside the cyst. Histopathological examination revealed neoplastic cells were arranged in well-defined cell clusters separated by fibrous septa (**Figure 3**). Mitotic figures were not conspicuous. Immunohistochemical analysis showed that tumor cells were strongly positive for chromogranin A (cga), synaptophysin (syn) and

## Intra-suprasellar paraganglioma resembling a craniopharyngioma



**Figure 1.** CT scan of paraganglioma. CT scan of paraganglioma showing a round homodensity lesion in the sellar region, at front part of the lesion a high density mass which was confirmed to be bony like mass in the operation.

neuron-specific enolase (NSE), and were negative for endomysial antibody (EMA) (Figure 4). The tumor cells were also immunonegative for all pituitary hormones. Combination histological features with immunohistochemical findings confirmed the diagnosis of a paraganglioma.

### Discussion

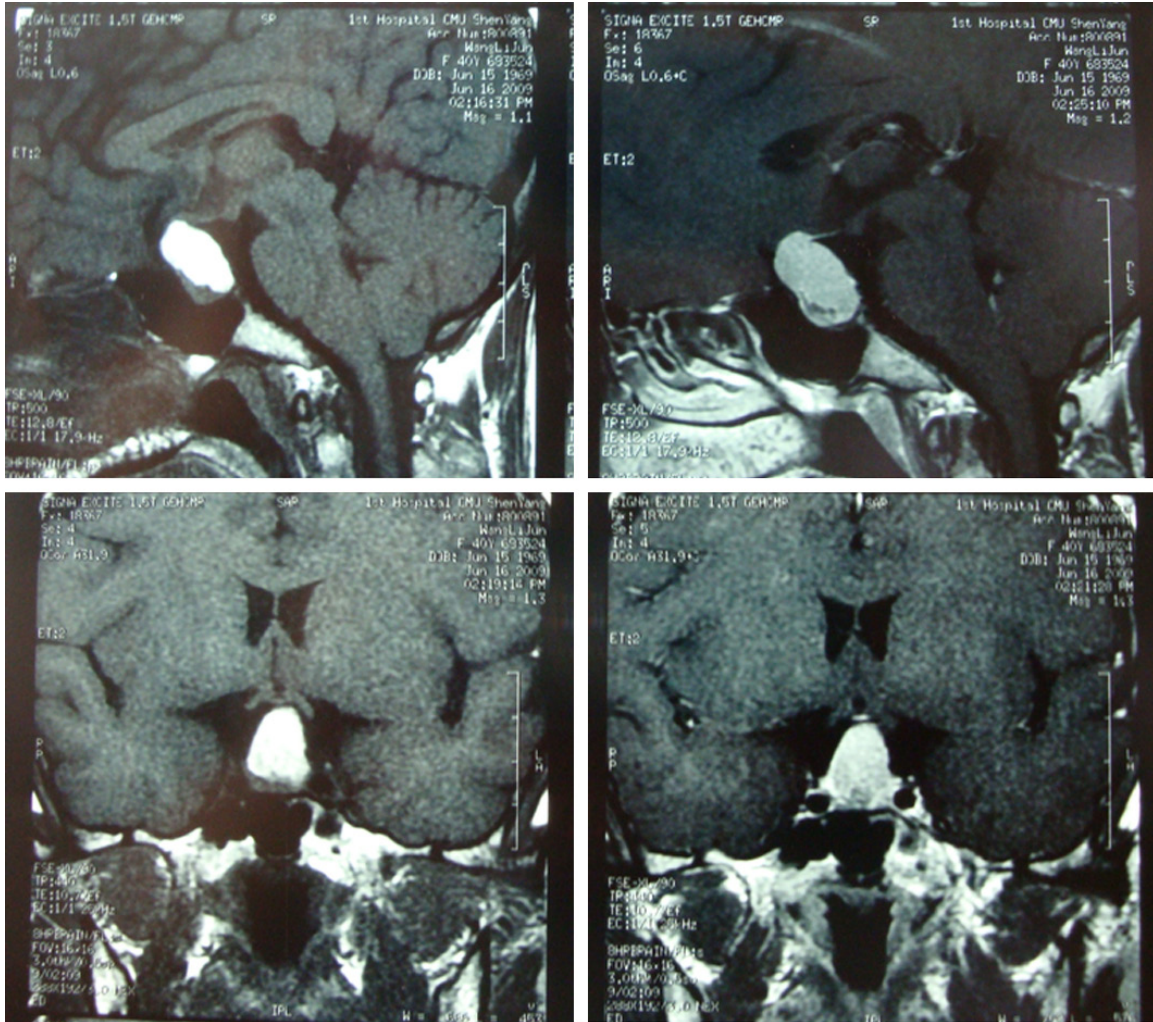
Since the first description in 1967 [1], only 22 cases of paraganglioma in sellar region have been reported in English literature (Table 1). The average age at diagnosis for them is 47 years (14-84) and predominance in male was seen in these reported cases (16 males and 6 females), in contrast to paragangliomas of the glomus-jugular region, whose predominance in female was reported by large case series (33 males and 198 females) [2]. More cases and further study were needed to explain this discrepancy.

Paragangliomas are assumed to originate from ectodermic cells derived from neuron crest progenitor cells [3], Extra-adrenal paragangliomas can be found in the intercarotidum tissue, tympanojugular and vagal nerve [4], in central nervous system paraganglioma most frequently affect glomus jugular [2] and cauda equine

[5]. The vast majority of paragangliomas in central nervous system presented as tumors at cauda equine and glomus jugular, however, rare examples of purely intracranial presentation, including sellar region like the present case, cerebellar region, and skull base, have been reported. There is no definite explanation for the development of intracranial paragangliomas. The possible hypotheses include (1) anomaly of migration of neural crest cells; (2) anomaly of involution of fetal paraganglia (persistence of vestigial tissue); (3) intracerebral metastasis of an undiagnosed paraganglioma in another location [6, 7]. Further studies are needed to clarify the tumorigenesis of intracranial paraganglioma.

Since intracranial paragangliomas show no characteristic clinical features, such as endocrinological symptoms seen in adrenal paragangliomas, pre-operative diagnosis of paragangliomas in sellar region can be obtained only by radiographic examinations. Radiographic findings of paragangliomas in the sellar region were summarized in Table 1. Because majority of them appeared as well-enhanced hypo-isointense mass on T1-weighted images, which led to the preoperative diagnosis of pituitary adenoma or meningioma due to their radiographic similarities. Conversely, the tumor

## Intra-suprasellar paraganglioma resembling a craniopharyngioma



**Figure 2.** MR image of paraganglioma. MR image of paraganglioma Left, T1-weighted without gadolinium; right, T1-weighted with gadolinium. MRI image showing a hyper intensive lesion of sellar region in T1, and showing enhancement of the wall after gadolinium administration.

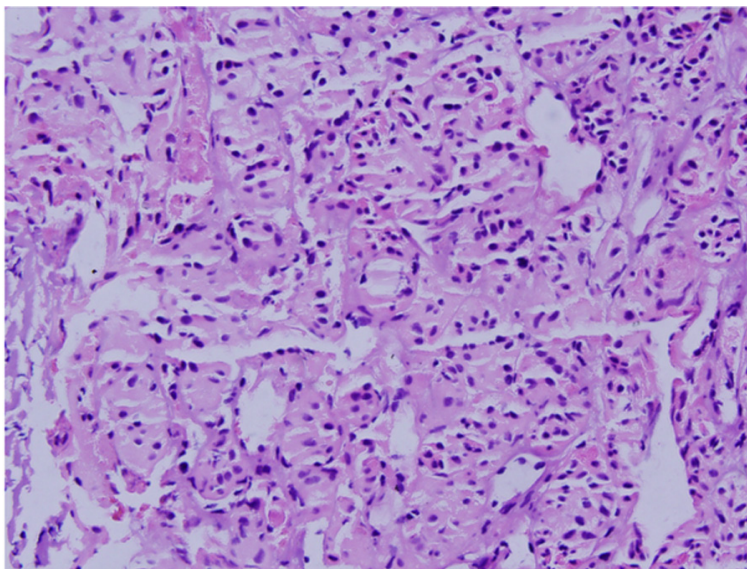
in the present case showed hyperintense in T1 weighted image, which induced presurgical diagnosis of craniopharyngioma. During the operation, the yellow colloid mass inside the cyst and highly vascularized reddish cyst wall were observed. To the best of our knowledge this is the first report of paraganglioma in sellar with such kind of radiological and intraoperative manifestation.

Pathological features of paraganglioma resembles normal paraganglia, composed of chief cells in well-defined cell nests (Zellballen), surrounded by layer of sustentacular cells. In our case, the typical zellballen architecture was evident, however, the S-100 positive sustentacular cells were scarce. The same phenomena

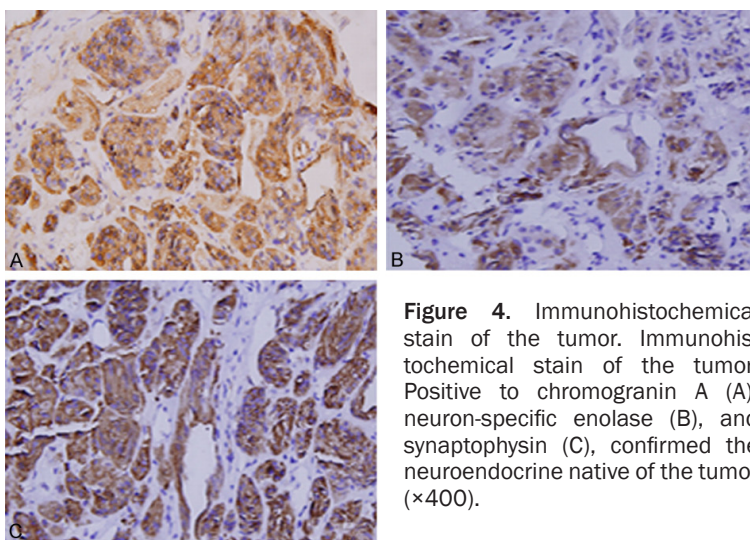
were also reported by other author, these authors regarded the tumor with few sustentacular cells as more aggressive forms of paragangliomas. The correlation between the presence of sustentacular cells and clinical behavior should be further confirmed.

We treated the present case with postoperative radiotherapy. During the 3-year follow-up, the residual tumor remains radiographically stable. Most of the reported paragangliomas at sellar region under went less than subtotal remove in order to avoid damaging adjacent structures, subsequently received radiotherapy (Table 1). There was no clear evidence of radiation effects for intracranial paragangliomas, Postoperative radiation for re-

## Intra-suprasellar paraganglioma resembling a craniopharyngioma



**Figure 3.** HE stain of the tumor. HE stain of the tumor. Nest of neoplastic cells separated fibrous septa. Tumor cells showing pleomorphism ( $\times 400$ ).



**Figure 4.** Immunohistochemical stain of the tumor. Immunohistochemical stain of the tumor. Positive to chromogranin A (A), neuron-specific enolase (B), and synaptophysin (C), confirmed the neuroendocrine nature of the tumor ( $\times 400$ ).

sidual tumors has been recommended in the previous reports. A recent study showed a 96% local control rate during a mean follow up of 50 months in 41 patients with jugular paraganglioma underwent radiotherapy [14]. Elucidating the detailed radiation effects for intracranial paraganglioma would be meaningful especially for the tumors radical operation should be avoided due to surrounding crucial structures, like the present case.

In conclusion, we reported a case of paraganglioma in sellar region resembling craniopharyngioma in radiologic features, implying that the

radiologic manifestation of sellar region paraganglioma was complex. Histopathological and immunohistochemical diagnosis was essential for the final confirmation. When diagnosed of sellar region tumors, especially the cystic lesion in this region, paraganglioma should also be considered.

### Disclosure of conflict of interest

None.

**Address correspondence to:** Dr. Guangyu Li, Department of Neurosurgery, The First Affiliated Hospital, China Medical University, 155# Nanjingbei Street Heping District, Shenyang 110001, China. Tel: 086-024-83283302; E-mail: tyjk1972@163.com

### References

- [1] Chytil S. [A case of nonchromaffin paraganglioma originating in the suprasellar region and invading the nose through the sphenoid sinus]. *Cesk Otolaryngol* 1967; 16: 115-119.
- [2] Brown JS. Glomus jugulare tumors revisited: a ten-year statistical follow-up of 231 cases. *Laryngoscope* 1985; 95: 284-288.
- [3] Wasserman PG, Savarganekar P. Paragangliomas: classification, pathology, and differential diagnosis. *Otolaryngol Clin North Am* 2001; 34: 845-862.
- [4] Sook M, Hamoir E, de Leval L, Duquenne S, Larbuisson R, Joris J, Meurisse M, Defraigne J, Radermecker MA. Cardiac paraganglioma: diagnostic work up and review of the literature. *Acta Chir Belg* 2012; 112: 310-313.
- [5] Hong JY, Hur CY, Modi HN, Suh SW, Chang HY. Paraganglioma in the cauda equina. a case report. *Acta Orthop Belg* 2012; 78: 418-423.
- [6] Reithmeier T, Gumprecht H, Stolze A, Lumenta CB. Intracerebral paraganglioma. *Acta Neurochir (Wien)* 2000; 142: 1063-1066.

## Intra-suprasellar paraganglioma resembling a craniopharyngioma

**Table 1** over review of reported sellar paraganglioma

Author	Age/sex	Location	Radiology	Operation finding
Chaudhry NS [8]	44/male	s/ss	Hyperdense in CT, enhancing, well-defined heterogeneous in consistency (MRI)	Very bloody, freshly/subtotal
Yokoo H [9]	52/female	ss	T1 low signal T2 high signal homogenously Enhanced (MRI)	Extremely hemorrhagic/biopsy
Ünal Özüm [10]	70/male	s/ps	Heterogeneous sellar mass (CT)	Soft, small grayish-brown tissue fragments/subtotal
Naggara O [11]	47/male	s/ss	Isointense T1, hyperintense T2, enhanced (MRI)	Extradural greyish-to-pinkish soft tumour/subtotal
Boari N [12]	52/male	s/ss	Homogenously enhanced (MRI)	Grey-pink fleshy tissue/subtotal
F. Hertel [13]	51/aml	s/ps	Isointense T1 hypointense T2 enhanced (MRI) Calcified (CT)	Imhomogeneous, not extremely vascular tumor
Zorlu F [14]	37/male	s/ps	Contrast enhancing parasellar mass (MRI)	Subtotal
Haresh KP [15]	17/male	s/ps	Isointense on T1 hypointense T2, well defined mass (MRI)	Highly vascular firm to hard tumor/biopsy (bone metasis)
Sinha S [16]	18/male	s/ss	Isointense on T1 hypointense T2, enhanced (MRI)	Subtotal (malignant)
Lu JQ [17]	81/male	s/ss	Well-circumscribed heterogeneous enhanced (MRI)	Variable consistency, both soft and firm/subtotal(metasis from esophageal)
Voulgaris SG [18]	48/male	s/ss	Solid and cystic hypointense T1 hyperintense T2 enhanced (MRI)	Encapsulated, with reddish-brown mass, in consistency/subtotal
	53/male	s/ss	Hypointense T1 hyperintense T2 homogenously enhanced (MRI)	Soft pinkish-gray and well-circumscribed mass/total
Del Basso De Caro ML [19]	84/male	s/ss/ps	Enlarged and eroded sellar turcica occupied by isodense mass (CT)	Soft yellow-reddish very hemorrhagic tissue
Mokry M [20]	76/female	s/ss	Lower signal T1 inhomogeneous T2 Enhanced (MRI)	Soft, highly vascular, friable tumor/subtotal Excessive bleeding/biopsy
Flint EW [21]	17/female	s/ss	Mass with some calcification (CT) vessel in the mass (MRI)	Not mention
Do Nascimento [22]	32/female	s/ss	Mass suggestive of meningioma or pituitary adenoma (CT)	Not mention
Albert A [23]	63/male	s/orbit	Isotense in T2 (MRI)	Grayish-to-pinkish soft tumor
Sambaziotis D [24]	54/male	s/ss	Clepsydra-shaped mass (MRI)	Highly fibrous and vascular tumor with extremely firm consistency
Salame K [25]	48/female	s/ss	Homogenous, isointense T1, hypertense T2 diffuse enhanced (MRI)	Red-gray somewhat fibrous mass, highly vascular/subtotal;
Scheithauer BW [26]	14/male	s/ss	Contrast-enhancing mass (CT)	
Steel TR [27]	44/female	s/ps	Lobulated lesion isotonicin T1 uniformly enhancement (MRI)	Soft white to slightly pink encaulated tumor/subtotal
	41/female	s/ps	Uniformly enhancemen (MRI)	Soft pinkish-white tumor/subtotal

S: sellar, SS: suprasellar, PS: parasellar.

## Intra-suprasellar paraganglioma resembling a craniopharyngioma

- [7] Deb P, Sharma MC, Gaikwad S, Gupta A, Mehta VS, Sarkar C. Cerebellopontine angle paraganglioma-report of a case and review of literature. *J Neurooncol* 2005; 74: 65-69.
- [8] Chaudhry NS, Ahmad F, Blieden C, Morcos JJ. Suprasellar and sellar paraganglioma presenting as a nonfunctioning pituitary macroadenoma. *J Clin Neurosci* 2013; 20: 1615-1618.
- [9] Yokoo H, Tanaka G, Isoda K, Hirato J, Nakazato Y, Fujimaki H, Watanabe K, Saito N, Sasaki T. Novel crystalloid structures in suprasellar paraganglioma. *Clin Neuropathol* 2003; 22: 222-228.
- [10] Ozum U, Egilmez R, Yildirim A. Paraganglioma in pituitary fossa. *Neuropathology* 2008; 28: 547-550.
- [11] Naggara O, Varlet P, Page P, Oppenheim C, Meder JF. Suprasellar paraganglioma: a case report and review of the literature. *Neuroradiology* 2005; 47: 753-757.
- [12] Boari N, Losa M, Mortini P, Snider S, Terreni MR, Giovanelli M. Intracellular paraganglioma: a case report and review of the literature. *Acta Neurochir (Wien)* 2006; 148: 1311-1314.
- [13] Hertel F, Bettag M, Morsdorf M, Feiden W. Paragangliomas of the parasellar region. *Neurosurg Rev* 2003; 26: 210-214.
- [14] Zorlu F, Selek U, Ulger S, Donmez T, Erden E. Paraganglioma in sella. *J Neurooncol* 2005; 73: 265-267.
- [15] Haresh KP, Prabhakar R, Anand RKD, Sharma DN, Julka PK, Rath GK. A rare case of paraganglioma of the sella with bone metastases. *Pituitary* 2009; 12: 276-279.
- [16] Sinha S, Sharma MC, Sharma BS. Malignant paraganglioma of the sellar region mimicking a pituitary macroadenoma. *J Clin Neurosci* 2008; 15: 937-939.
- [17] Lu JQ, Khalil M, Hu W, Sutherland GR, Clark AW. Tumor-to-tumor metastasis: esophageal carcinoma metastatic to an intracranial paraganglioma. *J Neurosurg* 2009; 110: 744-748.
- [18] Voulgaris SG, Partheni M, Tzortzidis F, Ravazoula P, Pessach IS, Papadakis N, Polyzoidis KS. Suprasellar and intrasellar paragangliomas. *Clin Neuropathol* 2006; 25: 221-226.
- [19] Del Basso De Caro ML, Siciliano A, Cappabianca P, Alfieri A, de Divitiis E. Intracellular paraganglioma with suprasellar extension: case report. *Tumori* 1998; 84: 408-411.
- [20] Mokry M, Kleinert R, Clarici G, Obermayer-Pietsch B. Primary paraganglioma simulating pituitary macroadenoma: a case report and review of the literature. *Neuroradiology* 1998; 40: 233-237.
- [21] Flint EW, Claassen D, Pang D, Hirsch WL. Intrasellar and suprasellar paraganglioma: CT and MR findings. *AJNR Am J Neuroradiol* 1993; 14: 1191-1193.
- [22] do NA, Maranh LA, Corredato RA, Araujo JC, Bleggi-Torres LF. 33 year-old woman with a large sellar tumor. *Brain Pathol* 2012; 22: 869-870.
- [23] Albert A, Ramirez JA, Codere F, Petrecca K. Sellar paraganglioma: a unique route to a rare destination case report and literature review. *Clin Neurol Neurosurg* 2011; 113: 675-677.
- [24] Sambaziotis D, Kontogeorgos G, Kovacs K, Horvath E, Levedis A. Intracellular paraganglioma presenting as nonfunctioning pituitary adenoma. *Arch Pathol Lab Med* 1999; 123: 429-432.
- [25] Salame K, Ouaknine GE, Yossipov J, Rochkind S. Paraganglioma of the pituitary fossa: diagnosis and management. *J Neurooncol* 2001; 54: 49-52.
- [26] Scheithauer BW, Parameswaran A, Burdick B. Intracellular paraganglioma: report of a case in a sibship of von Hippel-Lindau disease. *Neurosurgery* 1996; 38: 395-399.
- [27] Steel TR, Dailey AT, Born D, Berger MS, Mayberg MR. Paragangliomas of the sellar region: report of two cases. *Neurosurgery* 1993; 32: 844-847.