

## Original Article

# Diagnostic role of real-time shear wave elastography on staging of liver fibrosis

Yan Xue<sup>1</sup>, Qing Zhu<sup>2</sup>, Yuanzheng Chen<sup>3</sup>, Nan Bai<sup>4</sup>

Departments of <sup>1</sup>Ultrasonography, <sup>3</sup>Plastic Surgery, <sup>4</sup>Plastic Cosmetic Surgery, Linyi People's Hospital, Linyi City, Shandong Province 276000, China; <sup>2</sup>Gastrointestinal Surgery, Heze Municipal Hospital, Heze City, Shandong Province 274031, China

Received February 28, 2017; Accepted March 21, 2017; Epub August 15, 2017; Published August 30, 2017

**Abstract:** Background: Shear wave elastography (SWE) is one of newly-developed methods. Our meta-analysis was aimed to clarify whether SWE could be used as a diagnostic biomarker of liver fibrosis. Methods: We searched the potential articles in databases of PubMed, Embase and Google Scholar. The discrimination of F0 from F1/4 ( $F \geq 1$ ), F0/1 from F2/4 ( $F \geq 2$ ), F0/2 from F3/4 ( $F \geq 3$ ), and F0/3 from F4 ( $F \geq 4$ ) were tested by SWE. Overall results of sensitivity and specificity along with 95% confidence intervals (95% CI) were used to evaluate the diagnostic accuracy. Summary receiver operating characteristic (SROC) curve was analyzed as well. The random-effects model or fixed-effects model was used according to the between-study heterogeneity. Results: 7 articles were included in the present meta-analysis. The tests for  $F \geq 2$  based on 7 articles showed the sensitivity and specificity were 0.86 (0.82-0.89) and 0.76 (0.71-0.80), respectively. The area under curve (AUC) was 0.922. With respect to  $F \geq 3$ , overall sensitivity and specificity were 0.91 (0.85-0.95) and 0.84 (0.80-0.88). The corresponding AUC was 0.839. In terms of  $F \geq 4$ , high sensitivity and specificity were also obtained (sensitivity: 0.87; specificity: 0.87). AUC value of 0.934 also demonstrated the high accuracy of SWE. Conclusion: SWE appears to be a diagnostic biomarker with high accuracy for liver fibrosis.

**Keywords:** Shear wave elastography, liver fibrosis, diagnosis, meta-analysis

## Introduction


Liver fibrosis is the combined results of various liver diseases [1] and can bring about the onset of liver cirrhosis. The risk factors includes alcohol consumption, viruses infection and fat ingestion. Without suitable treatments, liver fibrosis develops easily into cirrhosis, hepatocellular carcinoma, or portal venous hypertension, thus causing increased mortality [2, 3]. Estimation of the staging of liver fibrosis helps for predicting the prognosis and regulating the treatment strategy for the patients with liver disease.

METAVIR classification criteria is one of widely used system for staging of liver fibrosis. According to the criteria, the stages of liver fibrosis were divided into  $\geq F2$  (significant fibrosis),  $\geq F3$  (severe fibrosis),  $\geq F4$  (cirrhosis) [4]. Until now, liver biopsy (LB) is still the gold stan-

dard for liver fibrosis [5, 6]. However, LB is an invasive and costly test with potential complication. The detection accuracy of LB in liver fibrosis may be affected by sampling error and differences in pathological interpretation [7, 8]. Therefore, LB is not regarded as a favorable method for repeated tests of liver fibrosis.

To date, increasing researches have provided many non-invasive indexes for liver fibrosis. Among them, assessment of liver stiffness (LS) based on acoustic radiation force impulse imaging (ARFI), transient elastography (TE), and magnetic resonance (MR) elastography have been extensively investigated [9-12]. Additionally, real-time shear wave elastography (SWE) is another new-developed technology for measuring LS [13]. During SWE test, the acoustic radiation force impulse excites the tissue to produce some small tissue (1-10 mm) displacements. Following that, the displacements affects the

## Diagnostic role of SWE in liver fibrosis



**Figure 1.** Flow chart for articles selection. 7 articles were selected in our meta-analysis.

shear wave propagation, thus shear wave velocity (SWV) or Young's modulus (E) are calculated. Until now, the diagnostic role of SWE has been widely researched in liver fibrosis, however, definite conclusion has not been obtained.

This meta-analysis was performed to get more precise estimation, which will uncover the clinical significance of SWE in detecting the stages of liver fibrosis.

### Methods

#### Articles search

The potential articles were searched in databases of PubMed, EMBASE and Google Scholar. The keywords were: shear wave elastography, liver and diagnosis. To get more related articles, we also searched the references of each article.

#### Inclusion criteria

Eligible articles were identified according to the inclusion criteria. The criteria was defined as follows: (1) the articles evaluated the diagnostic role of SWE in detecting the staging of liver fibrosis; (2) the articles utilized the liver biopsy as "gold standard" in the diagnosis of liver fibrosis; (3) the staging of liver fibrosis was performed according to METAVIR in the articles; (4) the articles provided data of true positive (TP), false positive (FP), false negative (FN) and

true negative (TN) or other related data, such as negative predictive value (NPV), positive predictive value (PPV), sensitivity and specificity, to calculate these results; (5) each article contained more than 30 patients.

#### Data extraction

The data was extracted by two reviewers independently: name of first author, year of publication, country, ethnicity, cut-off value, sensitivity, specificity, area under curve (AUC) and related clinical features. The disagreements were resolved by a discussion.

### Statistics

The stages of liver fibrosis were divided into five degrees: F0, no fibrosis; F1, portal fibrosis without septa; F2, portal fibrosis and few septa, but intact architecture; F3, numerous septa, architectural distortion, but no obvious cirrhosis; and F4, cirrhosis. In the present meta-analysis, we analyzed the diagnostic value of SWE in distinguishing F0 from F1/4 ( $F \geq 1$ ), F0/1 from F2/4 ( $F \geq 2$ ), F0/2 from F3/4 ( $F \geq 3$ ), and F0/3 from F4 ( $F \geq 4$ ). The corresponding TP, FP, TN and FN results were calculated. The overall results of sensitivity and specificity along with 95% confidence intervals (95% CI) represented the diagnostic accuracy of SWE for stages of liver fibrosis. Another index, summary receiver operating characteristic (SROC) curve, was analyzed as well. The between-study heterogeneity was evaluated by  $\chi^2$ .  $P < 0.05$  indicated that there was heterogeneity, then the random-effects model was used. Otherwise, the calculation adopted fixed-effects model. The analysis was conducted with MetaDiSc 1.4 software.

### Results

#### Articles features

After the systematic selection (Figure 1), 7 articles were included [14-20]. Total of 884 patients with liver fibrosis were included in our meta-analysis. Their mean age ranged from 36.3 to 61 years. The patients came from coun-

## Diagnostic role of SWE in liver fibrosis

**Table 1.** Clinical features of each study

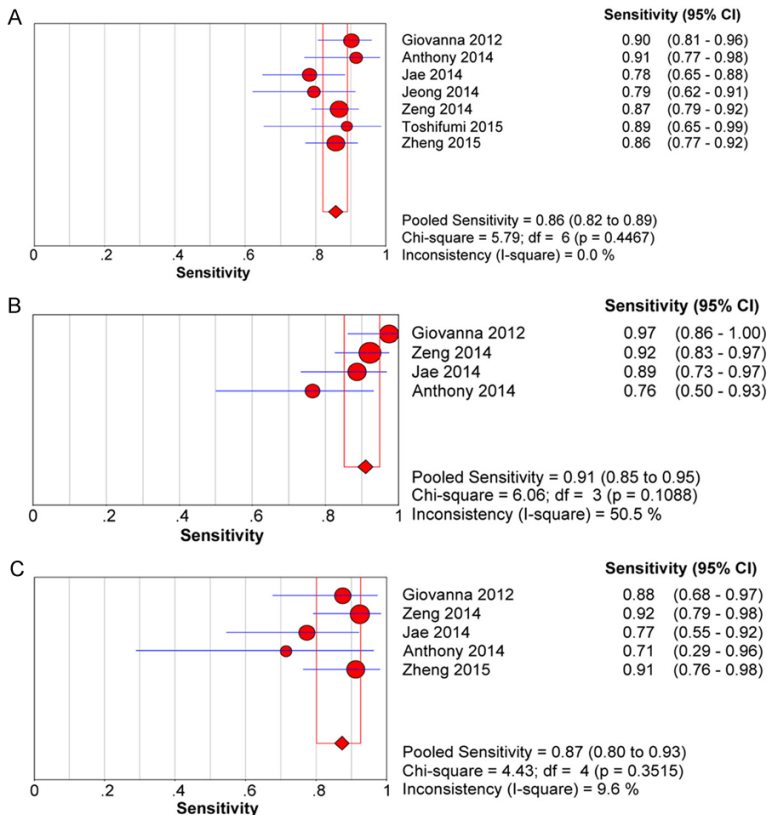
Study	Country	Sample size, n	Mean age, years	Disease Etiology	Cut-off Stage
Giovanna 2012	Italy	121	44.8	HCV	F $\geq$ 2, F $\geq$ 3, F $\geq$ 4
Jeong 2014	Korea	129	51.0	HCV, HBV and Others	F $\geq$ 2
Anthony 2014	America	136	51.0	HCV and Others	F $\geq$ 2, F $\geq$ 3, F $\geq$ 4
Jae 2014	Korea	70	45.9	HCV, HBV and Others	F $\geq$ 2, F $\geq$ 3, F $\geq$ 4
Zeng 2014	China	206	36.3	HBV	F $\geq$ 2, F $\geq$ 3, F $\geq$ 4
Toshifumi 2015	Japan	55	61.0	HCV	F $\geq$ 2
Zheng 2015	China	167	37.5	HCV, HBV and Others	F $\geq$ 2, F $\geq$ 4

Note: HCV, hepatitis C virus; HBV, hepatitis B virus; E, Young's modulus; SWV, shear wave elastography.

**Table 2.** Diagnosis data of each study

Study	F $\geq$ 2			F $\geq$ 3			F $\geq$ 4		
	Sensitivity	Specificity	AUC	Sensitivity	Specificity	AUC	Sensitivity	Specificity	AUC
Giovanna 2012	0.900	0.875	0.920	0.973	0.951	0.980	0.875	0.968	0.980
Jeong 2014	0.788	0.756	0.852	-	-	-	-	-	-
Anthony 2014	0.914	0.525	0.770	0.765	0.765	0.820	0.714	0.822	0.820
Zeng 2014	0.864	0.870	0.917	0.919	0.857	0.945	0.919	0.897	0.945
Jae 2014	0.782	0.933	0.915	0.886	0.80	0.913	0.773	0.854	0.878
Toshifumi 2015	0.889	0.919	0.940	-	-	-	-	-	-
Zheng 2015	0.857	0.739	0.860	-	-	-	0.912	0.797	0.930
Overall	0.86	0.76	0.922	0.91	0.84	0.839	0.87	0.87	0.934

Note: AUC, area under curve, "-" means the unavailable data.



**Figure 2.** Forest plot of sensitivity for F $\geq$ 2, F $\geq$ 3 and F $\geq$ 4. A: F $\geq$ 2; B: F $\geq$ 3; C: F $\geq$ 4.

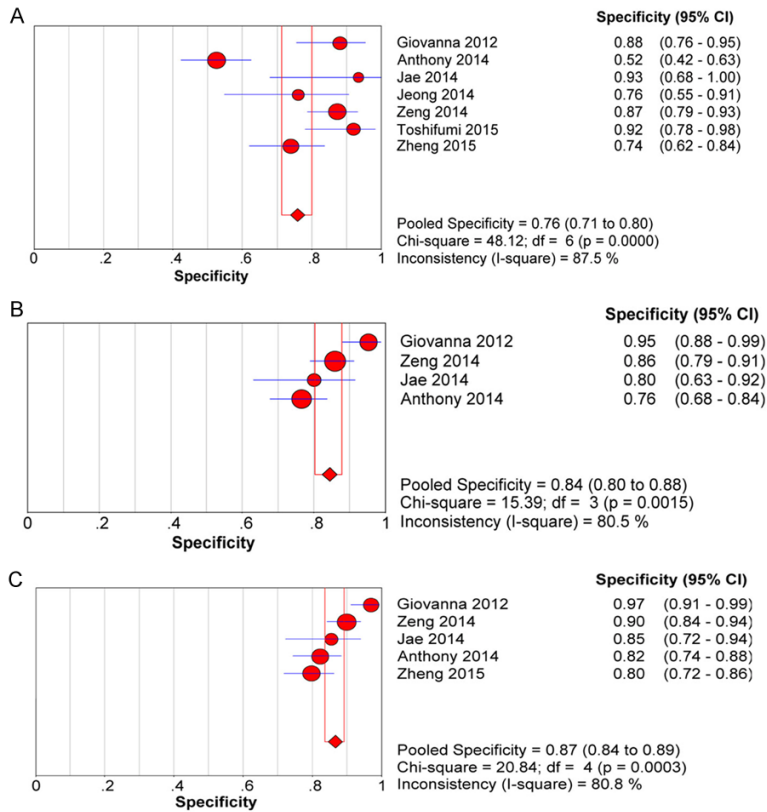
tries of Italy, Korea, America, China and Japan. The involved etiology contained HCV (hepatitis C virus), HBV (hepatitis B virus) and others. The detailed clinical informations were listed in **Table 1**.

### Diagnostic value of SWE in liver fibrosis

The analyzed stages of liver fibrosis were composed of F $\geq$ 2, F $\geq$ 3 and F $\geq$ 4. **Table 2** showed the detection results of SWE, such as sensitivity, specificity and area under curve (AUC). There were 7 articles for distinguishing F $\geq$ 2 (F0/1 vs. F2/4). The summary results of sensitivity and specificity were 0.86 (0.82-0.89) and 0.76 (0.71-0.80), respectively. The corresponded AUC was 0.922 (**Figures 2-4**).

As for the staging of F $\geq$ 3 (F0/2 vs. F3/4), the overall outcome of sensitivity and specificity

## Diagnostic role of SWE in liver fibrosis



**Figure 3.** Forest plot of specificity for F $\geq$ 2, F $\geq$ 3 and F $\geq$ 4. A: F $\geq$ 2; B: F $\geq$ 3; C: F $\geq$ 4.

based on 4 articles were 0.91 (0.85-0.95) and 0.84 (0.80-0.88), respectively.

The above mentioned this two indexes along with AUC (0.839) illustrated the high accuracy of SWE in detecting the stages of liver fibrosis.

In terms of F $\geq$ 4 (F0/3 vs. F4), we found the diagnosis sensitivity of SWE was 0.87 (0.80-0.93), and the corresponding specificity was 0.87 (0.84-0.89), which demonstrates the feasibility of SWE as a diagnostic biomarker. Another index, AUC (0.934) also supported this conclusion.

### Heterogeneity

In the overall sensitivity analysis, we found there was no significant heterogeneity (F $\geq$ 2: 0.4467; F $\geq$ 3: 0.1088; F $\geq$ 4: 0.3515), then the random-effects model was used. As for specificity, there existed obvious heterogeneity (F $\geq$ 2: 0.0000; F $\geq$ 3: 0.0015; F $\geq$ 4: 0.0003), hence, we adopted fixed-effects model.

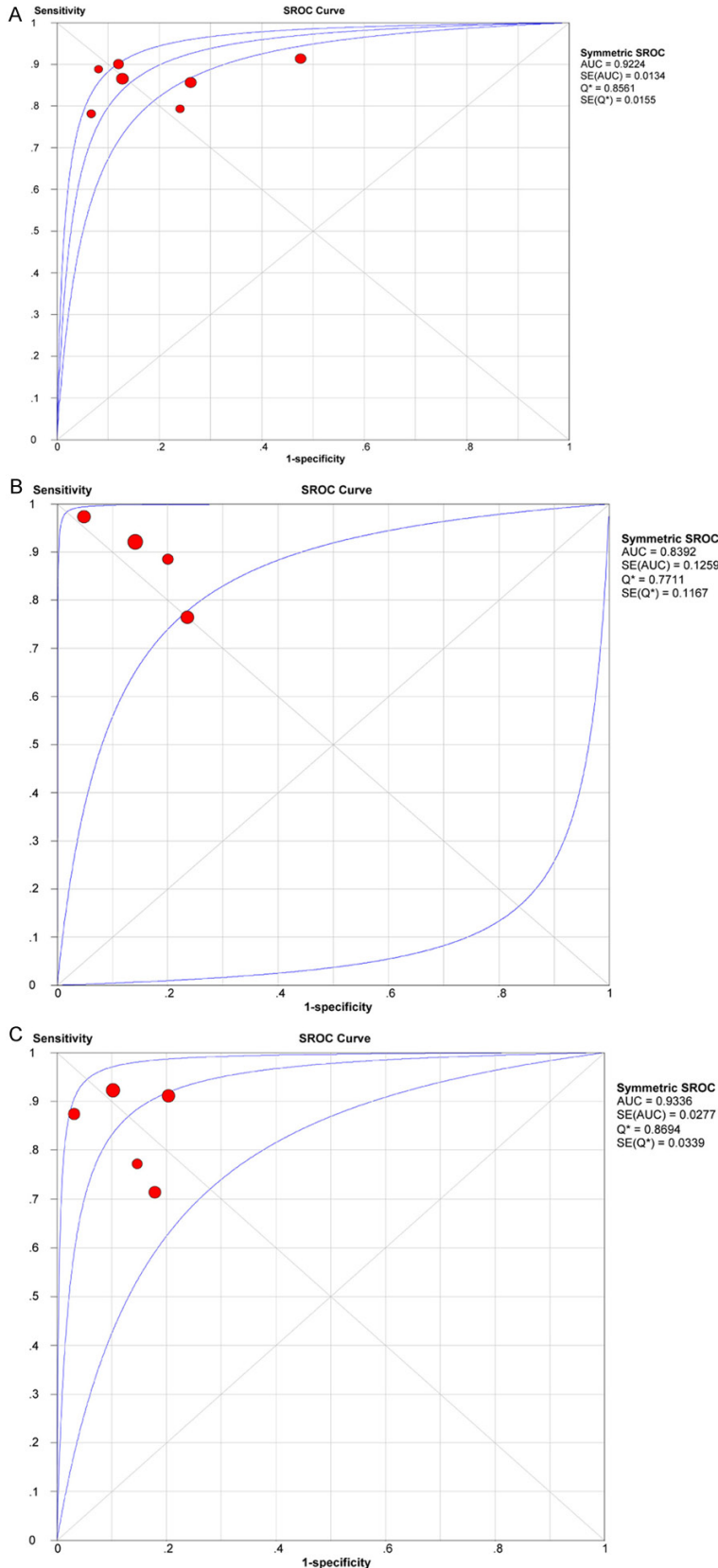
### Discussion

Elastography is a noninvasive method that uses ultrasonography to exert local mechanical compression on soft tissue and observe the tissue responses via strain images [21, 22]. Furthermore, elastography measurements were found to related with the stage of liver fibrosis [23]. LS measurement by elastography has been widely used for testing liver fibrosis. LS with more than 10 VMs is commonly considered reliable [24, 25].

Among the elastography technologies, TE has been commonly accepted as a diagnostic biomarker for liver fibrosis [26, 27]. TE technology is characterized with high accuracy, low cost and practical use. Whereas, there exists several limitations to be mentioned. It always fails to discriminate moderate liver fibrosis with high accuracy. Besides, the liver inflammation could affect its detection accuracy. Unfortunately, it cannot be used for diagnosis of patients with ascites [28, 29]. Real-time SWE by Aixplorer<sup>TM</sup> is a newly-developed two-dimensional transient elastography technique in liver fibrosis [13]. SWE shows good prospects in clinical application [13]. Both of TE and SWE methods show important function in clinical, however, SWE takes advantages over TE.

SWE combined with traditional diagnostic ultrasound system make it available that uses real-time B-mode imaging to detect liver lesions or evaluate morphological changes. Moreover, the greater bandwidths of SWE helps for improving the separation of fibrosis stages [30]. Another advantage of SWE over TE is that it could supply real-time quantitative map of liver stiffness. With SWE test, we could obtain visualized spatial variation of liver stiffness and adjust the size of targeted region according to the actual condition. The above mentioned advantages

## Diagnostic role of SWE in liver fibrosis



**Figure 4.** SROC for detecting F $\geq$ 2, F $\geq$ 3 and F $\geq$ 4. A: F $\geq$ 2; B: F $\geq$ 3; C: F $\geq$ 4.

enables test stability of real-time SWE in liver stiffness measurements [16].

Giovanna et al. reported that significant improvement in AUROCs by real-time SWE for F $\geq$ 2 was observed compared with TE, however, no significant improvements for F $\geq$ 3 and F $\geq$ 4 by SWE was obtained [16]. One study conducted by Zheng et al. concluded that SWE was superior to ultrasonography in diagnosis of F2 and F4 [19]. Compared with FIB-4, APRI and Forn's index, SWE behaves excellently in diagnosing the stages of liver fibrosis [20]. In our meta-analysis, SWE showed higher detection sensitivity and specificity for F $\geq$ 3, and the AUC was 0.839. Compared with F $\geq$ 3, SWE shows superiority in AUC in diagnosis of F $\geq$ 2 and F $\geq$ 4, while the sensitivity and specificity was relatively low.

The present meta-analysis contained 884 patients from Italy, Korea, America, China and Japan. The involved ethnicity included Asian and Caucasian, which ensures the reliability and accuracy of our results. There is still several limitations to be noted. The analyses of F $\geq$ 3 and F $\geq$ 4 were based on 4 and 5 articles, respectively. The sample size in each analysis was relatively small, which could affect the accuracy of results. Moreover, we did not perform subgroups analysis based on disease etiology. Future studies should concentrate on the diagnostic value of SWE liver fibrosis derived from different etiologies.

In conclusion, SWE seems to be a promising biomarker for



liver fibrosis. The outcome illustrates the significance of SWE in staging of liver fibrosis.

### Disclosure of conflict of interest

None.

**Address correspondence to:** Nan Bai, Department of Plastic Cosmetic Surgery, Linyi People's Hospital, Linyi City, Shandong Province 276000, China. E-mail: wgghdr3@126.com

### References

- [1] Kim SU, Han KH and Ahn SH. Non-invasive assessment of liver fibrosis: time to move from cross-sectional studies to longitudinal ones. *J Gastroenterol Hepatol* 2010; 25: 1472-1473.
- [2] Bensamoun SF, Wang L, Robert L, Charleux F, Latrive JP and Ho Ba Tho MC. Measurement of liver stiffness with two imaging techniques: magnetic resonance elastography and ultrasound elastometry. *J Magn Reson Imaging* 2008; 28: 1287-1292.
- [3] Wang Y, Ganger DR, Levitsky J, Sternick LA, McCarthy RJ, Chen ZE, Fasanati CW, Bolster B, Shah S, Zuehlsdorff S, Omary RA, Ehman RL and Miller FH. Assessment of chronic hepatitis and fibrosis: comparison of MR elastography and diffusion-weighted imaging. *AJR Am J Roentgenol* 2011; 196: 553-561.
- [4] Bedossa P and Poynard T. An algorithm for the grading of activity in chronic hepatitis C. The METAVIR cooperative study group. *Hepatology* 1996; 24: 289-293.
- [5] Amarapurkar D. Role of liver biopsy in management of chronic hepatitis B and chronic hepatitis C. *Trop Gastroenterol* 2007; 28: 67-68.
- [6] Quereda C, Moreno S, Moreno L, Moreno A, Garca-Sanmiguel L, Perez-Elas MJ, Navas E, Dronza F, Casado J, Antela A and Lopez-San Roman A. The role of liver biopsy in the management of chronic hepatitis C in patients infected with the human immunodeficiency virus. *Hum Pathol* 2004; 35: 1083-1087.
- [7] Bedossa P, Dargere D and Paradis V. Sampling variability of liver fibrosis in chronic hepatitis C. *Hepatology* 2003; 38: 1449-1457.
- [8] Friedman LS. Controversies in liver biopsy: who, where, when, how, why? *Curr Gastroenterol Rep* 2004; 6: 30-36.
- [9] Castera L. Invasive and non-invasive methods for the assessment of fibrosis and disease progression in chronic liver disease. *Best Pract Res Clin Gastroenterol* 2011; 25: 291-303.
- [10] Myers RP, Pomier-Layrargues G, Kirsch R, Pollett A, Beaton M, Levstik M, Duarte-Rojo A, Wong D, Crotty P and Elkashab M. Discordance in fibrosis staging between liver biopsy and transient elastography using the FibroScan XL probe. *J Hepatol* 2012; 56: 564-570.
- [11] Oudry J, Chen J, Glaser KJ, Miette V, Sandrin L and Ehman RL. Cross-validation of magnetic resonance elastography and ultrasound-based transient elastography: a preliminary phantom study. *J Magn Reson Imaging* 2009; 30: 1145-1150.
- [12] Rustogi R, Horowitz J, Harmath C, Wang Y, Chalian H, Ganger DR, Chen ZE, Bolster BD Jr, Shah S and Miller FH. Accuracy of MR elastography and anatomic MR imaging features in the diagnosis of severe hepatic fibrosis and cirrhosis. *J Magn Reson Imaging* 2012; 35: 1356-1364.
- [13] Muller M, Gennisson JL, Deffieux T, Tanter M and Fink M. Quantitative viscoelasticity mapping of human liver using supersonic shear imaging: preliminary in vivo feasibility study. *Ultrasound Med Biol* 2009; 35: 219-229.
- [14] Samir AE, Dhyani M, Vij A, Bhan AK, Halpern EF, Mendez-Navarro J, Corey KE and Chung RT. Shear-wave elastography for the estimation of liver fibrosis in chronic liver disease: determining accuracy and ideal site for measurement. *Radiology* 2015; 274: 888-896.
- [15] Jeong JY, Kim TY, Sohn JH, Kim Y, Jeong WK, Oh YH and Yoo KS. Real time shear wave elastography in chronic liver diseases: accuracy for predicting liver fibrosis, in comparison with serum markers. *World J Gastroenterol* 2014; 20: 13920-13929.
- [16] Ferraioli G, Tinelli C, Dal Bello B, Zicchetti M, Filice G, Filice C; Liver Fibrosis Study Group. Accuracy of real-time shear wave elastography for assessing liver fibrosis in chronic hepatitis C: a pilot study. *Hepatology* 2012; 56: 2125-2133.
- [17] Zeng J, Liu GJ, Huang ZP, Zheng J, Wu T, Zheng RQ and Lu MD. Diagnostic accuracy of two-dimensional shear wave elastography for the non-invasive staging of hepatic fibrosis in chronic hepatitis B: a cohort study with internal validation. *Eur Radiol* 2014; 24: 2572-2581.
- [18] Yoon JH, Lee JM, Joo I, Lee ES, Sohn JY, Jang SK, Lee KB, Han JK and Choi BI. Hepatic fibrosis: prospective comparison of MR elastography and US shear-wave elastography for evaluation. *Radiology* 2014; 273: 772-782.
- [19] Zheng J, Guo H, Zeng J, Huang Z, Zheng B, Ren J, Xu E, Li K and Zheng R. Two-dimensional shear-wave elastography and conventional US: the optimal evaluation of liver fibrosis and cirrhosis. *Radiology* 2015; 275: 290-300.
- [20] Tada T, Kumada T, Toyoda H, Ito T, Sone Y, Okuda S, Tsuji N, Imayoshi Y and Yasuda E. Utility of real-time shear wave elastography for as-

## Diagnostic role of SWE in liver fibrosis

- sessing liver fibrosis in patients with chronic hepatitis C infection without cirrhosis: comparison of liver fibrosis indices. *Hepatol Res* 2015; 45: E122-129.
- [21] Boursier J, Isselin G, Fouchard-Hubert I, Oberti F, Dib N, Lebigot J, Bertrais S, Gallois Y, Cales P and Aube C. Acoustic radiation force impulse: a new ultrasonographic technology for the widespread noninvasive diagnosis of liver fibrosis. *Eur J Gastroenterol Hepatol* 2010; 22: 1074-1084.
- [22] Mauldin FW Jr, Zhu HT, Behler RH, Nichols TC and Gallippi CM. Robust principal component analysis and clustering methods for automated classification of tissue response to ARFI excitation. *Ultrasound Med Biol* 2008; 34: 309-325.
- [23] Tsochatzis EA, Gurusamy KS, Ntaoula S, Cholongitas E, Davidson BR and Burroughs AK. Elastography for the diagnosis of severity of fibrosis in chronic liver disease: a meta-analysis of diagnostic accuracy. *J Hepatol* 2011; 54: 650-659.
- [24] Castera L, Vergniol J, Foucher J, Le Bail B, Chanteloup E, Haaser M, Darriet M, Couzigou P and De Ledinghen V. Prospective comparison of transient elastography, Fibrotest, APRI, and liver biopsy for the assessment of fibrosis in chronic hepatitis C. *Gastroenterology* 2005; 128: 343-350.
- [25] Ziol M, Handra-Luca A, Kettaneh A, Christidis C, Mal F, Kazemi F, de Ledinghen V, Marcellin P, Dhumeaux D, Trinchet JC and Beaugrand M. Noninvasive assessment of liver fibrosis by measurement of stiffness in patients with chronic hepatitis C. *Hepatology* 2005; 41: 48-54.
- [26] Shi KQ, Fan YC, Pan ZZ, Lin XF, Liu WY, Chen YP and Zheng MH. Transient elastography: a meta-analysis of diagnostic accuracy in evaluation of portal hypertension in chronic liver disease. *Liver Int* 2013; 33: 62-71.
- [27] Fitzpatrick E, Quaglia A, Vimallesvaran S, Basso MS and Dhawan A. Transient elastography is a useful noninvasive tool for the evaluation of fibrosis in paediatric chronic liver disease. *J Pediatr Gastroenterol Nutr* 2013; 56: 72-76.
- [28] Foucher J, Castera L, Bernard PH, Adhoute X, Laharie D, Bertet J, Couzigou P and de Ledinghen V. Prevalence and factors associated with failure of liver stiffness measurement using FibroScan in a prospective study of 2114 examinations. *Eur J Gastroenterol Hepatol* 2006; 18: 411-412.
- [29] Kim SU, Seo YS, Cheong JY, Kim MY, Kim JK, Um SH, Cho SW, Paik SK, Lee KS, Han KH and Ahn SH. Factors that affect the diagnostic accuracy of liver fibrosis measurement by Fibroscan in patients with chronic hepatitis B. *Aliment Pharmacol Ther* 2010; 32: 498-505.
- [30] Bavu E, Gennisson JL, Couade M, Bercoff J, Mallet V, Fink M, Badel A, Vallet-Pichard A, Nalpas B, Tanter M and Pol S. Noninvasive in vivo liver fibrosis evaluation using supersonic shear imaging: a clinical study on 113 hepatitis C virus patients. *Ultrasound Med Biol* 2011; 37: 1361-1373.