

## Original Article

# Effect of hyperbaric oxygen on HIF-1 $\alpha$ expression in rat experimental periodontitis with psychological stress

Gang Wang<sup>1\*</sup>, Zhi-Rong Wu<sup>2\*</sup>, Rong Wang<sup>2</sup>, Juan Li<sup>2</sup>, Shi-Guang Huang<sup>2</sup>

<sup>1</sup>Department of Conservative Dentistry, Affiliated Zhongshan Hospital, Sun Yat-sen University, Zhongshan, P. R. China; <sup>2</sup>Faculty of Dentistry, School of Stomatology, Jinan University, Guangzhou, P. R. China. \*Equal contributors.

Received March 26, 2017; Accepted July 9, 2017; Epub August 15, 2017; Published August 30, 2017

**Abstract:** Objective: This study is to investigate the effect of hyperbaric oxygen (HBO) on HIF-1 $\alpha$  expression in rat experimental periodontitis with psychological stress. Methods: One hundred and twenty male special pathogen-free Wistar rats were randomly divided into four groups: normal control group, experimental periodontitis group, psychological stress stimulation group, and periodontitis model with stress stimulation group. Six rats from each experiment group were randomly chosen for HBO treatment for 2 weeks. Gingival index (GI) and periodontal attachment loss (AL) were measured before sacrifice. The expression of HIF-1 $\alpha$  was detected by immunohistochemistry. Results: The sites of gingival attachment were normal in control group and psychological stress stimulation group. The tissue damage was more severe, and the levels of GI, AL, and HIF-1 $\alpha$  expression scores in periodontal tissues were higher in periodontitis with stress stimulation group than that in experimental periodontitis group, while they were comparable in control group and psychological stress stimulation group. After HBO treatment, the levels of GI, AL, and HIF-1 $\alpha$  expression scores were significantly lower than that of the untreated groups ( $P < 0.05$ ). Conclusion: The results demonstrated that the severity of periodontitis was related to psychological stress and HBO could be effective on periodontitis and periodontitis with psychological stress in rat models.

**Keywords:** Periodontitis, animal model, psychological stress, hyperbaric oxygen, hypoxia-inducible factor-1 $\alpha$

## Introduction

Periodontal disease is a chronic and destructive disease of the gums and periodontal tissue characterized by the formation of periodontal pocket, the inflammation of pocket wall, and the loss of alveolar bone [1]. It is determined by 3 factors: the presence of pathogenic species, the absence of so-called "beneficial bacteria", and a susceptible host [2]. In addition, previous studies have demonstrated a relationship between psychological stress and periodontitis [3].

More recent studies indicate that psychosocial stress represents a risk indicator for periodontal disease and should be addressed before and during treatment [4]. Studies have shown that stress, by stimulating the locus coeruleus-noradrenergic neurons/sympathetic-adrenal medullary axis, could cause a rapid increase of the concentration of epinephrine and norepinephrine in the plasma, regulate the body's response to acute stress, and then mediate a

series of metabolic and cardiovascular compensatory mechanisms [5]. To overcome the damages caused by stress, the compensatory pathways that could regulate heart rate and peripheral vascular resistance, inhibit insulin secretion, and stimulate glucagon secretion, are induced. This could result in the contraction of outer periphery microvascular and lead to the reduction of oxygen metabolism of periodontal tissue [6]. In addition, the swelling of gum tissue could cause poor local perfusion in periodontitis patients and in turn lead to the significant decrease of oxygen content in periodontal tissue [7, 8].

HIF-1 $\alpha$  is a key factor for cell hypoxia adaptation. Recent studies have shown that HIF-1 $\alpha$  is important in inflammatory process regulation [9, 10]. It's difficult to detect HIF-1 $\alpha$  in normal oxygen state, while hypoxic environment induces a rapid increase of HIF-1 $\alpha$  protein. Therefore, tissue oxygen metabolism could be reflected by detecting the expression of HIF-1 $\alpha$  protein in local tissue. HIF-1 $\alpha$  protein increase indicates

## Hyperbaric oxygen affects HIF-1 $\alpha$ expression

oxygen metabolism decline or that the tissue is in a hypoxic state.

Hyperbaric oxygen (HBO) has been successfully used in several medical applications [11] and its therapeutic effect is related to elevated partial oxygen pressure in the tissues. HBO could inhibit the growth and survival of anaerobic bacteria, which are the most common etiological agents of periodontal diseases [12]. Studies have shown that oxygen at 0.2 MPa could inhibit the growth of certain pathogens associated with periodontitis [13]. HBO exposure can increase local oxygen delivery, which will raise oxygen concentration in the periodontal pocket base to inhibit the growth of anaerobes and supply enough oxygen for ischemic tissues to facilitate early recovery of tissue metabolism [14]. More experiments confirm that HBO could inhibit the growth of anaerobes in the periodontal pockets of humans and animals, improve gingival microcirculation, and increase gingival blood flow [15-17]. Dental plaque index (PLI), GI, probing depth (PD), and AL decrease significantly after HBO treatment for patients with chronic periodontitis [18-20]. Additionally, previous studies have shown that HBO has good therapeutic effects on human severe periodontitis [18, 19, 21, 22].

This study aimed to investigate the effect of HBO on HIF-1 $\alpha$  expression in rat experimental periodontitis with psychological stress. In addition, the pathogenesis of periodontitis related to psychological stress and the effect of HBO therapy on periodontitis were assessed. The results would improve the scientific and rational interventions for periodontitis with or without psychological stress.

### Materials and methods

#### Materials

A total of 120 Wistar rats of specific pathogen-free (SPF) grade were purchased from the Experimental Animal Center of Sun Yat-sen University, Guangzhou, P. R. China. *Porphyromonas gingivalis* strains (*P. gingivalis* ATCC 33277) were provided by the laboratory of Jinan University, Guangzhou, P. R. China. Rat anti-HIF-1 $\alpha$  immunohistochemical kit was provided by Wuhan Boster Biologic Technology, P. R. China. YLC 0.5/1 infant hyperbaric oxygen chamber was provided by Xi'an 701 Institute, P. R. China.

#### Preparation of periodontal pathogens attachment thread

The 3/0 sterile silk thread was placed in the modified GAM medium (1 mg/L of vitamin K1, 5% defibrinated sheep blood) containing *P. gingivalis* ATCC 33277 and was cultured in anaerobic incubator (volume fraction: 80% N<sub>2</sub>, 10% H<sub>2</sub>, 10% CO<sub>2</sub>) for 5 days under 37°C.

#### Animal modeling

Before the experiment, 120 male Wistar rats (8/9-week-old) were raised at a constant temperature (22°C) for 7 days. The rats were numbered and assigned randomly and were divided into four groups with 30 rats in each group. The 4 groups were: normal control group, stress-stimulation group, experimental periodontitis group, and experimental periodontitis plus stress-stimulation group. For normal control group, no treatment was performed to the periodontal tissue. Rats in stress-stimulation group were treated with experimental psychological-stress-stimulation daily from 0 d.; For experimental periodontitis group, periodontitis was induced by wrapping a 3/0 silk ligature soaked with *P. gingivalis* at the gingival margins of the left second maxillary molar after anesthesia with sodium pentobarbital to set up periodontitis models. And for rats in experimental periodontitis plus stress-stimulation group, the same treatment was carried out as experimental periodontitis group, and they were additionally exposed to psychological stress daily from 0 d. Except for the normal control group, psychological stress was removed at 9th week, and 6 rats from each experiment group were randomly chosen to HBO treatment. The rats, 6 in each group, were sacrificed at the end of 2, 4 and 8 weeks after experiment and 12 rats in each group were sacrificed at the end of 10 weeks.

#### Stress strategies

There were three types of stress strategies in this study: 1) restrictive stress, where the rats were placed in small cages with limited space, and their activities and diet were restricted for 2 hours; 2) cold-water-immersion stress, where the rats were placed in small cages, and immersed above their clavicles in coldwater for 2 hours; and 3) cat-shock stress, female cats in estrus that were purring, pawing, caterwauling, impatient, and restless were chosen, and the

## Hyperbaric oxygen affects HIF-1 $\alpha$ expression

rats were put in the cat cages for 12 hours. To mimic the real source of variable and unpredictable social stress, one of the three stress strategies was randomly applied to the stress group rats every day after the experiment began.

### *HBO treatment*

Except normal control group, stress stimulation was removed at 9th week, and 6 rats from each of the other experiment groups were randomly chosen for HBO treatment (0.25 Mpa, YLC 0.5/1 infant hyperbaric oxygen chamber). The other rats were untreated. HBO treatment was applied once a day and 60 minutes every time. These animals were given continuous HBO treatment for 2 weeks and then were sacrificed at the end of the 10th week.

### *Measurements of GI and periodontal AL*

The rats were anesthetized with 0.3% pentobarbital sodium through intraperitoneal injection and were placed in supine position. Then a blunt periodontal probe was used to check the periodontal situation of their posterior teeth. The GI were measured according to the Löe-Silness method [2] and divided into 4 degrees: 0 = Normal gingiva; 1 = Mild inflammation-slight change in color and slight edema, and no bleeding on probing; 2 = Moderate inflammation-redness, edema, glazing and bleeding on probing; 3 = Severe inflammation-marked redness, edema, ulceration and tendency to spontaneous bleeding. The gum tissue of each experimental tooth was checked and 4 sites (mesial buccal gingival papilla, buccal gingival margin, distal buccal papilla, and lingual gingival papillae) were evaluated. The final score was the average of the above four sites. Periodontal probe was used to detect the depth of periodontal pockets. Both the scale unit of the periodontalprobe and the diameter of its work terminal were 0.2 mm. The distance from cemento-enamel junction (CEJ) to the pocket bottom is AL. Six surfaces for each experimental tooth were evaluated: mesial surface, middle surface, and distal surface of both buccal and palatal. The average of six measurements was measured as final score.

### *Hematoxylin and eosin (HE) staining*

The maxillae were removed and cut from the middle and were fixed in 10% buffered formalin

(pH = 7.0) for a period of over 48 hours. The specimens were then decalcified by mixed decalcification solution. The tissue was embedded with paraffin and was sliced into 6  $\mu$ m sections. The slices were stained with HE and covered with neutral gum. Then the histological changes of periodontal tissues could be observed under an optical microscope (Olympus, Tokyo, Japan).

### *Immunohistochemistry*

Rabbit anti-rat HIF-1 $\alpha$  antibody (1:50 dilution) was replaced by PBS in the negative control (NC) group. Slides were counterstained in hematoxylin. Immunohistochemical positive signal showed as brown fine particles located in the nucleus or cytoplasm. The positive cells of each sample slice were counted. The total number of cells and the number of positive cells of each sample slice in five visual fields was recorded under a microscope (Olympus, Tokyo, Japan). The positive cell rate (%), namely the positive cells proportion of the total number of cells was then calculated. The mean value represented the average rate of positive cells for specimen slices.

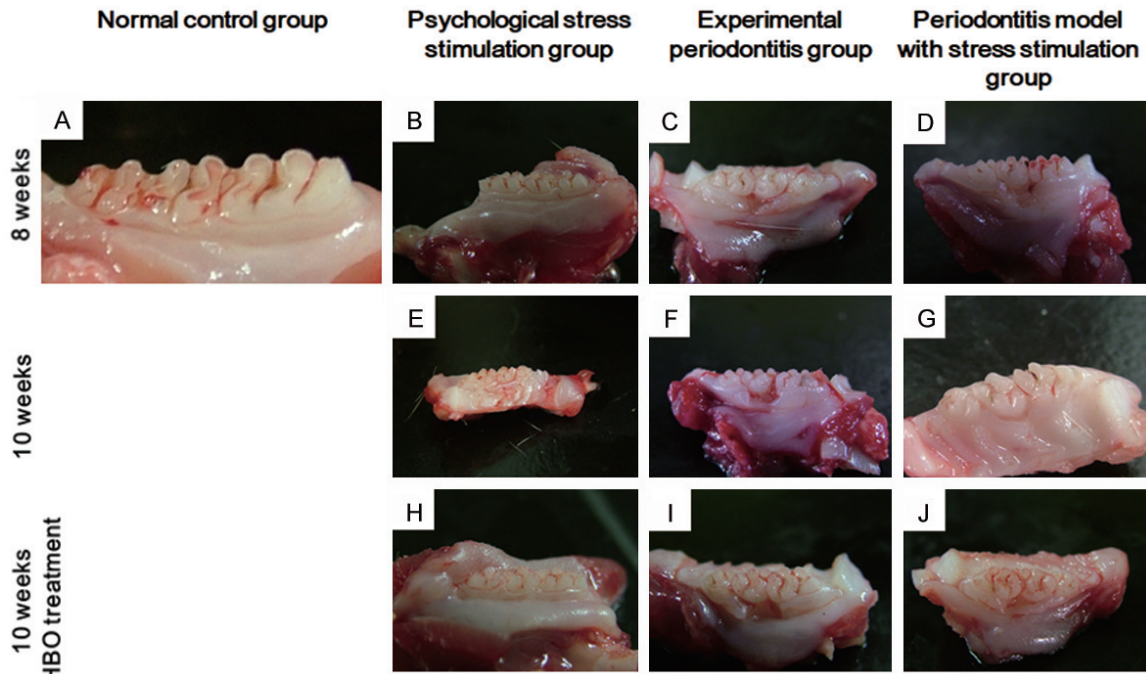
### *Statistical analysis*

The SPSS13.0 (SPSS Inc., Chicago, IL, USA) program was utilized for our data analysis. All data were expressed in the form of mean  $\pm$  standard deviation ( $\bar{x} \pm s$ ). Completely randomized design ANOVA (One-way analysis of variance, One-Way ANOVA) was used to compare multiple samples. When each group shared homogeneity of variance, least significant difference (LSD) Test way was used to the pairwise comparison of multiple samples means. If heterogeneity of variance occurs, Tamhane's T2 Test was used.  $P < 0.05$  was considered statistically significant.

## Results

### *Periodontal clinical manifestations*

In order to evaluate the changes of corresponding periodontal condition, periodontal clinical manifestations of the rats was observed. At 8 weeks after ligature, no significant changes were found in the structure of gingival epithelium and the periodontal attachment site between normal control group and stress-stimulation group (**Figure 1A, 1B, 1E and 1H**). The



**Figure 1.** The changes of tooth morphology in the four groups. (A) Normal control group; (B, E, H) Psychological stress stimulation group at the time point of 8 weeks (B), 10 weeks (E) and 10 weeks with HBO treated (H); (C, F, I) Experimental periodontitis group at the time point of 8 weeks (C), 10 weeks (F) and 10 weeks with HBO treated (I); (D, G, J) Experimental periodontitis group at the time point of 8 weeks (D), 10 weeks (G) and 10 weeks with HBO treated (J).

**Table 1.** Changes of gingival index in each group at different times ( $\bar{x} \pm s$ , n = 6)

Groups	2 weeks	4 weeks	8 weeks	10 weeks	
				Untreated by HBO	Treated by HBO
Normal control	0.13 $\pm$ 0.14	0.38 $\pm$ 0.14	0.38 $\pm$ 0.25	0.42 $\pm$ 0.21	0.42 $\pm$ 0.21
Psychological stress stimulation	0.25 $\pm$ 0.20	0.44 $\pm$ 0.24	0.38 $\pm$ 0.14	0.40 $\pm$ 0.15	0.41 $\pm$ 0.22
Experimental periodontitis	0.43 $\pm$ 0.21	1.06 $\pm$ 0.18 $\diamond$	1.69 $\pm$ 0.24 $\diamond$ $\blacktriangle$	1.72 $\pm$ 0.20 $\diamond$ $\blacktriangle$	0.43 $\pm$ 0.25 $\blacktriangledown$
Periodontitis model with stress stimulation	0.53 $\pm$ 0.29	2.13 $\pm$ 0.14 $\blacktriangle$	2.44 $\pm$ 0.31 $\blacktriangle$ $\blacktriangle$	2.49 $\pm$ 0.21 $\blacktriangle$ $\blacktriangle$	0.43 $\pm$ 0.14 $\blacktriangledown$

$\diamond$   $P < 0.01$  vs normal control group;  $\blacktriangle$   $P < 0.01$  vs normal control group and experimental periodontitis group;  $\blacktriangle$   $P < 0.01$  vs 4 weeks after operation in the same group;  $\blacktriangledown$   $P < 0.05$  vs untreated by HBO.

experimental periodontitis group showed mild gingival atrophy and shallow periodontal pocket, but no obvious AL at the end of 2 weeks appeared. However, gingival atrophy and obvious AL at the end of 4 weeks was found, and AL was more obvious at the end of 8 weeks (Figure 1C). At the end of 10 weeks, attachment loss of untreated group continued to increase, whereas that of HBO treatment group alleviated (Figure 1F, 1I). The experimental periodontitis plus stress-stimulation group showed obvious periodontal pocket and AL at the end of 2 weeks. In addition, AL aggravated at the end of 4 weeks. Moreover, at 8 weeks, the furcation of tooth root was exposed, involving both sides of

adjacent teeth (Figure 1D). At the end of 10 weeks, attachment loss of untreated group continued to increase, while the gingival edema alleviated and periodontal pocket became shallow in HBO treatment group (Figure 1G and 1H). Together, the results showed that gum edema reduced and periodontal probing depth shallowed after HBO treatment.

#### G $i$ and periodontal AL assessments

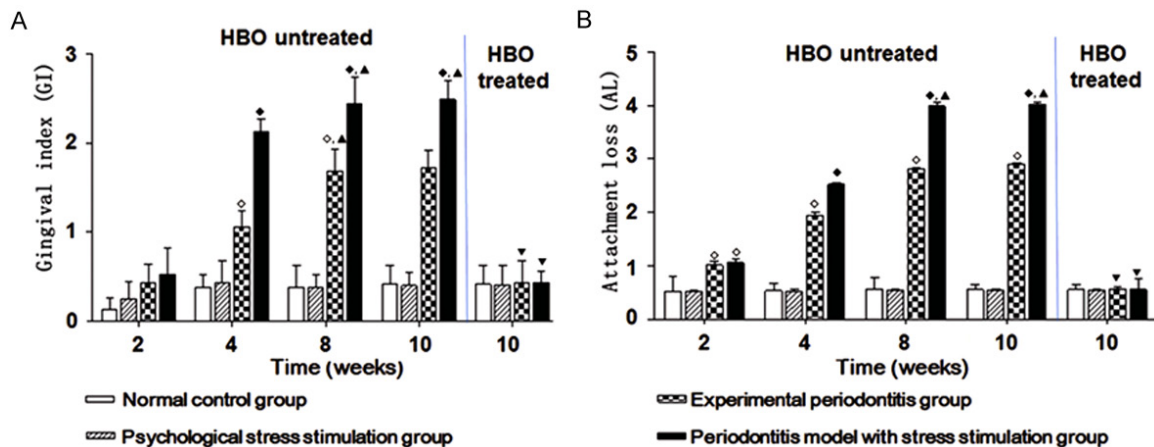
The changes of GI and AL in each group were shown in Tables 1, 2 and Figure 2. There were no significant difference of both GI and AL between the stress-stimulating group and nor-



**Table 2.** Changes of AL in each group at different times ( $\bar{x}\pm s$ , n = 6)

Groups	2 weeks	4 weeks	8 weeks	10 weeks	
				Untreated by HBO	Treated by HBO
Normal control	0.51 $\pm$ 0.30	0.53 $\pm$ 0.14	0.56 $\pm$ 0.22	0.55 $\pm$ 0.10	0.55 $\pm$ 0.10
Psychological stress stimulation	0.51 $\pm$ 0.03	0.52 $\pm$ 0.04	0.54 $\pm$ 0.02	0.54 $\pm$ 0.02	0.54 $\pm$ 0.01
Experimental periodontitis	1.01 $\pm$ 0.08 $\diamond$	1.94 $\pm$ 0.06 $\diamond$	2.82 $\pm$ 0.01 $\diamond$	2.90 $\pm$ 0.02 $\diamond$	0.56 $\pm$ 0.04 $\nabla$
Periodontitis model with stress stimulation	1.06 $\pm$ 0.08 $\diamond$	2.52 $\pm$ 0.03 $\blacklozenge$	3.99 $\pm$ 0.08 $\blacklozenge$ $\blacktriangle$	4.01 $\pm$ 0.06 $\blacklozenge$ $\blacktriangle$	0.55 $\pm$ 0.20 $\nabla$

$\diamond P < 0.01$  vs normal control group;  $\blacklozenge P < 0.01$  vs normal control group and experimental periodontitis group;  $\blacktriangle P < 0.01$  vs 4 weeks after operation;  $\nabla P < 0.05$  vs untreated by HBO.



**Figure 2.** The changes of GI and AL in each group at different times ( $\bar{x}\pm s$ , n = 6).  $\diamond P < 0.01$  vs normal control group;  $\blacklozenge P < 0.01$  vs normal control group and experimental periodontitis group;  $\blacktriangle P < 0.01$  vs 4 weeks after operation in the same group;  $\nabla P < 0.05$  vs untreated by HBO.

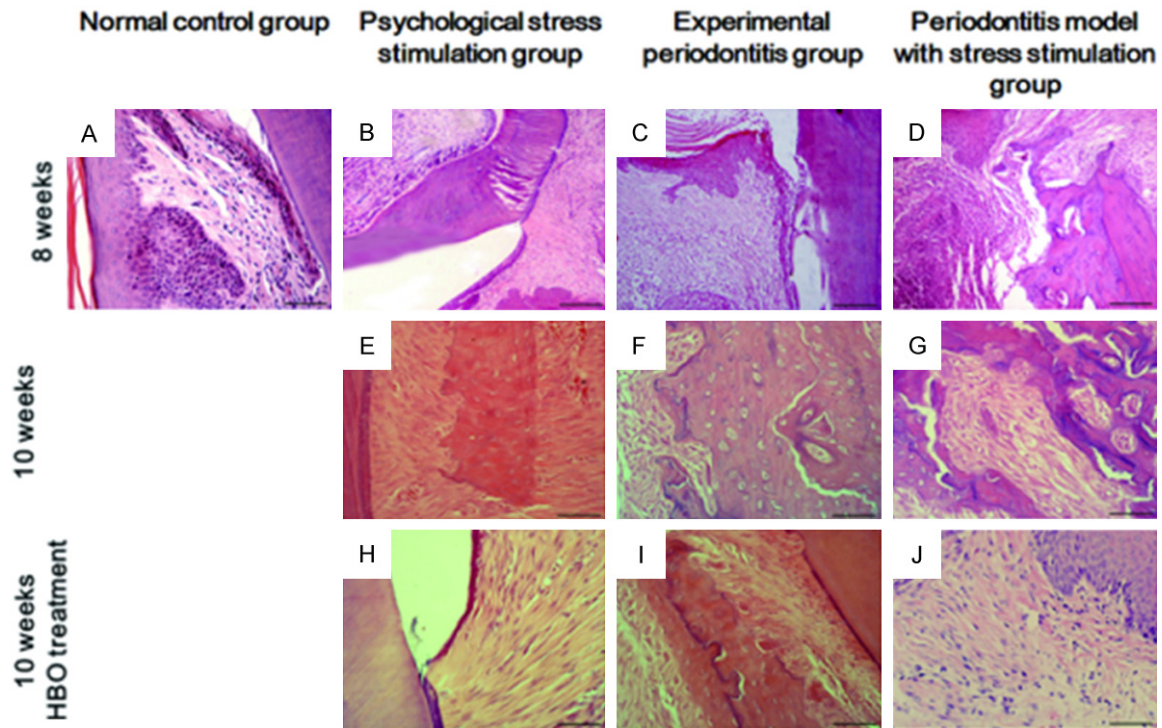
mal control group at each time point ( $P > 0.05$ ). Compared with the normal control group and stress-stimulating group, the experimental periodontitis group and the periodontitis with stress-stimulation group had significantly higher levels of GI and AL at each time point ( $P < 0.01$ ), and they increased significantly with time ( $P < 0.01$ ). Additionally, the GI and AL values of the periodontitis with stress-stimulation group were significantly higher than that of the experimental periodontitis group at 4 and 8 weeks ( $P < 0.01$ ). After HBO treatment, the GI and AL values of each group decreased and were significantly different from the untreated group ( $P < 0.05$ ). To sum up, the results argued that GI and periodontal AL had similar varying tendency and were significantly decreased than that of untreated group.

#### Histologic changes

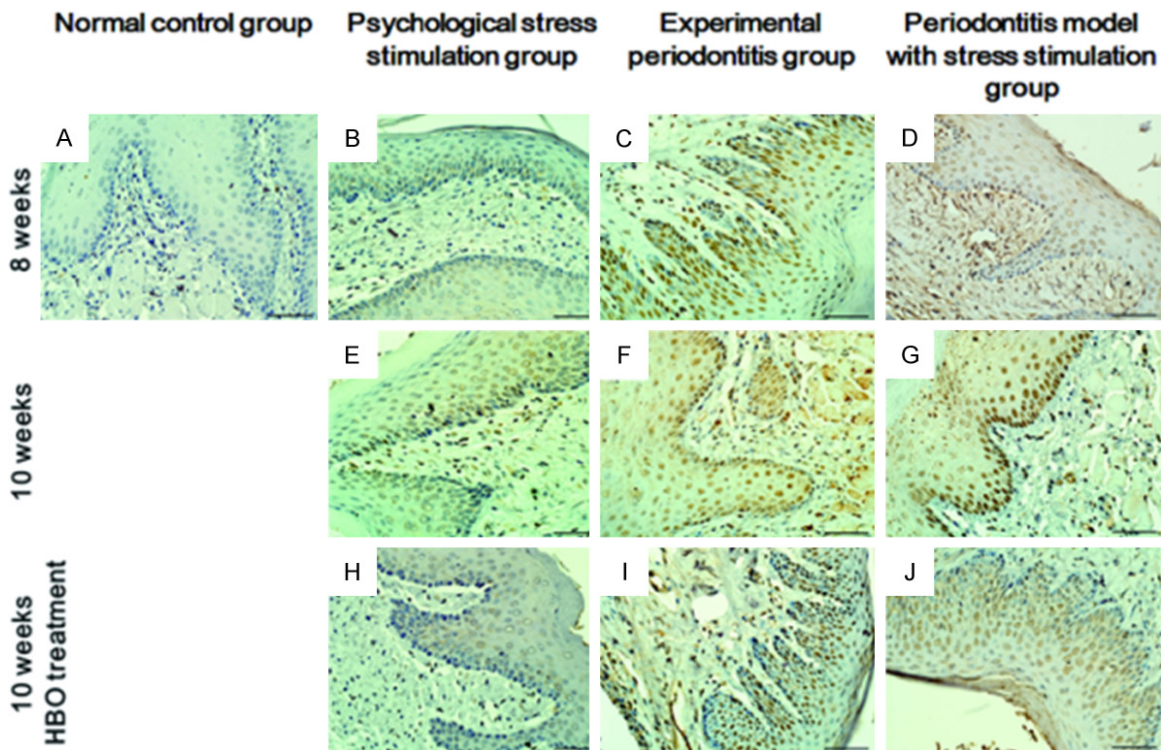
In order to testify the histologic changes in each group, HE staining was performed. There was no significant inflammation in periodontal

tissues in both the normal control group (Figure 3A) and stress-stimulation group, and no abnormal junctional epithelium, periodontal ligament fibers, or inherental veolar were detected (Figure 3B, 3E and 3H). A moderate periodontal inflammation in the experimental periodontitis group was observed. Ulceration of gingival epithelium was observed, and connective epithelium was separated from the root surface and migrated apically. A large number of inflammatory cells appeared in the deeper periodontal tissue, the structure of periodontal membrane was destroyed, and edema and denaturation of collagen fibers were found. In addition, vascular dilatation and congestion could be detected and active osteoclasts and dimple-like bone resorption occurred on the surface of alveolar bone. After HBO therapy, the above condition alleviated (Figure 3C, 3F and 3I). In the periodontitis with stress-stimulation group, the above phenomena showed more significant and more serious. The inflammation of rats' periodontal tissue decreased, inflammatory cells in the connective tissue reduced, and the

## Hyperbaric oxygen affects HIF-1 $\alpha$ expression



**Figure 3.** The inflammation in periodontal tissues were assayed (scale bars = 50  $\mu$ m, original magnification 400 $\times$ ). (A) Normal control group; (B, E, H) Psychological stress stimulation group at the time point of 8 weeks (B) 10 weeks (E) and 10 weeks with HBO treated (H); (C, F, I) Experimental periodontitis group at the time point of 8 weeks (C) 10 weeks (F) and 10 weeks with HBO treated (I); (D, G, J) Experimental periodontitis group at the time point of 8 weeks (D) 10 weeks (G) and 10 weeks with HBO treated (J).



**Figure 4.** Immunohistochemically staining results of HIF-1 $\alpha$  (scale bars = 50  $\mu$ m, original magnification 400 $\times$ ). (A) Normal control group; (B, E, H) Psychological stress stimulation group at the time point of 8 weeks (B) 10 weeks (E)

## Hyperbaric oxygen affects HIF-1 $\alpha$ expression

and 10 weeks with HBO treated (H); (C, F, I) Experimental periodontitis group at the time point of 8 weeks (C) 10 weeks (F) and 10 weeks with HBO treated (I); (D, G, J) Experimental periodontitis group at the time point of 8 weeks (D) 10 weeks (G) and 10 weeks with HBO treated (J).

**Table 3.** The average positive cell rate of HIF-1 $\alpha$  in each group at different times (% ,  $\bar{x} \pm s$ , n = 6)

Groups	2 weeks	4 weeks	8 weeks	10 weeks	
				Untreated by HBO	Treated by HBO
Normal control	0.02 $\pm$ 0.01	0.03 $\pm$ 0.01	0.03 $\pm$ 0.01	0.03 $\pm$ 0.01	0.03 $\pm$ 0.01
Psychological stress stimulation	0.01 $\pm$ 0.01	0.03 $\pm$ 0.01	0.04 $\pm$ 0.01	0.04 $\pm$ 0.01	0.03 $\pm$ 0.02
Experimental periodontitis	0.02 $\pm$ 0.01	12.65 $\pm$ 1.26 $\diamond$	31.05 $\pm$ 1.48 $\diamond$	31.72 $\pm$ 1.54 $\diamond$	0.03 $\pm$ 0.02 $\blacktriangledown$
Periodontitis model with stress stimulation	0.01 $\pm$ 0.01	24.73 $\pm$ 2.24 $\blacklozenge$	79.47 $\pm$ 2.85 $\blacklozenge$ $\blacktriangle$	80.11 $\pm$ 1.96 $\blacklozenge$ $\blacktriangle$	0.04 $\pm$ 0.01 $\blacktriangledown$

$\diamond$ P<0.01 vs normal control group;  $\blacklozenge$ P<0.01 vs normal control group and experimental periodontitis group;  $\blacktriangle$ P<0.01 vs 4 wk after operation in the same group;  $\blacktriangledown$ P<0.01 vs untreated by HBO.

number of open blood vessels in periodontal tissues increased after HBO treatment (**Figure 3D, 3G and 3H**).

### Immunohistochemical staining results of HIF-1 $\alpha$

To investigate the expression of HIF-1 $\alpha$  in tissues, immunohistochemical staining was carried out. The immunohistochemical positive signal of HIF-1 $\alpha$  showed as brown fine particles located in the nucleus or cytoplasm. Only a few HIF-1 $\alpha$ -weak-positive-expression cells were observed in the normal control group and stress-stimulating group (**Figure 4A, 4B, 4E and 4H**). More cells with HIF-1 $\alpha$ -positive-expression were observed in the experimental periodontitis group (**Figure 4C, 4F and 4I**). A large number of cells with HIF-1 $\alpha$ -strong-positive-expression were found in the experimental periodontitis with stress-stimulation group. After HBO treatment, the cells with HIF-1 $\alpha$ -positive-expression decreased (**Figure 4D, 4G and 4H**).

The average rates of HIF-1 $\alpha$ -positive cells in each experimental group were shown in **Table 3**. Statistical results showed that there was no significant difference of the average rates of HIF-1 $\alpha$ -positive cells between the stress-stimulating group and normal control group at each time point ( $P>0.05$ ), while the average rates of HIF-1 $\alpha$ -positive cells in the experimental periodontitis group and the periodontitis with stress-stimulation group were significantly higher at each time point ( $P<0.01$ ), compared with the normal control group and stress-stimulating group. Further analysis found that the average rates of HIF-1 $\alpha$ -positive cells in the experimental periodontitis plus stress-stimulation group were significantly higher than the

experimental periodontitis group at 4 and 8 weeks ( $P<0.01$ ). And the average rates of HIF-1 $\alpha$ -positive cells in the periodontitis with stress-stimulation group at 8 weeks were significantly higher than that at 4 weeks ( $P<0.01$ ). After HBO treatment, the average rates of HIF-1 $\alpha$ -positive cells in each group decreased and were significantly different from the untreated group ( $P<0.05$ ). It is possible to assume that HBO treatment could reduce the danger in rat experimental periodontitis with psychological stress.

### Discussion

In addition to bacterial infections, adverse effects of immunological changes in particular stress factors, may represent precipitating parameters of inflammatory periodontal diseases [23, 24]. Several questionnaire studies have demonstrated a positive relationship between psychological stress and periodontal diseases [25]. Breivik et al. [26] show that in the rat model, stress in early postnatal life would increase the severity of experimental periodontitis. Semen off and coworkers [27] find that the chronic stress, which the neonatal rats suffered, has an effect on the progression of adult periodontal ligation induced periodontitis. Unfortunately, a direct association between periodontal disease and stress remains to be proven. This is partly due to the lack of an adequate animal model and the difficulty in quantifying amount and duration of stress. In this study, three types of stress strategies (restrictive stress, cold-water-immersion stress, and cat-shock stress) were used so as to mimic the real source of variable and unpredictable social stress. The results argued that GI and AL levels and the destruction of periodontal tissues in



the periodontitis with stress-stimulation group were significantly higher than that of the experimental periodontitis group at the end of 4 weeks and 8 weeks ( $P < 0.01$ ), while there was no significant difference between normal control group and stress-stimulation group at each time point. Our results indicated that psychological stress alone could not cause significant periodontal inflammation; however, it could aggravate periodontal inflammation.

Oxygen metabolism in local tissue can be reflected by HIF-1 $\alpha$  expression. HIF-1 is a basic helix-loop-helix superfamily member which is composed of  $\alpha$  and  $\beta$  subunits. HIF-1 $\beta$  can be found in all cells, while HIF-1 $\alpha$  is not detected in normal oxygen state. HIF-1 $\alpha$  is a key factor for cell hypoxia adaptation, and plays key roles in many physiological and pathological processes [28]. The expression of HIF-1 $\alpha$  protein can be induced by the hypoxia environment of local inflammatory tissue rapidly [29]. Therefore, tissue oxygen metabolism could be reflected by detecting the expression of HIF-1 $\alpha$  protein in local tissue. In our experiments, by detecting the expression of HIF-1 $\alpha$  protein in periodontal tissue, the condition of tissue oxygen metabolism was measured, and the degree of tissue hypoxia was assessed by calculating the average rate of HIF-1 $\alpha$ -positive cells. Our results showed that oxygen metabolism would decline and stay in a hypoxic state when periodontal tissue was under an inflammatory state. Stress did not significantly affect the oxygen metabolism of normal periodontal tissue, however, it could significantly reduce oxygen metabolism of the periodontal tissue with inflammation. Therefore, it increased the hypoxia condition of periodontal tissue, which then aggravated periodontitis. Manhold et al. [30] also show that long-term emotional state can lead to the reduction of oxygen and nutrients supply, and reduce the ability of periodontal tissue to fight against bacteria. Additionally, they found that the ability of periodontal tissue to use oxygen would reduce when the rats were under stress [30]. Hyperbaric oxygen (HBO) has been successfully used in several medical applications [11]. It has been reported that HBO has significant therapeutic effects on senile periodontitis and periodontitis after periodontal flap surgery [20, 31, 32]. Costantino and colleagues [33] reported that HBO therapy could reduce the incidence and severity of bone necrosis and inhibit alveolar resorption. Although HBO could

inhibit the reproduction and growth of anaerobes in periodontitis, the detailed mechanism still needs further investigation [12]. In this study, after HBO therapy, the periodontal probing depth shallowed, and no obvious gingival edema could be seen. PI and AL levels in each group decreased significantly. Inflammatory destruction of periodontal tissue alleviated, and the number of inflammatory cells reduced. The average rate of HIF-1 $\alpha$ -positive cells was significantly decreased, showing that HBO therapy has effects on correcting the hypoxia state of periodontal inflammation. All the above results indicated that HBO treatment could significantly improve the oxygen supply of the periodontal tissues and thereby was of great benefit to periodontitis and periodontitis associated psychological stress.

In summary, our data showed that the severity of periodontitis was related to psychological stress and the tissue hypoxic state. HBO could elevate partial oxygen supply successfully in hypoxic state in periodontal tissues, which was effective on periodontitis and periodontitis with psychological stress in rat models.

### Acknowledgements

This study was supported by Science and Technology Planning Project of Guangdong Province, China (No.2013B021800043 and No.2014A020212212).

### Disclosure of conflict of interest

None.

**Address correspondence to:** Shi-Guang Huang, Faculty of Dentistry, School of Stomatology, Jinan University, 601 Huangpu Avenue West, Guangzhou 510632, P. R. China. Tel: +86-13002019868; E-mail: hangshiguang\_l@163.com

### References

- [1] Thornton-Evans G, Eke P, Wei L, Palmer A, Moeti R, Hutchins S, Borrell LN; Centers for Disease Control and Prevention (CDC). Periodontitis among adults aged  $\geq 30$  years-United States, 2009-2010. *MMWR Suppl* 2013; 62: 129-135.
- [2] Slots J. Periodontology: past, present, perspectives. *Periodontol* 2000 2013; 62: 7-19.
- [3] Evers AW, Verhoeven EW, van Middendorp H, Sweep FC, Kraaimaat FW, Donders AR, Eijssbouts AE, van Laarhoven AI, de Brouwer SJ,



## Hyperbaric oxygen affects HIF-1 $\alpha$ expression

- Wirken L, Radstake TR and van Riel PL. Does stress affect the joints? Daily stressors, stress vulnerability, immune and HPA axis activity, and short-term disease and symptom fluctuations in rheumatoid arthritis. *Ann Rheum Dis* 2014; 73: 1683-1688.
- [4] Hildebrand HC, Epstein J, Larjava H. The influence of psychological stress on periodontal disease. *J West Soc Periodontol Periodontol Abstr* 2000; 48: 69-77.
- [5] Harris RB. Chronic and acute effects of stress on energy balance: are there appropriate animal models? *Am J Physiol Regul Integr Comp Physiol* 2015; 308: R250-265.
- [6] Henderson B. Integrating the cell stress response: a new view of molecular chaperones as immunological and physiological homeostatic regulators. *Cell Biochem Funct* 2010; 28: 1-14.
- [7] Gözl L, Memmert S, Rath-Deschner B, Jäger A, Appel T, Baumgarten G, Götz W and Frede S. LPS from *P. gingivalis* and hypoxia increases oxidative stress in periodontal ligament fibroblasts and contributes to periodontitis. *Mediators Inflamm* 2014; 2014: 986264.
- [8] Gözl L, Memmert S, Rath-Deschner B, Jäger A, Appel T, Baumgarten G, Götz W, Frede S. Hypoxia and *P. gingivalis* synergistically induce HIF-1 and NF- $\kappa$ B activation in PDL cells and periodontal diseases. *Mediators Inflamm* 2015; 2015: 438085.
- [9] Cramer T, Yamanishi Y, Clausen BE, Förster I, Pawlinski R, Mackman N, Haase VH, Jaenisch R, Corr M, Nizet V, Firestein GS, Gerber HP, Ferrara N, Johnson RS. HIF-1 $\alpha$  is essential for myeloid cell-mediated inflammation. *Cell* 2003; 112: 645-57.
- [10] Liu JB, Ding JQ and Wang L. Immunohistochemistry localization of HIF-1 $\alpha$  in inflammatory dental pulp. *Journal of Clinical Stomatology* 2003; 19: 77-78.
- [11] Weaver LK. Hyperbaric oxygen treatment for the critically ill patient. *Diving Hyperb Med* 2015; 45: 1.
- [12] Chen TL, Xu B, Liu JC, Li SG, Li DY, Gong GC, Wu ZF, Lin SL and Zhou YJ. Effects of hyperbaric oxygen on aggressive periodontitis and subgingival anaerobes in Chinese patients. *J Indian Soc Periodontol* 2012; 16: 492-497.
- [13] Nogueira-Filho GR, Rosa BT, David-Neto JR. Effects of hyperbaric oxygen therapy on the treatment of severe cases of periodontitis. *Undersea Hyperb Med* 2010; 37: 107-114.
- [14] Grassmann JP, Schneppendahl J, Sager M, Hakimi AR, Herten M, Loegters TT, Wild M, Hakimi M, Windolf J and Jungbluth P. The effect of bone marrow concentrate and hyperbaric oxygen therapy on bone repair. *J Mater Sci Mater Med* 2015; 26: 5331.
- [15] Chen TL, Xu B, Liu JC, Li SG, Li DY, Gong GC, Wu ZF, Lin SL and Zhou YJ. Biological effects of hyperbaric oxygen on severe human periodontitis. *Undersea Hyperb Med* 2002; 29: 159-166.
- [16] Chen T, Lin S, Liu J, Xu B, Hai J and Tang D. Effects of hyperbaric oxygen to adult and juvenile periodontitis and subgingival anaerobes. *West China Journal for Stomatology* 1998; 16: 332-334.
- [17] Cheng TL, Liu JC, Lin SL, Xu B, Liu GQ, Song PZ, Wang G, Zhang XH, Yang M. Effect of hyperbaric oxygen on subgingival plaque of experimental periodontitis in animals. *Stomatology* 2003; 23: 270-271.
- [18] Chen TL, Lin SL, Li CL, Liu JC, Xu B, Lv YL, Liu GQ, Song PZ and Wang G. Effect of HBO on experimental periodontitis and gingival blood flows in animal. *Stomatology* 2002; 22: 60-61.
- [19] Chen TL, Lin SL, Liu GQ, Liu JC, Song PZ, Xu B, Zhang XH, Wang G, Chen J. Effect and holding time of hyperbaric oxygen on human severe periodontitis. *Shanghai Kou Qiang Yi Xue* 2003; 12: 403-5.
- [20] Chen TL, Lin SL, Liu JC, Xu B, Hai J, Tang D. Effects and mechanism of hyperbaric oxygen on prostaglandins in alveolar bone and gingival of experimental periodontitis in animal. *Zhonghua Kou Qiang Yi Xue Za Zhi* 2002; 37: 228-230.
- [21] Chen TL, Lin SL and Lu YL. The blood flow, blood current velocity and blood concentration in gingiva of the patients with periodontal diseases. *J Pract Stomatol* 1999; 15: 33-34.
- [22] Chen TL, Lin SL, Xu ZC, Liu JC, Du Y and Wang XX. Effect of HBO on gingival micro-blood-vessels and microcirculation. *Chinese Journal of Microcirculation* 1999; 9: 10-11.
- [23] Semenov TA, Rosa Júnior A, Borges ÁH, Porto AN, Caporossi C and Semenov Segundo A. Effect of chronic stress in newborn rats on the progression of ligature-induced-periodontitis in adulthood. *Acta Cir Bras* 2013; 28: 652-656.
- [24] Huang S, Lu F, Zhang Z, Yang X and Chen Y. The role of psychologic stress-induced hypoxia-inducible factor-1 $\alpha$  in rat experimental periodontitis. *J Periodontol* 2011; 82: 934-941.
- [25] Peruzzo DC, Benatti BB, Ambrosano GM, Nogueira-Filho GR, Sallum EA, Casati MZ, Nociti FH Jr. A systematic review of stress and psychological factors as possible risk factors for periodontal disease. *J Periodontol* 2007; 78: 1491-504.
- [26] Semenov-Segundo A, Borges ÁH, Bandeca MC, Porto AN, Pedro FL, Santos RS, Tonetto MR and Semenov TA. Effect of chronic stress on ligature-induced periodontitis in inbred and noninbred rats: a radiographic study. *J Contemp Dent Pract* 2014; 15: 556-560.
- [27] Semenov TA, Rosa Júnior A, Borges ÁH, Porto AN, Caporossi C and Semenov Segundo A. Ef-

## Hyperbaric oxygen affects HIF-1 $\alpha$ expression

- fect of chronic stress in newborn rats on the progression of ligature-induced-periodontitis in adulthood. *Acta Cir Bras* 2013; 28: 652-656.
- [28] Fallone F, Britton S, Nieto L, Salles B, Muller C. ATR controls cellular adaptation to hypoxia through positive regulation of hypoxia-inducible factor 1 (HIF-1) expression. *Oncogene* 2013; 32: 4387-96.
- [29] Xie HC, He JP, Zhu JF, Li JG. Expression of HIF-1 $\alpha$  and VEGF in skeletal muscle of plateau animals in response to hypoxic stress. *Physiol Res* 2014; 63: 801-5.
- [30] Manhold JH, Doyle JL and Weisinger EH. Effects of social stress on oral and other bodily tissues. II. Results offering substance to a hypothesis for the mechanism of formation of periodontal pathology. *J Periodontol* 1971; 42: 109-111.
- [31] Zhou C, Yang XM and Zhan B. Effects of HBO on human periodontitis in the aged. *Practical Journal of Clinical Medicine* 2004; 1: 53-54.
- [32] Lai SP, Huang F. Observation of the therapeutic effects of hyperbaric oxygen on periodontitis after periodontal flap surgery. *J Dent Prev Treat* 2004; 12: 175-176.
- [33] Costantino PD, Friedman CD and Steinberg MJ. Irradiated bone and its management. *Otolaryngol Clin North Am* 1995; 28: 1021-1038.