

Case Report

Primary pulmonary meningioma: report of a case and review of the literature

Ruixue Lei, Lanfang Miao, Mei Guo, Haimei Li, Haijun Yang

Anyang Tumor Hospital, Anyang, Henan, China

Received May 2, 2017; Accepted July 20, 2017; Epub August 15, 2017; Published August 30, 2017

Abstract: Primary pulmonary meningioma (PPM) is a rare disease and usually presents as a solitary pulmonary nodule (SPN), therefore primary lung cancer or metastasis may be suspected on imaging. These lesions are mostly benign, but malignant PPMs have been reported. We report a case of PPM occurring in a 65-year-old man with acute cerebral infarction. The diagnosis of PPM was only established after resection. No tumor was observed in the cranial cavity and the patient showed no respiratory symptoms. A chest x-ray incidentally revealed a well-circumscribed nodule in the upper lobe of the left lung. The tumor showed defined nodules resembling whorls or onion skin and immunohistochemical analysis showed that the tumor cells were positive for epithelial membrane antigen, vimentin and progesterone receptor. No recurrence was observed at 24-month follow-up.

Keywords: Primary pulmonary meningioma, solitary pulmonary nodule, lung

Introduction

The vast majority of meningiomas arise in intracranial, intraspinal, and orbital locations, but rare cases have been reported in almost all organs. Primary pulmonary meningioma (PPM) is a rare disease. Most of PPM cases are benign neoplasms. Only three cases with malignant features have been described [1-3]. PPM usually appears as a solitary pulmonary nodule (SPN) and is detected incidentally by chest radiograph or computed tomography (CT). In this article, we present a solitary pulmonary meningioma case with acute cerebral infarction and briefly review the related literature.

Case Report

Clinical history

A 65-year-old man with acute cerebral infarction was admitted to the emergency room, and magnetic resonance imaging of the neural axis revealed no evidence of cranial cavity tumor. The patient is a farmer, who never smokes and has no history of malignancy and TB. Although there were no abnormal respiratory symptoms, a chest x-ray incidentally showed an abnormal shadow in the upper lobe of the left lung. In

order to determine the relationship between the shadow and its surrounding, the patient received chest CT scan. The chest CT showed a 10-cm large, solitary, well-circumscribed nodular mass in the upper lobe of the left lung (**Figure 1A**). MRI of the neural axis and other tests failed to demonstrate a primary tumour. Thus, the lesion was considered to be primary lung cancer and surgical removal was recommended after the treatment of cerebral infarction. The patient received surgery of the left upper lobe. The surgical specimen showed a 10-cm large, tan-white, solitary well-circumscribed nodular mass located in the left upper lobe (**Figure 2**). And the patient remained well and free of disease 24 months after surgery.

Materials and methods

The specimen was fixed in 4% buffered formalin, routinely processed, with tissue sections embedded in paraffin. The sections were cut at 4 µm in thickness and were stained with hematoxylin and eosin (H&E). Immunohistochemistry was performed according to standard protocols. The following antibodies were used: epithelial membrane antigen (Dako Denmark, prediluted), vimentin (Dako Denmark, prediluted), CD34 (Dako Denmark, prediluted), cytoke-

Primary pulmonary meningioma

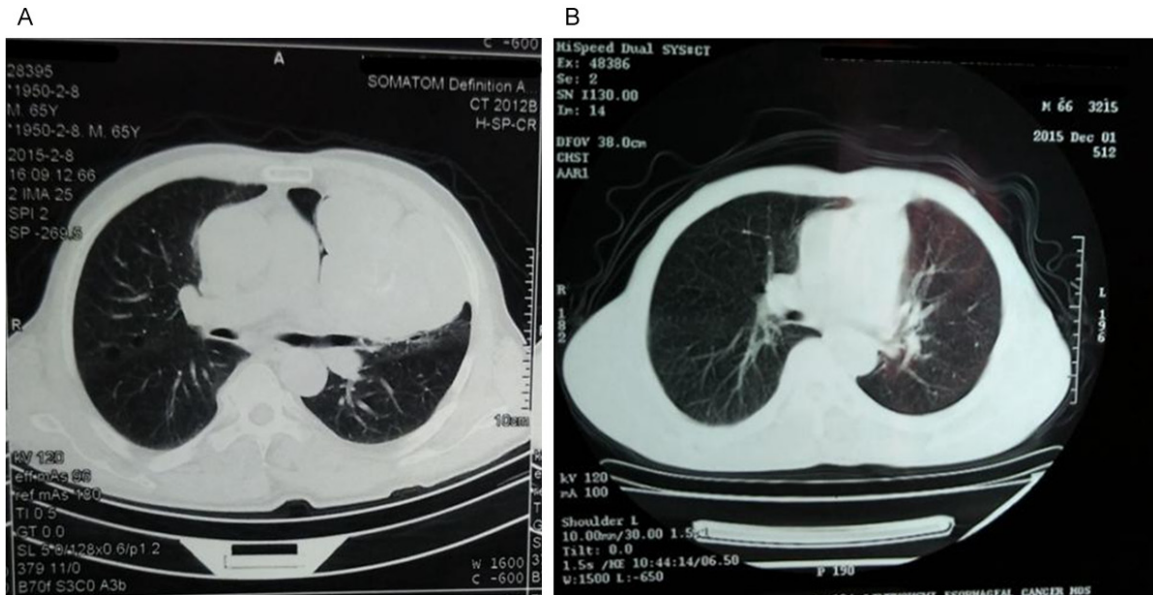


Figure 1. A. The chest CT showed a 10-cm solitary well-circumscribed nodular mass in the upper lobe of the left lung; B. 8 months after operation, no abnormal changes were found through the CT scan.

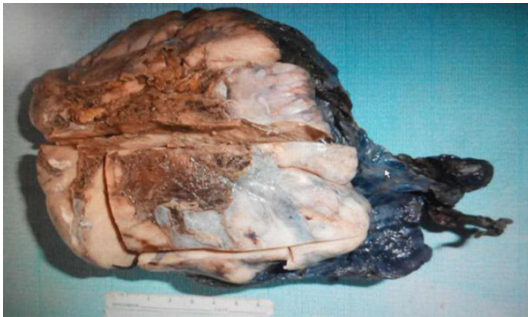

Figure 2. Macroscopic observation of the formalin-perfused lung, demonstrating a 10-cm large, well-circumscribed, tan-white mass, located in the left upper lobe.

atins (Dako Denmark, prediluted), S100 (Dako Denmark, prediluted), smooth muscle actin (Dako Denmark, prediluted), p63 (Dako Denmark, prediluted), estrogen receptors (ER) (Dako Denmark, prediluted), MIB1/Ki67 (Dako Denmark, prediluted) and progesterone receptors (PR) (Dako Denmark, prediluted).

Results

The tumor showed defined nodules resembling whorls or onion skin. The nodule contained cytologically bland, oval, and spindle cells with abundant pale eosinophilic cytoplasm lying in dense collagenous stroma. Each of these cells had round or oval monomorphic nuclei with a

delicate nuclear membrane and contained small nucleoli. Scattered psammoma bodies were noted within the tumor, and no cytological atypia, mitotic activity, or necrosis was identified (Figure 3A, 3B).

The tumor cells were diffusely positive for epithelial membrane (EMA), vimentin and CD34. (Figure 4A-C) They were negative for cytokeratins (AE1/AE3), S-100, smooth-muscle actin, p63 and ER (data not shown). The MIB-1 labeling index was less than 2% (Figure 4D). Furthermore, the tumor cells were positive for PR (Figure 4E).

In this case, the combination of histological and immunohistochemical features contributed to the diagnosis of meningioma. MRI of the neural axis did not show mass lesion or other evidence of primary or metastatic disease, supporting the diagnosis of the patient's lesion as PPM (transitional meningioma). Eight months after operation, no abnormal changes were found through a CT scan (Figure 1B). The patient presented no recurrence at 24-month follow-up.

Discussion

Meningiomas, the most frequent primitive tumors of the central nervous system, arise in the cranial cavity and spinal cord. Extracranial meningiomas are infrequent, however, they

Primary pulmonary meningioma

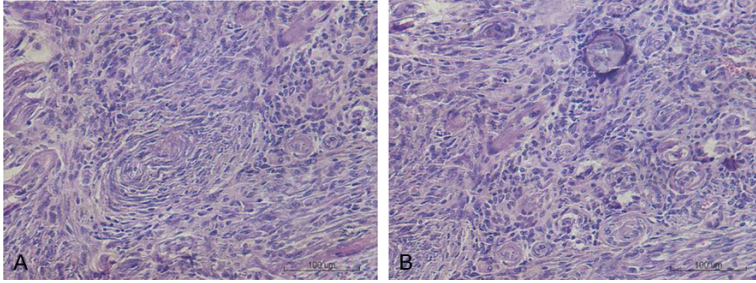


Figure 3. H&E×200 staining showing typical whorl formations (A), and scattered psammoma bodies (B).

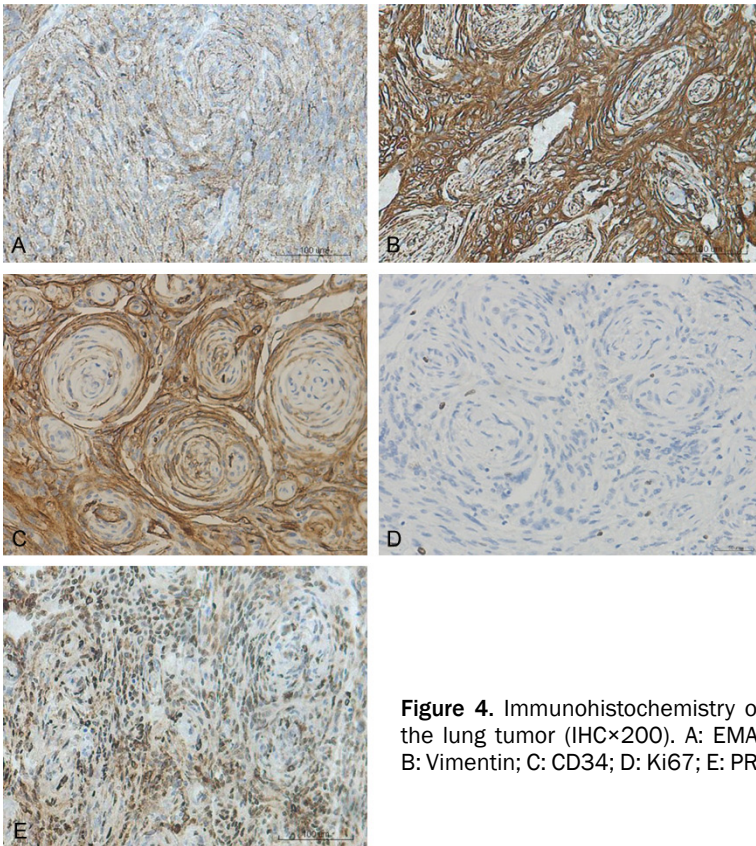


Figure 4. Immunohistochemistry of the lung tumor (IHC×200). A: EMA; B: Vimentin; C: CD34; D: Ki67; E: PR.

have been reported in different anatomic locations, mostly in the head and neck, including orbit, nasal cavity, paranasal sinuses and skull, and also in the skin [4-7], in which the possibility of metastasis from an intracranial or intraspinal meningioma have been excluded.

PPM presents as an asymptomatic solitary lung nodule and generally shows a benign course after surgical excision. This type of neoplasm must meet two diagnostic criteria: the histologic features of a meningioma and the absence of Central Nervous System (CNS) lesion [8]. A

radiologic study of the CNS is mandatory to exclude the possibility of intracranial or spinal meningioma. Compared to CT, MRI is currently preferred for its higher sensibility [9, 10].

Two main hypotheses regarding the pathogenesis of PPM have been proposed: these tumors may be derived (a) from Ectopic arachnoid cells of the lungs, or (b) from pluripotential subpleural mesenchyma [11, 12].

Meningiomas are usually benign tumors with a slow evolution (World Health Organization, WHO grade I). And 20-35% of meningiomas are actually classified as atypical (WHO grade II) [13], whereas anaplastic/malignant meningiomas (WHO grade III) remain rare. Metastases involving lung, pleura, bone, and liver rarely occur. The WHO grading system, according to the WHO Classification of Tumors of the Central Nervous System, is based on histological examination, with the main criteria of grade progression being the mitotic count. Histologic grade is an important predictor of the tumour behavior including metastatic potential and may influence the choice of therapies [14, 15]. The 2016 WHO Classification of

the Central Nervous System has introduced brain invasion as a criterion for the diagnosis of atypical meningioma, WHO grade II [16]. Immunohistochemical staining for the proliferative potential of meningiomas with Ki67 antibody may be helpful in assessing the aggressiveness of the tumour. Ki67 positive tumour tends to be more aggressive, with a higher chance of recurrence following resection or metastases [15]. Histologic features and Ki67 staining in patients indicated a low-grade recurrence and metastasis.

Primary pulmonary meningioma

In 1979, Dinell *et al.* [17] found the existence of ER in intracranial meningioma, and proposed the dependence of intracranial meningioma on sexual hormone. Subsequently, the role of ER and PR in the development of intracranial meningioma has captured great attention and been widely studied. The sexual difference in the incidence of intracranial meningioma has been well established, and the morbidity in women is 1.7-3.5 times that in men. The existing research results showed that there was low or no ER expression in intracranial meningioma, while the positive rate of PR in intracranial meningioma was 56%~100%. This result was consistent with other groups' finding [18]. PR was more likely to be expressed in benign meningioma than in malignant meningioma [19], thus it can be used as a predictor of early development reference index for the prognosis of meningioma. Similarly, in PPM, PR was always expressed in the benign meningioma and less likely to be expressed in malignant meningioma [20, 21]. However, ER was usually very low or no expressed in the PPM [2, 3].

In conclusion, PPM is a very rare disease and presents as a SPN, usually incidentally detected by routine radiological screening studies. Evaluation of the CNS by MRI or CT scan is required to exclude primary intracranial or spinal meningioma. Histological morphology and immunohistochemistry are helpful to the diagnosis of PPM. PPM is generally a benign tumor, although three malignant cases have been reported. Ki67 and PR can be used as a reference index for the early development of meningioma. The treatment usually includes radical surgical resection. Even though the majority of cases demonstrate a benign behavior, Satoh, *et al.* [22] has successfully followed up the first case of multiple pulmonary meningioma. Ten years after the first operation, another lesion developed and was histologically confirmed to be meningioma, which may explain the synchronous and metachronous multiplicity: multiple pulmonary meningothelium-like nodules grew synchronously and metachronously.

Disclosure of conflict of interest

None.

Address correspondence to: Haijun Yang, Anyang Tumor Hospital, Anyang, Henan, China. E-mail: yhj1972@126.com

References

- [1] Prayson RA, Farver CF. Primary pulmonary malignant meningioma. *Am J Surg Pathol* 1999; 23: 722-6.
- [2] vander Meij JJ, Boomars KA, vanden Bosch JM, van Boven WJ, de Bruin PC and Seldenrijk CA. Primary pulmonary malignant meningioma. *Ann Thorac Surg* 2005; 80: 1523-5.
- [3] Weber C, Pautex S, Zulian GB, Pusztaszeri M and Lobrinus JA. Primary pulmonary malignant meningioma with lymph node and liver metastasis in a centenarian woman, an autopsy case. *Virchows Arch* 2013; 462: 481-5.
- [4] Olivares-Pakzad BA, Tazelaar HD, Dehner LP, Kasperbauer JL and Bite U. Oropharyngeal hairy polyp with meningothelial elements. *Oral Surg Oral Med Oral Pathol Oral Radiol Endod* 1995; 79: 462-8.
- [5] Rozat E, Yang W, DeLa Torre R. Fine needle aspiration cytology of parapharyngeal meningioma. *Acta Cytol* 1991; 35: 497-500.
- [6] Cistallini EG, Bolis GB, Ottaviano P. Fine needle aspiration biopsy of orbital meningioma: report of a case. *Acta Cytol* 1990; 34: 236-8.
- [7] Kalfa M, Daskalopoulou D, Markidou S. Fine needle aspiration (FNA) biopsy of primary cutaneous meningioma: Report of two cases. *Cytopathology* 1999; 10: 54-60.
- [8] Picquet J, Valo I, Jousset Y and Enon B. Primary pulmonary meningioma first suspected of being a lung metastasis. *Ann Thorac Surg* 2005; 79: 1407-9.
- [9] Whittle IR, Smith C, Navoo P and Collie D. Meningiomas. *Lancet* 2004; 363: 1535-43.
- [10] Surov A, Gottschling S, Bolz J, Kornhuber M, Alfieri A, Holzhausen HJ, Abbas J, Kösling S. Distant metastases in meningioma: an underestimated problem. *J Neurooncol* 2013; 112: 323-7.
- [11] Marchevsky AM. Lung tumors derived from ectopic tissues. *Semin Diagn Pathol* 1995; 12: 172-84.
- [12] Moran CA, Hochholzer L, Rush W and Koss MN. Primary intrapulmonary meningiomas. A clinicopathologic and immunohistochemical study of ten cases. *Cancer* 1996; 78: 2328-33.
- [13] Rogers L, Gilbert M, Vogelbaum MA. Intracranial meningiomas of atypical (WHO gradell) histology. *J Neurooncol* 2010; 99: 393-405.
- [14] Louis DN, Ohgaki H, Wiestler OD, Louis DN, Cavenee WK, Burger PC, Jouvet A, Scheithauer BW and Kleihues P. The 2007 WHO classification of tumours of the central nervous system. *Acta Neuropathol* 2007; 114: 97-109.
- [15] Estanislau ES, Carvalho GT, Reis BL, de Freitas Barbosa W, Brandão RA, Sousa AA and Oliveira JB. Malignant meningioma with extracranial metastases. *Arq Neuropsiquiatr* 2009; 67: 730-2.

Primary pulmonary meningioma

- [16] Louis DN, Perry A, Reifenberger G, von Deimling A, Figarella-Branger D, Cavenee WK, Ohgaki H, Wiestler OD, Kleihues P and Ellison DW. The 2016 World Health Organization classification of tumors of the central nervous system: a summary. *Acta Neuropathol* 2016; 131: 803-20.
- [17] Donnell MS, Meyer GA, Donegan WL. Estrogen-receptor protein in intracranial meningiomas. *J Neurosurg* 1979; 50: 499-502.
- [18] Wahab M, Al-Azzawi F. Meningioma and hormonal influences. *Climacteric* 2003; 6: 285-92.
- [19] Gursan N, Gundogdu C, Albayrak A and Kabalar ME. Immunohistochemical detection of progesterone receptors and the correlation with Ki-67 labeling indices in paraffin-embedded sections of meningiomas. *Int J Neurosci* 2002; 112: 463-70.
- [20] Okiror L, von der Thusen J, Ladas G. Solitary lung meningioma with synchronous brain nodules: clinical and pathological features. *Gen Thorac Cardiovasc Surg* 2013; 61: 648-50.
- [21] Masago K, Hosada W, Sasaki E, Murakami Y, Sugano M, Nagasaka T, Yamada M and Yatabe Y. Is primary pulmonary meningioma a giant form of a meningotheial-like nodule? A case report and review of the literature. *Case Rep Oncol* 2012; 5: 471-8.
- [22] Satoh Y, Ishikawa Y. Primary pulmonary meningioma: Ten-year follow-up findings for a multiple case, implying a benign biological nature. *J Thorac Cardiovasc Surg* 2010; 139: e39-40.