

Case Report

Endovascular stent-graft treatment in aorto-esophageal fistula caused by foreign bodies

Chao Lu, Jiande Gong, Zhe Shen, Chaohui Yu, Youming Li

Department of Gastroenterology, The First Affiliated Hospital, College of Medicine, Zhejiang University, Hangzhou 310003, China

Received March 18, 2017; Accepted July 31, 2017; Epub September 15, 2017; Published September 30, 2017

Abstract: Background: Aorto-esophageal fistula (AEF) caused by the ingestion of foreign bodies is rare and often life threatening. We aim to summarize effective measures to improve the curative effect and survival rate. Case Reports: Between January 2010 and September 2015, three patients with AEF received endovascular stent-graft treatment in our hospital. Through the effective prevention of hemorrhage by stent-grafting, surgical repair of the esophageal rupture was performed successfully. All three cases were treated successfully and survived up to the day that this article was written. Comments: It may be safer to first perform an endovascular stent-graft to prevent hemorrhage in AEF.

Keywords: Aorto-esophageal fistula, stent-graft, foreign body

Introduction

Accidental swallowing of foreign bodies is common, but it rarely causes severe complications. Esophageal penetration caused by the accidental swallowing of foreign bodies is especially unusual, with a reported incidence from 1% to 4% [1]. Of various foreign bodies, fish bones are the most common (60%), and they can cause severe complications, such as aorto-esophageal fistula (AEF), more easily. In a series of 2394 cases of accidental swallowing of foreign bodies reported in Hong Kong, perforation occurred in 25 cases (1%) and AEFs occurred in two cases (0.08%) [2]. Acute AEF is fatal, and prompt diagnosis is crucial for treatment. Surgical treatment is the main method, but often the outcome is not satisfactory with surgical trauma [3]. As a minimally invasive surgery, endovascular stent-graft treatment may become the main adjunctive treatment after AEF caused by accidental swallowing of foreign bodies [4].

Case reports

Between January 2010 and September 2015, thousands of patients with esophageal foreign bodies came to the First Affiliated Hospital,

College of Medicine, Zhejiang University. Among them, 328 patients underwent foreign body extraction in the hospital. Moreover, 37/328 patients were diagnosed with esophageal perforation, including three patients with AEF and one patient with left atrium perforation. All three AEF patients caused by fish bones received endovascular stent-graft treatment to prevent hemorrhage.

The first case was a female patient aged 51 years old. Sore throat occurred after accidental oral intake of a fish bone on January 23, 2015. Then, persistent substernal pain occurred gradually and became worse after eating, eventually becoming unbearable. At the same time, fever and chest distress became more and more obvious, whereas no hematemesis appeared. The junior hospital CT suggested esophageal perforation. The patient came to our hospital on January 25, 2015. In the emergency ward, thoracic aorta CTA showed that a foreign body was located in the middle of the esophagus, on the fifth thoracic level, and it penetrated into artery 3-4 cm (**Figure 1A** and **1B**). However, no obvious extravasation and leakage of the contrast agent were observed. Considering the depth of the fish bone in the thoracic aorta, the emergency endovascular stent-graft was plac-

Aortoesophageal fistula

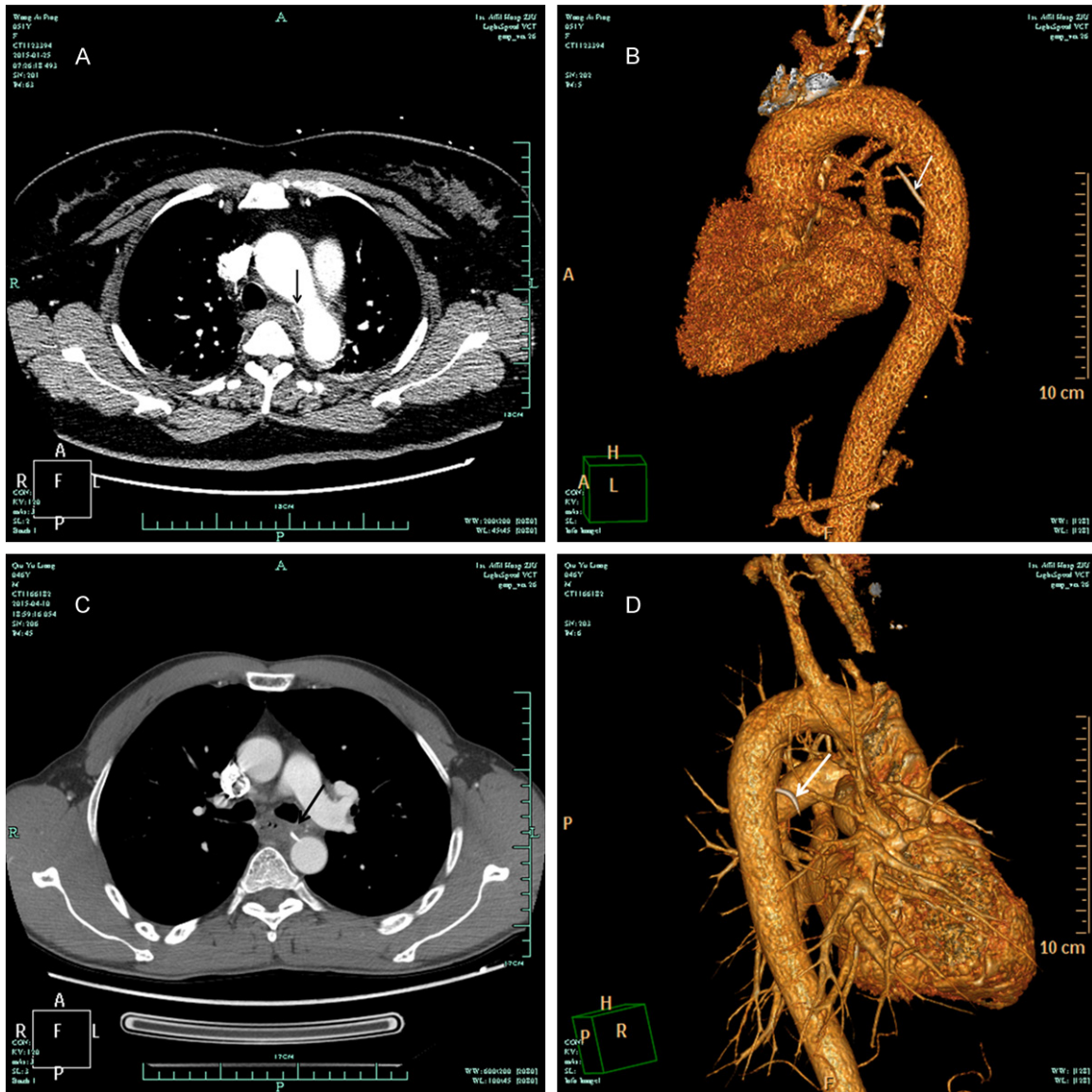


Figure 1. Thoracic aorta CTA of patient 1, (A) the section of fish bone that penetrated into the aorta; (B) Three-dimensional reconstruction of the thoracic aorta CTA. Thoracic aorta CTA of patient 2, (C) the section of fish bone that penetrated into the aorta; (D) Three-dimensional reconstruction of the thoracic aorta CTA.

ed to prevent hemorrhage and further piercing of the artery. Through the right femoral artery, a 28 × 150 mm stent-graft (Medtronic, Inc, USA) was placed in the thoracic aorta. Active bleeding was not detected. Then the surgical repair of esophageal rupture was performed immediately and the fish bone was removed. After the operation, WBC and CRP reached $12.9 \times 10^9/L$ and 177.8 mg/L, respectively. The body temperature reached 38.2°C. Tienam plus Teicoplanin were used as anti-infective therapy for 7 days. On January 28, 2015, chest CT showed pleural effusion and pneumonia, whereas no

esophageal stricture, no esophageal fistula and no bleeding were observed (Figure 3A). WBC and CRP dropped to $8.2 \times 10^9/L$ and 86.3 mg/L, respectively, on February 4, 2015. Then, the patient was administered Biapenem (TianC). Re-examination of the chest CT showed that the absorption of inflammation and no short-term complications of surgery were found (Figure 3B). The patient was discharged successfully on February 11, 2015. No complications, such as hemorrhage, embolism, or stricture, were observed on one-month follow-up and three-month follow-up (Figure 3C).

Aortoesophageal fistula

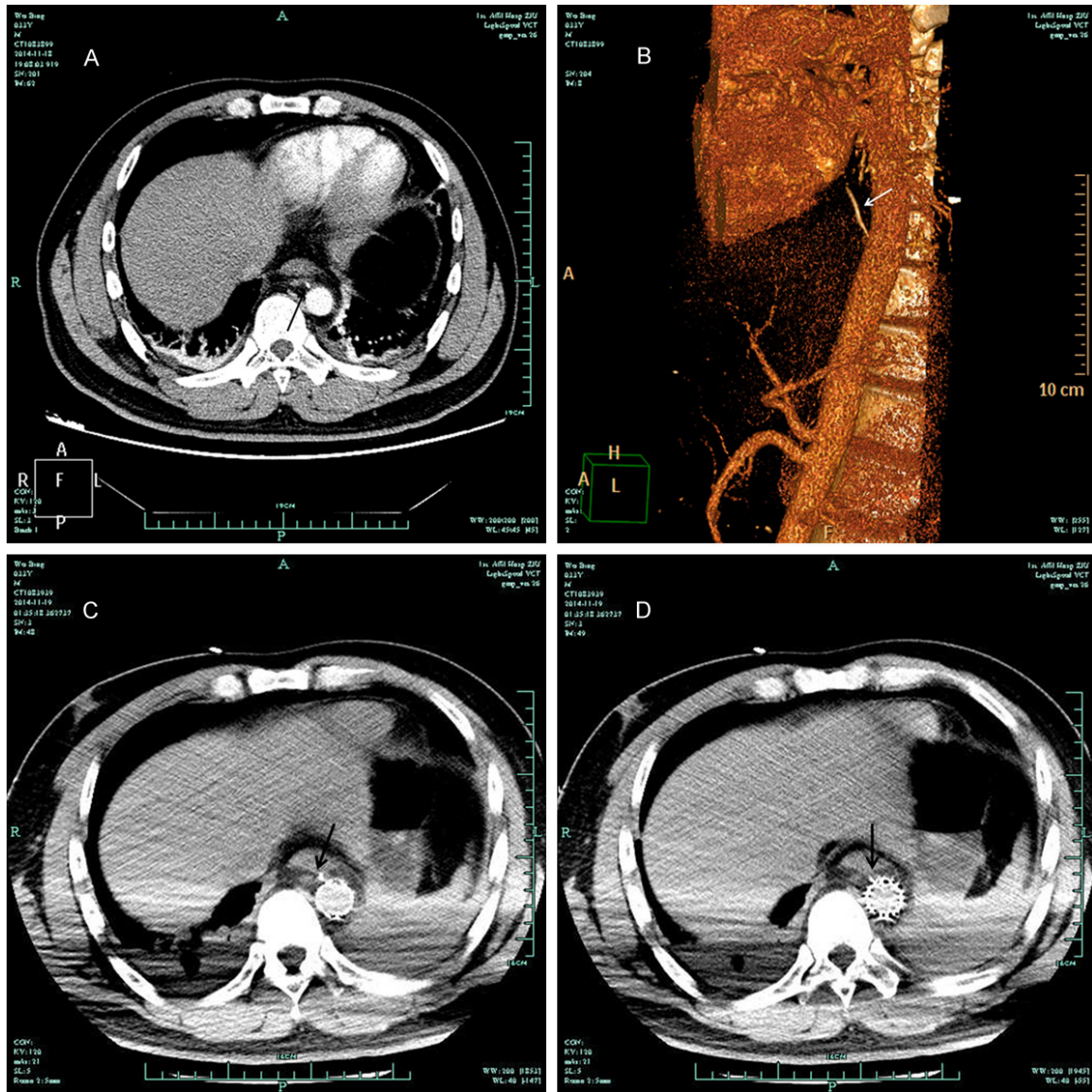


Figure 2. Thoracic aorta CTA of patient 3, (A) the section of fish bone that penetrated into the aorta; (B) Three-dimensional reconstruction of the thoracic aorta CTA; (C and D) Reexamination of CT imaging showed the location of foreign body after the placement of the endovascular stent-graft.

The second patient was a 46-year-old male. Chest pain occurred one day after accidental oral intake of a fish bone without high fever and hematemesis. The junior hospital CT showed a foreign body in the esophagus, suggesting esophageal perforation. The thoracic aorta CTA in our emergency ward verified the above diagnosis, and CTA showed that a foreign body penetrated into the thoracic aorta on the level of trachea carina (**Figure 1C** and **1D**). Removal of the foreign body under endoscopy may be an ideal therapeutic strategy. Unfortunately, nothing was found under endoscopy, which found

only a 0.3-cm white ulcer 33 cm from the incisors. After discussion, an endovascular stent-graft was placed to prevent from hemorrhage and improve the safety of the operation. Through the right femoral artery, a 28 × 160 mm stent-graft (LifeTech Scientific Corporation, China) was placed in the thoracic aorta, and no shadow from the fish bone or extravasation of the contrast agent was observed. After stent-graft placement, the patient was rushed to the operating room for surgical repair of the esophageal rupture. After the operation, temperature reached 38.5°C on April 11, 2015. Moreover,

Aortoesophageal fistula

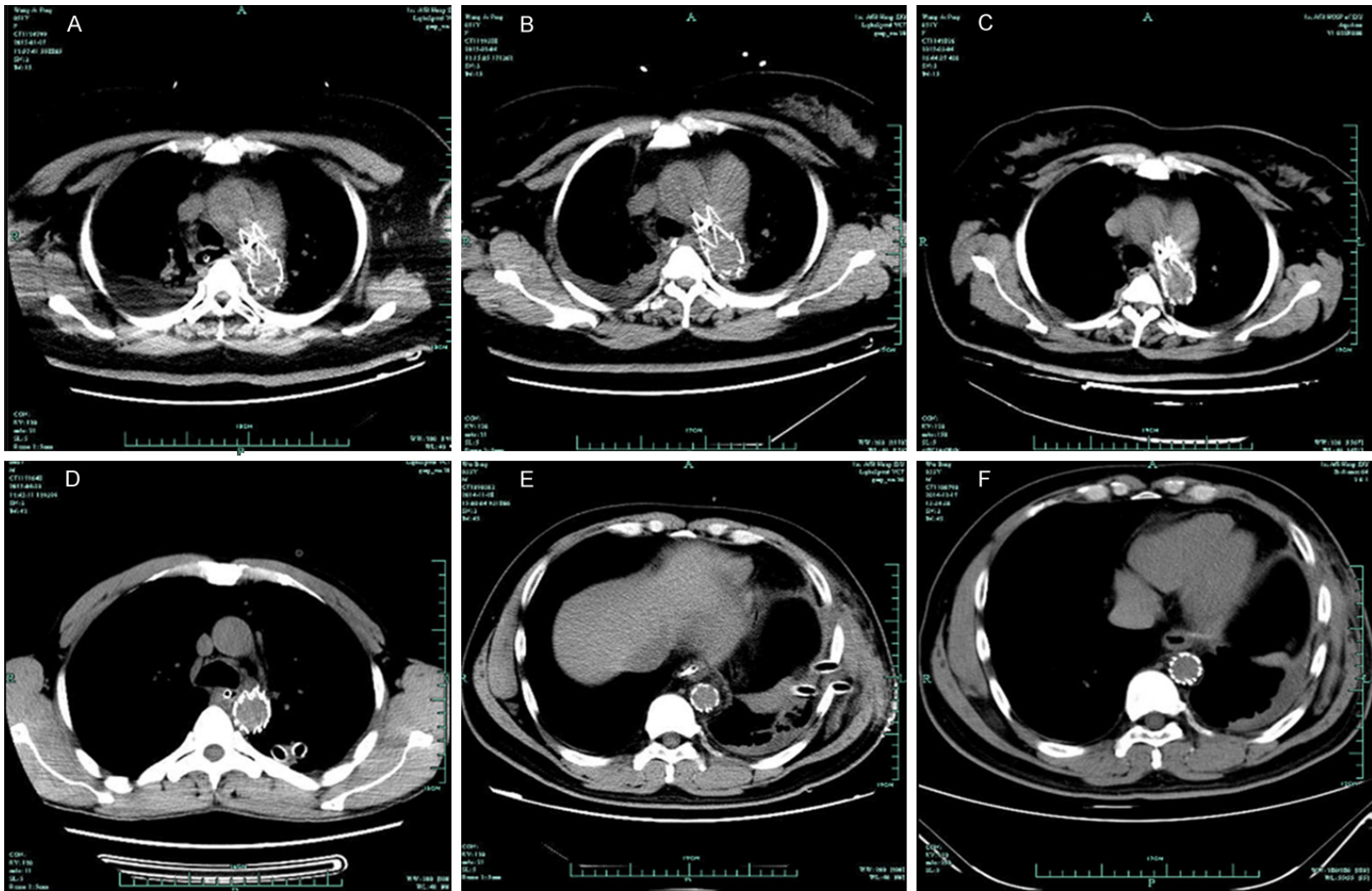


Figure 3. In patient 1, (A) on January 28, 2015, chest CT showed pleural effusion and pneumonia; (B) Reexamination of CT on February 4, 2015 showed that the absorption of inflammation and no short-term complications of surgery were found; (C) No complications were found on CT imaging on March 4, 2015. Patient 2, (D) chest CT showed no inflammation, pleural effusion or expansion of the esophagus on April 20, 2015; In patient 3, (E) chest CT showed atelectasis, pneumonia, left pneumothorax and left pleural effusion on November 29, 2015; (F) Reexamination of chest CT showed that pneumothorax and pleural effusion were absorbed on December 17, 2015.

Aortoesophageal fistula

WBC and CRP reached $14.9 \times 10^9/L$ and 124.2 mg/L, respectively. Tienam was used for 4 days. Then, Cefotiam plus Isepamicin were used as continuous anti-infection therapy. WBC and CRP dropped to $12.6 \times 10^9/L$ and 19.1 mg/L, respectively, on April 20, 2015. Chest CT showed no inflammation, pleural effusion or expansion of the esophagus (**Figure 3D**). This patient was discharged successfully on April 21, 2015. No complications were found three months follow-up.

The third patient was a 33-year-old male. Chest and substernal pain occurred 2 days after fish bone injury on November 18, 2014. Thoracic aorta CTA in the junior hospital showed that the foreign body was swelling outward, contacting with thoracic aorta 5 cm from cardiac tissue. The next day, the patient was transferred to our hospital. The thoracic aorta CTA in our emergency ward indicated that the foreign body in the esophagus in combination with its close association with the artery had penetrated the esophageal wall (**Figure 2A** and **2B**). To prevent hemorrhage and improve the safety rate with the next treatment, the emergency endovascular stent-graft (28 × 160 mm, LifeTech Scientific Corporation, China) was placed on November 19, 2014. Then, we sought to remove the foreign body under endoscopy. However, we did not find a fish bone under endoscopy, which showed elevated mucosa (0.3-0.4 cm) 40 cm from the incisors and no ulcers or erosion (November 19, 2014). Reviewing another chest CT on November 19, 2014, we still observed a foreign body piercing the thoracic aorta (**Figure 2C** and **2D**). Combining these images, we concluded that the fish bone pierced the esophagus and arrived at the aorta. The next day, surgical repair of the esophageal rupture was conducted and the fish bone was removed successfully. The WBC and CRP were $15.8 \times 10^9/L$ and 175.5 mg/L postoperative day, respectively. Temperature reached 39.4°C. Sulperazone plus Vancomycin were used for 5 days, and then only Sulperazone was used for 14 days. WBC and CRP dropped to $7.0 \times 10^9/L$ and 19.4 mg/L on November 29, 2015. Chest CT showed atelectasis and pneumonia. Left pneumothorax and left pleural effusion were also found. No esophageal lesions, esophageal stenosis, oesophageal fistula were observed (**Figure 3E**). Through continuous anti-infective therapy and careful nursing, the patient was discharged on December 8, 2015. Reexamining the chest

CT on December 17, 2015, pneumothorax and pleural effusion were absorbed (**Figure 3F**). In addition, esophagography showed that esophageal was unobstructed and contrast leakage was found.

All three patients survived until this article was written (range: 5 months-10 months).

Comments

AEF caused by a foreign body is rare, and its long-term survival rate is very low. Kelly *et al* found that over one hundred cases of AEF secondary to the ingestion of foreign bodies have been undocumented, but only seven have survived over 12 months [5]. Among survival cases, two cases used endovascular stent-grafts for the first treatment [5, 6]. Our three patients had less than 1 year of follow-up, emphasizing the need for close follow-up. The long-term complications and survival rate should be considered. In addition, Ctercteko *et al* reported the first successfully cured case of AEF in 1980 [7]. They occluded the descending aorta and sutured the aortic and esophageal fistula directly. Although the operation was successful, the risk of complications was still high. Burks *et al* indicated that stent-grafts should be considered a temporary measure to achieve short-term hemostasis as a bridge to conventional surgery within a few hours or days [8], as wounds caused by foreign bodies are always associated with contamination and infection. Our patients all underwent operations because no foreign bodies were seen under endoscopy. Therefore, stent-graft treatment in our cases was more likely a temporary transition treatment to prevent hemostasis and infection and to preclude the fish bone from deeply piercing into the artery [9].

We should note that air is released by endoscopy to fully expose the field of vision. Does endoscopy present a risk of air embolism through the fistula? Ha *et al* reported a review of 14 cases of air embolism associated with gastroscopy [9]. The results showed that the main presenting symptoms were neurological and respiratory compromise. The main tools used for diagnosis were CT and echocardiogram. Air embolism is a very rare complication and is often overlooked. Our patients did neither have this symptom nor a diagnostic basis for air embolism.

Aorto-esophageal fistula

In conclusion, if an AEF caused by foreign bodies is diagnosed without shock, severe infection or other acute life-threatening complications, it can be initially treated with endovascular stent-grafting to prevent hemostasis and preclude the fish bone from deeply piercing into the artery. Subsequently, repair of the esophagus by surgery or endoscopic surgery can be carried out more successfully.

Disclosure of conflict of interest

None.

Address correspondence to: Youming Li, Department of Gastroenterology, The First Affiliated Hospital, College of Medicine, Zhejiang University, No. 79 Qingchun Road, Hangzhou 310003, China. Tel: +86-571-87236532; E-mail: ymsego@zju.edu.cn

References

- [1] Scher RL, Tegtmeyer CJ, McLean WC. Vascular injury following foreign body perforation of the esophagus. Review of the literature and report of a case. *Ann Otol Rhinol Laryngol* 1990; 99: 698-702.
- [2] Nandi P, Ong GB. Foreign body in the oesophagus: review of 2394 cases. *Br J Surg* 1978; 65: 5-9.
- [3] Assink J, Vierhout BP, Snellen JP, Benner PM, Paul MA, Cuesta MA, Wisselink W. Emergency endovascular repair of an aorto-esophageal fistula caused by a foreign body. *J Endovasc Ther* 2005; 12: 129-33.
- [4] Hanif MZ, Li D, Jabeen S, Fan Q. Endovascular repair in penetrating aorto-esophageal foreign body injury. *Ann Thorac Surg* 2013; 96: 1457-9.
- [5] Kelly SL, Peters P, Ogg MJ, Li A, Smithers BM. Successful management of an aorto-esophageal fistula caused by a fish bone—case report and review of literature. *J Cardiothorac Surg* 2009; 4: 21.
- [6] Assink J, Vierhout BP, Snellen JP, Benner PM, Paul MA, Cuesta MA, Wisselink W. Emergency endovascular repair of an aorto-esophageal fistula caused by a foreign body. *J Endovasc Ther* 2005; 12: 129-33.
- [7] Ctercteko G, Mok CK. Aorta-esophageal fistula induced by a foreign body: the first recorded survival. *J Thorac Cardiovasc Surg* 1980; 80: 233-5.
- [8] Burks JA Jr, Faries PL, Gravereaux EC, Hollier LH, Marin ML. Endovascular repair of bleeding aortoenteric fistulas: a 5-year experience. *J Vasc Surg* 2001; 34: 1055-9.
- [9] Ha JF, Allanson E, Chandraratna H. Air embolism in gastroscopy. *Int J Surg* 2009; 7: 428-30.