

Original Article

Efficacy of real-time tele-transmission system of 12-lead electrocardiogram for myocardial hemorrhage patients on the first-aid

Jian Wang, Shunyi Feng, Jinping Guo, Long Yang, Guangxin Lv, Yong Li

Emergency Department, Cangzhou Central Hospital, Cangzhou, Hebei Province, China

Received June 14, 2017; Accepted February 14, 2018; Epub October 15, 2018; Published October 30, 2018

Abstract: The admiration of electrocardiographic (ECG) is the most widely used in the diagnosis of myocardial hemorrhage. Clinical analyses have identified real-time tele-transmission system of 12-lead electrocardiogram (RTTS-12LE) is a new diagnostic method that can be used to validate the condition of myocardial hemorrhage patients. The purpose of this study was to evaluate the efficacy of RTTS-12LE for myocardial hemorrhage patients on the first-aid. The application of RTTS-12LE was also discussed in this work. A total of 175 consecutive patients with myocardial hemorrhage were diagnosed by RTTS-12LE on the first-aid. All patients with suspicious myocardial hemorrhage were further analyzed by contrast-enhanced cardiac magnetic resonance imaging (ceMRI). Our results demonstrated that RTTS-12LE presented a sensitivity of 60% and specificity of 95% for myocardial hemorrhage patients. Outcomes showed that RTTS-12LE improved sensitivity for detection of myocardial hemorrhage patients from 52% to 88% ($P < 0.01$) and decreased specificity from 95% to 90% ($P > 0.50$). In conclusion, RTTS-12LE showed more accuracy for patients admitted to hospital with possible myocardial hemorrhage, suggesting RTTS-12LE recording may be an efficient diagnostic method for myocardial hemorrhage patients on the first-aid.

Keywords: RTTS-12LE, myocardial hemorrhage, first-aid, ceMRI

Introduction

Complications of coronary heart disease (CAD) is usually caused by myocardial ischemia that ultimately affect function of myocardial vascular and multiple organ systems [1]. CAD is also a kind of diseases of coronary arteries atherosclerosis lesions, which is caused by vascular cavity stenosis, occlusion, myocardial ischemia, hypoxia and/or necrosis [2, 3]. Prospective review and randomized clinical trials have investigated factors associated with increased coronary heart disease risk [4]. A systematic review has indicated socioeconomic inequalities in access to treatment for CAD [5]. Myocardial hemorrhage is associated with inflammation and thrombosis that further leads to the luminal stenosis or occlusion [6, 7]. A systematic review and meta-analysis has indicated the prognostic value of glycated hemoglobin among patients with ST-segment elevation myocardial hemorrhage [8]. In recent years, more and more reports focus on the first-aid for

the patients with myocardial hemorrhage [9, 10].

Recently, two electrocardiographic (ECG) indices have been reported to be diagnosed in myocardial hemorrhage patients [11]. ECG indices include P wave dispersion (Pdisp) and QT dispersion (QTdisp), which reflects homogeneity of atrial conduction and abnormalities of ventricular repolarization [12]. Previous study presented 12-lead electrocardiogram is an efficient method in diagnosis of patients with suspicious myocardial hemorrhage [13]. Evidences have indicated that ST-segment deviation analysis of the admission 12-lead electrocardiogram can be regarded as an aid to early diagnosis of acute myocardial hemorrhage with a cardiac magnetic resonance imaging gold standard [14]. Notably, the effect of a real-time tele-transmission system of 12-lead electrocardiogram (RTTS-12LE) on the first-aid has been investigated for athletes with ST-elevation myocardial hemorrhage, which is beneficial to the

Efficacy of RTTS-12LE for myocardial hemorrhage diagnosis

Table 1. Characteristic of patients with myocardial infarction

Parameters	Patients	Healthy
Subjects (n)	178	96
Age (years)	46.5 ± 12.6	43.8 ± 14.2
Body weight (kg)	73.8 ± 12.4	70.2 ± 13.8
Heart rate (time/min)	85 ± 16	75 ± 13
Blood pressure (mmHg)	8.5 ± 1.6	7.4 ± 1.8

Table 2. Clinical characteristics of myocardial infarction patients

	Patients	Healthy
ESR (mm/hour)	40.8 ± 16.8	26.2 ± 12.0
CRP (mg/dl)	1.73 ± 0.42	1.02 ± 0.44
SAA (mg/dl)	6.73 ± 3.48	1.72 ± 0.60

pre-hospital diagnosis of ST-elevation myocardial hemorrhage [9]. However, the efficacy of RTTS-12LE in diagnosing of patients with myocardial hemorrhage has not been systematically surveys.

In this study, we aim to investigate the diagnostic accuracy of RTTS-12LE for patients with myocardial hemorrhage. Here, we reported that RTTS-12LE significantly improved sensitivity for detection of myocardial hemorrhage patients.

Materials and methods

Patients and controls

This study was approved by the ethics committee of Cangzhou Central Hospital. Patients with myocardial hemorrhage were determined by the simplified Livneh criteria. Patients with myocardial hemorrhage were prospectively included into the study at Cangzhou central hospital [15]. The study was approved by the ethics committee of the medical faculty of the Cangzhou central hospital, China (study register number: 2015-11051712). 178 patients with suspicious myocardial hemorrhage who need to first-aid were enrolled in this study. Age-matched 96 healthy adults served as controls. All myocardial hemorrhage patients were diagnosed by RTTS-12LE or ceMRI. Written informed consent was obtained from all the participators included in the present study.

Analysis of biochemical indices

Plasma samples were prepared immediately by centrifugation (2000 × g, 4°C for 10 min) of peripheral venous blood. Erythrocyte sedimentation rate (ESR), c reactive protein (CRP) and serum amyloid A (SAA) were assessed from plasma obtained at study inclusion. Disease severity in myocardial hemorrhage patients was scored using the Pras *et al* [16].

Electrocardiography

A RTTS-12LE was performed during 5 seconds using a MAC 1200 ST (GE Medical systems information technology, GE, Providence, RI, USA) at a paper speed of 50 mm/sec and a gain of 10 mm per mV for myocardial hemorrhage patients. RTTS-12LE was conducted in a detailed description [9].

MRI scan protocol

The MRI diagnosis system was used to diagnose suspicious myocardial hemorrhage patients by using preprogrammed setting. The preprogrammed setting was optimized to reach the best image formation. Myocardial hemorrhage and its affiliated structure in all the patients were underwent MRI according to instrument of the manufacture (Philips Medical Systems, Cleveland, Ohio, USA). The details of principles and settings of MRI were described in previous study [17].

Statistical analysis

Statistical analysis was performed by using SPSS 19.0 software and Excel. Association ECG, RTTS-12LE measurements and biochemical indexes were assessed using Pearson's correlation coefficient. **P* < 0.05 was considered statistically significant.

Results

Characteristics of myocardial hemorrhage patients on the first-aid

A total of 175 consecutive patients with myocardial hemorrhage were enrolled and diagnosed by RTTS-12LE on the first-aid. We demonstrated that the numbers of male (*n* = 104) patients were more than female (*n* = 71)

Efficacy of RTTS-12LE for myocardial hemorrhage diagnosis

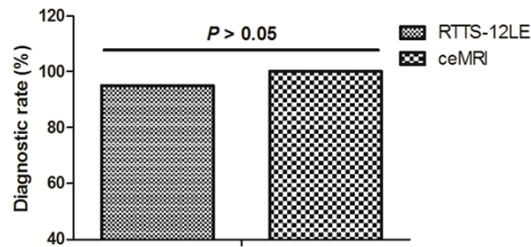


Figure 1. Plasma ESR levels between myocardial hemorrhage patients and healthy participants.

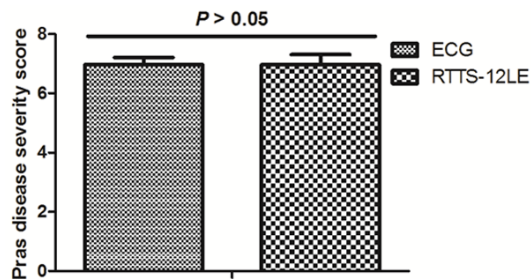


Figure 2. Plasma CRP levels between myocardial hemorrhage patients and healthy participants.

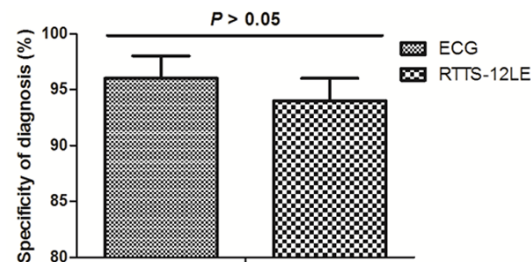


Figure 3. Plasma SAA levels between myocardial hemorrhage patients and healthy participants.

patients. Their age in myocardial hemorrhage patients was 46.5 ± 12.6 . Six of those myocardial hemorrhage patients had history of coronary heart disease. Characteristics of myocardial hemorrhage patients were summarized in **Table 1**.

Age at FMF onset.

Analysis the biochemical parameters in myocardial hemorrhage patients on the first-aid

The clinical biochemical parameter values of the study participants are summarized in **Table 2**. Results showed ESR levels in myocardial hemorrhage patients were 40.8 ± 16.8 (mm/

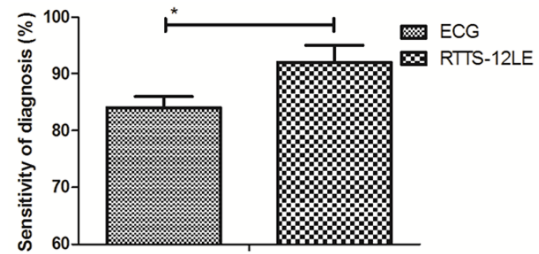


Figure 4. RTTS-12LE presented higher sensitivity of 92% for patients with suspicious myocardial hemorrhage.

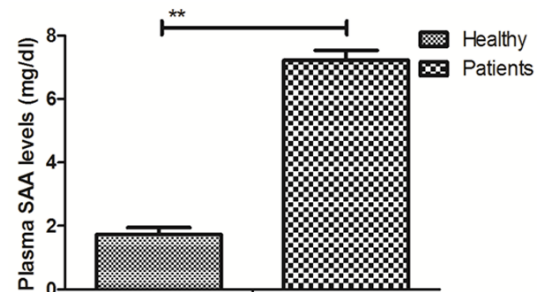


Figure 5. RTTS-12LE presented a slight decreasing specificity for patients with suspicious myocardial hemorrhage.

hour), which was higher than healthy participants (26.2 ± 12.0 mm/hour) ($P < 0.01$, **Figure 1**). The plasma CRP levels presented higher plasma levels in myocardial hemorrhage patients than healthy participants (1.73 ± 0.42 vs 1.02 ± 0.44 mg/dl, **Figure 2**). Outcomes revealed that plasma SAA levels also up-regulated in myocardial hemorrhage patients than healthy participants (6.73 ± 3.48 vs 1.72 ± 0.60 mg/dl, **Figure 3**).

Analysis the efficacy of RTTS-12LE myocardial hemorrhage patients on the first-aid

The diagnostic efficacy of RTTS-12LE was analyzed in patients with suspicious myocardial hemorrhage. We demonstrated that RTTS-12LE presented a sensitivity of 92% (**Figure 4**) and specificity of 95% for myocardial hemorrhage patients (**Figure 5**). We showed that myocardial hemorrhage patients had no difference in Plas disease severity score between RTTS-12LE and ECG (**Figure 6**). The RTTS-12LE characteristics of myocardial hemorrhage patients and healthy volunteers are shown in **Table 3**. We showed Pdisp, QTdisp and cQTdisp were significantly

Efficacy of RTTS-12LE for myocardial hemorrhage diagnosis

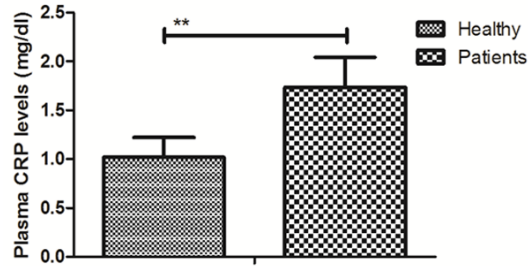


Figure 6. Myocardial hemorrhage patients had no difference in Pras disease severity score between RTTS-12LE and ECG.

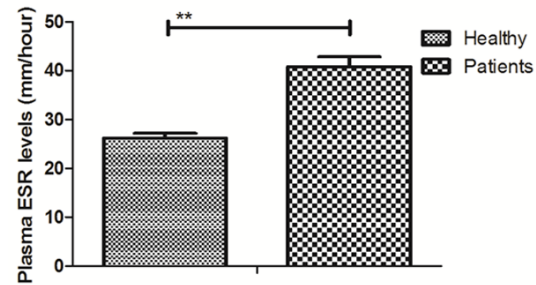


Figure 7. MRI confirmed RTTS-12LE-diagnosed patients with myocardial hemorrhage.

Table 3. Electrocardiographic characteristics of myocardial infarction patients

	Patients	Healthy
RR (ms)	826.2 ± 114.6	778.2 ± 102.6
Pmin (ms)	84.5 ± 10.4	62.4 ± 19.6
Pmax (ms)	122.4 ± 12.8	106.5 ± 9.6
Pdisp (ms)	48.8 ± 12.6	46.5 ± 10.5
QTmin (ms)	358.5 ± 38.4	342.3 ± 30.4
cQTmin (ms)	394.5 ± 35.2	382.6 ± 28.8
QTmax (ms)	434.3 ± 38.4	368.2 ± 32.0
cQTmax (ms)	468.6 ± 37.4	426.8 ± 31.6
QTdisp (ms)	74.8 ± 14.6	60.4 ± 11.5
cQTdisp (ms)	80.4 ± 12.6	70.2 ± 10.2

differences between 154 myocardial hemorrhage patients and healthy volunteers. Outcomes revealed the longest QT interval (QT max) in all leads intra class correlation coefficient (ICC) was 0.86 ± 0.10 for myocardial hemorrhage patients, which is difference from healthy volunteers.

Contrast-enhanced cardiac magnetic resonance imaging (ceMRI) confirms the diagnosis of myocardial hemorrhage

All myocardial hemorrhage patients diagnosed by RTTS-12LE were further confirmed by ceMRI. As shown in **Figure 7**, we demonstrated that ceMRI diagnosed 165 patients with myocardial hemorrhage, while RTTS-12LE only diagnosed 154 patients with myocardial hemorrhage. MRI image further confirmed the diagnosis for patients without or with myocardial hemorrhage on the first-aid (**Figure 8**). These outcomes suggest that RTTS-12LE is an efficient diagnosis method for patients with myocardial hemorrhage on the first-aid.

Discussion

Acute myocardial hemorrhage is myocardial necrosis disease caused by acute, persistent ischemia hypoxia coronary artery myocardial necrosis [18]. Many reports have proposed a number of major advances in pharmacological and mechanical treatments for acute myocardial hemorrhage [8, 19, 20]. Zhang *et al* have investigated the diagnostic effects of a real-time tele-transmission system of 12-lead electrocardiogram on the first-aid for athletes with ST-elevation myocardial hemorrhage and real-time tele-transmission system of 12 lead electrocardiogram is beneficial to the pre-hospital diagnosis of ST-elevation myocardial hemorrhage [9]. In this study, we further evaluated the efficacy of RTTS-12LE for myocardial hemorrhage patients on the first-aid in a total of 175 consecutive patients with myocardial hemorrhage. Outcomes have indicated that plasma ESR, CRP, and SAA levels in myocardial hemorrhage patients are higher than healthy participants. Notably, outcomes suggest that RTTS-12LE presented a sensitivity of 92% and specificity of 95% for myocardial hemorrhage patients.

Evidences have indicated that intravenous beta-blockers in ST-segment elevation myocardial hemorrhage and ST-segment elevation myocardial hemorrhage patients presenting in Killip Class 1 or 2, IV beta-blockers in conjunction with PCI are associated with improvement of LVEF in a systematic review and meta-analysis [21]. Aertker *et al* have suggested that pre-hospital 12-lead electrocardiogram within 60 minutes differentiates proximal versus non-proximal left anterior descending artery myocardial hemorrhage [22]. The relation of ST segment deviations in 12-lead conventional elec-

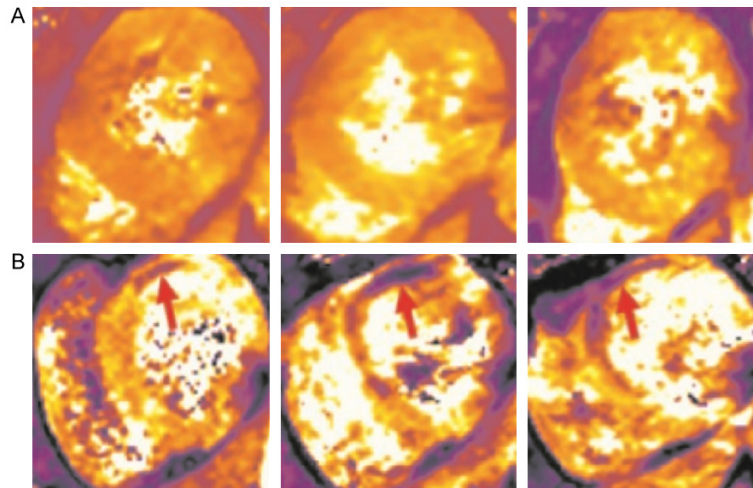


Figure 8. Reprehensive MRI image for patients without ort with myocardial hemorrhage.

trocardiogram, right and posterior leads with the site of occlusion in acute inferior myocardial hemorrhage [23]. In this study, we showed that myocardial hemorrhage patients had a higher Pras disease severity score than healthy volunteers. Outcomes revealed that the sensitivity and specificity of RTTS-12LE is reliable in diagnosing of patients with suspicious myocardial hemorrhage.

Currently, ECG measurements of atrial conduction and cardiac repolarization have not been proven to be useful for diagnosing patients with suspicious myocardial hemorrhage [24, 25]. Research has indicated the diagnostic effects of RTTS-12LE on activation of the cardiac catheterization laboratory and door-to-balloon time in ST-segment elevation acute myocardial hemorrhage [26]. Effectiveness of a prehospital wireless RTTS-12LE for elevation of myocardial hemorrhage has been investigated and results showed that our system of transmitted prehospital electrocardiography and STEMI interpretation by emergency physicians at an online medical control center showed a total false-positive and inappropriate CCL activation rate of 14% over the 8-year study period [27]. Here, we showed the diagnostic rate of RTTS-12LE is 95% for patients with suspicious myocardial hemorrhage. We reported that RTTS-12LE presents more accuracy for patients admitted to hospital with possible myocardial hemorrhage than ECG, suggesting RTTS-12LE recording may be an efficient diagnostic method for

myocardial hemorrhage patients on the first-aid.

In conclusion, our outcomes indicted the diagnostic efficacy for patients with myocardial hemorrhage on the first-aid, but only slightly decreased specificity from 95% to 90%. Although this study identified the diagnostic accuracy of RTTS-12LE for patients with suspicious myocardial hemorrhage, further study should be investigated in a large number population in myocardial hemorrhage patients on first-aid.

Acknowledgements

We appreciated the financial support from Health and Family Planning Commission of Shanghai Jinshan District (JSKJ-KTMS-2015-06).

Disclosure of conflict of interest

None.

Address correspondence to: Yong Li, Emergency Department, Cangzhou Central Hospital, 16 Xinhua West Road, Cangzhou, Hebei Province, China. Tel: +86-317-2075584; E-mail: liyongprof@yeah.net

References

- [1] Muhammad I, He HG, Kowitlawakul Y and Wang W. Narrative review of health-related quality of life and its predictors among patients with coronary heart disease. *Int J Nurs Pract* 2016; 22: 4-14.
- [2] Ski CF, Jelinek M, Jackson AC, Murphy BM and Thompson DR. Psychosocial interventions for patients with coronary heart disease and depression: a systematic review and meta-analysis. *Eur J Cardiovasc Nurs* 2016; 15: 305-316.
- [3] Valtorta NK, Kanaan M, Gilbody S, Ronzi S and Hanratty B. Loneliness and social isolation as risk factors for coronary heart disease and stroke: systematic review and meta-analysis of longitudinal observational studies. *Heart* 2016; 102: 1009-1016.
- [4] Hashemian M, Poustchi H, Mohammadi-Nasrabadi F and Hekmatdoost A. Systematic review of zinc biochemical indicators and risk of coronary heart disease. *ARYA Atheroscler* 2015; 11: 357-365.

- [5] Schroder SL, Richter M, Schroder J, Frantz S and Fink A. Socioeconomic inequalities in access to treatment for coronary heart disease: a systematic review. *Int J Cardiol* 2016; 219: 70-78.
- [6] Christou GA, Christou KA, Nikas DN and Goudevenos JA. Acute myocardial infarction in a young bodybuilder taking anabolic androgenic steroids: a case report and critical review of the literature. *Eur J Prev Cardiol* 2016; 23: 1785-1796.
- [7] Bauters C, Lemesle G, de Groote P and Lamblin N. A systematic review and meta-regression of temporal trends in the excess mortality associated with diabetes mellitus after myocardial infarction. *Int J Cardiol* 2016; 217: 109-121.
- [8] Li G, Hou X, Li Y, Zhang P, Zhao Q, Li J and Shi J. Prognostic value of glycated hemoglobin among patients with ST-segment elevation myocardial infarction: a systematic review and meta-analysis. *Clin Chem Lab Med* 2017; 55: 1090-1099.
- [9] Zhang H, Song D and An L. Effect of a real-time tele-transmission system of 12-lead electrocardiogram on the first-aid for athletes with ST-elevation myocardial infarction. *Pak J Pharm Sci* 2016; 29: 1059-1062.
- [10] Salvini P, Tanzi P, Terranova A, Albi F, Petrolati S, Re F, Verde M, Pozzessere C and Serio A. [First-aid treatment for acute myocardial infarction. Experience at the San Camillo Hospital of Rome]. *Recenti Prog Med* 2002; 93: 523-528.
- [11] Misumida N, Kobayashi A, Saeed M, Fox JT and Kanei Y. Electrocardiographic left ventricular hypertrophy as a predictor for nonsignificant coronary artery disease in patients with non-ST-segment elevation myocardial infarction. *Angiology* 2016; 67: 27-33.
- [12] Arini PD and Valverde ER. Beat-to-beat electrocardiographic analysis of ventricular repolarization variability in patients after myocardial infarction. *J Electrocardiol* 2016; 49: 206-213.
- [13] Ferrando-Castagnetto F, Garibaldi-Remunan A, Vignolo G, Ricca-Mallada R and Baranchuk A. Brugada phenocopy as a dynamic electrocardiographic pattern during acute anterior myocardial infarction. *Ann Noninvasive Electrocardiol* 2016; 21: 425-428.
- [14] Martin TN, Groenning BA, Murray HM, Steedman T, Foster JE, Elliot AT, Dargie HJ, Selvester RH, Pahlm O and Wagner GS. ST-segment deviation analysis of the admission 12-lead electrocardiogram as an aid to early diagnosis of acute myocardial infarction with a cardiac magnetic resonance imaging gold standard. *J Am Coll Cardiol* 2007; 50: 1021-1028.
- [15] Dabrowska B. [Recommendations for the standardization and interpretation of the electrocardiogram according to the American Heart Association Electrocardiography and Arrhythmias Committee and the Heart Rhythm Society 2007 and 2009 - new standards]. *Kardiol Pol* 2009; 67: 1128-1132.
- [16] Polikutina OM, Slepynina YS, Bazdyrev ED, Karetnikova VL and Barbarash OL. [Rate of detection of atherosclerosis in patients with ST elevation myocardial infarction and concomitant chronic obstructive pulmonary disease of light or moderate degree of severity]. *Kardiologia* 2015; 55: 26-31.
- [17] Sahibzada I, Batura D and Hellawell G. Validating multiparametric MRI for diagnosis and monitoring of prostate cancer in patients for active surveillance. *Int Urol Nephrol* 2016; 48: 529-533.
- [18] Doi-Kanno M and Fukahori H. Predictors of depression in patients diagnosed with myocardial infarction after undergoing percutaneous coronary intervention: a literature review. *J Med Dent Sci* 2016; 63: 37-43.
- [19] Al Rajoub B, Noureddine S, El Chami S, Haidar MH, Itani B, Zaiter A and Akl EA. The prognostic value of a new left bundle branch block in patients with acute myocardial infarction: a systematic review and meta-analysis. *Heart Lung* 2017; 46: 85-91.
- [20] Mondello C, Cardia L and Ventura-Spagnolo E. Immunohistochemical detection of early myocardial infarction: a systematic review. *Int J Legal Med* 2017; 131: 411-421.
- [21] Sterling LH, Filion KB, Atallah R, Reynier P and Eisenberg MJ. Intravenous beta-blockers in ST-segment elevation myocardial infarction: a systematic review and meta-analysis. *Int J Cardiol* 2017; 228: 295-302.
- [22] Aertker RA, Barker CM, Anderson HV, Denktas AE, Giesler GM, Julapalli VR, Ledoux JF, Persse DE, Sdringola S, Vooletich MT, McCarthy JJ and Smalling RW. Prehospital 12-lead electrocardiogram within 60 minutes differentiates proximal versus nonproximal left anterior descending artery myocardial infarction. *West J Emerg Med* 2011; 12: 408-413.
- [23] Karbalaie S, Hosseini K and Bozorgi A. The relation of ST segment deviations in 12-lead conventional electrocardiogram, right and posterior leads with the site of occlusion in acute inferior myocardial infarction. *Med J Islam Repub Iran* 2014; 28: 103.
- [24] Moustafa A, Abi-Saleh B, El-Baba M, Hamoui O and AlJaroudi W. Anatomic distribution of culprit lesions in patients with non-ST-segment elevation myocardial infarction and normal ECG. *Cardiovasc Diagn Ther* 2016; 6: 25-33.

Efficacy of RTTS-12LE for myocardial hemorrhage diagnosis

- [25] Levis JT. ECG Diagnosis: isolated posterior wall myocardial infarction. *Perm J* 2015; 19: e143-144.
- [26] Brown JP, Mahmud E, Dunford JV and Ben-Yehuda O. Effect of prehospital 12-lead electrocardiogram on activation of the cardiac catheterization laboratory and door-to-balloon time in ST-segment elevation acute myocardial infarction. *Am J Cardiol* 2008; 101: 158-161.
- [27] Tanguay A, Brassard E, Lebon J, Begin F, Hebert D and Paradis JM. Effectiveness of a prehospital wireless 12-lead electrocardiogram and cardiac catheterization laboratory activation for ST-elevation myocardial infarction. *Am J Cardiol* 2017; 119: 553-559.