

Original Article

Novel *HOXD13* frameshift mutation causes synpolydactyly and clinodactyly

Feng Ni^{1*}, Gang Han^{1*}, Ruiji Guo¹, Yu An², Bin Wang¹, Qingfeng Li¹

¹Department of Plastic and Reconstructive Surgery, Shanghai 9th People's Hospital, Shanghai Jiaotong University School of Medicine, Shanghai 200011, P.R. China; ²Human Phenome Institute and MOE Key Laboratory of Contemporary Anthropology, School of Life Sciences, Fudan University, Shanghai 200438, P.R. China. *Equal contributors.

Received March 1, 2018; Accepted July 13, 2018; Epub October 15, 2018; Published October 30, 2018

Abstract: *HOXD13* is a member of homeobox transcription factor genes essential for the vertebrate body plan. Mutations of this gene have been associated with different types of human limb deformities, including synpolydactyly, clinodactyly, and brachydactyly, but the gene-phenotype relationships are not fully understood. This study reports a novel heterozygous frameshift mutation of *HOXD13* (c.610delC, p. P204fs61x) in a Chinese family with synpolydactyly and clinodactyly. This mutation was detected in the proband by whole-exome sequencing and confirmed by Sanger sequencing. This mutation co-segregated among family members with the phenotype. Furthermore, this study systemically reviewed previous studies and updated the gene-phenotype relationship for human *HOXD13* mutations.

Keywords: *HOXD13*, mutation, synpolydactyly, clinodactyly

Introduction

HOX genes encode a large family of homeobox transcription factors essential for embryonic patterning [1]. There are four *HOX* gene clusters in human genome *HOXA-D*, each containing 9-11 genes. For each cluster, genes at the 3' end are expressed early, in anterior and proximal regions of the embryo. Genes at the 5' end are expressed later, in posterior and distal regions [2]. The 5' members of *HOX* genes (*HOXA9-13* and *HOXD9-13*) are important for vertebrate limb development. During anterior-posterior asymmetry formation of the limb, Sonic Hedgehog (*Shh*) is locally expressed at the posterior margin, as well as other patterning genes, including *dHand*, *Twist1*, and most 5' members of the *Hoxd* gene cluster. At the anterior side, expression of the transcriptional repressor form of Gli3 (Gli3R) inhibits expression of these genes. The opposing gradient of *Shh* and Gli3R, as well as their target genes, specifies digit number and identity [3].

Germline mutations of *HOXD13* have been associated with various human congenital limb

malformations [4]. This gene is comprised of two exons encoding a protein of 343 amino acids. The N-terminal region of *HOXD13* protein contains several poly-serine and poly-alanine residues, whereas the C-terminal region contains the DNA-binding homeobox domain [5]. Patients with *HOXD13* mutations display various phenotypes, including synpolydactyly 1 (SPD1) [6-9], brachydactyly D (BDD) [10], syndactyly 5 (SDTY5) [11], brachydactyly-syndactyly syndrome (BDS) [11], brachydactyly E1 (BDE1) [7, 10], VACTERL association (VACTERL) [12], and brachydactyly-syndactyly-oligodactyly syndrome (BDSO) [13]. However, the gene-phenotype relationship is not fully understood.

The present study identified a novel frameshift mutation of *HOXD13* (c.610delC, p. P204fs61x) in a family with synpolydactyly and clinodactyly. Phenotypes varied between affected family members, exhibiting either synpolydactyly, clinodactyly, or both. Finally, this study systemically reviewed the literature and updated the gene-phenotype relationship of this gene.

A novel HOXD13 frameshift mutation causes synpolydactyly and clinodactyly

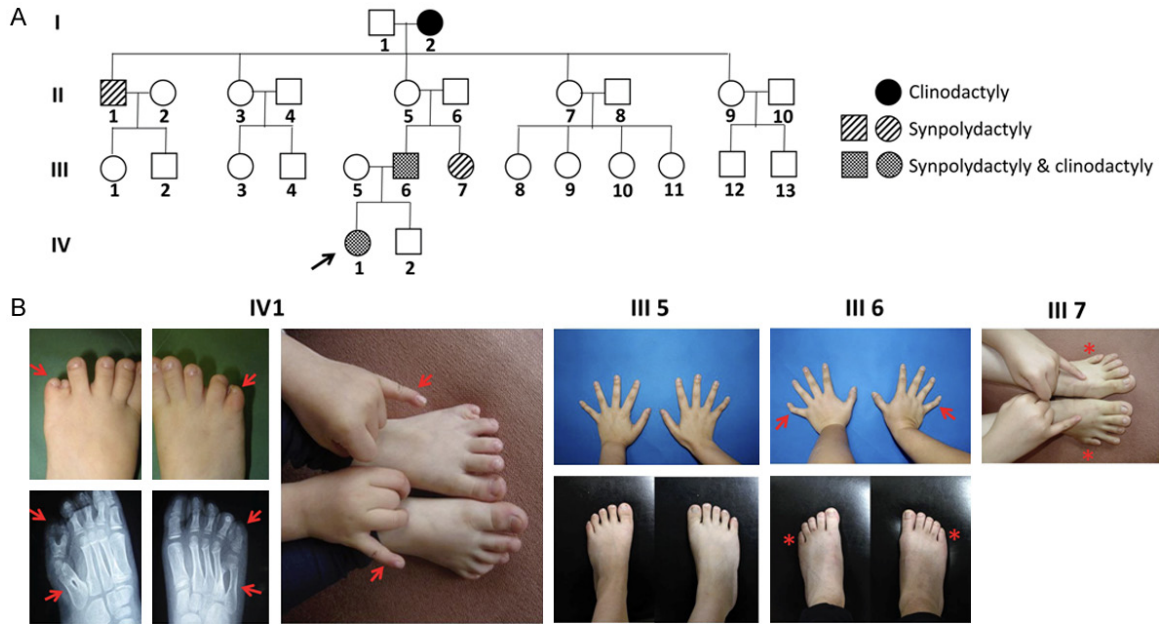


Figure 1. A. Pedigree of a four-generation Chinese family with synpolydactyly and/or clinodactyly. Squares and circles denote males and females, respectively. Unaffected family members are presented as blank squares and circles. Phenotypes of affected family members are as indicated. The proband is denoted by an arrow. B. Clinical features of the proband (IV-1) and other family members (III5, III6 and III7). Asterisks indicate affected limbs after previous surgery. Arrows indicate limb malformations.

Methods

Pedigree recruitment

Members of a four-generation Chinese family with synpolydactyly and clinodactyly were recruited with written consent. Phenotypes of all family members were obtained based on either orthopedist diagnoses or description from the proband's parents. Participant hands and feet were radiographed. A thorough physical examination was performed to exclude other congenital malformations.

Genomic DNA extraction

Peripheral blood of the proband (IV1), her affected father (III6), and unaffected mother (III5) was collected (**Figure 1A**). Genomic DNA was extracted from 200 μ l peripheral blood using a QIAGEN DNeasy Blood & Tissue Kit (Cat. No. 69504), following manufacturer instructions. Quantity and quality of extracted DNA was assessed by NanoDrop spectrophotometer (Thermo Fisher Scientific, USA) and agarose electrophoresis.

Whole exome sequencing

Genomic DNA of the proband was subjected to whole exome sequencing. Exome capture was

performed by using SureSelectXT Human All Exon V5 kit (Agilent Technologies, USA). DNA library was sequenced on an Illumina HiSeq 2000 sequencing system (Illumina, CA, USA) with a read length of 100 base pairs.

Sequencing data analysis

Raw data was converted to Fastq format and the base quality was assessed by FastQC program. Reads were aligned to reference human genome hg19 using BWA (0.7.12) program. Variations of target regions were identified by HaplotypeCaller tool of GATK program (version 3.5). They were then annotated by ANNOVAR program.

Sanger sequencing

To validate this mutation, this study amplified the DNA fragment flanking this position by polymerase chain reaction (PCR) and performed Sanger sequencing. Primer sequences were 5'-TCGTCCTCTTCTGCCGTTG-3' (forward) and 5'-GAGAAAACGTGTCTGCGCT-3' (reverse).

Results

Clinical report

The great-grandmother (I2) of the proband had bilateral clinodactyly in the fifth fingers. The

A novel HOXD13 frameshift mutation causes synpolydactyly and clinodactyly

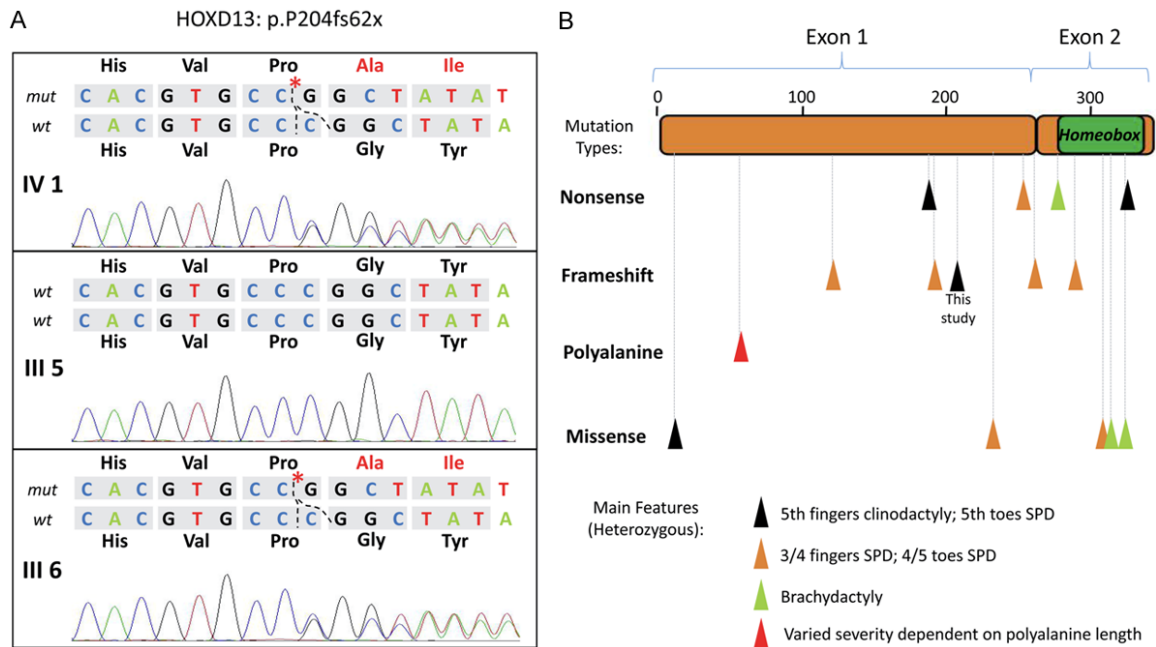


Figure 2. A. Novel single-nucleotide deletion in *HOXD13* of the proband and her father, but not her mother, examined by Sanger sequencing. B. The simplified gene-phenotype relationship of *HOXD13*. Described phenotypes are from individuals with heterozygous mutations; SPD, synpolydactyly. References of this schematic are shown in the discussion section.

proband (IV1) and her father (III6) exhibited bilateral synpolydactyly in the fifth toes, in addition to bilateral clinodactyly in the fifth fingers (**Figure 1B**). However, the other two affected family members (III1 and III7) only had bilateral synpolydactyly in the fifth toes.

Whole exome sequencing data

The unique mapped ratio was 76%. Exome coverage was above 99% and the mean read depth was above 80x. A total of 38,685 single nucleotide variations and 4,759 small insertion and deletions were identified.

Identification of pathogenic mutations

Of identified single-nucleotide variations and insertion/deletions, this study found a heterozygous single nucleotide deletion, c.610delC, in the key limb development gene *HOXD13*. This deletion resulted in a frameshift in the open reading frame of *HOXD13* gene, causing a pre-mature termination of the protein (p.P204fs61x). This mutation was not found in 1000 Genomes [14], Exome Aggregation Consortium [15], and Kaviar [16] databases. According to ACMG guidelines [17], this mutation can be classified as PVS1 (pathogenicity

is very strong) because loss of function of *HOXD13* is a known mechanism for causing synpolydactyly. To validate this mutation, this study amplified the DNA fragment flanking this position by polymerase chain reaction (PCR) and performed Sanger sequencing. Results clearly showed a heterozygous single cytosine deletion in the proband (**Figure 2A**). This mutation was also detected in the proband's affected father, but not in the unaffected mother (**Figure 2A**), further supporting the pathogenicity of this mutation.

Discussion

Germline mutations of *HOXD13* have been frequently detected in human congenital limb malformations [8]. Using WES analysis, the present study identified a novel frameshift mutation of *HOXD13* in a Chinese family with synpolydactyly and/or clinodactyly, with no other obvious malformations.

Many *HOXD13* mutations have been identified in various limb malformations [4]. Reported mutations are of wide range of types, including point mutation, insertion, and deletion. They are located in both exons and splicing sites of this gene, causing protein truncation, amino

A novel HOXD13 frameshift mutation causes synpolydactyly and clinodactyly

acids substitution, insertion, and deletion. In most cases, *HOXD13* mutations are heterozygous and inherit in a dominant manner. Reviewing all PubMed papers reporting *HOXD13* mutations in humans, the gene-phenotype relationship for this gene was summarized (**Figure 2B**). In general, there is a wide spectrum of phenotypes caused by *HOXD13* mutation, shared by different mutation forms, including synpolydactyly of 3rd and 4th fingers or 4th and 5th toes, postaxial polysyndactyly of 5th toe, and clinodactyly or camptodactyly of 4th or 5th fingers. In addition, phenotypes can considerably vary among family numbers bearing the same mutation. Despite this complexity, there is still a certain gene-phenotype relationship for *HOXD13* mutations. For N-terminal polyalanine tract expansion, penetrance, involved limb number, and severity of limb malformation are positively correlated with expansion length [6, 9, 12, 18-33]. The most severe limb malformation has been found in this form of *HOXD13* mutation, probably due to a strong dominant negative effect [21]. Certain missense mutations within the homeobox domain of *HOXD13* can cause severe or uncommon phenotypes, such as brachydactyly and ectrodactyly, not observed in other mutation forms [7, 8, 10, 11, 13, 19, 34-39]. This could be attributed to the gain of function of the homeobox domain. In contrast, the nonsense, frameshift, and splicing site mutations usually cause mild or typical synpolydactyly phenotypes, probably due to nonsense-mediated mRNA decay-caused haploinsufficiency [19, 40-47]. In this study, the p. P204fs61x mutation only resulted in synpolydactyly in the fifth toes and clinodactyly in the fifth fingers. In a recent study, a nearby p. R186x mutation of *HOXD13* was reported to cause very similar phenotypes, indicating a certain gene-phenotype relationship [48]. Homozygous mutations of *HOXD13* have generally resulted in severe limb malformations, such as complete syndactyly, brachydactyly, ectrodactyly, and hypoplastic metacarpals [6, 9, 22, 25, 27-30, 34, 43, 44]. Hypospadias has also been found in several homozygous individuals [25, 29]. The molecular basis of intrafamilial phenotype variation and gene-phenotype relationship require further exploration.

Currently, WES is the most cost-effective method for screening of pathogenic gene mutations for Mendelian inherited diseases. This study has proven the effectiveness of this approach

in identification of pathogenic mutations in synpolydactyly. However, due to the strong gene-phenotype relationship for *HOXD13* mutation, a quick candidate gene test before WES will be more efficient when the patient has typical *HOXD13*-related phenotype, such as syndactyly of 3rd and 4th fingers, clinodactyly of 5th or 4th fingers, and synpolydactyly of 5th toes.

In conclusion, this present study identified a novel heterozygous *HOXD13* single-base deletion (c.610delC), causing a frameshift before the homeobox domain (p. P204fs61x), resulting in bilateral synpolydactyly of 5th and 5' toes and/or clinodactyly of 5th fingers in a Chinese family. These findings should help to further delineate the gene-phenotype relationship for *HOXD13* gene.

Acknowledgements

The authors would like to thank Xi Yang and Yongkang Jiang (Department of Plastic and Reconstructive Surgery, Shanghai 9th People's Hospital, Shanghai Jiaotong University School of Medicine) for information and blood sample collection of this pedigree. This work was funded by the National Natural Science Foundation of China [grant numbers 81271725, 81571930, and 81772115] and the Top Priority Clinical Medical Center of Shanghai Municipal Commission of Health and Family Planning.

Disclosure of conflict of interest

None.

Address correspondence to: Qingfeng Li and Bin Wang, Department of Plastic and Reconstructive Surgery, Shanghai 9th People's Hospital, Shanghai Jiaotong University School of Medicine, 639 Zhizaoju Road, Shanghai 200011, P.R. China. Tel: +86 21 23271699; Fax: +86 21 53078025; E-mail: dr.liqingfeng@yahoo.com (QFL); wangbin1766@163.com (BW)

References

- [1] Krumlauf R. Hox genes in vertebrate development. *Cell* 1994; 78: 191-201.
- [2] Goodman FR. Limb malformations and the human HOX genes. *Am J Med Genet* 2002; 112: 256-65.
- [3] Zeller R, Lopez-Rios J, Zuniga A. Vertebrate limb bud development: moving towards integrative analysis of organogenesis. *Nat Rev Genet* 2009; 10: 845-58.

A novel HOXD13 frameshift mutation causes synpolydactyly and clinodactyly

- [4] Brison N, Debeer P, Tylzanowski P. Joining the fingers: a HOXD13 Story. *Dev Dyn* 2014; 243: 37-48.
- [5] Goodman FR, Scambler PJ. Human HOX gene mutations. *Clin Genet* 2001; 59: 1-11.
- [6] Akarsu AN, Stoilov I, Yilmaz E, Sayli BS, Sarfarazi M. Genomic structure of HOXD13 gene: a nine polyalanine duplication causes synpolydactyly in two unrelated families. *Hum Mol Genet* 1996; 5: 945-52.
- [7] Dai L, Liu D, Song M, Xu X, Xiong G, Yang K, Zhang K, Meng H, Guo H, Bai Y. Mutations in the homeodomain of HOXD13 cause syndactyly type 1-c in two Chinese families. *PLoS One* 2014; 9: e96192.
- [8] Debeer P, Bacchelli C, Scambler PJ, De Smet L, Fryns JP, Goodman FR. Severe digital abnormalities in a patient heterozygous for both a novel missense mutation in HOXD13 and a polyalanine tract expansion in HOXA13. *J Med Genet* 2002; 39: 852-6.
- [9] Ibrahim DM, Tayebi N, Knaus A, Stiege AC, Sahebzamani A, Hecht J, Mundlos S, Spielmann M. A homozygous HOXD13 missense mutation causes a severe form of synpolydactyly with metacarpal to carpal transformation. *Am J Med Genet A* 2016; 170: 615-21.
- [10] Kjaer KW, Hansen L, Eiberg H, Utkus A, Skovgaard LT, Leicht P, Opitz JM, Tommerup N. A 72-year-old Danish puzzle resolved—comparative analysis of phenotypes in families with different-sized HOXD13 polyalanine expansions. *Am J Med Genet A* 2005; 138: 328-39.
- [11] Johnson D, Kan SH, Oldridge M, Trembath RC, Roche P, Esnouf RM, Giele H, Wilkie AO. Missense mutations in the homeodomain of HOXD13 are associated with brachydactyly types D and E. *Am J Hum Genet* 2003; 72: 984-97.
- [12] Zhao X, Sun M, Zhao J, Leyva JA, Zhu H, Yang W, Zeng X, Ao Y, Liu Q, Liu G, Lo WH, Jabs EW, Amzel LM, Shan X, Zhang X. Mutations in HOXD13 underlie syndactyly type V and a novel brachydactyly-syndactyly syndrome. *Am J Hum Genet* 2007; 80: 361-71.
- [13] Garcia-Barceló MM, Wong KK, Lui VC, Yuan ZW, So MT, Ngan ES, Miao XP, Chung PH, Khong PL, Tam PK. Identification of a HOXD13 mutation in a VACTERL patient. *Am J Med Genet A* 2008; 146A: 3181-5.
- [14] Ibrahim DM, Hansen P, Rödelsperger C, Stiege AC, Doelken SC, Horn D, Jäger M, Janetzki C, Krawitz P, Leschik G, Wagner F, Scheuer T, Schmidt-von Kegler M, Seemann P, Timmermann B, Robinson PN, Mundlos S, Hecht J. Distinct global shifts in genomic binding profiles of limb malformation-associated HOXD13 mutations. *Genome Res* 2013; 23: 2091-102.
- [15] 1000 Genomes Project Consortium, Auton A, Brooks LD, Durbin RM, Garrison EP, Kang HM, Korbel JO, Marchini JL, McCarthy S, McVean GA, Abecasis GR. A global reference for human genetic variation. *Nature* 2015; 526: 68-74.
- [16] Lek M, Karczewski KJ, Minikel EV, Samocha KE, Banks E, Fennell T, O'Donnell-Luria AH, Ware JS, Hill AJ, Cummings BB, Tukiainen T, Birnbaum DP, Kosmicki JA, Duncan LE, Estrada K, Zhao F, Zou J, Pierce-Hoffman E, Berghout J, Cooper DN, Deflaux N, DePristo M, Do R, Flannick J, Fromer M, Gauthier L18, Goldstein J, Gupta N, Howrigan D, Kiezun A, Kurki MI, Moonshine AL, Natarajan P, Orozco L, Peloso GM, Poplin R, Rivas MA, Ruano-Rubio V, Rose SA, Ruderfer DM, Shakir K, Stenson PD, Stevens C, Thomas BP, Tiao G, Tusie-Luna MT, Weisburd B, Won HH, Yu D, Altshuler DM, Ardisino D, Boehnke M, Danesh J, Donnelly S, Elosua R, Florez JC, Gabriel SB, Getz G, Glatt SJ, Hultman CM, Kathiresan S, Laakso M, McCarrroll S, McCarthy MI, McGovern D, McPherson R, Neale BM, Palotie A, Purcell SM, Saleheen D, Scharf JM, Sklar P, Sullivan PF, Tuomilehto J, Tsuang MT, Watkins HC, Wilson JG, Daly MJ, MacArthur DG; Exome Aggregation Consortium. Analysis of protein-coding genetic variation in 60,706 humans. *Nature* 2016; 536: 285-91.
- [17] Glusman G, Caballero J, Mauldin DE, Hood L, Roach JC. Kaviar: an accessible system for testing SNV novelty. *Bioinformatics* 2011; 27: 3216-7.
- [18] Richards S, Aziz N, Bale S, Bick D, Das S, Gastier-Foster J, Grody WW, Hegde M, Lyon E, Spector E, Voelkerding K, Rehm HL; ACMG Laboratory Quality Assurance Committee. Standards and guidelines for the interpretation of sequence variants: a joint consensus recommendation of the American college of medical genetics and genomics and the association for molecular pathology. *Genet Med* 2015; 17: 405-24.
- [19] Dai L, Heng ZC, Zhu J, Cai R, Mao M, Wang H, Lin MJ. Mutation analysis of HOXD13 gene in a Chinese pedigree with synpolydactyly. *Zhonghua Yi Xue Yi Chuan Xue Za Zhi* 2005; 22: 277-80.
- [20] Furniss D, Kan SH, Taylor IB, Johnson D, Critchley PS, Giele HP, Wilkie AO. Genetic screening of 202 individuals with congenital limb malformations and requiring reconstructive surgery. *J Med Genet* 2009; 46: 730-5.
- [21] Gong L, Wang B, Wang J, Yu H, Ma X, Yang J. Polyalanine repeat expansion mutation of the HOXD13 gene in a Chinese family with unusual clinical manifestations of synpolydactyly. *Eur J Med Genet* 2011; 54: 108-11.
- [22] Goodman FR, Mundlos S, Muragaki Y, Donnai D, Giovannucci-Uzielli ML, Lapi E, Majewski F, McGaughan J, McKeown C, Reardon W, Upton J, Winter RM, Olsen BR, Scambler PJ. Synpoly-

A novel HOXD13 frameshift mutation causes synpolydactyly and clinodactyly

- dactyly phenotypes correlate with size of expansions in HOXD13 polyalanine tract. *Proc Natl Acad Sci U S A* 1997; 94: 7458-63.
- [23] Horsnell K, Ali M, Malik S, Wilson L, Hall C, Debeer P, Crow Y. Clinical phenotype associated with homozygosity for a HOXD13 7-residue polyalanine tract expansion. *Eur J Med Genet* 2006; 49: 396-401.
- [24] Jin H, Lin PF, Wang QM, Mao F, Cai Y, Gong YQ. [Synpolydactyly in a Chinese kindred: mutation detection, prenatal ultrasonographic and molecular diagnosis]. *Zhonghua Yi Xue Yi Chuan Xue Za Zhi* 2011; 28: 601-5.
- [25] Kjaer KW, Hedeboe J, Bugge M, Hansen C, Fris-Henriksen K, Vestergaard MB, Tommerup N, Opitz JM. HOXD13 polyalanine tract expansion in classical synpolydactyly type Vordingborg. *Am J Med Genet* 2002; 110: 116-21.
- [26] Kuru I, Maralcan G, Yucel A, Aktepe F, Turkmen S, Solak M. Synpolydactyly of the foot in homozygotes. *J Am Podiatr Med Assoc* 2006; 96: 297-304.
- [27] Li Y, Xin Q, Shan S, Li J, Liu Q. [Mutation analysis of HOXD13 gene in a Chinese family affected with autosomal dominant synpolydactyly]. *Zhonghua Yi Xue Yi Chuan Xue Za Zhi* 2015; 32: 481-4.
- [28] Malik S, Girisha KM, Wajid M, Roy AK, Phadke SR, Haque S, Ahmad W, Koch MC, Grzeschik KH. Synpolydactyly and HOXD13 polyalanine repeat: addition of 2 alanine residues is without clinical consequences. *BMC Med Genet* 2007; 8: 78.
- [29] Muragaki Y, Mundlos S, Upton J, Olsen BR. Altered growth and branching patterns in synpolydactyly caused by mutations in HOXD13. *Science* 1996; 272: 548-51.
- [30] Tüzel E, Samli H, Kuru I, Türkmen S, Demir Y, Maralcan G, Güler C. Association of hypospadias with hypoplastic synpolydactyly and role of HOXD13 gene mutations. *Urology* 2007; 70: 161-4.
- [31] Wajid M, Ishii Y, Kurban M, Dua-Awereh MB, Shimomura Y, Christiano AM. Polyalanine repeat expansion mutations in the HOXD13 gene in Pakistani families with synpolydactyly. *Clin Genet* 2009; 76: 300-2.
- [32] Xin Q, Li L, Li J, Qiu R, Guo C, Gong Y, Liu Q. Eight-alanine duplication in homeobox D13 in a Chinese family with synpolydactyly. *Gene* 2012; 499: 48-51.
- [33] Zhao XL, Meng JP, Sun M, Ao Y, Wu AH, Lo HY, Zhang X. [HOXD13 polyalanine tract expansion in synpolydactyly: mutation detection and prenatal diagnosis in a large Chinese family]. *Zhonghua Yi Xue Yi Chuan Xue Za Zhi* 2005; 22: 5-9.
- [34] Zhou J, Chen Y, Cao K, Zou Y, Zhou H, Hu F, Ni B, Chen Y. Functional classification and mutation analysis of a synpolydactyly kindred. *Exp Ther Med* 2014; 8: 1569-74.
- [35] Brison N, Debeer P, Fantini S, Oley C, Zappavigna V, Luyten FP, Tylzanowski P. An N-terminal G11A mutation in HOXD13 causes synpolydactyly and interferes with Gli3R function during limb pre-patterning. *Hum Mol Genet* 2012; 21: 2464-75.
- [36] Caronia G, Goodman FR, McKeown CM, Scambler PJ, Zappavigna V. An I47L substitution in the HOXD13 homeodomain causes a novel human limb malformation by producing a selective loss of function. *Development* 2003; 130: 1701-12.
- [37] Deng H, Tan T, He Q, Lin Q, Yang Z, Zhu A, Guan L, Xiao J, Song Z, Guo Y. Identification of a missense HOXD13 mutation in a Chinese family with syndactyly type I-c using exome sequencing. *Mol Med Rep* 2017; 16: 473-7.
- [38] Fantini S, Vaccari G, Brison N, Debeer P, Tylzanowski P, Zappavigna V. A G220V substitution within the N-terminal transcription regulating domain of HOXD13 causes a variant synpolydactyly phenotype. *Hum Mol Genet* 2009; 18: 847-60.
- [39] Wang B, Xu B, Cheng Z, Zhou X, Wang J, Yang G, Cheng L, Yang J, Ma X. A novel non-synonymous mutation in the homeodomain of HOXD13 causes synpolydactyly in a Chinese family. *Clin Chim Acta* 2012; 413: 1049-52.
- [40] Zhou X, Zheng C, He B, Zhu Z, Li P, He X, Zhu S, Yang C, Lao Z, Zhu Q, Liu X. A novel mutation outside homeodomain of HOXD13 causes synpolydactyly in a Chinese family. *Bone* 2013; 57: 237-41.
- [41] Goodman F, Giovannucci-Uzielli ML, Hall C, Reardon W, Winter R, Scambler P. Deletions in HOXD13 segregate with an identical, novel foot malformation in two unrelated families. *Am J Hum Genet* 1998; 63: 992-1000.
- [42] Jamsheer A, Sowinska A, Kaczmarek L, Latos-Bielenska A. Isolated brachydactyly type E caused by a HOXD13 nonsense mutation: a case report. *BMC Med Genet* 2012; 13: 4.
- [43] Kan SH, Johnson D, Giele H, Wilkie AO. An acceptor splice site mutation in HOXD13 results in variable hand, but consistent foot malformations. *Am J Med Genet A* 2003; 121A: 69-74.
- [44] Kurban M, Wajid M, Petukhova L, Shimomura Y, Christiano AM. A nonsense mutation in the HOXD13 gene underlies synpolydactyly with incomplete penetrance. *J Hum Genet* 2011; 56: 701-6.
- [45] Low KJ, Newbury-Ecob RA. Homozygous nonsense mutation in HOXD13 underlies synpolydactyly with a cleft. *Clin Dysmorphol* 2012; 21: 141-3.
- [46] Radhakrishnan P, Nayak SS, Pai MV, Shukla A, Girisha KM. Occurrence of synpolydactyly and

A novel HOXD13 frameshift mutation causes synpolydactyly and clinodactyly

- omphalocele in a fetus with a HOXD13 mutation. *J Pediatr Genet* 2017; 6: 194-7.
- [47] Shi X, Ji C, Cao L, Wu Y, Shang Y, Wang W, Luo Y. A splice donor site mutation in HOXD13 underlies synpolydactyly with cortical bone thinning. *Gene* 2013; 532: 297-301.
- [48] Wang B, Li N, Geng J, Wang Z, Fu Q, Wang J, Xu Y. Exome sequencing identifies a novel nonsense mutation of HOXD13 in a Chinese family with synpolydactyly. *Congenit Anom (Kyoto)* 2017; 57: 4-7.