Int J Clin Exp Med 2018;11(10):11262-11269
www.ijcem.com /ISSN:1940-5901/IJCEM0078990

Case Report

Primary intraosseous myxoid chondrosarcoma arising in the right radius

Chang-Hong Wei[1*], Mei-Qin Li[2*], Sheng-Ming Wu[1*], Si-Tong Lin[1], Xin-Qing Ye[1], Ying Huang[3], Jian-Hong Zhong[4], Jun Chen[1]

Departments of [1]Pathology, [2]Laboratory, [3]Radiology, [4]Hepatobiliary Surgery, Affiliated Tumor Hospital of Guangxi Medical University, Nanning, Guangxi, P. R. China. [*]Equal contributors.

Received May 4, 2018; Accepted July 26, 2018; Epub October 15, 2018; Published October 30, 2018

Abstract: Aims: The aim of this study was to explore and analyze clinicopathological features, diagnosis, and differential diagnosis of primary intraosseous myxoid chondrosarcoma. Methods: A rare case of intraosseous myxoid chondrosarcoma was analyzed by histopathology, immunohistochemistry, and molecular pathology, combined with imaging. Related literature was comprehensively reviewed. Results: The patient was a 29-year-old young woman with a tumor located in the right forearm (10×6 cm). Imaging studies showed that the mid-right radius bone had expanded to a size of about 6.8×4.9×3.7 cm, with corresponding cortical thinning. Saw segmentation and enhanced scanning showed irregular enhancement, with the possibility of a low-grade malignant tumor on the right side of the middle radius. She underwent surgical resection. Histopathology, immunohistochemistry, and molecular pathology testing revealed intraosseous myxoid chondrosarcoma. Conclusion: Intraosseous myxoid chondrosarcoma is a rare soft tissue tumor. Diagnosis mainly relies on imaging, morphology, and immunohistochemical markers. If necessary, the line of molecular pathology is helpful, but the main treatment is surgical excision.

Keywords: Myxoid chondrosarcoma, bone, diagnosis, EWSR1

Introduction

Myxoid chondrosarcoma is a rare soft tissue malignancy with unique morphological features, including extra-skeletal myxoid chondrosarcoma and intraosseous myxoid chondrosarcoma. For the former, studies have confirmed that it can occur in soft tissue, liver, lung, breast, nasopharyngeal, and other tissues [1]. For intraosseous myxoid chondrosarcoma, studies are rare. There are few abroad, with myxoid chondrosarcoma existing with characteristic translocation, usually involving NR4A3 and EWSR1 [2, 3]. Extra-skeletal myxoid chondrosarcoma has been rarely reported in bones and may be confused with conventional chondrosarcoma or mucosal sarcoma with mucus characteristics. Myxoid chondrosarcoma in bone is a diagnostic difficulty, requiring molecular confirmation. However, extra-skeletal myxoid chondrosarcomas have been reported to be extensively involved in the skeleton, in rare cases, radiologically manifesting as the main source of bone. In these cases, differential diagnosis includes conventional chondrosarcoma, chordoma, myoepithelioma, Ewing's sarcoma, and primitive chondroblastic osteosarcoma with mucus characteristics. Diagnosis had been controversial, as it overlaps with the rarity and morphology of other solid tumors. This present study describes a case of extra-skeletal myxoid chondrosarcoma present in the bone, incorporating imaging findings and molecular confirmation of the presence of the translocation with EWSR1 genes, proving that it can be used as a primary tumor arising within the bone.

Materials and methods

Case information

The case was from the Affiliated Tumor Hospital of Guangxi Medical University for surgical resection specimens from February 2017. A 29-year-old woman inadvertently found the right forearm tumor 10 years ago and did not pay attention. However, the mass of the tumor

Table 1. Immunohistochemistry reagents used in this study

Antibody marker	Clone number	Dilution	Antigen retrieval	Manufacturer	Result
Cytokeratin (pan)	AE1/AE3	1:150	Heat, Pressure	China MaiXin	(-)
P63	4A4	Prediluted	Heat, Pressure	China MaiXin	(-)
Calponin	CALP	Prediluted	Heat, Pressure	China MaiXin	(-)
SMA	1A4	Prediluted	Heat, Pressure	China MaiXin	(-)
CK14	LL002	Prediluted	Heat, Pressure	China MaiXin	(-)
S-100	4c4.9	Prediluted	Heat, Pressure	China MaiXin	(-)
SOX-10	EP268	Prediluted	Heat, Pressure	China MaiXin	(-)
CD56	123C3.D5	1:50	Heat, Pressure	China MaiXin	(-)
Synaptophysin (SY)	SP11	1:80	Heat, Pressure	China MaiXin	(-)
NSE	E27	Prediluted	Heat, Pressure	China MaiXin	(+)
CD117	YR145	Prediluted	Heat, Pressure	China MaiXin	(-)
CD99	O13	Prediluted	Heat, Pressure	China MaiXin	(-)
Ki-67	MIB-1	1:200	Heat, Pressure	China MaiXin	15% (+)

increased over the past two years, with the size of about 10×6 cm, but upper limb activity was not significantly affected. This patient's tumor was surgically removed and she was followed up for 10 months. As of the last follow up, the patient was disease free and in good condition.

Immunohistochemical analysis

Surgical specimens were fixed in 4% neutral buffered formalin, embedded in paraffin, and cut into 4 μm thick sections. With deparaffinization, hydration and endogenous peroxidase were used to block the inactivation, after immunohistochemical staining (Ventana BenchMark Ultra) and visualizing using the view DAB Assay kit to obtain a brown reaction product. Antigen, antibody source, dilution, cloning number, and source used are shown in **Table 1**. At the end of staining, the slides were removed from the automatic dyeing machine, counterstained with hematoxylin, and dehydrated with gradient alcohol. For the experiment, both negative controls and positive controls were performed. The two pathologists observed with the microscope and recorded experimental results.

Fluorescent in situ hybridization analysis

Fluorescence *in situ* hybridization (FISH) studies were performed for this case. Specimens of formalin-fixed paraffin embedded sections of 4 μm thick were subjected to two-color FISH using the EWSR1 isolation probe. EWSR1 FISH ASSAY kit was purchased from the United States Abbott Corp. Prior to hybridization, sections were each dewaxed in three-cylinder xylene for 5 minutes at room temperature, then dehydrated in 75%, 85% and 95% ethanol for 2 minutes each before air-drying. Sections were placed in a flask containing 1 Boil in the autoclave in boiling water (100°C) for 3 minutes, then under pressure for 7 minutes. The autoclave was flushed with tap water to depressurize and cool, then the slices were placed in distilled water for 2 times. Slices are immersed in 37°C pepsin solution for 50 minutes (pepsin and HCL mixed, mixed into a 37°C water baths preheated). They were placed in distilled water for 3 minutes after slicing 70%, 90% and 100% alcohol dehydration, each for 1 minute. The film was blown with a hot hair dryer, followed by denaturation, overnight hybridization, and DAPI counterstaining. Hybridization signals were evaluated in 100 intervals nuclei to characterize strong signals and good signals, while experimental results were recorded.

Case report

A 29-year-old young woman with a mass in the right radius was presented. She noticed the tumor as early as 10 years ago, but she felt that the tumor had increased in the past two years. During clinical evaluation, the lumps were solid and painless, but the activities of the upper limbs were not significantly affected. Radiographs, CT, and MRI examinations showed that there were multiple high-density images in the middle of the right radius, considered as a low-grade primary bone cancer. After the entire tumor in the right radius was excised, the surgeon filled the defect with the prepared left

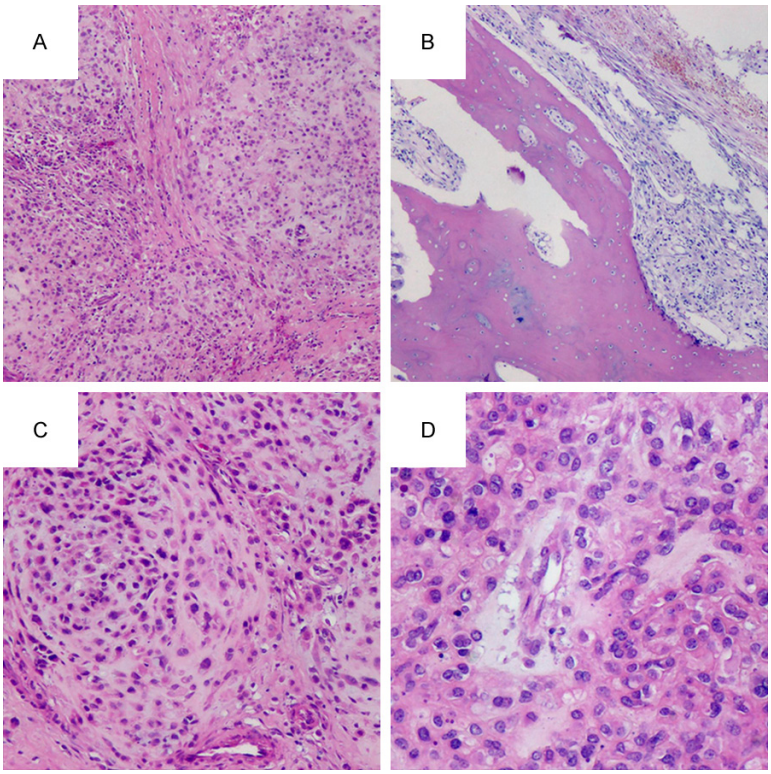

Figure 1. (A, HEX40): Images show a lobulated tumor resembling a chondrosarcoma image without the formation of a cartilaginous lacuna; (B, HEX40): tumor invasion destroys the normal host bone; (C, HEX100): The tumor cells are ribbon-like, cord-like, small nest arrangement, visible number of different mucus-like matrix. (D, HEX400): Tumor cells are round, oval or short fusiform, cytoplasmic eosinophilic or vascular.

fibular segment. The pathologist diagnosed the tumor as intraosseous myxoid chondrosarcoma. After a stable course of disease, the patient did not relapse according to 10 months of follow-up.

Results

Pathologic findings

In the general specimen, clinical examination was a section of the radius of 10×5.5×4 cm. The radius body around the tumor mass had a size of 7.5 * 5.5 * 4 cm. After cutting the tumor to destroy the radius and the formation of a cavity, no normal radial structure was seen. The tumor was polygonal and pale yellow solid nature, with obvious hemorrhagic necrosis. Tumor destruction of the original bone structure infiltration was obvious.

According to histopathology, the tumor showed a lobulated structure under the microscope, mainly composed of chondroblast-like small round cells, accompanied by immature cartilage-like matrix. Juvenile small cells in the mucus background were cord-like, tubular-like arrangement, with a small number of transparent cells. The tumor cells were rich, round, and short fusiform. Focal cells were epithelial and rhabdomyosarcoma and the chromatin was rough, with interstitial seeing myxoid matrix. Local tumor cells showed small cluster-like infiltration of interstitial (**Figure 1**).

Immunohistochemistry

According to immunohistochemistry, the tumor cells showed negative expression of cytokeratin AE1/AE3, P63, Calponin, SMA, CK14, S-100, SOX-10, CD56, CD117, Syn, and CD99, along with positive expression of Ki-67 of approximately 15% (**Table 1**; **Figure 2A** and **2B**).

Radiographic findings

The patient underwent a series of imaging examinations that showed primary bone tumors. X-ray examinations revealed bone expansion near the mid-radius of the right radius, with a size of about 7.6 * 4.1 * cm, corresponding cortical bone thinning, and visible within the bone several oval-shaped bone interspaces that were “soap bubble-like”. The tumor boundary was still clear. Lesions and normal bone boundaries could be seen at the hardening border, with no periosteal reaction and soft tissue mass, suggesting that tumor lesions were located in the bone, with the possibility of giant cell tumor of bone (**Figure 3A**). SPECT/PET-ECT examination showed that the right radial median bulge could be seen as a radioactive defect and enrichment focus. Diagnosis showed that the right radial bone metabolism was likely of the primary bone tumor (**Figure 3B**). CT scan showed the proximal radius of the right radius of the bone expansion. Corresponding cortical thinning and uneven thickness and internal density were revealed, seeing multiple high or

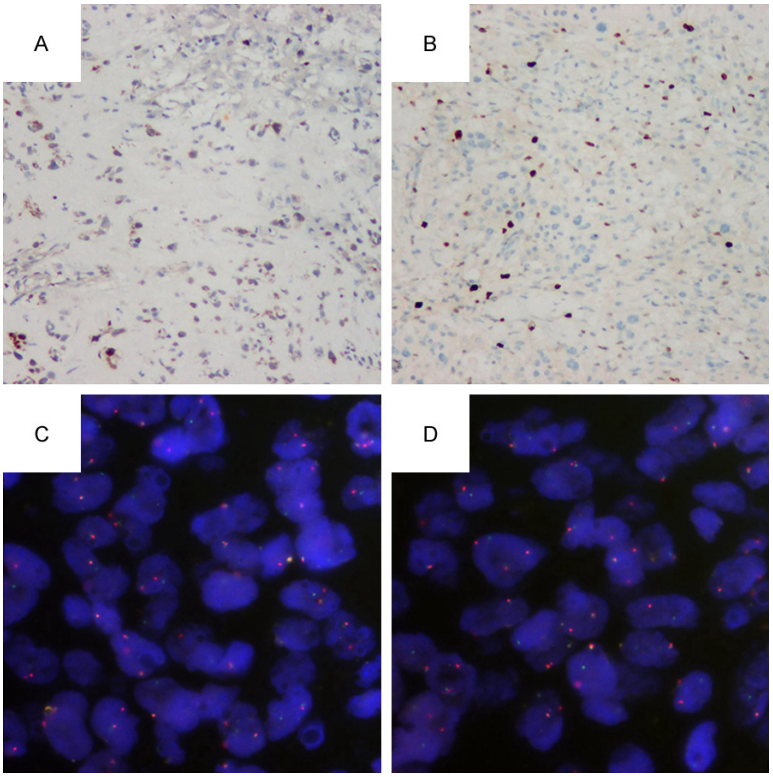

Figure 2. Immunohistochemical and FISH results of this case. A. Tumor cells exhibit NSE positivity, DABX100. B. Dispersible Ki-67 positive, DABX100. C and D. Fluorescent *in situ* hybridization showing EWSR1 rearrangement in the form of red-green split signals. Inset showing red-green split signal with a single red-green fused signal, DAPIX1000.

slightly higher density separation enhanced after scanning separation was significantly enhanced. The outer edge of the bone was still clear, with no periosteal reaction and soft tissue mass. Considering the right side of the middle of the primary tumor of the radius, the possibility of giant cell tumor of bone and other bone tumors were excluded (**Figure 3C**). Magnetic resonance imaging showed bone expansion in the proximal and distal segments of the right radius. The size of the tumor was about 6.8 * 4.9 * 3.7 cm. Corresponding cortical bone became thinner and uneven in thickness. It contained a long T1 long T2 signal. Separated was uneven sheet-like enhancement, considered to be a possible low-grade malignant lesion (**Figure 3D**).

Molecular findings

FISH test of the EWSR1 fusion gene was performed. Molecular pathology showed that EWSR1-positive signals were seen in the tumor nuclei: one yellow fusion signal, one red signal, one green signal, or a separate red signal or a separate green signal appeared, suggesting that the case involved EWSR1 gene translocation (**Figure 2A** and **2B**).

Treatment and follow-up

The patient underwent surgical resection and reconstruction. The specific approach was to remove the right radius of the tumor after the whole block. They took the spare left fibula bone defect filling, after the plate with a fixed end. They did not use radiotherapy and chemotherapy. At present, the patient has been followed for 10 months, with no recurrence or metastatic lesions.

Discussion

Myxoid chondrosarcoma is a rare but a unique morphological malignancy, including two types of extraneous and intraosseous myxoid chondrosarcoma [4]. For the former, studies have been reported both at home and abroad, indicating that it can occur in soft tissue, lung, breast, and even the liver. For the latter, domestic and foreign literature is rare. There are no relevant studies on intraosseous myxoid chondrosarcoma. The pathology textbooks of Chinese and foreign only describe myxoid chondrosarcoma as a type of chondrosarcoma. However, in recent years, research has been more inclined to use myxoid chondrosarcoma as a single pathological type. Because of its many pathological features and molecular mechanisms, further study is required. The WHO (2013 edition) latest revision of soft tissue and bone tumor classification is divided into a class of tumors with uncertain differentiation [5]. This study found and reported on this extremely rare case of intraosseous myxoid chondrosarcoma, aiming to raise awareness and improve diagnosis of this disease.

Moreover, experts already described a similar myxoid chondrosarcoma a long time ago [6-8].

Figure 3. Plain radiograph showing a lumps lesion located in the radius (A). SPECT/PET-ECT examination shows that the right radial median bulge can be seen radioactive defect and enrichment focus (B). CT scans showed that the proximal radius of the right radius of the bone expansion, the tumor is located in the bone, no periosteal reaction and soft tissue mass (C). Magnetic resonance imaging shows bone expansion in the proximal and distal segments of the right radius. It contained a long T1 long T2 signal (D).

Enzinger et al. reported on extra-skeletal myxoid chondrosarcomas and named them [9]. They indicated that pathological examinations, combined with X-ray, CT, and MRI examinations, are necessary to diagnose the source of tumors. Additionally, reports on myxoid chondrosarcoma mostly focus on the description of extra-skeletal myxoid chondrosarcoma. According to a series of related reports, there is evidence of extra-skeletal myxoid chondrosarcoma involving bone invasion, which is also rare. In the largest series of EMC reports, Meis et al. [10] reported no cases of skeletal involvement. The majority of cases were from the Soft Branch Registry of the Armed Forces Pathology Institute, not including incintraosseous bone tumors. Myxoid chondrosarcomas in bone account for less than 3%, according to the literature of most research institutions [11].

Pathological findings

In general, this case saw the tumor destructive to the radial body and the formation of a cyst. No normal radial structure was seen, the tumor was polygonal, lobulated or lobulated section nodular, yellow jellylike, solid, quality, and local mucus-like transparent. These may be associated with significant bleeding necrosis. The tumor on the destruction of the original bone structure infiltration was obvious in the histology. The tumor was divided into fibrous globular, while lobular tumor cells were round or short fusiform, distributed in the mucus-like matrix. Myxoid chondrosarcoma can be divided into the type of classic, cell type, solid, and non-mucus, of which 29% are rich in cell type of tumors [12]. This case of tumor tissue turned into invasive growth. The dense arrangement of tumor cells was solid, but the tumor cells were rich, arraeosinophilice, medium-sized tumor cells, cytorhabdomyosarcoidnophilic, spindle-shaped, epithelial, and rhabdomyosarcoid nuclei round deep stained.

According to immunohistochemistry, the tumor cells were positive for Vimentin and epithelial markers were generally negative. According to the literature, the positive rate of S-100 protein is about 20%, but expression is generally focal or weakly positive [13]. Some tumors express neuroendocrine markers (CD56, NSE), but CgA was generally negative. The tumor cells did not express smooth muscle and striated muscle markers (myosin, calponin, H-caldesmon, Desmin, myoD1), but expressed the neuroendocrine marker NSE, which suggests neuroendocrine differentiation.

Genetics and molecular pathology analysis revealed that approximately 75% of bone myxoid chondrosarcomas have a relatively specific chromosomal translocation (9;22)(q22;q12) and produce NR4A3 (encoding CHN and TEC or NOR1 proteins, located at 9q22) and EWSR1 (located at 22q12) fusion genes [4, 13, 14]. In addition, a small fraction of extra-skeletal myxoid chondrosarcomas with the chromosomal t(9;17)(q22;q11.2) translocation, involve the

RBP: 56 gene on 17qll and NR4A3. This is thought to be associated with neuroendocrine differentiation. In this case, the results of detection by FISH were also in agreement with those reported in the literature. The EWSR1 separation probe was used to generate gene-breakage translocation and the red-green signal point was broken by the yellow signal.

Imaging performance

Imaging findings of this case were atypical. There was no periosteal reaction, no obvious surrounding soft tissue swelling, and slow growth. X-ray examinations showed no periosteal reaction and a soft tissue mass, suggesting that the tumor lesions located were in the bone, but a giant cell tumor of bone was very likely. CT scanning and magnetic resonance imaging considered the possibility of low-grade malignancy. Radiologists first considered a giant cell tumor of the bone. Imaging analysis is difficult to come to the conclusion of malignant tumors, especially if it is not obvious soft tissue with a mass shadow around the tumor [12, 15, 16]. In this case, myxoid chondrosarcoma in bone should be a low-grade soft tissue tumor, relative to osteosarcoma and chondrosarcoma, only from the imaging experience. No evidence of malignancy was found elsewhere in the patient's bone. Only in the middle of the right radial bone was found a bone mass, with no periosteal reaction and soft tissue mass around the shadow. Therefore, it was diagnosed as a primary bone tumor.

Treatment and prognosis

Most myxoid chondrosarcomas have slow clinical development and a long history. WHO (2013) classification of soft tissue tumors has classified extra-skeletal myxoid chondrosarcoma as an undetermined differentiated type of moderate to severe, malignant soft tissue tumor, with local recurrence rates and metastasis rates of 37% to 48%. A total of 87 cases of extra-skeletal myxoid chondrosarcoma were studied by Drilon et al. [17]. Local re%, respectively, and distant metastasis rates were 37% and 13% respectively. Survival rates at 5, 10 and 15 years were 82%, 65% and 58%. According to the literature, in general, with larger tumor diameter, tumor recurrence, and metastasis there are more mitosis, Ki-67 index is higher, etc. These are indications for a poor prognosis of the tumor [18]. The follow-up office followed up the patient for 10 months, with no recurrence or metastasis observed. This may be due to the fact that the follow-up period was not long enough. With myxoid chondrosarcoma in the bone, radiotherapy and chemotherapy are not effective. The most effective treatment is surgical resection or amputation, currently. Recent studies have reported that anthracycline on postoperative adjuvant chemotherapy has some positive effects [16, 19].

Intraosseous myxoid chondrosarcoma is not specific in histopathology. It requires attention from extra-skeletal myxoid chondrosarcoma, soft tissue mixed tumor/myoepithelioma/myoepithelial carcinoma, chordoma, myxoid liposarcoma, periosteal chondrosarcoma, cartilage mucoid fibroma, and other tumors for differential diagnosis. (1) Extra-skeletal myxoid chondrosarcoma: It is a sarcoma that occurs in extra-soft tissue of the bone and the true source of differentiation is indeterminate. Intraosseous myxoid chondrosarcoma clearly occurs in the bone tissue via imaging. There is cartilage or bone tissue visible under the microscope, whereas extra-skeletal myxoid chondrosarcoma does not have these components. (2) Myoepithelioma has a histologically diagnostic challenge, but the intraosseous and extra-skeletal myxoid chondrosarcomas are usually distinguished by a stronger or more diffuse expression of keratin and EMA [20]. Since the morphology of these two entities characteristics is similar and there is EWSR1 gene rearrangement in both tumors, the most difficult differential diagnosis is between myxoid chondrosarcoma and myoepithelioma. Immunohistochemistry is helpful in this differential diagnosis: Expression of cytokeratin AE1/AE3 or EMA associated with S100 or GFAP positivity is a unique marker for diagnosis of myoepithelioma [21]. (3) Chordoma: this tumor has a cartilage-like mucus-like the tumor cell cytoplasmlogy, showing eosinophilic-like cells, tumor cell cytoplasm is richlobulatednophilic, tumor cells arrange cord-like or lobulated and show CK and EMA positive expression. Brachyury is the latest antibody used to diagnose chordoma, most of which are positive. (4) Myxoid liposarcoma: its pathological features are visible morphological and quantitative fat cells. The background is rich in mixed matrix and immunohistochemical S-100 protein staining is positive, with 90% of the cases existing with DDIT3 (CHOP) gene

translocation, which forms the CHOP-FUS fusion gene with the FUS gene [22]. (5) Periosteal chondrosarcoma: imaging studies suggest that the tumor occurs in the periosteum. Histologically, you can see chondrocyte neoplastic hyperplasia and the tumor often shows invasive growth. (6) Cartilage myxoid fibroma: it is the primary bone of benign cartilage tumors, which are rich in mucus, but tumor cells are spindle or mantle and atopy is not obvious, but showing visible hyaline cartilage, focal ossification, and calcification.

In conclusion, intraosseous myxoid chondrosarcoma is an extremely rare tumor with unique morphological manifestations. Based on limited data, imaging findings are not typical and specific. It is difficult to distinguish between benign and malignant, thus pathological examinations are necessary. Imaging examinations for the determination of the extent, location of the lesion, assessment of postoperative efficacy, and determination of recurrence and metastasis are also very necessary. The best treatment for intraosseous myxoid chondrosarcoma is surgical resection. The present study suggests that the combination of imaging and pathological examinations, along with the use of molecular diagnostic techniques to detect its characteristic translocation, are necessary to achieve a clear diagnosis.

Acknowledgements

This work was supported by grants from the Bureau of Public Health of Guangxi Province of China (Z2015624, Z2016502) and the Graduate Course Construction Project of Guangxi Medical University (YJSA2017014).

Disclosure of conflict of interest

None.

Address correspondence to: Jun Chen, Department of Pathology, Affiliated Tumor Hospital of Guangxi Medical University, 71 Hedi Road, Nanning 530021, P. R. China. Tel: +86-7715332699; E-mail: chenjun2826@163.com

References

[1] Morioka H, Takahashi S, Araki N, Sugiura H, Ueda T, Takahashi M, Yonemoto T, Hiraga H, Hiruma T, Kunisada T, Matsumine A, Susa M, Nakayama R, Nishimoto K, Kikuta K, Horiuchi K, Kawai A. Results of sub-analysis of a phase 2 study on trabectedin treatment for extraskeletal myxoid chondrosarcoma and mesenchymal chondrosarcoma. BMC Cancer 2016; 16: 479.

[2] Broehm CJ, Wu J, Gullapalli RR, Bocklage T. Extraskeletal myxoid chondrosarcoma with a t(9;16)(q22;p11.2) resulting in a NR4A3-FUS fusion. Cancer Genet 2014; 207: 276-280.

[3] Agaram NP, Zhang L, Sung YS, Singer S, Antonescu CR. Extraskeletal myxoid chondrosarcoma with non-EWSR1-NR4A3 variant fusions correlate with rhabdoid phenotype and high-grade morphology. Hum Pathol 2014; 45: 1084-1091.

[4] Springfeld R, Fritsch J, Möbius G, Wiedersberg H. Extra-skeletal myxoid chondrosarcoma of the popliteal fossa. Beitr Orthop Traumatol 1990; 37: 182-186.

[5] Davis EJ, Wu YM, Robinson D, Schuetze SM, Baker LH, Athanikar J, Cao X, Kunju LP, Chinnaiyan AM, Chugh R. Next generation sequencing of extraskeletal myxoid chondrosarcoma. Oncotarget 2017; 8: 21770-21777.

[6] Stout AP, Verner EW. Chondrosarcoma of the extraskeletal soft tissues. Cancer 1953; 6: 581-590.

[7] Goldenberg RR, Cohen P, Steinlauf P. Chondrosarcoma of the extraskeletal soft tissues. A report of seven cases and review of the literature. J Bone Joint Surg Am 1967; 49: 1487-1507.

[8] Mehio AR, Ferenczy A. Extraskeletal myxoid chondrosarcoma with “chordoid” features (chordoid sarcoma). Am J Clin Pathol 1978; 70: 700-705.

[9] Enzinger FM, Shiraki M. Extraskeletal myxoid chondrosarcoma. An analysis of 34 cases. Hum Pathol 1972; 3: 421-435.

[10] Meis-Kindblom JM, Bergh P, Gunterberg B, Kindblom LG. Extraskeletal myxoid chondrosarcoma: a reappraisal of its morphologic spectrum and prognostic factors based on 117 cases. Am J Surg Pathol 1999; 23: 636-650.

[11] Finos L, Righi A, Frisoni T, Gambarotti M, Ghinelli C, Benini S, Vanel D, Picci P. Primary extraskeletal myxoid chondrosarcoma of bone: Report of three cases and review of the literature. Pathol Res Pract 2017; 213: 461-466.

[12] Demicco EG, Wang WL, Madewell JE, Huang D, Bui MM, Bridge JA, Meis JM. Osseous myxochondroid sarcoma: a detailed study of 5 cases of extraskeletal myxoid chondrosarcoma of the bone. Am J Surg Pathol 2013; 37: 752-762.

[13] Stacchiotti S, Pantaleo MA, Astolfi A, Dagrada GP, Negri T, Dei Tos AP, Indio V, Morosi C, Gronchi A, Colombo C, Conca E, Toffolatti L, Tazzari M, Crippa F, Maestro R, Pilotti S, Casali PG. Ac-

tivity of sunitinib in extraskeletal myxoid chondrosarcoma. Eur J Cancer 2014; 50: 1657-1664.

[14] Urbini M, Astolfi A, Pantaleo MA, Serravalle S, Dei Tos AP, Picci P, Indio V, Sbaraglia M, Benini S, Righi A, Gambarotti M, Gronchi A, Colombo C, Dagrada GP, Pilotti S, Maestro R, Polano M, Saponara M, Tarantino G, Pession A, Biasco G, Casali PG, Stacchiotti S. HSPA8 as a novel fusion partner of NR4A3 in extraskeletal myxoid chondrosarcoma. Genes Chromosomes Cancer 2017; 56: 582-586.

[15] Kemmerer EJ, Gleeson E, Poli J, Ownbey RT, Brady LW, Bowne WB. Benefit of radiotherapy in extraskeletal myxoid chondrosarcoma: a propensity score weighted population-based analysis of the SEER database. Am J Clin Oncol 2018; 41: 674-680.

[16] Shao R, Lao IW, Wang L, Yu L, Wang J, Fan Q. Clinicopathologic and radiologic features of extraskeletal myxoid chondrosarcoma: a retrospective study of 40 Chinese cases with literature review. Ann Diagn Pathol 2016; 23: 14-20.

[17] Drilon AD, Popat S, Bhuchar G, D'Adamo DR, Keohan ML, Fisher C, Antonescu CR, Singer S, Brennan MF, Judson I, Maki RG. Extraskeletal myxoid chondrosarcoma: a retrospective review from 2 referral centers emphasizing long-term outcomes with surgery and chemotherapy. Cancer 2008; 113: 3364-3371.

[18] Ogura K, Fujiwara T, Beppu Y, Chuman H, Yoshida A, Kawano H, Kawai A. Extraskeletal myxoid chondrosarcoma: a review of 23 patients treated at a single referral center with long-term follow-up. Arch Orthop Trauma Surg 2012; 132: 1379-1386.

[19] Kapoor N, Shinagare AB, Jagannathan JP, Shah SH, Krajewski KM, Hornick JL, Ramaiya NH. Clinical and radiologic features of extraskeletal myxoid chondrosarcoma including initial presentation, local recurrence, and metastases. Radiol Oncol 2014; 48: 235-242.

[20] Nambirajan A, Mridha AR, Sharma MC, Panda A, Palaniswamy A. Primary intra-osseous myoepithelioma of phalanx mimicking an enchondroma. Skeletal Radiol 2016; 45: 1453-1458.

[21] Urbini M, Astolfi A, Indio V, Tarantino G, Serravalle S, Saponara M, Nannini M, Gronchi A, Fiore M, Maestro R, Brenca M, Dei Tos AP, Dagrada GP, Negri T, Pilotti S, Casali PG, Biasco G, Pession A, Stacchiotti S, Pantaleo MA. Identification of SRF-E2F1 fusion transcript in EWSR-negative myoepithelioma of the soft tissue. Oncotarget 2017; 8: 60036-60045.

[22] Fritchie KJ, Goldblum JR, Tubbs RR, Sun Y, Carver P, Billings SD, Rubin BP. The expanded histologic spectrum of myxoid liposarcoma with an emphasis on newly described patterns: implications for diagnosis on small biopsy specimens. Am J Clin Pathol 2012; 137: 229-239.