

## Original Article

# Effect of video-assisted thoracoscopic surgery on immune function and trauma in patients with non-small cell lung cancer

Le Han\*, Hao Cheng\*, Jia Liu\*, Wei Gao, Hua Wang, Haiyan Xie, Xinwei Zhang, Yangrong Song

*Department of Thoracic Surgery, Shaanxi Provincial Tumor Hospital, Xi'an Jiaotong University, Xi'an, Shaanxi Province, P. R. China. \*Equal contributors and co-first authors.*

Received April 16, 2018; Accepted May 28, 2018; Epub November 15, 2018; Published November 30, 2018

**Abstract:** Objective: to explore the effect of minimally invasive video-assisted thoracoscopic surgery (VATS) on immune function and trauma in patients with non-small cell lung cancer (NSCLC). Methods: One hundred and fifty-eight patients with NSCLC presented to Shaanxi Provincial Tumor Hospital between January 2016 and October 2017 were recruited as participants in this study. The patients were randomly classified into the observation group (n=83) and the control group (n=75). The patients in the observation group underwent minimally invasive VATS whereas those in the control group received conventional thoracotomy. The patients in the two groups were compared in operation time, the number of dissected mediastinal lymph nodes, intraoperative blood loss, duration of catheter drainage, hospital stay, time to ambulation, the rates of postoperative complications, as well as the levels of serum C-reactive protein (CRP), interleukin-6 (IL-6), tumor necrosis factor- $\alpha$  (TNF- $\alpha$ ) and serum amyloid A (SAA) expression, and the levels of immune cells. Results: No significant disparities were found in the operation time and the number of dissected mediastinal lymph nodes between the two groups (both  $P>0.05$ ). Nevertheless, less intraoperative blood loss ( $P<0.05$ ), shorter catheter drainage duration, hospital stay, and time to ambulation, as well as a lower rate of postoperative complications were noted in the observation group than in the control group (all  $P<0.001$ ). Insignificant variations were observed in the levels of preoperative inflammatory cytokines and immune cells between the two groups (all  $P>0.05$ ). Three days after surgery, CRP, IL-6, TNF- $\alpha$ , and SAA expression in the observation group were remarkably lower than those in the control group (all  $P<0.001$ ). Total blood lymphocyte count and the percentages of CD4<sup>+</sup>, CD8<sup>+</sup>, and natural killer (NK) T-cells in the observations were higher than those in the control group (all  $P<0.001$ ). Conclusion: Minimally invasive VATS is superior to conventional thoracotomy in reducing the degree of trauma and suppression of immune functions in patients with NSCLCs. Hence, it is worthy of clinically extensive use.

**Keywords:** Non-small cell lung cancer, minimally invasive video-assisted thoracoscopic surgery, conventional thoracotomy, immune function, trauma

## Introduction

Lung cancer (LC) is one of the most severe malignancies which pose a threat to human health. The prevalence of LC is increasing on a yearly basis, and approximately 80% of lung cancers are non-small cell lung cancers (NSCLC) [1, 2]. To date, surgery is considered as the most direct and effective technique for the treatment of NSCLCs at the early and intermediate stages [3]. However, surgery may cause trauma to patients. Surgical trauma has shown to give rise to acute phase reactions, exacerbate the release of pro-inflammatory

cytokines and the cytokines that inhibit cellular immune function, thereby suppressing the immune function of the body [4, 5]. For NSCLC patients, surgical trauma inhibits their immune function, which may attenuate the anti-tumor effect, and results in higher risks for local recurrence and distant metastasis of tumor [6, 7]. Therefore, the goal of thoracic surgeons developing new surgical modalities is to minimize the degree of surgical trauma while ensuring favorable therapeutic effects.

Under normal circumstances, conventional thoracotomy for NSCLC is associated with adverse

**Table 1.** Characteristics of patients at baseline

Characteristic	Control group (n=75)	Observation group (n=83)	t/χ <sup>2</sup>	P
Age (year)	62.35±4.78	61.42±5.02	0.425	0.572
Male/Female (n)	52/23	58/25	0.006	0.941
BMI	24.21±0.45	23.93±0.42	0.417	0.678
PT (n, %)			0.043	0.979
Adenocarcinoma	41 (54.67)	45 (54.22)		
SC	24 (32.00)	26 (31.33)		
AC	10 (13.33)	12 (14.45)		
TD (cm)	3.25±1.14	3.19±1.27	0.124	0.859
PS (n, %)			0.003	0.957
I	50 (66.67)	55 (66.27)		
II	25 (33.33)	28 (33.73)		
TS (n, %)			0.330	0.988
RUL	19 (25.33)	19 (22.89)		
RML	13 (18.06)	16 (19.28)		
RLL	15 (20.00)	15 (18.07)		
LUL	14 (18.67)	17 (20.48)		
LLL	14 (18.67)	16 (19.28)		
SM	47 (62.67)	53 (63.86)	0.005	0.945

Note: BMI denotes body mass index; PT, pathologic type; SC, squamous carcinoma; AC, adenocarcinoma; TD, tumor diameter; PS, pathologic staging; TS tumor site; RUL, right upper lobe; RML, right middle lobe; RLL, right lower lobe; LUL, left upper lobe; LLL, left lower lobe; SM, smoking history.

**Table 2.** Intraoperative indicators of patients

Variable	Case	Operative time (min)	No. of dissected mediastinal lymph nodes	Intraoperative blood loss (mL)
Control group	75	132.47±15.36	11.23±2.17	261.47±55.36
Observation group	83	139.86±18.45	10.86±2.35	143.25±42.34
t/χ <sup>2</sup>		1.085	0.262	12.962
P		0.102	0.754	<0.001

events of long postoperative pain, much blood loss, and severe trauma [8, 9]. With advances in minimally invasive techniques, video-assisted thoracoscopic surgery (VATS) is increasingly favored by thoracic surgeons in the clinical setting, and its effectiveness, safety, and minimal invasiveness have been confirmed by evidence-based medicine [10, 11]. For patients with NSCLCs at early and intermediate stages, minimally invasive VATS is better than conventional thoracotomy in the rates of 5-year survival, local recurrence, and distant metastasis [12]. Currently, relevant research has been focused on validating that VATS is more minimally invasive than conventional thoracotomy by comparing the clinical data of surgical incision size,

intraoperative blood loss, and complications [13, 14]. Nevertheless, microcosmic differences in the immune function and inflammation between the two surgical techniques are rarely reported. Therefore, in the current study, we compared the NSCLC patients with minimally invasive VATS and those with conventional thoracotomy in the preoperative and postoperative indicators (the levels of inflammatory cytokines, immune functions, and trauma), as well as their clinical data, with an aim to develop a safer and more effective modality for the management of NSCLC patients.

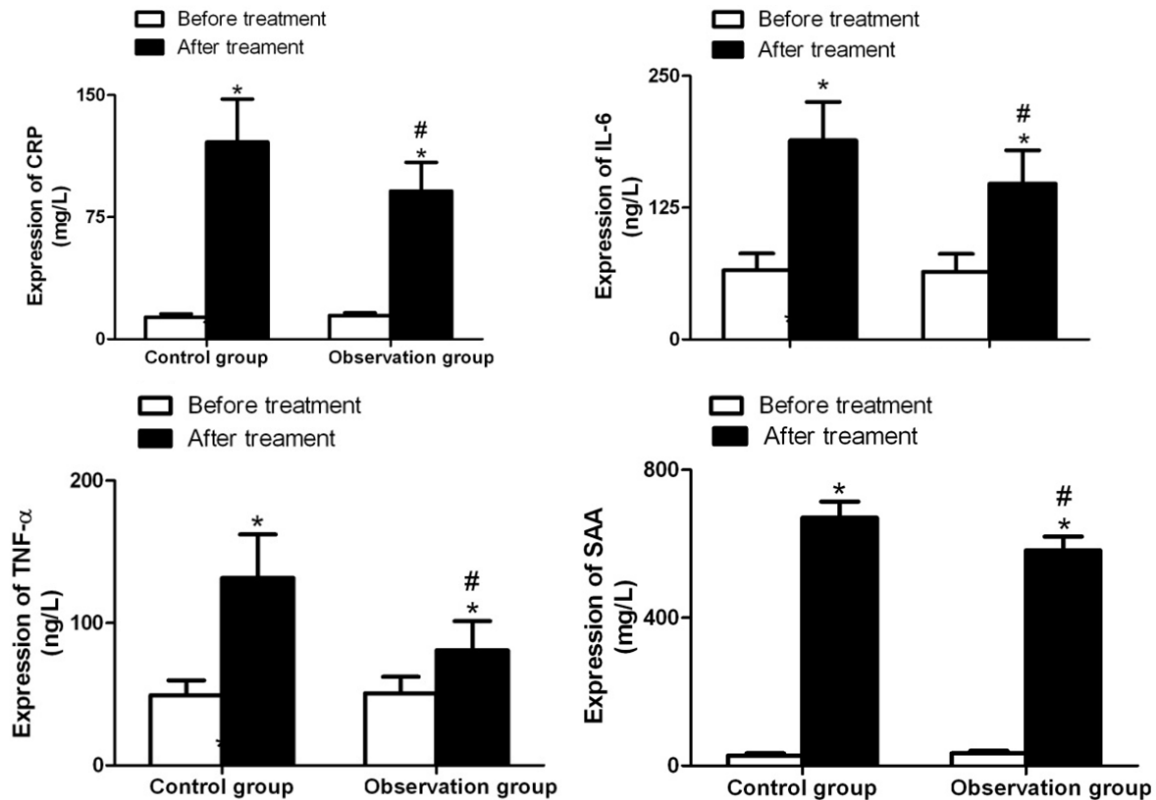
**Materials and methods**

*Patients*

From January 2016 to October 2017, 158 patients with NSCLC admitted to Shaanxi Provincial Tumor Hospital who underwent surgical treatment were recruited in this study and randomly assigned to receive either minimally invasive VATS (observation group, n=83) or conventional thoracotomy (control group, n=75). Inclusion criteria were patients that varied in age from 18 to 75 years old; patients that were pathologically diagnosed as having NSCLCs; the tumor being than 5 cm in diameter; CT enhancement scanning and other imaging studies showing no significant enlargement of mediastinal and hilar lymph nodes; patients having had no surgical contraindications. Exclusion criteria were patients having had distant metastases; patients having had severe hepatic and renal dysfunction; patients having had a 50% excess of pleural adhesions and cancer cells that also involved the chest wall; patients having had a history of previous ipsilateral thoracotomy; patients having had converted to thoracotomy after a failure of minimally

**Table 3.** Postoperative indicators of patients

Variable	Case	Catheter drainage duration (d)	Length of hospital stay (d)	Time to ambulation (d)	Postoperative complications (n, %)
Control group	75	5.16±0.49	12.23±3.17	3.05±0.78	18 (24.00)
Observation group	83	3.45±0.36	9.52±2.42	1.58±0.64	10 (12.05)
t/χ <sup>2</sup>		12.617	14.452	11.761	4.193
P		<0.001	<0.001	<0.001	0.041



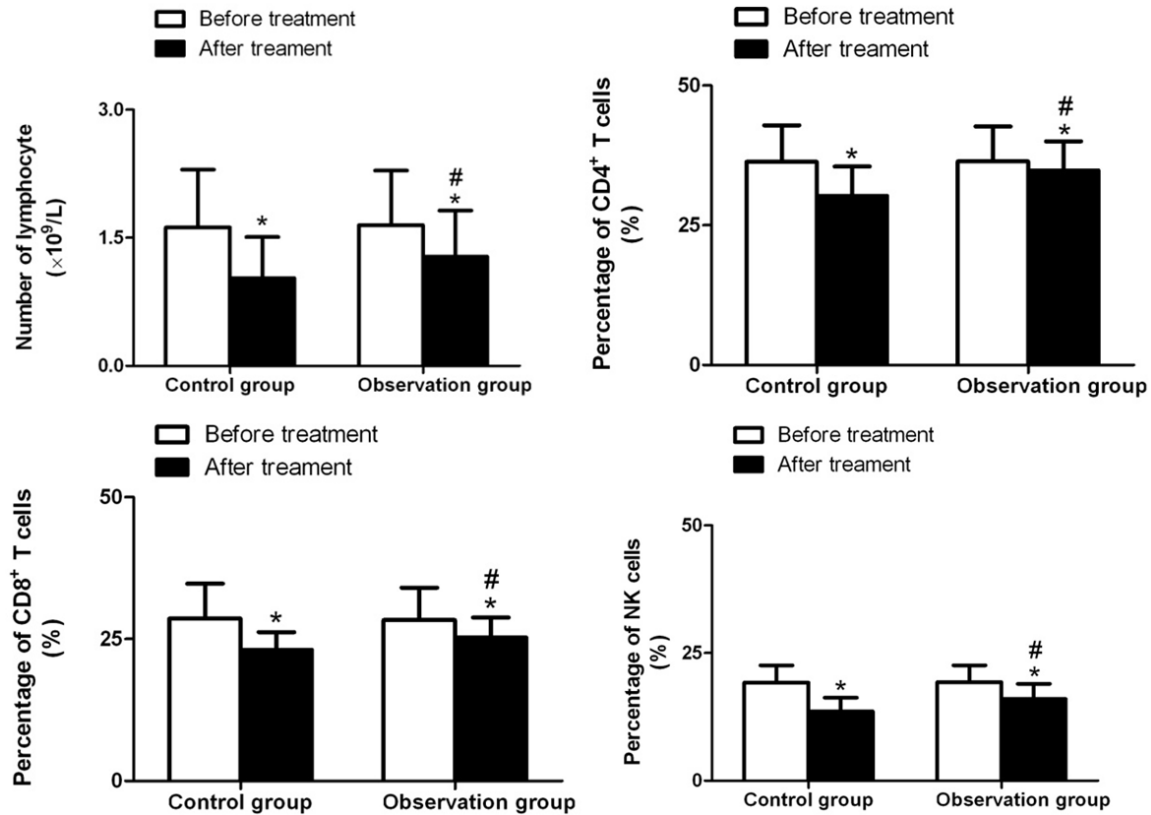
**Figure 1.** Comparison of expression of CRP, IL-6, TNF-α, and SAA of patients in the control group and the observation group. \*P<0.001, compared within the same group before surgery; #P<0.001, compared with the control group at the same time points. CRP denotes C-reactive protein; IL-6, interleukin-6; TNF-α, tumor necrosis factor-α; SAA serum amyloid A.

invasive VATS; patients with prior immune system disease; patients having received prior chemotherapy, radiotherapy, and other targeted therapies before enrollment. This study was approved by the Medical Ethics Committee of Shaanxi Provincial Tumor Hospital, and all the enrolled patients submitted written informed consent.

*Surgical procedures*

Under general anesthesia, patients in both groups underwent surgery with double-lumen endotracheal intubation. The patients were

placed in contralateral position and ventilated at contralateral lung. Each patient in the observation group underwent minimally invasive VATS. In the observation group, minimally invasive thoracotomy was performed through the main operation hole at a 4.0-cm incision in the fifth or fourth axillary frontline, the auxiliary operation hole at a 2.0-cm incision in the seventh intercostal subscapular line, and the observation hole at a 1.5-cm incision in the seventh intercostal midaxillary centerline. The incisional skin and subcutaneous tissue in the main operation hole were pulled with the mas-



**Figure 2.** Comparison of total blood lymphocyte count, the percentages of CD4<sup>+</sup>, CD8<sup>+</sup>, and NK T-cells between the control group and the observation group. \*P<0.001, compared within the same group before surgery; #P<0.001, compared with the control group at the same time points.

toid retractor to facilitate the operation of the instrument and complete the operation. A soft rubber was used to protect the incision, instead of a rib spreader to support the rib. After the tumor location had been determined under a thoracoscope, lobectomy and lymphadenectomy were performed. Patients in the control group were treated with conventional thoracotomy with the fourth intercostal posterolateral incision as the surgical approach. The latissimus dorsi, serratus anterior and intercostal muscles were dissected. The ribs were spread with a rib spreader, and the rib at the lower border of the incision was cut if necessary. The patient's diseased lobes were removed, and conventional lymphadenectomy was performed. The intraoperative bronchia and blood vessels of patients in the two groups were sutured directly or with a stapler. The lungs were then conventionally inflated and exhausted, and indwelled with drainage tubes, and finally the thoracic cavity was closed layer by layer. Routine anti-infective treatment was given to all patients after surgery.

#### Outcome measures

Primary outcomes included intraoperative indicators and the results of postoperative cellular immunity assays. Secondary outcomes comprised postoperative measures, as well as serum C-reactive protein (CRP), interleukin-6 (IL-6), tumor necrosis factor- $\alpha$  (TNF- $\alpha$ ), and serum amyloid A (SAA) levels.

The patients in the two groups were compared regarding the intraoperative indicators (including operation time, the number of dissected mediastinal lymph nodes, and intraoperative blood loss), postoperative indicators (including catheter drainage duration, hospital stay, time to ambulation and the rates of postoperative complications).

Serum CRP, IL-6, TNF- $\alpha$ , and SAA levels of all patients were measured as follows: 3 mL of fasting peripheral venous blood was extracted from each patient before surgery and 3 days after surgery, placed in an anticoagulant tube, centrifuged at 3000 r/min for 10 minutes. The

## Video-assisted thoracoscopic surgery for immune function and trauma in patients

serum was separated and the samples were stored at  $-20^{\circ}\text{C}$ . The serum CRP, IL-6, TNF- $\alpha$ , and SAA levels were detected by an enzyme-linked immunosorbent assay (ELISA) using the CRP, IL-6, TNF- $\alpha$ , and SAA kits (R&D science, USA). The above experimental procedures were performed strictly following the instructions on the kits.

Assays of cellular immunity were conducted as follows: the levels of CD4<sup>+</sup>, CD8<sup>+</sup>, and natural killer (NK) T-cells of all patients were detected using a Beckmann Quanta SC flow cytometer (USA) before surgery and 3 days after surgery. The number of lymphocytes in both groups was measured using an automated hematology analyzer.

### Statistical analysis

All data in this study were processed with the use of the SPSS software, version 18.0. Measurement data are presented as mean  $\pm$  sd; between-group comparisons at the same time points were conducted by the independent samples t-test, whereas intra-group comparisons at different time points were made by the paired t-test. Count data were described as rates, and the Chi-square test was utilized for between-group comparisons. A *P* value less than 0.05 was deemed significant for the difference between the data of the two groups.

## Results

### Patients

Patients in the two study groups were basically balanced in age, gender, body mass index (BMI), pathologic type, tumor diameter, pathologic staging, tumor sites, and smoking (all  $P > 0.05$ ), so they were comparable, as shown in **Table 1**.

### Intraoperative parameters of patients

The operation time and the number of dissected mediastinal lymph nodes varied insignificantly between the two groups (both  $P > 0.05$ ). The intraoperative blood loss of the observation group was remarkably less than that of the control group ( $P < 0.05$ ; **Table 2**).

### Postoperative indicators of patients

The duration of catheter drainage, length of hospital stay, time to ambulation and the rates of postoperative complications in the observa-

tion group were markedly lower than those in the control group ( $P < 0.05$ ; **Table 3**).

### CRP, IL-6, TNF- $\alpha$ and SAA expression of patients

There were insignificant disparities in the CRP, IL-6, TNF- $\alpha$ , and SAA expression between the two groups before surgery (all  $P > 0.05$ ). Three days after surgery, higher serum CRP, IL-6, TNF- $\alpha$ , and SAA levels were observed in the two groups after surgery than before surgery (all  $P < 0.001$ ), and the levels in the observation group were substantially lower than those in the control group (all  $P < 0.001$ ; **Figure 1**).

### Immune cell levels of patients

The preoperative total blood lymphocyte counts, the percentages of CD4<sup>+</sup> T, CD8<sup>+</sup> T, and NK cells varied insignificantly between the two groups (all  $P > 0.05$ ). Nevertheless, 3 days after surgery, the percentages of CD4<sup>+</sup>, CD8<sup>+</sup>, and NK T-cells were markedly lower than those before surgery in both groups (all  $P < 0.05$ ). Total blood lymphocyte count, the percentages of CD4<sup>+</sup> T cells, CD8<sup>+</sup> T cells, and NK cells in the observation group were remarkably higher than those in the control group (all  $P < 0.001$ ; **Figure 2**).

## Discussion

NSCLC is a clinically common malignant tumor. Conventional lobectomy has been the primary modality for surgical treatment of NSCLC patients. In recent years, VATS has become the treatment of choice for NSCLC patients. VATS is advantageous over conventional thoracotomy in less trauma, fewer impacts on cardiopulmonary function, less pain, and faster postoperative recovery [15]. Hence, it has attracted increasing attention from clinical scholars. However, few prospective randomized controlled studies have been focused on the effects of minimally invasive VATS and conventional thoracotomy on trauma indexes, inflammatory cytokines, and immune function in patients with NSCLCs. In our current study, the two groups differed insignificantly in baseline characteristics (age, gender, pathologic type, tumor diameter, pathologic staging, and tumor sites) (all  $P > 0.05$ ), suggesting that the effect of the surgery-unrelated factors on the study outcomes were ruled out, and a more objective assessment was made regarding the effects of the surgical techniques on the NSCLC patients.

Studies indicate that minimally invasive VATS is associated with stress response and suppressed immune function at various degrees, and closely related to the degree of surgical trauma in NSCLC patients [16]. For patients with cancers, suppression of immune function is associated with postoperative prognosis of patients. The operation time, intraoperative blood loss, the number of dissected mediastinal lymph nodes, and postoperative complication rates are considered as important markers reflecting the degree of surgical trauma. Catheter drainage duration, length of hospital stay, and time to ambulation are regarded as crucial markers for postoperative recovery. The before-mentioned markers are related to the degree of surgical trauma. The results of this study indicate insignificant disparities in the operation time and the number of dissected mediastinal lymph nodes between the two groups, but the patients in the observation group had less intraoperative blood loss than those in the control group, as well as shorter time to ambulation, shorter catheter drainage duration and hospital stay (all  $P < 0.05$ ). The reason is that for minimally invasive VATS, it is not necessary to cut off the latissimus dorsi, serratus anterior and intercostal muscles, or to spread the ribs. Hence it has small damage to tissues and cells, and can protect muscle and nerves more effectively, reduce postoperative pain, and alleviate the fears of the patients. In this way, the patients can recover more quickly and ambulate earlier. Meanwhile, the magnified views of the thoracoscope allow subtle anatomy, complete hemostasis, and less blood loss during the surgery. Pulmonary infection, atelectasis, and arrhythmias are common complications of surgery, which are also related to the degree of surgical trauma [17]. In the current study, the rate of postoperative complications in the observation group was 12.05%, remarkably lower than 24.00% of the control group. This was attributed to the fact that minimally invasive VATS resulted in smaller injuries to the tissues in the chest wall and less postoperative pain in patients which helped the patients take deep breaths, do exercise and cough up sputum. Earlier ambulation was also beneficial to the recovery of pulmonary functions. Overall, the findings demonstrate that compared with conventional thoracotomy, VATS has a significant advantage of minimal inva-

sion, which is consistent with the results reported previously [18, 19].

Additionally, in the current study, the severity of trauma following VATS or conventional thoracotomy were evaluated from the perspective of the changes in the levels of inflammatory cytokines CRP, IL-6, TNF- $\alpha$ , and SAA in blood of patients. A study states that surgical trauma induces the production and response of cytokines, which primarily manifests as dramatically elevated levels of pro-inflammatory cytokines and cytokines that inhibit cellular immunity. The effects of surgical trauma on the cytokines vary greatly, with more severe surgical trauma presenting higher levels of cytokines [20]. Both CRP and SAA are acute phase proteins, and the levels of them rapidly enhance when there is trauma in the body. IL-6 and TNF- $\alpha$  both can act to regulate inflammation. Studies have indicated that the CRP, SAA, IL-6, and TNF- $\alpha$  levels are associated with surgical trauma, postoperative inflammation, and immune status [21, 22]. The result of our current study revealed higher serum CRP, IL-6, TNF- $\alpha$ , and SAA levels in the two groups after surgery than before surgery, suggesting that NSCLC patients are present with diverse degrees of postoperative trauma and acute phase response, and that serum CRP, IL-6, TNF- $\alpha$  and SAA levels in the observation group were considerably lower than those in the control group 3 days after surgery (all  $P < 0.05$ ). Altogether, these data indicate that patients with VATS have a milder acute phase response, and it is further confirmed that VATS is more minimally invasive.

Surgical trauma inhibits the immune function of patients with NSCLCs, which is associated with the cytotoxicity of inflammatory cytokines on lymphocytes [23]. The current study indicates that conventional thoracotomy induces a more significant inflammatory response in patients than minimally invasive VATS, so the immune function was inhibited more severely in patients with conventional thoracotomy than those with minimally invasive VATS. Moreover, in the current study, the total blood lymphocyte count, the percentages of CD4<sup>+</sup>, CD8<sup>+</sup>, and NK T-cells 3 days after surgery were markedly lower than those before surgery in both groups (all  $P < 0.05$ ), with greater improvements in the observation group than in the control groups (all  $P < 0.05$ ). Therefore, the minimally invasive

VATS has fewer impacts on the immune function of patients with NSCLCs, and the immune function is recovered more quickly, which is in line with the findings reported by Ng et al. [24].

In conclusion, minimally invasive VATS shows significant advantages over conventional thoracotomy in terms of reducing the degree of trauma and suppression of immune function in patients with NSCLCs. However, some limitations still exist in this study, for example, the differences in surgical techniques adopted by different surgeons which might affect the surgical results, there is lack of patient data on post-operative adjuvant therapy, and failure to evaluate the long-term effects of the two surgical modalities. Therefore, prospective randomized controlled trials with larger sample sizes and long-term follow-ups are required for further validating the advantages of minimally invasive VATS for NSCLC.

### Disclosure of conflict of interest

None.

**Address correspondence to:** Yangrong Song, Department of Thoracic Surgery, Shaanxi Provincial Tumor Hospital, Xi'an Jiaotong University, No. 309 Yanta West Road, Xi'an 710061, Shaanxi Province, P. R. China. Tel: +86-029-85276156; Fax: +86-029-85276156; E-mail: yangrongsongb8@163.com

### References

- [1] Barone M, Cipollone G and Mucilli F. Immune response after video-assisted thoracic surgery in non-small cell lung cancer patients. *J Vis Surg* 2018; 4: 25.
- [2] Wang LY, Cui JJ, Guo AX and Yin JY. Clinical efficacy and safety of afatinib in the treatment of non-small-cell lung cancer in Chinese patients. *Onco Targets Ther* 2018; 11: 529-538.
- [3] She XW, Gu YB, Xu C, Li C, Ding C, Chen J and Zhao J. Three-dimensional (3D)-computed tomography bronchography and angiography combined with 3D-video-assisted thoracic surgery (VATS) versus conventional 2D-VATS anatomic pulmonary segmentectomy for the treatment of non-small cell lung cancer. *Thorac Cancer* 2018; 9: 305-309.
- [4] Schneider T, Hoffmann H, Dienemann H, Herpel E, Heussel CP, Enk AH, Ring S and Mahnke K. Immune response after radiofrequency ablation and surgical resection in nonsmall cell lung cancer. *Semin Thorac Cardiovasc Surg* 2016; 28: 585-592.
- [5] Jones RO, Anderson NH, Murchison JT, Brittan M, Simon EJ, Casali G, Simpson AJ and Walker WS. Innate immune responses after resection for lung cancer via video-assisted thoracoscopic surgery and thoracotomy. *Innovations (Phila)* 2014; 9: 93-103.
- [6] Cata JP, Bauer M, Sokari T, Ramirez MF, Mason D, Plautz G and Kurz A. Effects of surgery, general anesthesia, and perioperative epidural analgesia on the immune function of patients with non-small cell lung cancer. *J Clin Anesth* 2013; 25: 255-262.
- [7] Yan X, Jiao SC, Zhang GQ, Guan Y and Wang JL. Tumor-associated immune factors are associated with recurrence and metastasis in non-small cell lung cancer. *Cancer Gene Ther* 2017; 24: 57-63.
- [8] Bendixen M, Jorgensen OD, Kronborg C, Andersen C and Licht PB. Postoperative pain and quality of life after lobectomy via video-assisted thoracoscopic surgery or anterolateral thoracotomy for early stage lung cancer: a randomised controlled trial. *Lancet Oncol* 2016; 17: 836-844.
- [9] Luo QQ, Lin H, Tan Q, Huang J and Xu L. Analysis of clinical application of thoracoscopic lobectomy for lung cancer. *World J Surg Oncol* 2014; 12: 157.
- [10] Vannucci F and Gonzalez-Rivas D. Is VATS lobectomy standard of care for operable non-small cell lung cancer? *Lung Cancer* 2016; 100: 114-119.
- [11] Whitson BA, Groth SS, Duval SJ, Swanson SJ and Maddaus MA. Surgery for early-stage non-small cell lung cancer: a systematic review of the video-assisted thoracoscopic surgery versus thoracotomy approaches to lobectomy. *Ann Thorac Surg* 2008; 86: 2008-2016.
- [12] Wang S, Sun T, Sun H, Li X, Li J, Zheng X, Mallampati S, Sun H, Zhou X, Zhou C, Zhang H, Cheng Z and Ma H. Survival improvement in patients with non-small cell lung cancer between 1983 and 2012: analysis of the surveillance, epidemiology, and end results database. *Tumour Biol* 2017; 39: 1010-428317691677.
- [13] Whitson BA, Andrade RS, Boettcher A, Bardales R, Kratzke RA, Dahlberg PS and Maddaus MA. Video-assisted thoracoscopic surgery is more favorable than thoracotomy for resection of clinical stage I non-small cell lung cancer. *Ann Thorac Surg* 2007; 83: 1965-1970.
- [14] Oh DS, Reddy RM, Gorrepati ML, Mehendale S and Reed MF. Robotic-assisted, video-assisted thoracoscopic and open lobectomy: propensity-matched analysis of recent premier data. *Ann Thorac Surg* 2017; 104: 1733-1740.

## Video-assisted thoracoscopic surgery for immune function and trauma in patients

- [15] Kim SW, Hong JM and Kim D. What is difficult about doing video-assisted thoracic surgery (VATS)? A retrospective study comparing VATS anatomical resection and conversion to thoracotomy for lung cancer in a university-based hospital. *J Thorac Dis* 2017; 9: 3825-3831.
- [16] Ng CS and Lau KK. Surgical trauma and immune functional changes following major lung resection. *Indian J Surg* 2015; 77: 49-54.
- [17] Park JS, Kim K, Choi MS, Chang SW and Han WS. Video-assisted thoracic surgery (VATS) lobectomy for pathologic stage I non-small cell lung cancer: a comparative study with thoracotomy lobectomy. *Korean J Thorac Cardiovasc Surg* 2011; 44: 32-38.
- [18] Yan TD, Black D, Bannon PG and McCaughan BC. Systematic review and meta-analysis of randomized and nonrandomized trials on safety and efficacy of video-assisted thoracic surgery lobectomy for early-stage non-small-cell lung cancer. *J Clin Oncol* 2009; 27: 2553-2562.
- [19] Long H, Tan Q, Luo Q, Wang Z, Jiang G, Situ D, Lin Y, Su X, Liu Q and Rong T. Thoracoscopic surgery versus thoracotomy for lung cancer: short-term outcomes of a randomized trial. *Ann Thorac Surg* 2018; 105: 386-392.
- [20] Ng CS, Wan IY and Yim AP. Impact of video-assisted thoracoscopic major lung resection on immune function. *Asian Cardiovasc Thorac Ann* 2009; 17: 426-432.
- [21] Walker WS and Leaver HA. Immunologic and stress responses following video-assisted thoracic surgery and open pulmonary lobectomy in early stage lung cancer. *Thorac Surg Clin* 2007; 17: 241-249.
- [22] Nobata H, Suga N, Itoh A, Miura N, Kitagawa W, Morita H, Yokoi T, Banno S and Imai H. Systemic AA amyloidosis in a patient with lung metastasis from renal cell carcinoma. *Amyloid* 2012; 19: 197-200.
- [23] Uso M, Jantus-Lewintre E, Bremnes RM, Calabuig S, Blasco A, Pastor E, Borreda I, Molina-Pinelo S, Paz-Ares L, Guijarro R, Martorell M, Forteza J, Camps C and Sirera R. Analysis of the immune microenvironment in resected non-small cell lung cancer: the prognostic value of different T lymphocyte markers. *Oncotarget* 2016; 7: 52849-52861.
- [24] Ng CS, Lee TW, Wan S, Wan IY, Sihoe AD, Arifi AA and Yim AP. Thoracotomy is associated with significantly more profound suppression in lymphocytes and natural killer cells than video-assisted thoracic surgery following major lung resections for cancer. *J Invest Surg* 2005; 18: 81-88.