

## Original Article

# Renoprotective effects of L-Carnitine in streptozotocin-induced diabetic nephropathy

Hailan Zheng<sup>1\*</sup>, Shangguo Piao<sup>1\*</sup>, Lijuan Sun<sup>2</sup>, Haiyan Zhao<sup>3</sup>, Jian Jin<sup>1,4,5</sup>, Jizhe Jin<sup>1</sup>, Chulwoo Yang<sup>4,5</sup>, Can Li<sup>1</sup>

Departments of <sup>1</sup>Nephrology, <sup>2</sup>Operating Theatre, <sup>3</sup>Health Examination Center, Yanbian University Hospital, Yanji, China; <sup>4</sup>Transplantation Research Center, Department of Internal Medicine, <sup>5</sup>Convergent Research Consortium for Immunologic Disease, Seoul St. Mary's Hospital, The Catholic University of Korea, Seoul, South Korea. \*Equal contributors.

Received October 27, 2017; Accepted March 19, 2018; Epub May 15, 2018; Published May 30, 2018

**Abstract:** *Aim:* L-Carnitine (LC) exerts protective effects on various types of injuries. This study aimed to investigate whether LC treatment would confer renoprotection in a rat model of streptozotocin (STZ)-induced diabetic nephropathy (DN). *Methods:* Diabetes was established by intraperitoneal STZ injection (65 mg/kg) in Sprague Dawley rats. Diabetic rats were treated daily for 12 weeks with LC (50 or 200 mg/kg/d intravenously). The effects of LC on STZ-induced DN were evaluated by assessing renal function, urinary protein excretion, histopathology, macrophage infiltration, expression of proinflammatory and prosclerotic cytokines, apoptotic cell death, oxidative stress, and expression of nuclear factor kappa B (NF- $\kappa$ B). *Results:* LC administration significantly decreased glomerulosclerosis, preserved the number of podocytes, and reduced macrophage infiltration, which accompanied with improvements in urinary protein excretion and renal dysfunction. At the molecular level, LC treatment suppressed expression of proinflammatory and prosclerotic cytokines, which paralleled by significant attenuation of NF- $\kappa$ B expression. LC treatment also attenuated increase of apoptotic cell death and oxidative stress. *Conclusion:* LC has a renoprotective effect on STZ-induced DN.

**Keywords:** L-Carnitine, diabetic nephropathy, oxidative stress, apoptosis, nuclear factor kappa B

## Introduction

Diabetes mellitus (DM) is the leading cause of end-stage renal disease (ESRD) worldwide. Despite strict control of glycemic and metabolic abnormalities, the percentage of diabetic patients entering ESRD because of DM remains as high as 40% [1, 2]. Diabetic nephropathy (DN) is a common and serious complication of DM requiring costly renal-replacement therapies such as dialysis or kidney transplantation. Therefore, minimizing incidence of DN may improve quality of life among people with DM and may reduce the overall burden on society. DN is characterized pathologically by glomerular inflammation, mesangial proliferation, and progressive glomerulosclerosis, eventually leading to proteinuria and renal failure [3]. Molecular mechanisms underlying the evolution of DN are extremely complex, and several mediators have been implicated. Of these, oxi-

dative stress, chemoattractants, fibrotic cytokines, and apoptosis have been proposed as important players [4-6].

L-Carnitine (LC,  $\beta$ -hydroxy- $\gamma$ -N-trimethyl ammonium-butyrate), a quaternary ammonium compound, is a cofactor required for the transport of long-chain fatty acids into the mitochondria for energy production in peripheral tissues. LC inhibits free radical generation, helping to prevent impairment of fatty acid beta-oxidation in mitochondria and protecting tissues from damage by repairing oxidized membrane lipids [7]. LC has also been reported to be a direct scavenger of  $O_2^{\cdot -}$  and  $H_2O_2$  [8]. There is overwhelming evidence that, through its antioxidative effects, LC supplementation plays a beneficial role in protecting against insulin resistance, diabetic podocyte injury, and diabetes-induced endothelial dysfunction [9, 10]. We have previously demonstrated that LC treatment protects

against cyclosporine A (CsA)-induced pancreatic and renal injury in rats [11]. The renoprotective effects of LC are also mirrored in prevention of ischemia-reperfusion injury [12], glycerol- and contrast-induced nephropathy [13, 14], hypertension-associated renal fibrosis [15, 16], cisplatin nephropathy [17], and doxorubicin-induced nephrotic syndrome [18]. However, its role in DN remains unexplored.

Considering the above mentioned findings, we hypothesized that LC would confer renoprotection against DN. To test this hypothesis, we investigated the effects of LC in a rat model of streptozotocin (STZ)-induced DN.

### Materials and methods

#### *Experiment and treatment schedule*

Male Sprague Dawley rats (Charles River, Technology, Korea) weighting 240-260 g were housed in individual cages in a temperature- and light-controlled environment and allowed free access to tap water and standard laboratory chow. The rats were randomly divided into six groups and treated daily for 12 weeks as follows: Control group (Con, n = 8): rats received saline (1 mL/kg/d intravenously, i.v.); Control plus LC 50 group (Con+LC50, n = 8): rats received saline and LC (50 mg/kg/d i.v.); Control plus LC 200 group (Con+LC200, n = 8): rats received saline and LC (200 mg/kg/d i.v.); Diabetic control group (DN, n = 8): diabetic rats received saline; Diabetes plus LC 50 group (DN+L50, n = 8): diabetic rats received LC (50 mg/kg/d i.v.); Diabetes plus LC 200 group (DN+L200, n = 8): diabetic rats received LC (200 mg/kg/d i.v.).

Diabetes was induced by a single intraperitoneal injection of STZ (65 mg/kg). Induction of diabetes was defined as the point at which blood glucose concentration was  $\geq 16.7$  mmol/L (300 mg/dL). LC treatment began at 2 weeks after confirmation of diabetes and was administered at two dosages of 50 or 200 mg/kg/d for 12 weeks. At 0, 4, 8, and 12 weeks, the animals were placed in individual metabolic cages (Tecniplast Gazzada S. a r.l., Italy), urine and blood samples were collected, rats were euthanized under ketamine anesthesia, and kidney tissues were rapidly removed for mor-

phological and molecular studies. Each group included eight rats at each time point. Dosages of LC used in this study were chosen based on previous reports [11, 19].

Our experimental protocol was approved by the Animal Care Committee of the Catholic University of Korea (CUMC-2016-0101-01).

#### *Biochemical examination*

Body weight (BW) was recorded periodically for each rat. Fasting blood glucose (FBG) concentration, serum creatinine (Scr) concentration, and 24-h urinary protein excretion (UPE) were measured at 0, 4, 8, and 12 weeks (Coulter Electronics, Inc., CA, USA).

#### *Histopathology*

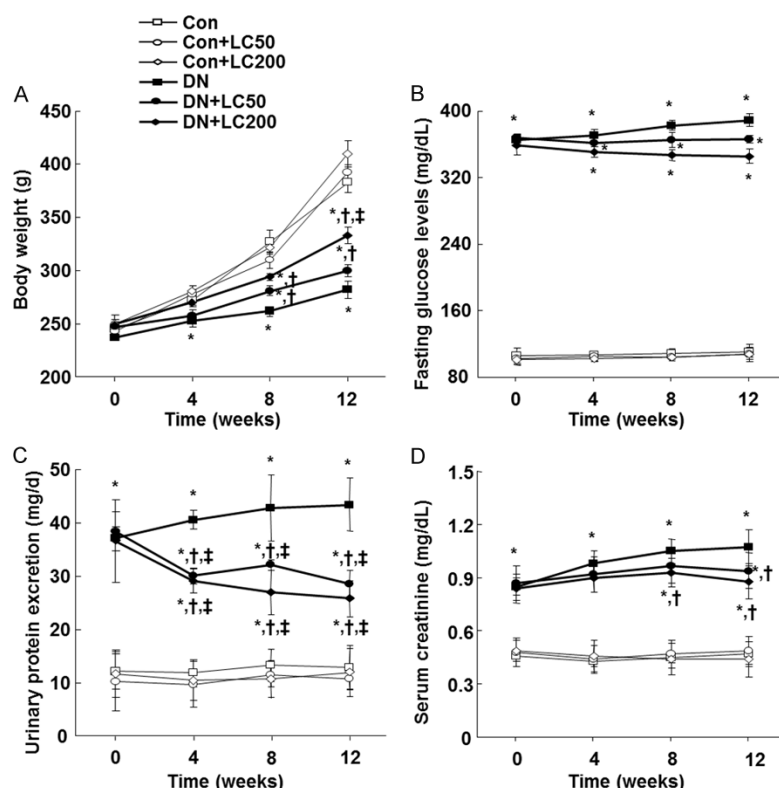
Kidney sections were stained with Periodic acid-Schiff (PAS) and Masson's trichrome. Evaluation of tubulointerstitial fibrosis (TIF) was performed as previously described [11, 20].

#### *Immunohistochemistry*

Sections were incubated for ED-1 (Serotec Inc., UK) and Wilms tumor protein (WT-1, Santa Cruz Biotechnology, CA). The number of WT-1- or ED-1-positive cells was evaluated by counting a minimum of 50 glomeruli/specimen in each section at  $\times 400$  magnification using a color image autoanalyzer (Polygon program, TDI Scope Eye Version 3.5 for Windows; Olympus, Japan).

#### *Electron microscopy*

For transmission electron microscopy, the kidneys were removed and fixed. Sections were washed in 0.1 M phosphate buffer (0.1 MPB). Isolated glomeruli were fixed in 50 mM sodium cacodylate buffer (pH 7.4) that contained 2% glutaraldehyde in paraformaldehyde for 30 minutes at 32°C, post fixed in 1% osmium tetroxide for 2 hours at 4°C, and dehydrated by treatment with a graded series of ethanol (5 minutes each in 50, 60, 70, 80, 90, and 95% and twice in 100%). Isolated glomeruli were treated with propylene oxide and embedded in Epon 812 according to standard procedures. One micrometer semithin sections were stained



**Figure 1.** Basic parameters during the treatment period. A. Body weight; B. FBG; C. UPE; D. Scr. \* $p < 0.05$  vs. Con; † $p < 0.05$  vs. DN; ‡ $p < 0.05$  vs. DN+LC50.

with toluidine blue to visualize general cell morphology. Ultrathin sections were cut, stained with lead citrate and photographed with a transmission electron microscope, JEOL 1200EX (Tokyo, Japan). Two adjacent toluidine blue stained semi thin sections 3  $\mu$ m apart were observed in pairs at a magnification of  $\times 10000$ , and nuclei present in the top section but not in the bottom section were counted and summed. Ten glomeruli in five rats from each group and 11 to 13 semithin sections from the mid glomerular area were examined.

#### Immunoblotting

Immunoblotting analyses were performed as previously described [11]. Monocyte chemoattractant protein-1 (MCP-1, Santa Cruz Biotechnology, Inc., USA), toll-like receptor-2 (TLR-2, Santa Cruz Biotechnology, Inc., USA), transforming growth factor-beta1 (TGF- $\beta$ 1, R&D Systems, Minneapolis, MN, USA), TGF- $\beta$ -inducible gene-3 ( $\beta$ ig-h3, Proteintech, Chicago, IL, USA), NF- $\kappa$ B (Santa Cruz Biotechnology, Inc., USA), I- $\kappa$ B (Santa Cruz Biotechnology, Inc., USA), Bcl-2

(Santa Cruz Biotechnology, CA, USA), active caspase-3 (Millipore, Billerica, Mass), and MnSOD (Abcam, Cambridge, MA) were detected with specific antibodies. Optical densities were obtained using the Con group as 100% reference and normalized with  $\beta$ -actin.

#### Enzyme linked immunosorbent assay

Urinary concentrations of DNA adduct 8-hydroxy-2'-deoxyguanosine (8-OHdG) were determined at 24 hours using a competitive enzyme-linked immunosorbent assay (Japan Institute for the Control of Aging, Shizuoka, Japan), according to manufacturer protocol. All samples were assayed in triplicate.

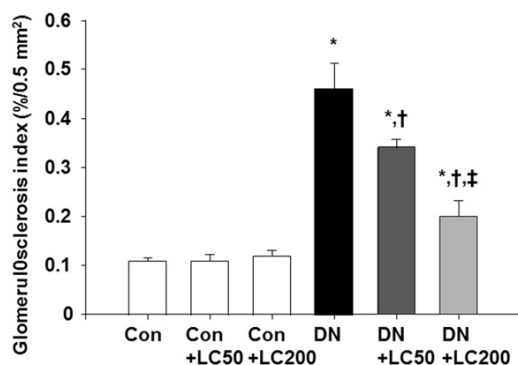
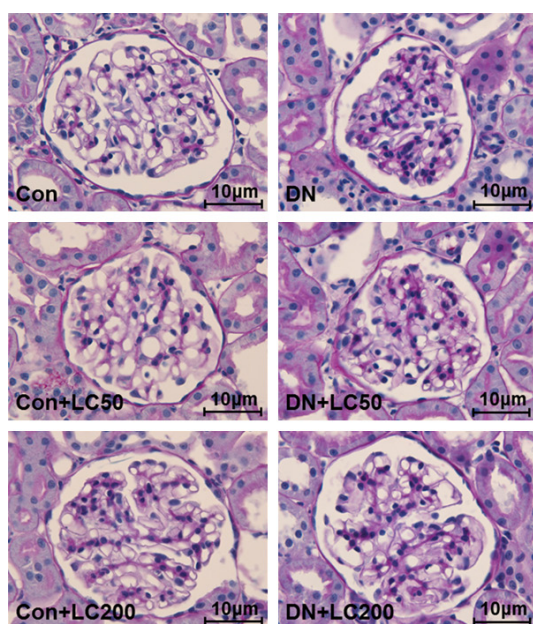
#### Statistical analysis

Data are expressed as mean  $\pm$  SEM. For all variables, values were compared with those of the control group because there were no significant differences between control and control plus LC 50 and 200 groups at any time point. Multiple comparisons between groups were performed using one-way ANOVA and Bonferroni post hoc test using SPSS software (version 19.0; IBM, Armonk, NY). Statistical significance was accepted at  $p < 0.05$ .

#### Results

##### Effects of LC on basic parameters

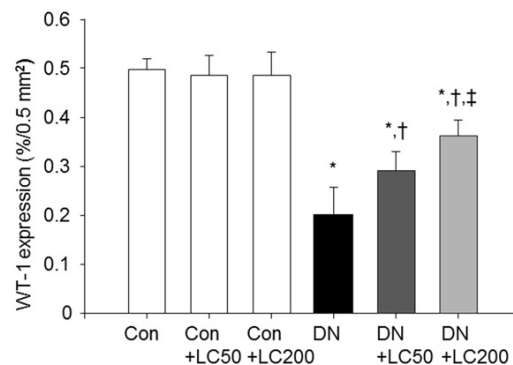
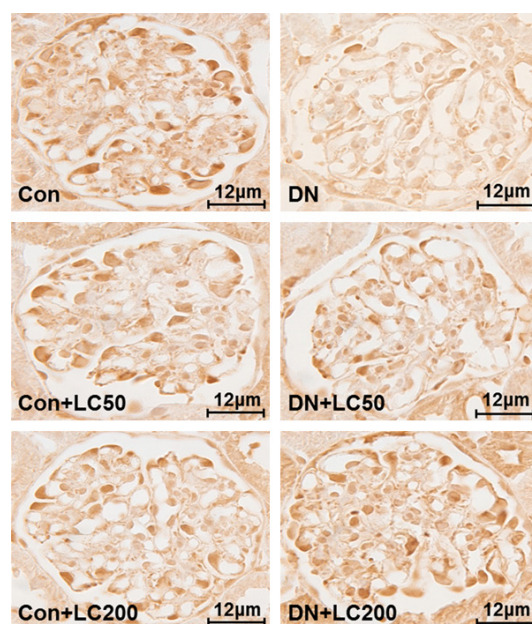
DN rats lost BW and exhibited an increase in FBG concentration. LC treatment at both dosages significantly prevented loss of BW (**Figure 1A**). FBG concentration did not differ significantly between experimental groups (**Figure 1B**). Renal dysfunction, as shown by increased UPE (**Figure 1C**) and Scr levels (**Figure 1D**) in DN rats, was significantly improved by administration of LC at both dosages compared with untreated diabetic rats.



**Figure 2.** Representative photomicrographs of PAS staining and semiquantitative analyses. Original magnification ( $\times 400$ ). \* $p < 0.05$  vs. Con; † $p < 0.05$  vs. DN; ‡ $p < 0.05$  vs. DN+LC50.

#### Effects of LC on histopathology

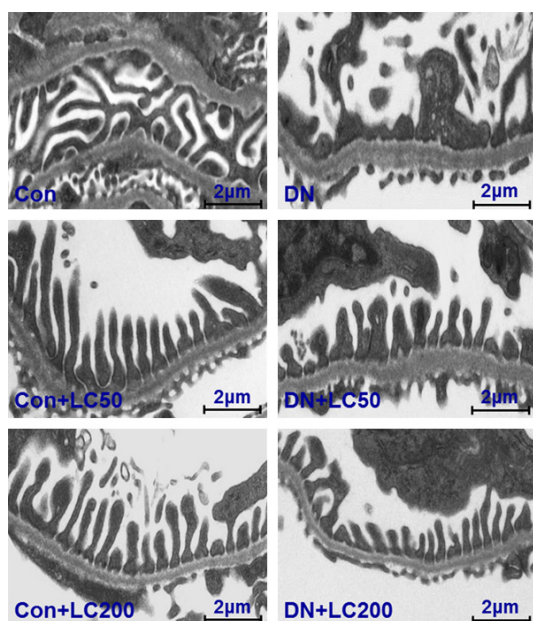
Rats with diabetes-induced renal injury showed typical histological features of glomerulopathy, characterized by glomerular hypertrophy, mesangial expansion, thickening of the basement membrane, arteriolar hyalinosis, and nodular or sclerosis (Figure 2). As assessed by our semi-quantitative scoring system, GSI was higher in the DN group than the Con group ( $0.453 \pm 0.059\%/0.5 \text{ mm}^2$  vs.  $0.142 \pm 0.032\%/0.5 \text{ mm}^2$ ,  $p < 0.01$ ). GSI was decreased markedly by LC administration in the lower dosage group (DN+LC50,  $0.369 \pm 0.043\%/0.5 \text{ mm}^2$  vs. DN,  $p < 0.05$ ) and was decreased further in the higher dosage group (DN+LC200,  $0.203 \pm 0.031\%/0.5 \text{ mm}^2$  vs. DN+LC50,  $p < 0.05$ ). To



**Figure 3.** Representative photomicrographs of immunohistochemistry for WT-1 and semiquantitative analyses. Original magnification ( $\times 400$ ). \* $p < 0.05$  vs. Con; † $p < 0.05$  vs. DN; ‡ $p < 0.05$  vs. DN+LC50.

detect podocyte injury, we used immunohistochemistry to examine WT-1 immunoreactivity. Glomerular expression of WT-1 was abundant in the Con group, as shown in Figure 3, whereas its immunoreactivity and number of WT-1-positive glomeruli were significantly lower in the DN group than in the Con group ( $0.208 \pm 0.018\%/0.5 \text{ mm}^2$  vs. DN,  $p < 0.05$ ). LC treatment preserved WT-1 expression and increased number of WT-1-positive cells. These effects were greater at the higher dose of LC ( $0.294 \pm 0.053\%/0.5 \text{ mm}^2$  vs. DN,  $0.385 \pm 0.023\%/0.5 \text{ mm}^2$  vs. DN+LC50,  $p < 0.05$ , respectively). Transmission electron microscopy showed that diabetic glomeruli exhibited severe damage such as glomerular basement membrane thickening and broadening of podocyte foot process





**Figure 4.** Representative photomicrographs of transmission electron microscopy for podocytes.

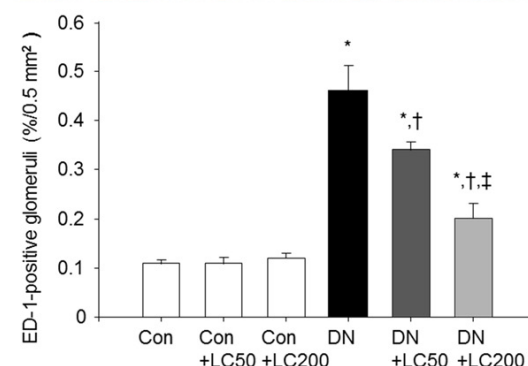
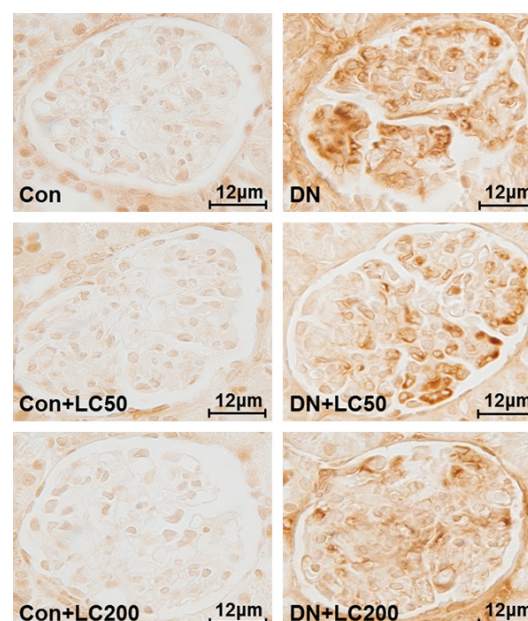
effacement, which is associated with a significant reduction in number of podocyte per glomerulus. By contrast, administration of LC preserved the ultrastructural appearance of podocytes (**Figure 4**).

#### Effects of LC on inflammation

ED-1-positive cells were rarely detected in glomeruli in the Con group (**Figure 5**, left panel), but the number increased significantly in glomeruli of the DN group ( $0.475 \pm 0.016\%/0.5 \text{ mm}^2$  vs. Con,  $p < 0.05$ ). Administration of LC decreased the number of ED-1-positive cells ( $0.343 \pm 0.036\%/0.5 \text{ mm}^2$  vs. DN,  $p < 0.05$ ). This decrease was more prominent at the higher dosage than lower dosage ( $0.206 \pm 0.042\%/0.5 \text{ mm}^2$  vs. DN+LC50,  $p < 0.05$ ). Immunoblotting showed markedly greater expression of MCP-1 and TLR-2 in the DN group than in the Con group (MCP-1:  $168.4 \pm 29.3\%$  vs.  $100.3 \pm 2.1\%$ ; TLR-2:  $221.4 \pm 32.7\%$  vs.  $100.6 \pm 2.4\%$ ,  $p < 0.01$ , respectively). LC dose dependently decreased the expression of these two proteins (**Figure 6**).

#### Effects of LC on TGF- $\beta$ 1 and $\beta$ ig-h3 expression

Immunoblotting revealed that diabetic rats displayed a marked upregulation in expression of TGF- $\beta$ 1 ( $279.2 \pm 16.8\%$  vs.  $100.4 \pm 5.3\%$ ,  $p < 0.01$ ) and  $\beta$ ig-h3 ( $240.2 \pm 21.5\%$  vs.  $101.8 \pm$



**Figure 5.** Representative photomicrographs of immunohistochemistry for ED-1 and semiquantitative analyses ( $\times 400$ ). \* $p < 0.05$  vs. Con; † $p < 0.05$  vs. DN; ‡ $p < 0.05$  vs. DN+LC50.

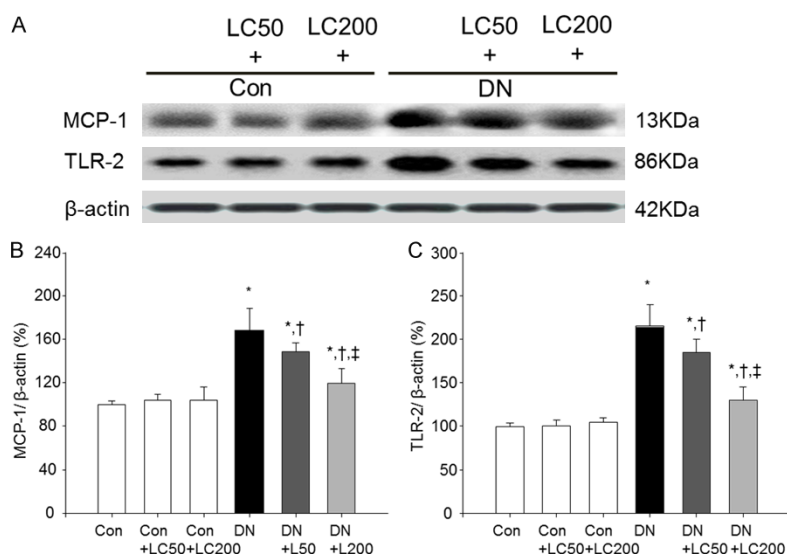
$3.2\%$ ,  $p < 0.01$ ) compared with the Con group, whereas LC suppressed their expression in a dose-dependent manner (**Figure 7**).

#### Effects of LC on NF- $\kappa$ B

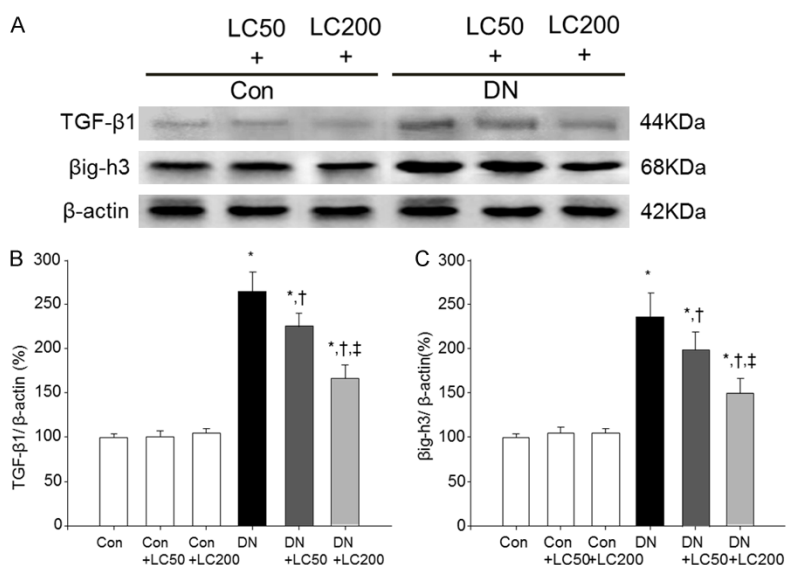
Induction of DN increased NF- $\kappa$ B protein expression ( $249.2 \pm 12.9\%$  vs.  $108.3 \pm 2.3\%$ ,  $p < 0.01$ ), accompanied by inhibition of I- $\kappa$ B protein expression ( $50.2 \pm 9.7\%$  vs.  $100.8 \pm 2.7\%$ ,  $p < 0.01$ ). However, this pattern was reversed by LC in a dose-dependent manner (**Figure 8**).

#### Effects of LC on apoptosis

Apoptotic cell death is attributed to the loss of podocyte in DN. We compared apoptosis-related gene expression between treatment groups.



**Figure 6.** Immunoblotting (A) and desitometric analysis (B and C) for MCP-1 and TLR-2 in the treatment groups. MCP-1 and TLR-2 protein expression values are represented relative to the Con reference group, which is designated as 100% and are normalized to β-actin. \* $p < 0.05$  vs. Con; † $p < 0.05$  vs. DN; ‡ $p < 0.05$  vs. DN+LC50.



**Figure 7.** Immunoblotting (A) and desitometric analysis (B and C) for TGF-β1 and βig-h3 in the treatment groups. TGF-β1 and βig-h3 protein expression values are represented relative to the Con reference group, which is designated as 100% and are normalized to β-actin. \* $p < 0.05$  vs. Con; † $p < 0.05$  vs. DN; ‡ $p < 0.05$  vs. DN+LC50.

Bcl-2 expression was downregulated ( $42.3 \pm 3.1\%$  vs. Con,  $p < 0.05$ ) in the DN group, but active caspase-3 was upregulated ( $172.6 \pm 9.8\%$  vs. Con,  $p < 0.05$ ). LC treatment at a dosage of 50 mg/kg/d significantly reversed these changes in expression of Bcl-2 and active cas-

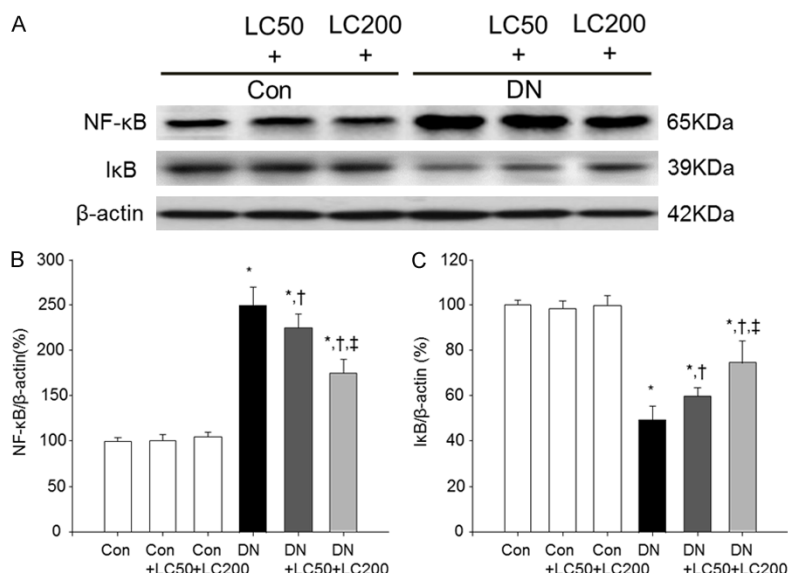
pase-3 proteins (Bcl-2:  $56.3 \pm 3.1\%$  vs. DN; caspase-3:  $143.9 \pm 2.4\%$ ,  $p < 0.05$ , respectively). This effect was more pronounced at the higher dosage of 200 mg/kg/d (Bcl-2:  $76.3 \pm 2.5\%$  vs. DN+LC50; caspase-3:  $121.7 \pm 3.8\%$ ,  $p < 0.05$ , respectively) (Figure 9).

#### Effects of LC on oxidative stress

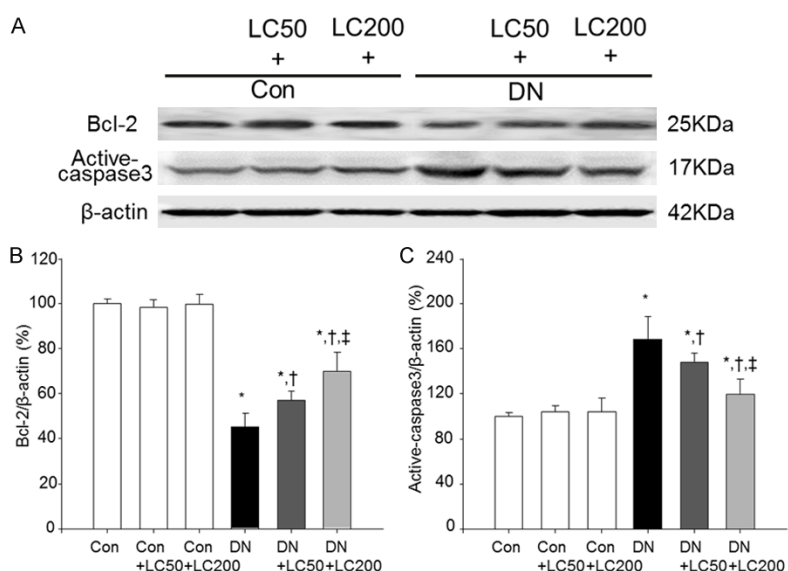
We examined markers of oxidative stress by measuring MnSOD expression and urinary 8-OHdG excretion in the treatment groups. As shown in Figure 10, MnSOD expression was suppressed in diabetic rats ( $56.4 \pm 4.5\%$  vs.  $100.5 \pm 2.7\%$ ,  $p < 0.01$ ) and was markedly upregulated by LC treatment in a dose-dependent manner (DN+LC50:  $64.7 \pm 3.8\%$  vs. DN; DN+LC200:  $79.6 \pm 7.9\%$  vs. DN+L50,  $p < 0.05$ , respectively). Urinary 8-OHdG excretion was  $83.8 \pm 9.3$  ng/day in the Con group and increased to  $165.2 \pm 37.2$  ng/day after induction of diabetes. By contrast, starting at 4 weeks and continuing throughout the treatment period, 8-OHdG excretion was significantly lower in the DN+LC50 (4W:  $228.3 \pm 12.9$  ng/day vs.  $255.9 \pm 8.9$  ng/day,  $p < 0.05$ ) and DN+LC200 (4W:  $205.7 \pm 15.3$  ng/day vs.  $255.9 \pm 8.9$  ng/day,  $p < 0.05$ ).

#### Discussion

Our present study clearly demonstrates that, in this rat model of STZ-induced DN, LC administration attenuates progression of glomerular inflammation and sclerosis by downregulating expression of pro-inflammatory and pro-sclerotic cytokines. These molecular modifications



**Figure 8.** Immunoblotting (A) and desitometric analysis (B and C) for NF-κB and IκB in the treatment groups. NF-κB and IκB expression values are represented relative to the Con reference group, which is designated as 100% and are normalized to β-actin. \* $p < 0.05$  vs. Con; † $p < 0.05$  vs. DN; ‡ $p < 0.05$  vs. DN+LC50.



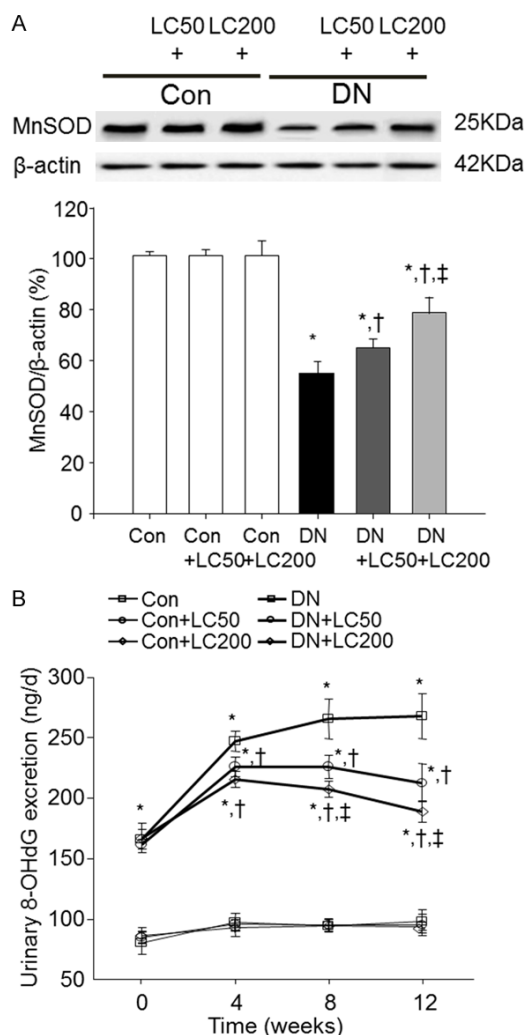
**Figure 9.** Immunoblotting (A) and desitometric analysis (B and C) for Bcl-2 and active caspase-3 in the treatment groups. Bcl-2 and active caspase-3 expression values are represented relative to the Con reference group, which is designated as 100% and are normalized to β-actin. \* $p < 0.05$  vs. Con; † $p < 0.05$  vs. DN; ‡ $p < 0.05$  vs. DN+LC50.

were accompanied by recovery from both renal dysfunction and proteinuria. Of note, there was no significant difference in FBG level between groups. Our study demonstrates, for the first time, that LC may protect against DN.

actions are not well known. Accumulating evidence has demonstrated that upregulation of βig-h3 together with overexpression of TGF-β1 correlates with renal tubulointerstitial fibrosis and glomerulosclerosis in chronic CsA nephrop-

LC inhibits pro-inflammatory cytokines (e.g. MCP-1, TNF-α, and IL-1) and macrophage infiltration and decreases TGF-β1 expression and extracellular matrix deposition in CsA- and contrast-induced renal injury [11, 13]. Therefore, LC may possess both anti-inflammatory and anti-fibrotic potential in kidneys. In this study, we found that LC significantly suppressed MCP-1, TLR-2, and TGF-β1 expression, and decreased the number of ED-1-positive cells in a dose-dependent manner. These changes were accompanied by marked improvement of renal dysfunction (UPE and Scr) and glomerulosclerosis (GSI). These findings are consistent with previous studies regarding anti-inflammatory and anti-fibrotic effects of LC in hemodialysis patients and rats with hypertension-associated renal fibrosis [15, 21]. These findings suggest that LC minimizes glomerular inflammation and sclerosis in STZ-induced DN through a mechanism involving decreased MCP-1, TLR-2, and TGF-β1 expression.

βig-h3 is a member of the extracellular matrix superfamily that interconnects different matrix components and resident cells to organize normal architecture of multiple organ systems including the kidney. However, its exact physiological and pathological func-



**Figure 10.** Immunoblotting for MnSOD (A) and urinary 8-OHdG concentrations (B) during the treatment period. MnSOD protein expression values are represented relative to the Con reference group, which is designated as 100% and are normalized to β-actin. \* $p < 0.05$  vs. Con; † $p < 0.05$  vs. DN; ‡ $p < 0.05$  vs. DN+LC50.

athy and DN, implying a pathological role of βig-h3 in disease [21, 22]. As a result, βig-h3 expression is considered to provide an index of TGF-β1 bioactivity and degree of renal injury in human and rats [20, 23, 24]. In this study, we found that increased βig-h3 protein expression in diabetic rat kidneys was significantly decreased by LC administration in a dose-dependent manner. This effect was paralleled with downregulation of TGF-β1. Our findings suggest that renoprotective effects of LC in diabetic rat kidneys may be related in part to its action on βig-h3.

Podocyte injury is a hallmark of DN. Podocyte loss has been strongly associated with proteinuria, glomerulosclerosis, and decreased GFR in Pima Indians with type II diabetes [25, 26]. Several cell death pathways account for podocyte death and apoptosis may play a major role. Exposure of mouse podocytes to high glucose concentrations can cause apoptosis. For example, in Akita and db/db mice, about one-third of cells exposed to high glucose concentration underwent apoptotic cell death [27] and podocyte apoptosis coincided with onset of urinary albumin excretion and preceded significant loss of podocytes [28]. Here, we observed that LC upregulated Bcl-2 expression but downregulated active caspase-3, which favored cell survival. These changes were associated with increased WT-1 immunoreactivity and preservation of podocytes (transmission electron microscopy) in diabetic rat kidneys. These findings are consistent with earlier studies showing that LC attenuates hydrogen peroxide-mediated oxidative stress in a human tubule epithelial cell line (HK-2) through inhibition of cell apoptosis and protects renal tubular cells (NRK-52E) from gentamicin-induced apoptosis [29, 30]. Taken together, these findings suggest that LC exerts anti-apoptotic effects.

Mechanisms by which LC diminished glomerular inflammation and sclerosis in this study may be multifactorial, but two possibilities should be considered. First, oxidative stress caused by chronic hyperglycemia plays a critical role in development of DN [31]. This concept was confirmed by a study demonstrating that antioxidative agents inhibited MCP-1 expression in cultured podocytes and TGF-β1 production in glomerular mesangial cells. LC has been shown to improve endothelial dysfunction, diabetes-induced liver damage [32], and hyper-coagulation states [33] in diabetic rats by suppressing oxidative stress. Second, NF-κB is activated by numerous physiological and non-physiological stimuli. Activation of NF-κB, in turn, governs expression of many genes that play critical roles in the pathogenesis of various kidney diseases. It is well known that a high glucose concentration directly or indirectly induces MCP-1 or TGF-β1 upregulation [34, 35] in podocytes [36] and mesangial cells [37] via phosphorylation of the NF-κB signaling pathway. LC confers antiinflammatory and antiapoptotic effects by modulating NF-κB in contrast- and carboplatin-



induced renal injury [13, 38]. In this study, we found that LC inhibited urinary 8-OHdG excretion, increased production of antioxidant enzyme MnSOD and regulated NF- $\kappa$ B subunit expression (NF- $\kappa$ B and I $\kappa$ B) in DN rats. We propose that the anti-inflammatory and antisclerotic effects of LC observed in this study are associated with interference in both oxidative stress and NF- $\kappa$ B signaling pathways.

One aspect to consider when interpreting our results is the effect of LC on FBG level. It is generally accepted that LC augments glucose oxidation by increasing mitochondrial efflux of excess acyl groups and stimulating carnitine acetyltransferase, thereby causing feedback suppression of fatty acid oxidation by relieving inhibition of pyruvate dehydrogenase complex, the rate-limiting enzyme in mitochondrial glucose oxidation [39]. Therefore, LC may improve insulin sensitivity, glucose disposal rate, and glucose tolerance in patients with type 2 DM and severe insulin resistance [40, 41]. We and others have previously reported that LC treatment ameliorated the blood glucose level in STZ-induced diabetic rats that were fed a high-fat diet or with CsA-associated diabetes [11]. However, the opposite result was observed by Sleem et al., who reported that LC protected against endothelial dysfunction beyond its effect on blood glucose level in STZ-induced diabetic rats fed a normal diet. In this study, we found that LC did not affect FBG level at any time point in the treatment groups. Reasons for these discrepancies in the response of blood glucose level to LC remain unknown but they may reflect use of different conditions (e.g., diet) and models of DM.

In current clinical practice, LC supplements are used to treat carnitine deficiency caused by genetic disorders or ESRD requiring hemodialysis. However, LC exerts antioxidative activity and may play diverse roles. It has been reported that LC can improve vascular injury in patients on hemodialysis [42] as well as ventricular arrhythmia and angina symptoms in patients experiencing acute myocardial infarction [43]. In diabetes and metabolic diseases, LC improves insulin resistance, promotes glucose oxidation, and has beneficial effects on diabetic peripheral neuropathy and hepatic steatosis in nonalcoholic fatty liver disease and diabetes [44]. On the basis of our results and previously outlined reports, it is likely that add-

ing LC to diabetes treatment as early as possible may provide extra benefits beyond attenuating DN. Future clinical trials are required to further investigate this issue.

In summary, our present study clearly shows that LC confers renoprotection through anti-inflammatory and anti-sclerotic effects in a rat model of DN. Inhibition of oxidative stress and NF- $\kappa$ B may be two underlying mechanisms of the beneficial effects of LC. Our study may provide a new avenue for administration of LC in the management of DN.

## Acknowledgements

This work was supported by the National Natural Science Foundation of China (No. 81560125; No. 81760293; No. 81760132), the Korean Health Technology R&D project, Ministry for Health & Welfare, Republic of Korea (HI14C3417), and Basic Science Research Program through the National Research Foundation of Korea (NRF) funded by the Ministry of Science, ICT & Future Planning (NRF-2015-R1A1A3A0400946).

## Disclosure of conflict of interest

None.

**Address correspondence to:** Can Li, Department of Nephrology, Yanbian University Hospital, #1327 Juzi Street, Yanji 133000, Jilin, China; Tel: +86-188-4333-0302; Fax: +86-433-251-3610; E-mail: lican@ybu.edu.cn

## References

- [1] Ahn JH, Yu JH, Ko SH, Kwon HS, Kim DJ, Kim JH, Kim CS, Song KH, Won JC, Lim S, Choi SH, Han K, Cha BY, Kim NH; Taskforce Team of Diabetes Fact Sheet of the Korean Diabetes Association. Prevalence and determinants of diabetic nephropathy in Korea: Korea national health and nutrition examination survey. *Diabetes Metab J* 2014; 38: 109-119.
- [2] Tuttle KR, Bakris GL, Bilous RW, Chiang JL, de Boer IH, Goldstein-Fuchs J, Hirsch IB, Kalantar-Zadeh K, Narva AS, Navaneethan SD, Neumiller JJ, Patel UD, Ratner RE, Whaley-Connell AT and Molitch ME. Diabetic kidney disease: a report from an ADA consensus conference. *Diabetes Care* 2014; 37: 2864-2883.
- [3] Li C, Yang CW, Park CW, Ahn HJ, Kim WY, Yoon KH, Suh SH, Lim SW, Cha JH, Kim YS, Kim J, Chang YS and Bang BK. Long-term treatment with ramipril attenuates renal osteopontin ex-

- pression in diabetic rats. *Kidney Int* 2003; 63: 454-463.
- [4] Yuan H, Zhang X, Zheng W, Zhou H, Zhang BY and Zhao D. Minocycline attenuates kidney injury in a rat model of streptozotocin-induced diabetic nephropathy. *Biol Pharm Bull* 2016; 39: 1231-1237.
- [5] Jin H, Piao SG, Jin JZ, Jin YS, Cui ZH, Jin HF, Zheng HL, Li JJ, Jiang YJ, Yang CW and Li C. Synergistic effects of leflunomide and benazepril in streptozotocin-induced diabetic nephropathy. *Nephron Exp Nephrol* 2014; 126: 148-156.
- [6] Qi XM, Wu GZ, Wu YG, Lin H, Shen JJ and Lin SY. Renoprotective effect of breviscapine through suppression of renal macrophage recruitment in streptozotocin-induced diabetic rats. *Nephron Exp Nephrol* 2006; 104: e147-e157.
- [7] Giudetti AM, Stanca E, Siculella L, Gnoni GV and Damiano F. Nutritional and hormonal regulation of citrate and carnitine/acylcarnitine transporters: two mitochondrial carriers involved in fatty acid metabolism. *Int J Mol Sci* 2016; 17.
- [8] Gulcin I. Antioxidant and antiradical activities of L-carnitine. *Life Sci* 2006; 78: 803-811.
- [9] Fan JP, Kim D, Kawachi H, Ha TS and Han GD. Ameliorating effects of L-carnitine on diabetic podocyte injury. *J Med Food* 2010; 13: 1324-1330.
- [10] Ringseis R, Keller J and Eder K. Role of carnitine in the regulation of glucose homeostasis and insulin sensitivity: evidence from in vivo and in vitro studies with carnitine supplementation and carnitine deficiency. *Eur J Nutr* 2012; 51: 1-18.
- [11] Xiang Y, Piao SG, Zou HB, Jin J, Fang MR, Lei DM, Gao BH, Yang CW and Li C. L-carnitine protects against cyclosporine-induced pancreatic and renal injury in rats. *Transplant Proc* 2013; 45: 3127-3134.
- [12] Liu Y, Yan S, Ji C, Dai W, Hu W, Zhang W and Mei C. Metabolomic changes and protective effect of (L)-carnitine in rat kidney ischemia/reperfusion injury. *Kidney Blood Press Res* 2012; 35: 373-381.
- [13] Kunak CS, Ugan RA, Cadirci E, Karakus E, Polat B, Un H, Halici Z, Saritemur M, Atmaca HT and Karaman A. Nephroprotective potential of carnitine against glycerol and contrast-induced kidney injury in rats through modulation of oxidative stress, proinflammatory cytokines, and apoptosis. *Br J Radiol* 2016; 89: 20140724.
- [14] Boyacioglu M, Turgut H, Akgullu C, Eryilmaz U, Kum C and Onbasili OA. The effect of L-carnitine on oxidative stress responses of experimental contrast-induced nephropathy in rats. *J Vet Med Sci* 2014; 76: 1-8.
- [15] Zambrano S, Blanca AJ, Ruiz-Armenta MV, Miguel-Carrasco JL, Arevalo M, Mate A and Vázquez CM. L-carnitine attenuates the development of kidney fibrosis in hypertensive rats by upregulating PPAR-gamma. *Am J Hypertens* 2014; 27: 460-470.
- [16] Zambrano S, Blanca AJ, Ruiz Armenta MV, Miguel-Carrasco JL, Arévalo M, Vázquez MJ, Mate A and Vázquez CM. L-carnitine protects against arterial hypertension-related cardiac fibrosis through modulation of PPAR-γ expression. *Biochem Pharmacol* 2013; 27: 937-944.
- [17] Tufekci O, Gunes D, Ozogul C, Kolatan E, Altun Z, Yilmaz O, Aktaş S, Erbayraktar Z, Kirkim G, Mutafoğlu K, Soylu A, Serbetçioglu B, Güneri EA and Olgun N. Evaluation of the effect of acetyl L-carnitine on experimental cisplatin nephrotoxicity. *Chemotherapy* 2009; 55: 451-459.
- [18] Boosanit D, Kanchanapangka S and Buranakarl C. L-carnitine ameliorates doxorubicin-induced nephrotic syndrome in rats. *Nephrology (Carlton)* 2006; 11: 313-320.
- [19] Arafa HM, Hemeida RA, Hassan MI, Abdel-Wahab MH, Badary OA and Hamada FM. Acetyl-L-carnitine ameliorates caerulein-induced acute pancreatitis in rats. *Basic Clin Pharmacol Toxicol* 2009; 105: 30-36.
- [20] Li C, Lim SW, Choi BS, Lee SH, Cha JH, Kim IS, Kim J and Yang CW. Inhibitory effect of pravastatin on transforming growth factor beta1-inducible gene h3 expression in a rat model of chronic cyclosporine nephropathy. *Am J Nephrol* 2005; 25: 611-620.
- [21] Shakeri A, Tabibi H and Hedayati M. Effects of L-carnitine supplement on serum inflammatory cytokines, C-reactive protein, lipoprotein (a), and oxidative stress in hemodialysis patients with Lp (a) hyperlipoproteinemia. *Hemodial Int* 2010; 14: 498-504.
- [22] Lee SH, Bae JS, Park SH, Lee BH, Park RW, Choi JY, Park JY, Ha SW, Kim YL, Kwon TH and Kim IS. Expression of TGF-beta-induced matrix protein betaig-h3 is up-regulated in the diabetic rat kidney and human proximal tubular epithelial cells treated with high glucose. *Kidney Int* 2003; 64: 1012-1021.
- [23] Sun BK, Li C, Lim SW, Choi BS, Lee SH, Kim IS, Kim YS, Bang BK and Yang CW. Blockade of angiotensin II with losartan attenuates transforming growth factor-beta1 inducible gene-h3 (betaig-h3) expression in a model of chronic cyclosporine nephrotoxicity. *Nephron Exp Nephrol* 2005; 99: e9-e16.
- [24] Gilbert RE, Wilkinson-Berka JL, Johnson DW, Cox A, Soulis T, Wu LL, Kelly DJ, Jerums G, Pollock CA and Cooper ME. Renal expression of transforming growth factor-beta inducible gene-h3 (beta ig-h3) in normal and diabetic rats. *Kidney Int* 1998; 54: 1052-1062.

- [25] Pagtalunan ME, Miller PL, Jumping-Eagle S, Nelson RG, Myers BD, Rennke HG, Coplon NS, Sun L, Meyer TM. Podocyte loss and progressive glomerular injury in type II diabetes. *J Clin Invest* 1997; 99: 342-348.
- [26] Lemley KV. Diabetes and chronic kidney disease: lessons from the Pima Indians. *Pediatr Nephrol* 2008; 23: 1933-1940.
- [27] Sun LN, Liu XC, Chen XJ, Guan GJ and Liu G. Curcumin attenuates high glucose-induced podocyte apoptosis by regulating functional connections between caveolin-1 phosphorylation and ROS. *Acta Pharmacol Sin* 2016; 37: 645-655.
- [28] Susztak K, Raff AC, Schiffer M and Böttinger EP. Glucose-induced reactive oxygen species cause apoptosis of podocytes and podocyte depletion at the onset of diabetic nephropathy. *Diabetes* 2006; 55: 225-233.
- [29] Ye J, Li J, Yu Y, Wei Q, Deng W and Yu L. L-carnitine attenuates oxidant injury in HK-2 cells via ROS-mitochondria pathway. *Regul Pept* 2010; 161: 58-66.
- [30] Chen HH, Sue YM, Chen CH, Hsu YH, Hou CC, Cheng CY, Lin SL, Tsai WL, Chen TW and Chen TH. Peroxisome proliferator-activated receptor alpha plays a crucial role in L-carnitine anti-apoptosis effect in renal tubular cells. *Nephrol Dial Transplant* 2009; 24: 3042-9.
- [31] Chen F, Zhang N, Ma X, Huang T, Shao Y, Wu C and Wang Q. Naringin alleviates diabetic kidney disease through inhibiting oxidative stress and inflammatory reaction. *PLoS One* 2015; 10: e0143868.
- [32] Shaker ME, Houssen ME, Abo-Hashem EM and Ibrahim TM. Comparison of vitamin E, L-carnitine and melatonin in ameliorating carbon tetrachloride and diabetes induced hepatic oxidative stress. *J Physiol Biochem* 2009; 65: 225-233.
- [33] ElGendy AA and Abbas AM. Effects of warfarin and L-carnitine on hemostatic function and oxidative stress in streptozotocin-induced diabetic rats. *J Physiol Biochem* 2014; 70: 535-546.
- [34] Xiong F, Li X, Yang Z, Wang Y, Gong W, Huang J, Chen C, Liu P and Huang H. TGR5 suppresses high glucose-induced upregulation of fibronectin and transforming growth factor-beta1 in rat glomerular mesangial cells by inhibiting RhoA/ROCK signaling. *Endocrine* 2016; 54: 657-670.
- [35] Quan Y, Jiang CT, Xue B, Zhu SG and Wang X. High glucose stimulates TNFalpha and MCP-1 expression in rat microglia via ROS and NF-kappaB pathways. *Acta Pharmacol Sin* 2011; 32: 188-193.
- [36] Chen XW, Liu WT, Wang YX, Chen WJ, Li HY, Chen YH, Du XY, Peng FF, Zhou WD, Xu ZZ and Long HB. Cyclopropanyldehydrocostunolide LJ attenuates high glucose-induced podocyte injury by suppressing RANKL/RANK-mediated NF-kappaB and MAPK signaling pathways. *J Diabetes Complications* 2016; 30: 760-769.
- [37] Yang X, Wang Y and Gao G. High glucose induces rat mesangial cells proliferation and MCP-1 expression via ROS-mediated activation of NF-kappaB pathway, which is inhibited by eleutheroside E. *J Recept Signal Transduct Res* 2016; 36: 152-157.
- [38] Sue YM, Chou HC, Chang CC, Yang NJ, Chou Y and Juan SH. L-carnitine protects against carboplatin-mediated renal injury: AMPK- and PPARalpha-dependent inactivation of NFAT3. *PLoS One* 2014; 9: e104079.
- [39] Power RA, Hulver MW, Zhang JY, Dubois J, Marchand RM, Ilkayeva O, Muoio DM and Mynatt RL. Carnitine revisited: potential use as adjunctive treatment in diabetes. *Diabetologia* 2007; 50: 824-832.
- [40] Noland RC, Koves TR, Seiler SE, Lum H, Lust RM, Ilkayeva O, Stevens RD, Hegardt FG and Muoio DM. Carnitine insufficiency caused by aging and overnutrition compromises mitochondrial performance and metabolic control. *J Biol Chem* 2009; 284: 22840-22852.
- [41] Muoio DM, Noland RC, Kovalik JP, Seiler SE, Davies MN, DeBalsi KL, Ilkayeva O, Stevens RD, Kheterpal I, Zhang J, Civington JD, Bajpeyi S, Ravussin E, Kraus W, Koves TR and Mynatt RL. Muscle-specific deletion of carnitine acetyltransferase compromises glucose tolerance and metabolic flexibility. *Cell Metab* 2012; 15: 764-777.
- [42] Fukami K, Yamagishi S, Sakai K, Kaida Y, Yokoro M, Ueda S, Wada Y, Takeuchi M, Shimizu M, Yamazaki H and Okuda S. Oral L-carnitine supplementation increases trimethylamine-N-oxide but reduces markers of vascular injury in hemodialysis patients. *J Cardiovasc Pharmacol* 2015; 65: 289-295.
- [43] Dinicolantonio JJ, Niazi AK, McCarty MF, Lavie CJ, Liberopoulos E and O'Keefe JH. L-carnitine for the treatment of acute myocardial infarction. *Rev Cardiovasc Med* 2014; 15: 52-62.
- [44] Bae JC, Lee WY, Yoon KH, Park JY, Son HS, Han KA, Lee KW, Woo JT, Ju YC, Lee WJ, Cho YY and LeeMK. Improvement of nonalcoholic fatty liver disease with carnitine-orotate complex in type 2 diabetes (CORONA): a randomized controlled trial. *Diabetes Care* 2015; 38: 1245-1252.